

# Morphology of suprascapular notch in medieval skeletons from Bulgaria

D. Toneva, S. Nikolova

*Institute of Experimental Morphology, Pathology and Anthropology with Museum, Bulgarian Academy of Sciences, Sofia, Bulgaria*

[Received 28 October 2013; Accepted 25 November 2013]

*The suprascapular notch is situated in the lateral part of the superior border of the scapula, just medial to the base of the coracoid process, giving passage for the suprascapular nerve. The aim of this study is to determine the frequency of different types of suprascapular notch in male and female medieval skeletal series and to assess the sexual differences. The shape of the notch was classified into 5 types, based on the scheme given by Alekseev. A total of 102 scapulae and scapular fragments were investigated. The results show that the deep notch was the most common. In the left female scapulae the shallow notch was frequently observed as well. Three cases of suprascapular foramen, which is considered as a risk factor for suprascapular nerve neuropathy, were observed and there was a double foramen in one of them, which is a very rare case. According to the results of  $\chi^2$  test, there were no significant sexual differences in the distribution of notch types. Our results illustrate that there were some individuals among the investigated medieval population potentially affected by suprascapular nerve entrapment syndrome and their way of living may have been impacted by the symptoms accompanying this condition. (Folia Morphol 2014; 73; 2: 210–215)*

**Key words:** suprascapular nerve, suprascapular foramen, suprascapular nerve entrapment, superior transverse suprascapular ligament

## INTRODUCTION

The suprascapular notch (SSN) is situated in the lateral part of the superior border of the scapula, just medial to the base of the coracoid process, giving passage for the suprascapular nerve. The suprascapular nerve provides sensory innervation to the posterosuperior aspect of the shoulder and motor innervation to supraspinatus and infraspinatus muscles and its dysfunction is intimately associated with rotator cuff pathology [30].

The shape of the SSN shows wide variety, ranging from an absence of the notch through differently deep notches to a presence of a small opening instead of the notch. There are many studies on the morphology of the

SSN, but most of them are devoted to the cases, in which the SSN is converted to a foramen, because of the ossification of superior transverse scapular ligament. These cases are associated with suprascapular entrapment neuropathy [5, 8, 10, 24]. Avery et al. [4] and Polguy et al. [26] considered the ossification of anterior coracoscapular ligament, which causes a reduction in the height of the suprascapular foramen, also as a possible aetiologic factor in suprascapular nerve entrapment. According to Ofusori et al. [21], the complete absence of the SSN could be considered as a possible cause of suprascapular nerve entrapment as well.

Data about the frequency of the types of SSN, and suprascapular foramen in particular, are published



**Figure 1.** Types of suprascapular notch (SSN) (the scheme is taken from Alekseev's handbook [2]). Types: 1 — the superior border of the scapula passes smoothly into the base of the coracoid process without a depression; 2 — the march of the superior border towards the end of SSN is clearly pronounced, but the notch is shallow; 3 — the SSN is deep and its border outlines approximately 3/4 of the circumference; 4 — the border of the SSN outlines nearly full circumference; 5 — the SSN is converted into a complete bony foramen.

for different contemporary populations. However, there are scarce or missing data about this topic in the ancient populations as well as about the sexual differences in the distribution of the types of SSN. Therefore, the aim of this study is to determine the frequency of different types of SSN, based on its shape, in male and female medieval skeletal series and to assess the sexual differences.

## MATERIALS AND METHODS

A total of 102 (51 male, 51 female) scapulae and scapular fragments were investigated. The osteological material was collected from medieval necropolises in the territory of Northeastern Bulgaria (9<sup>th</sup>–11<sup>th</sup> century AD). Skeletal sex and age were determined by standard anthropological methods [3, 6]. The shape of the notch was classified into 5 types, according to the scheme given by Alekseev [2]. The shape was determined depending on the march of the superior border towards the SSN (Fig. 1): type 1 — the superior border of the scapula passes smoothly into the base of the coracoid process without a depression, i.e. absence of the SSN; type 2 — the march of the superior border towards the end of SSN is clearly pronounced, but the notch is shallow; type 3 — the SSN is deep and its border outlines approximately 3/4 of the circumference; type 4 — the border of the SSN outlines nearly full circumference; type 5 — the SSN is converted into a complete bony foramen. A  $\chi^2$  test was used

to assess sexual differences in the distribution of the types of SSN.

## RESULTS

The distribution of the various types of suprascapular notches is illustrated in Table 1.

The most common type in both right and left male and right female scapulae was type 3, and in the second place was type 2 (Fig. 2). In the left female scapulae, most frequently observed type of the notch was the shallow notch (type 2), followed by the deep one (type 3). The absence of the SSN was in the third place. Three scapulae with suprascapular foramen (type 5) were observed and there was a double foramen in one of them. It should be noticed that all 3 cases were observed in female scapulae.

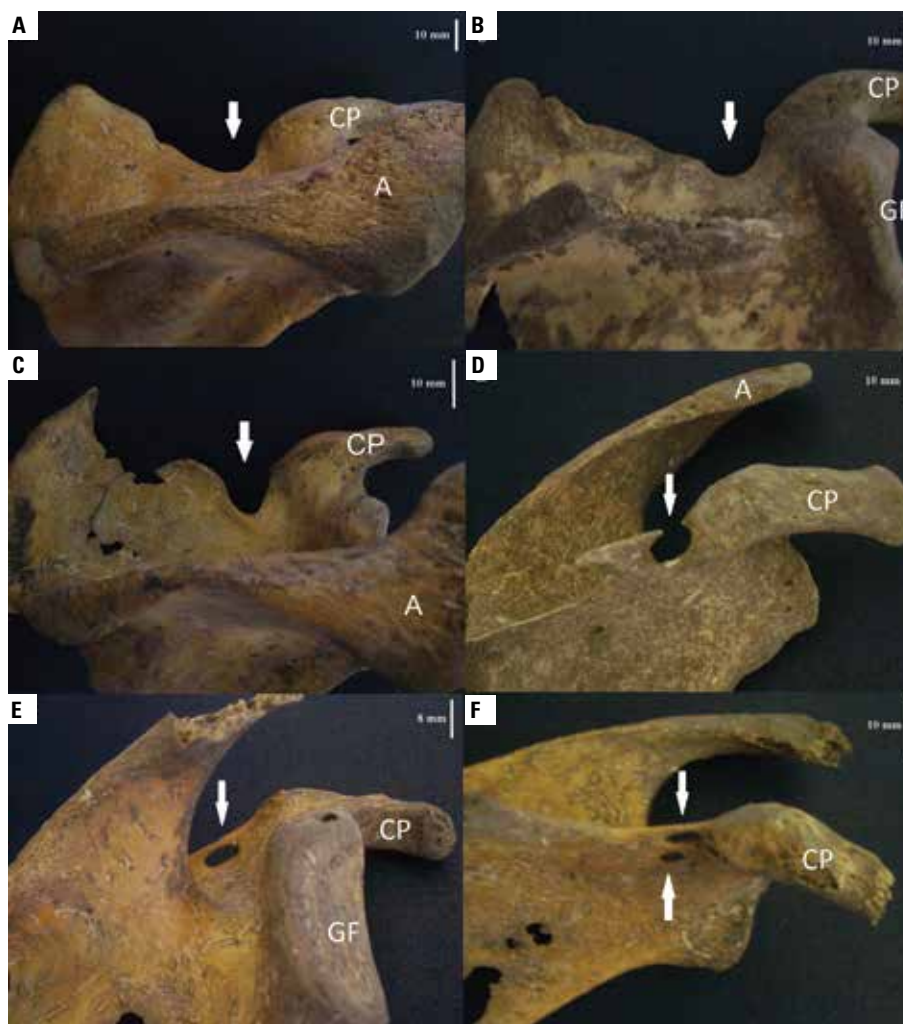
According to the results of  $\chi^2$  test, there were no significant sexual differences in the distribution of the types of SSN. The distributions in the right scapulae of both sexes were almost identical. Although there were no significant sexual differences in the left scapulae, type 3 in the left male scapulae was nearly twice as frequently observed as in the left female ones and the other types were reported with greater frequency in the left female scapulae.

## DISCUSSION

The SSN is an anatomical structure of great clinical importance because it is a probable site

**Table 1.** Frequency of the types of suprascapular notch in both male and female scapulae

Laterality	Sex	Type 1	Type 2	Type 3	Type 4	Type 5
Right	Male	4 (16.7%)	7 (29.2%)	11 (45.8%)	2 (8.3%)	0 (0%)
	Female	4 (16.0%)	6 (24.0%)	11 (44.0%)	3 (12.0%)	1 (4.0%)
Left	Male	3 (11.1%)	5 (18.5%)	16 (59.3%)	3 (11.1%)	0 (0%)
	Female	5 (19.2%)	8 (30.8%)	7 (26.9%)	4 (15.4%)	2 (7.7%)
Total		16 (15.7%)	26 (25.5%)	45 (44.1%)	12 (11.8%)	3 (2.9%)



**Figure 2.** Scapulae showing different notch types; **A.** Absence of the suprascapular notch (type 1); **B.** Shallow notch (type 2); **C.** Deep notch (type 3); **D.** Partial ossification of the superior transverse suprascapular ligament (type 4); **E.** Complete ossification of the superior transverse suprascapular ligament (suprascapular foramen) (type 5); **F.** Double suprascapular foramen; A — acromion; CP — coracoid process; GF — glenoid fossa.

of suprascapular nerve compression. According to Odita et al. [20], the ossification of coracoid process influences the shape of the notch.

Various authors have classified the SSN on the basis of scapular features or measurements, such as vertical and transversal diameters of the notch. Rengachary et al. [28] observed six basic types of SSN. Natsis et al. [19] distinguished 5 types of the notch on the basis of specific geometrical parameters. Ticker et al. [35] reported 2 types of the notch — “U” and “V” types. Iqbal et al. [13] separated the notches into 3 types — “U”, “V” and “J” types, without involving any measurements. Wang et al. [37] have found a new variable morphology of the SSN with a double suprascapular foramen. The clas-

sification of SSN that was used in our study is simple and does not require complicated measurements, and it makes possible to very easily distinguish the three types of the notch — its absence (type 1) and the partial and complete ossification of the superior transverse suprascapular ligament (types 4 and 5), which are supposed to be risk factors for suprascapular entrapment neuropathy.

The results of the present study show that the most common type of SSN is type 3, which corresponds to a deep notch. According to Wang et al. [37] and Soni et al. [33], the most common type in their samples is the type, where the notch has longer transversal diameter than the vertical length. The results of Natsis et al. [19] show an equal inci-

dence of the types, where the notch is longest in its transverse diameter or it is longest in its vertical length. Mahdy and Shehab [17] also reported close values of these 2 types, but with slightly prevalence of the type with longer transverse diameter than the vertical one. However, Sinkeet et al. [32] found in a higher frequency the type with longer vertical diameter. As we did not use metrical parameters for determination of the types, we could assume that our types 2 (a shallow notch) and 3 (a deep notch), which are together the most common types, correspond with both most common types established by the other authors. In this way, our results are in accordance to a great extent with the study of Sinkeet et al. [32], where the deep notches were the most prevalent too. But results obtained by us strongly differ from these ones of Wang et al. [37] and Soni et al. [33], who reported a shallower notch in very high percentages — 58.16% and 72%, respectively.

The complete absence of SSN has been supposed to be a predisposing factor for suprascapular nerve entrapment syndrome, because of the possibility of compression of the suprascapular nerve by the superior transverse scapular ligament on the superior border of the scapula [21]. Our results show absence of the notch in 15.7%, which is a medial value in relation to the results of other authors — 2.12% [32], 5% [33], 7.65% [14], 8.3% [19], 18% [34], 22.5% [13] and 28% [37].

The variations of the superior transverse suprascapular ligament, including partial or complete ossification, are considered to be main predisposing factors in cases of suprascapular nerve entrapment. The compression of the suprascapular nerve at the notch can result in suprascapular neuropathy. Kopell and Thompson [16] were the first to define a suprascapular neuropathy syndrome. The common symptoms of the suprascapular neuropathy are a deep, diffuse and dull shoulder pain, weakness in external rotation and abduction of the upper extremity, and atrophy of both supraspinatus and infraspinatus muscles [9, 24, 30]. Cohen et al. [7] described 2 cases of entrapment of the suprascapular nerve from a calcified superior transverse scapular ligament, and both patients were members of the same family, which suggests a genetic precondition for the ossification. Mistry et al. [18] established that the ossified superior transverse suprascapular ligament was more frequently observed in the right scapulae than the left ones.

There are many studies devoted to the complete ossification of the superior transverse suprascapular ligament, because of the necessity of better understanding and interpretation of the causes and mechanisms leading to the development of suprascapular neuropathy syndrome and the great importance of these cases for the surgical and arthroscopic practices. The frequency of the complete and partial ossifications of the superior transverse suprascapular ligament varies in different population groups (Table 2). Our result (2.9%) is generally lower than the results of other authors.

The presence of a double suprascapular foramen is a very rare anatomical finding. Such a case has been described only few times [11, 23, 37]. The coexistence of 2 foramina in the place of SSN is very likely to increase the risk of suprascapular neuropathy, because of additional narrowing of the suprascapular nerve passage. Polguy et al. [23] proposed 4 potential hypotheses of double suprascapular foramen formation. The probable mechanism of formation in cases with parallel course of both bony bridges, as it is in our case, is that either the upper bony bridge was created by ossification of the single bundle superior transverse scapular ligament and the lower one was created by the osseous transformation of the anterior coracoscapular ligament, or both bridges were formed as a result of the ossification of the superior and inferior bands of the trifid superior transverse scapular ligament. As the trifid superior transverse scapular ligament was reported on rare occasions in the literature [25, 35], whereas the frequency of anterior coracoscapular ligament varied up to 60% [4], the formation of the lower bony bridge by ossification of the anterior coracoscapular ligament seems to be more probable explanation.

As a whole, there have been very few studies concerning the sexual differences in the shape of the SSN. Finnegan [12] reported that sexual differences in the presence of suprascapular foramen were significant in the right scapulae of the White Americans ( $p < 0.01$ ) and in the right bones of the Black Americans ( $p < 0.05$ ). But no significant sexual differences were established in our study. According to the results of Polguy et al. [27], the distribution of the SSN types in both sexes was similar too. Albino et al. [1] concluded in their study that the type of the SSN is not related

**Table 2.** Frequency (%) of ossifications of the superior transverse scapular ligament in different populations

Researchers	Complete ossification	Partial ossification	Sample
Silva et al. [31] (Brasil)	30.76	–	221
Mistry et al. [17] (India)	19.4	25	180
Bayramoglu et al. [5] (Turkey)	12.5	–	32
Polguy et al. [27] (Poland)	7.4	24.7	81
Natsis et al. [19] (Germany)	7.3	–	423
Polguy et al. [22] (Poland)	7	24.4	86
Vallois [36] (Italy)	6.1	–	152
Ticker et al. [35] (USA)	5	–	79
Rengachary et al. [28] (USA)	4	–	211
Sinkeet et al. [32] (Kenya)	4	–	138
Albino et al. [1] (Italy)	3.6	–	500
Edelson [10] (USA)	3.7	8.1	1000
Mahdy and Shehab [17] (Egypt)	3.03	–	132
Wang et al. [37] (China)	3	–	295
Soni et al. [33] (India)	3	11	100
Sutaria et al. [34] (India)	3	7	314
Sangam et al. [29] (India)	1.93	5.76	104
Kajava [15] (Finland)	1.5	–	133
Present study	2.9	11.8	102

to the sex and age of the individuals. As far as the completely ossified superior transverse ligament is concerned, Polguy et al. [27] established that it was more frequent in females than in males (9.1% vs. 4.9%). Our results confirm the more common ossification of the superior transverse ligament in the female scapulae, because we did not observe it in any of the male bones.

### CONCLUSIONS

The knowledge of the anatomical variations of SSN is very important for clinical and surgery practices, since the shape of the notch could be a predisposing factor for a compression of the suprascapular nerve. Results reported in the present work illustrate that there were some individuals among the investigated medieval population potentially affected by suprascapular nerve entrapment syndrome and their way of living may have been impacted by the symptoms accompanying this condition.

### ACKNOWLEDGEMENTS

This work was supported by the European Social Fund and Republic of Bulgaria, Operational Program-

me "Human Resources Development" 2007–2013 framework, Grant No. BG051PO001-3.3.06-0048 from 04.10.2012.

### REFERENCES

- Albino P, Carbone S, Candela V, Arceri V, Vestri AR, Gumina S (2013) Morphometry of the suprascapular notch: correlation with scapular dimensions and clinical relevance. *BMC Musculoskeletal Disorders*, 14: 172.
- Alekseev VP (1966) *Osteometriya*. Nauka, Moscow [in Russian].
- Alekseev VP, Debets GF (1964) *Kraniometriya*. Nauka, Moscow [in Russian].
- Avery BW, Pilon FM, Barclay JK (2002) Anterior coracoscapular ligament and suprascapular nerve entrapment. *Clin Anat*, 15: 383–386.
- Bayramoglu A, Demiryurek D, Tuccar E, Erbil M, Aldur MM, Tetik O, Doral MN (2003) Variations in anatomy at the suprascapular notch possibly causing suprascapular nerve entrapment: an anatomical study. *Knee Surg Sport Trum Arthros*, 11: 393–398.
- Buikstra JE, Ubelaker DH (1994) Standards for Data Collection from Human Skeletal Remains. *Arkansas Archaeological Survey Research Series No. 44*, Fayetteville.
- Cohen SB, Dines DM, Moorman CT (1997) Familial calcification of the superior transverse scapula ligament causing neuropathy. *Clin Orthop Rel Res*, 334: 131–135.
- Cummins CA, Messer TM, Number GW (2000) Suprascapular nerve entrapment. *J Bone Joint Surg Am*, 82: 415–424.

9. Das S, Suri R, Kapur V (2007) Ossification of superior transverse scapular ligament and its clinical implications. *Sultan Qaboos Univ Med J*, 7: 157–160.
10. Edelson JG (1995) Bony bridges and other variations of the suprascapular notch. *J Bone Joint Surg Br*, 77: 505–506.
11. Hrdlicka A (1942) The adult scapula: additional observations and measurements. *Am J Phys Antropol*, 29: 363–415.
12. Finnegan M (1978) Non-metric variation of the infracranial skeleton. *J Anat*, 125: 23–37.
13. Iqbal K, Iqbal R, Khan SG (2010) Anatomical variations in shape of suprascapular notch of scapula. *J Morphol Sci*, 27: 1–2.
14. Jadhav SD (2012) The suprascapular notch: its various shapes in Indian dry scapulae. *Res J Pharmaceutical, Biological Chem Sci*, 3: 1085–1090.
15. Kajava Y (1924) Über den Schultergürtel der Finen. *Ann Acad Sci Fenn*, 21: 1–69.
16. Kopell HP, Thompson WA (1959) Pain and the frozen shoulder. *Surg Gynecol Obstet*, 109: 92–96.
17. Mahdy AA, Shehab AA (2013) Morphometric variations of the suprascapular notch as a potential cause of neuropathy: anatomical study. *J Am Sci*, 9: 189–197.
18. Mistry P, Chauhan K, Mehta C, Patil D, Bansal M, Suthar K (2013) A study of incidence of ossification of superior transverse scapular ligament of scapula and its clinical implications. *Int J Basic Applied Med Sci*, 3: 41–45.
19. Natsis K, Totlis T, Tsikaras P, Appell HJ, Skandalakis K (2007) Proposal for classification of the suprascapular notch: a study on 423 dried scapulas. *Clin Anat*, 20: 135–139.
20. Odita JC, Ugboadaga VI, Omene JA, Okolo AA (1983) Humeral head and coracoid ossification in Nigerian newborn infants. *Paediatric Radiol*, 13: 276–278.
21. Ofusori D, Ude R, Okwuonu Ch, Adesanya O (2008) Complete absence of the suprascapular notch in a Nigerian scapula: a possible cause of suprascapular nerve entrapment. *Int J Shoul Surg*, 2: 85–86.
22. Polguy M, Jędrzejewski K, Podgórski M, Topol M (2011) Morphometric study of the suprascapular notch: proposal of classification. *Surg Radiol Anat*, 33: 781–787.
23. Polguy M, Podgórski M, Jędrzejewski K, Topol M (2012) The double suprascapular foramen: unique anatomical variation and the new hypothesis of its formation. *Skeletal Radiol*, 41: 1631–1636.
24. Polguy M, Jędrzejewski K, Majos A, Topol M (2012) Variations in bifid superior transverse scapular ligament as a possible factor of suprascapular entrapment: an anatomical study. *Int Orthop*, 36: 2095–2100.
25. Polguy M, Jędrzejewski K, Majos A, Topol M (2012) The trifid superior transverse scapular ligament: a case report and review of the literature. *Folia Morphol*, 71: 118–120.
26. Polguy M, Jędrzejewski K, Topol M (2013) Variable morphology of the anterior coracoscapular ligament: a proposal of classification. *Ann Anat*, 195: 77–81.
27. Polguy M, Jędrzejewski K, Topol M (2013) Sexual dimorphism of the suprascapular notch: morphometric study. *Arch Med Sci*, 9: 177–183.
28. Rengachary SS, Burr D, Lucas S, Hassanein KM, Mohn MP, Matzke H (1979) Suprascapular entrapment neuropathy: a clinical, anatomical, and comparative study. Part 2: Anatomical study. *Neurosurgery*, 5: 447–451.
29. Sangam MR, Sarada Devi SS, Krupadanam K, Anasuya K (2013) A study on the morphology of the suprascapular notch and its distance from the glenoid cavity. *J Clin Diagn Res*, 7: 189–192.
30. Shi LL, Freehill MT, Yannopoulos P, Warner JP (2012) Suprascapular nerve: is it important in cuff pathology? *Advances Orthoped*, 2012.
31. Silva JG, Abidu-Figueiredo M, Fernandes RMP, Aureliano-Rafael F, Sgrott EA, Silva SF, Babinski MA (2007) High incidence of complete ossification of the superior transverse scapular ligament in Brazilians and its clinical implications. *Int J Morphol*, 25: 855–859.
32. Sinkeet SR, Awori KO, Odula PO, Ogeng'o JA, Mwachaka PM (2010) The suprascapular notch: its morphology and distance from the glenoid cavity in a Kenyan population. *Folia Morphol*, 69: 241–245.
33. Soni G, Malik VS, Shukla L, Chhabra S, Gaur N (2012) Morphometric analysis of the suprascapular notch. *Internet J Biol Anthropol*, 5: 1.
34. Sutaria LK, Nayak TV, Patel SV, Jadav HR, Pensi CA (2013) Morphology and morphometric analysis of suprascapular notch. *Int J Biomed Advance Res*, 4: 35–39.
35. Ticker JB, Djurasovic M, Strauch RJ, April EW, Pollock RG, Flatow EL, Bigliani LU (1998) The incidence of ganglion cysts and variations in anatomy along the course of the suprascapular nerve. *J Shoulder Elbow Surg*, 7: 472–478.
36. Vallois HV (1926) Variations de la cavité glénoïde de l'omoplate. *Soc Biol Comptes Rendus Hebdomadaires Soc Seances et Inenoriores*, 94: 559–560.
37. Wang HJ, Chen C, Wu LP, Pan CQ, Zhang WJ, Li YK (2011) Variable morphology of the suprascapular notch: an investigation and quantitative measurements in Chinese population. *Clin Anat*, 24: 47–55.