

Laryngeal nerve “anastomoses”

L. Naidu, L. Lazarus, P. Partab, K.S. Satyapal

Department of Clinical Anatomy, School of Laboratory Medicine and Medical Sciences, College of Health Sciences, University of KwaZulu-Natal, Westville Campus, Durban, South Africa

[Received 5 July 2013; Accepted 29 July 2013]

Laryngeal nerves have been observed to communicate with each other and form a variety of patterns. These communications have been studied extensively and have been of particular interest as it may provide an additional form of innervation to the intrinsic laryngeal muscles. Variations noted in incidence may help explain the variable position of the vocal folds after vocal fold paralysis. This study aimed to examine the incidence of various neural communications and to determine their contribution to the innervation of the larynx. Fifty adult cadaveric en-bloc laryngeal specimens were studied. Three different types of communications were observed between internal and recurrent laryngeal nerves viz. (1) Galen’s anastomosis (81%): in 13%, it was observed to supply the posterior cricoarytenoid muscle; (2) thyroarytenoid communication (9%): this was observed to supply the thyroarytenoid muscle in 2% of specimens and (3) arytenoid plexus (28%): in 6%, it supplied a branch to the transverse arytenoid muscle. The only communication between the external and recurrent laryngeal nerves was the communicating nerve (25%). In one left hemi-larynx, the internal laryngeal nerve formed a communication with the external laryngeal nerve, via a thyroid foramen. The neural communications that exist in the larynx have been thought to play a role in laryngeal innervation. The results of this study have shown varying incidences in neural communications. Contributions from these communications have also been noted to various intrinsic laryngeal muscles which may be a possible factor responsible for the variable position of the vocal folds in certain cases of vocal fold paralysis. (Folia Morphol 2014; 73, 1: 30–36)

Key words: Galen’s anastomosis, thyroarytenoid, arytenoid

INTRODUCTION

Laryngeal nerves have been observed to communicate with each other and form a variety of patterns. These communications have been studied extensively and have been of particular interest as it has been considered a factor responsible for the variable position of the vocal folds after vocal fold paralysis [20]. Communications have been observed to occur between the (1) internal and recurrent laryngeal nerves; (2) external and recurrent laryngeal nerves and (3) internal and external laryngeal nerves [20]. Sañudo et al. [20] further classified the communication between the internal and recurrent

laryngeal nerves into four categories viz. (1) Galen’s anastomosis; (2) arytenoid plexus; (3) thyroarytenoid communication and (4) cricoid communication.

Communication between internal and recurrent laryngeal nerves

Galen’s anastomosis. Recent investigators describe Galen’s anastomosis as the direct connection between the posterior branch of the internal laryngeal nerve and the recurrent laryngeal nerve [13, 20] and that it is located over the posterior surface of the posterior cricoarytenoid, transverse and oblique aryte-

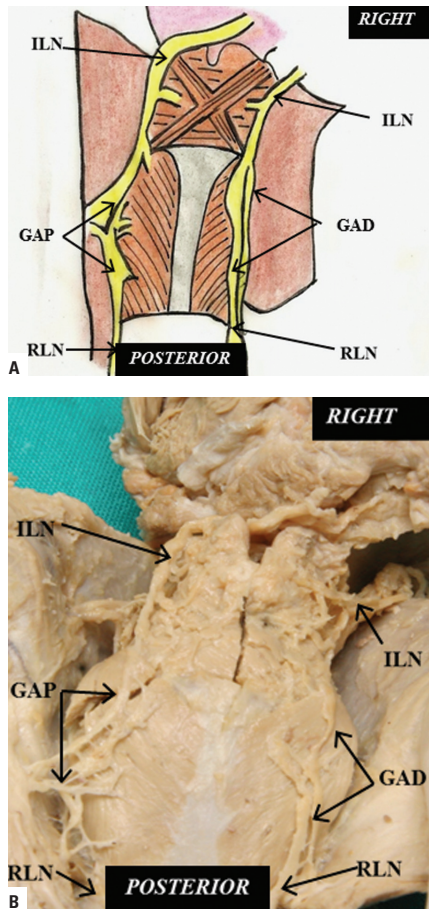


Figure 1. Schematic representation (A) and cadaveric dissection (B) of Galen's anastomosis (posterior view); ILN — internal laryngeal nerve; RLN — recurrent laryngeal nerve; GAP — Galen's anastomosis; GAD — Galen's anastomosis double trunk.

noid muscles under the mucosa of the hypopharynx [3] (Fig. 1A).

Arytenoid plexus. Sañudo et al. [20] stated that this neural connection is related to the transverse arytenoid muscle which functions to close the rima glottidis (inlet of the larynx). The arytenoid plexus is a connection between the arytenoid branch from the posterior division of the internal laryngeal nerve and the anterior branch of the recurrent laryngeal nerve: in their series this was located superficial (86%; 74/90) or deep (100%; 90/90) to the arytenoid muscle (Fig. 2A). Their study further demonstrated branches from the deep arytenoid plexus contributing to the transverse arytenoid muscle and sensory branches to the posterior commissure of the larynx (in 100% of the specimens dissected). In addition, connections from side to side were observed between the arytenoid branches of the internal and recurrent laryngeal nerves (observed in all of the 90 specimens they dissected).

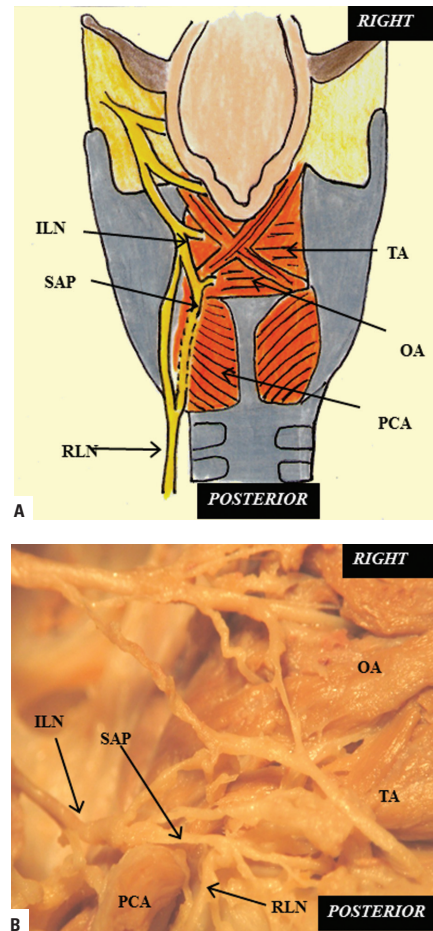


Figure 2. Schematic representation (A) and cadaveric dissection (B) of superficial arytenoid plexus (left posterior view); ILN — internal laryngeal nerve; RLN — recurrent laryngeal nerve; SAP — superficial arytenoid plexus; TA — transverse arytenoid muscle; OA — oblique arytenoid muscle; PCA — posterior cricoarytenoid muscle.

A further investigation that studied this communication has suggested that it allows axons from the superior laryngeal nerve to cross over to the recurrent laryngeal nerve in the area of the transverse arytenoid muscle, and then travel inferiorly to innervate the posterior cricoarytenoid muscle and possibly also other intrinsic laryngeal muscles [19].

Thyroarytenoid communication. According to Sañudo et al. [20], the thyroarytenoid communication is formed by the union of a descending branch which originates from the anterior branch of the internal laryngeal nerve and an ascending branch which arises from the recurrent laryngeal nerve, just after the latter nerve passes over the cricothyroid joint (Fig. 3A). This pattern was present in 14 % (13/90) of their hemilarynges and was located over the thyroarytenoid muscle. No branches were observed from this communication and its functions are yet to be determined [20]. On the other hand, recent

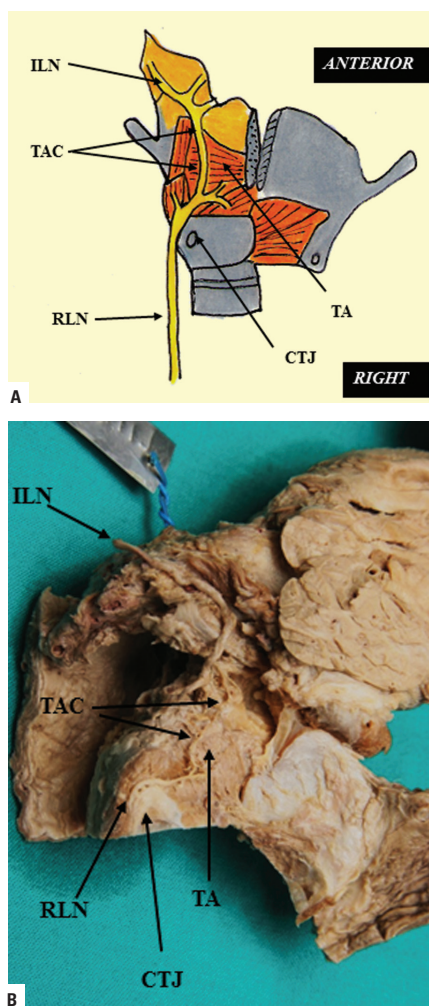


Figure 3. Schematic representation (A) and cadaveric dissection (B) of the thyroarytenoid communication located over the superficial surface of the thyroarytenoid muscle (right lateral view); TA — thyroarytenoid muscle; ILN — internal laryngeal nerve; TAC — thyroarytenoid communication; CTJ — cricothyroid joint; RLN — recurrent laryngeal nerve.

investigations by Marañillo et al. [9], observed a branch from the thyroarytenoid communication to the thyroarytenoid muscle in 1% (1/75) of larynges.

Cricoid communication. The cricoid communication is formed from a superior branch originating from the deep part of the arytenoid plexus and an inferior branch arising from the connection of 2 smaller branches originating from each recurrent laryngeal nerve before their entrance into the larynx [20]. The cricoid communication was located anterior to the cricoid lamina and was observed to give off branches to the mucosa of the posterior surface of the subglottis. The precise role of this communication has yet to be established. This communication was found in 60% (6/10) of the specimens studied by Sañudo et al. [10].

Table 1. Incidence of communicating nerve in the literature

Author [Reference]	Number of hemilarynges	Incidence (%)
Dilworth (1921) [2]	46	43
Mayet (1956) [10]	20	5
Meng and Li (1976) [11]	100	41
Kambic et al. (1984) [4]	90	1.2
Sanders et al. (1993) [19]	20	20
Wu et al. (1994) [26]	27	44
Tanaka and Tanebe (1997) [23]	30	3
Sañudo et al. (1999) [20]	180	68
Kreyer and Pomaroli (2000) [6]	112	2.7
Marañillo et al. (2003) [9]	206	85
Weighted mean		45.7
Current study	100	25

Communication between external and recurrent laryngeal nerves (the “communicating nerve”)

Dilworth [2] described a submucosal communication between the external laryngeal nerve and the recurrent laryngeal nerve. Since then, numerous names have been used to describe this communication such as the “communicating nerve” [19, 26], the “piriform nerve” [19] and the “cricothyroid anastomosis” [20]. A review of the literature reveals a variable incidence of this communication from 1.2% up to 85% (Table 1).

Authors who have studied this communication have suggested that it has no significance as far as laryngeal muscle innervation is concerned [7] and that these neural branches are entirely sensory [5, 24].

According to Wu et al. [26], the external branch of the superior laryngeal nerve enters the cricothyroid muscle and it exits the medial surface to form the communicating nerve. The communicating nerve passes between the piriform sinus mucosa and lateral cricoarytenoid muscle to enter the lateral surface of the thyroarytenoid muscle (Fig. 4A). Upon its entrance to the thyroarytenoid muscle, it usually divides into 2 branches, one that is presumed sensory as it terminates in the subglottic mucosa and the cricoarytenoid joint, and the second branch is presumed motor because it joins with the recurrent laryngeal nerve to supply the thyroarytenoid muscle or terminates directly among the thyroarytenoid muscle fibres. In addition, they stated further that the communicating nerve may be the nerve of the 5th pharyngeal arch, a structure that has never been identified by anatomists [26]. Kreyer and Pomaroli [6] suggested that there may be rare occurrences of dysphagia and difficulties with phonation following severing of the superior laryngeal nerve because of the

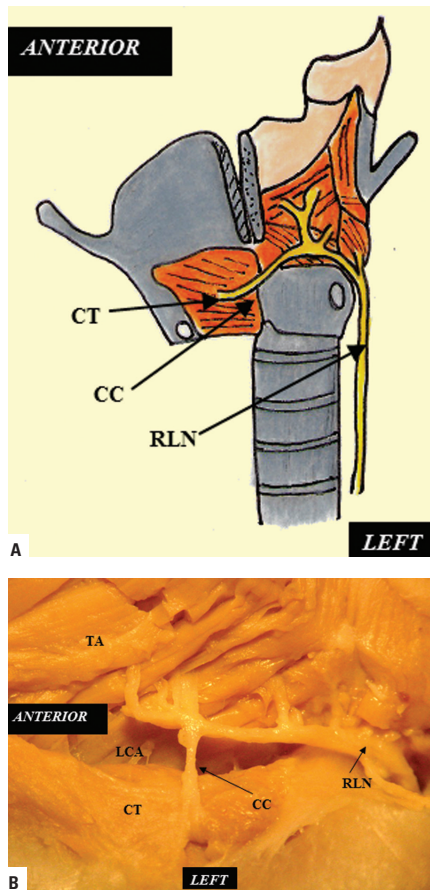


Figure 4. Schematic representation (A) and cadaveric dissection (B) of the communicating nerve (left lateral view); CT — cricothyroid muscle; LCA — lateral cricoarytenoid muscle; TA — thyroarytenoid muscle; CC — communicating nerve; RLN — recurrent laryngeal nerve.

existence of an external anastomosis between the superior and recurrent laryngeal nerves.

Communication between internal and external laryngeal nerves

The communication between the internal laryngeal and the external laryngeal nerves exist via the thyroid foramen (when present) and was observed in 95% (19/20) of specimens studied by Sañudo et al. [20] (Fig. 5A). Partab et al. [15] also observed a single case in which the right internal laryngeal nerve communicated with the external laryngeal nerve through the thyroid foramen.

This study thus aimed to examine the incidence of the various neural communications, as well as to determine their contribution to the innervation of the larynx.

MATERIALS AND METHODS

The study comprised a sample size of 50 adult cadaveric en-bloc laryngeal specimens. Each laryngeal specimen contained the hyoid bone, larynx, oesophagus, trachea and the inferior constrictor muscle of the pharynx. These

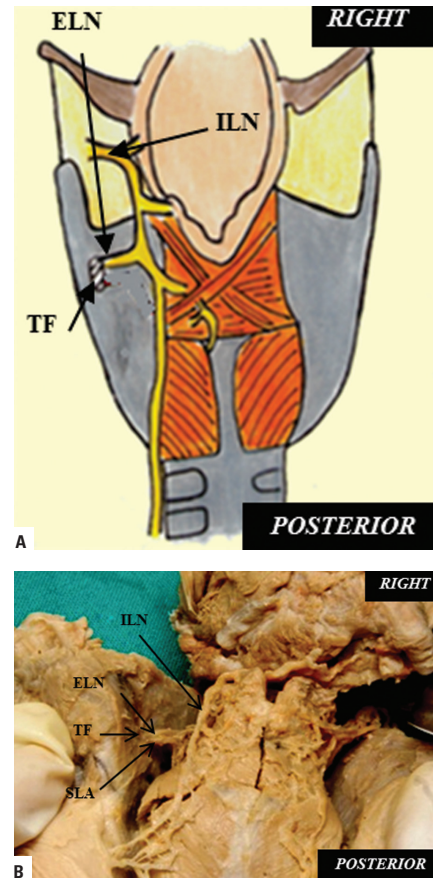


Figure 5. Schematic representation (A) and cadaveric dissection (B) of the internal and external laryngeal nerve communication via a thyroid foramen; ILN — internal laryngeal nerve; ELN — external laryngeal nerve; TF — thyroid foramen; SLA — superior laryngeal artery.

specimens (which formed part of a bank of specimens used for routine teaching in the undergraduate programme) were obtained from the Department of Clinical Anatomy, University of KwaZulu Natal (UKZN), (Westville and Nelson R Mandela School of Medicine campuses), and Durban University of Technology, in accordance with the Human Tissue Act (No. 65 of 1983) and National Health Act (No. 61 of 2003). Ethical clearance was obtained from the Bio-Medical Research Ethics Committee of UKZN (Ethics number BE131/08).

Standard anatomical micro-dissection techniques were employed to dissect the larynges with the aid of a Stemi DV4 light microscope (Carl Zeiss Inc, Germany). The fascia surrounding the internal and recurrent laryngeal nerves were removed and their branches to the laryngeal musculature were traced.

Sigma Stat (ver. 3.5) using the Student t test was utilised for all statistical comparisons between right and left sides. A p value < 0.05 was used to denote a statistically significant difference. A χ^2 test was used to determine differences in the incidence between right and left sides

of all neural communications as well as differences in the incidence between right and left sides of the distribution of all neural communications.

RESULTS

Neural connections were observed between (1) the internal and recurrent laryngeal nerves; (2) the external and the recurrent laryngeal nerves; (3) the internal and the external laryngeal nerves (via the thyroid foramen).

Communication between the internal and the recurrent laryngeal nerves

Three different types of communications were observed between the internal and the recurrent laryngeal nerves viz. Galen's anastomosis, thyroarytenoid communication and arytenoid plexus.

Galen's anastomosis. *Morphology:* Galen's anastomosis was formed by the union of the posterior division of the recurrent laryngeal nerve and the most inferior descending division of the internal laryngeal nerve, after each had given off their muscular branches. It was located over the posterior surface of the transverse and oblique arytenoid and the posterior cricoarytenoid muscles. *Incidence:* Galen's anastomosis was present in 81% (81/100) of the hemilarynges dissected (left: 80%, 40/50; right: 82%, 41/50). There was no statistically significant difference noted between right and left sides (χ^2 test = 14.662 with 34 degrees of freedom; $p = 0.998$). The anastomosis was observed to exhibit 3 different patterns viz. single trunk (71%; 71/100) double trunk (5%; 5/100) and plexus formation (5%; 5/100) (Figs. 1A, B). In the remaining 19% (19/100) of sides there was no union between the internal and recurrent laryngeal nerves, instead these nerves terminated within the mucosa of the larynx. *Distribution:* In 13% (13/100) of dissections, Galen's anastomosis was observed to give branches to the posterior cricoarytenoid muscle. In the remaining 87% (87/100) sides no muscular branches were given off.

Arytenoid plexus. *Morphology:* An arytenoid plexus was formed from the union between the arytenoid branches of the internal laryngeal nerve and the anterior branch of the recurrent laryngeal nerve (after the recurrent laryngeal nerve passed superiorly deep to the posterior cricoarytenoid muscle). It was found to be in relation to the transverse arytenoid muscle (Figs. 2A, B). *Incidence:* An arytenoid plexus was present in 28% (28/100) of hemilarynges dissected (left: 38%, 19/50; right: 18%, 9/50). A statistically significant difference was noted between right and left sides (p value: $0.001 < 0.05$). *Distribution:* In 6% (6/100) of cases, the arytenoid plexus was observed to

give a branch to the transverse arytenoid muscle (left: 10%, 5/50; right: 2%, 1/50). There was no statistically significant difference between sides ($p = 0.998$).

Thyroarytenoid communication. *Morphology:* Directly after the recurrent laryngeal nerve passed over the cricothyroid joint, it gave off an ascending branch that united with a descending branch from the middle trunk of the internal laryngeal nerve. This anastomosis was vertical, and located over the superficial surface of the thyroarytenoid muscle (Figs. 3A, B). *Incidence:* The thyroarytenoid communication was present in 9% (9/100) of dissections (left: 12%, 6/50; right: 6%, 3/50). There was no statistically significant difference between right and left sides ($p = 0.998$). *Distribution:* In 2% (2/100) of cases (left: 2%, 1/50; right 2%, 1/50) the thyroarytenoid communication was observed to supply the thyroarytenoid muscle. There was no statistically significant difference between sides ($p = 0.998$).

Cricoid communication. This communication was not encountered in any of the specimens dissected in the current series.

Communication between the external and the recurrent laryngeal nerves (the "communicating nerve")

The communication between the external laryngeal and the recurrent laryngeal nerves (cricothyroid connection) occurred in the piriform fossa. *Morphology:* After the external laryngeal nerve supplied the cricothyroid muscle, it passed through the aforementioned muscle to enter the larynx, where it connected with the anterior branch of the recurrent laryngeal nerve (Figs. 4A, B). *Incidence:* The "communicating nerve" was present in 25% (25/100) of the hemilarynges dissected (left: 24%, 12/50; right: 26%, 13/50). There was no statistically significant difference between sides ($p = 0.998$).

Communication between internal and external laryngeal nerves via a thyroid foramen

The internal laryngeal nerve formed an anastomosis with the external laryngeal nerve, via a thyroid foramen (Figs. 5A, B). *Morphology:* In this specimen, a branch of the external laryngeal nerve passed through a foramen in the thyroid cartilage, (together with the superior laryngeal artery), and united with a branch from the middle trunk of the internal laryngeal nerve. *Incidence:* This was observed in one left hemilarynx. *Distribution:* It was found to terminate in the mucosa of the true and false vocal cords.

DISCUSSION

The following neural communications as described by Sañudo et al. [10] were observed in the current study viz. Galen’s anastomosis, formation of an arytenoid plexus, the thyroarytenoid communication, communication between the external and recurrent laryngeal nerves (“communicating nerve”) and the communication between the internal laryngeal and the external laryngeal nerves (via a thyroid foramen). Each of these neural communications will be discussed in-seriatim.

Communication between the internal and the recurrent laryngeal nerves

Galen’s anastomosis. Galen’s anastomosis when present (81%), was formed by the union of the descending division of the internal laryngeal nerve and the posterior division of the recurrent laryngeal nerve [13]. It was located over the posterior surface of the transverse and oblique arytenoid and posterior cricoarytenoid muscles; this concurs with descriptions from studies conducted by Sañudo et al. [20] as well as Furlan et al. [3]. The weighted mean incidence of Galen’s anastomosis (77.3%) calculated from a review of the literature (Table 2) compared favourably with the present finding of 81%.

Arytenoid plexus. According to studies conducted by Sanders et al. [19] and Sañudo et al. [20], the superficial arytenoid plexus was formed by the connection between the arytenoid branches of the internal laryngeal nerve and the anterior branch of the recurrent laryngeal nerve (after the recurrent laryngeal nerve passed upward deep to the posterior cricoarytenoid muscle). It was related to the transverse arytenoid muscle. The current series noted an incidence of 28% which differed from the calculated weighted mean of 93% obtained from a review of the literature (Table 3).

Thyroarytenoid connection. A thyroarytenoid communication was formed directly after the recurrent laryngeal nerve passed over the cricothyroid joint. It gave an ascending branch that united with a descending branch from the middle trunk of the internal laryngeal nerve and was located over the superficial surface of the thyroarytenoid muscle. The weighted mean incidence of 8.1% calculated from a review of the literature compared favourably with the present finding of 9% (Table 4). In 2% of cases, branches from this communication to the thyroarytenoid muscle were observed. There were no statistically significant differences between sides. This finding has also been previously recorded by Marañillo et al. [9], but differs from reports by Sañudo et al. [20] who observed no branches from this communication.

Table 2. Incidence of Galen’s anastomosis in the literature

Author [Reference]	Sample size	Incidence (%)
Berlin and Lahey (1929) [1]	12	25.0
Nordland (1930) [14]	19	15.8
Lemere (1932) [7]	10	Non-constant
Williams (1951) [25]	60	75.0
Pichler and Giesal (1957) [16]	100	100
Reuger (1972) [17]	19	89.5
Scouza et al. (1981) [22]	150	42.0
Migueis et al. (1981) [12]	47	88.0
Schweizer and Dorfl (1997) [21]	32	84.4
Sañudo et al. (1999) [20]	180	100
Libermann-Meffert et al. (1999) [8]	6	33.3
Furlan et al. (2002) [3]	100	87.0
Weighted mean		77.3
Current study	100	81

Table 3. Incidence of arytenoid plexus in the literature

Author [Reference]	Sample size	Sides (n)	Incidence (%)
Sanders et al. (1995) [19]	5	10	100
Marañillo et al. (2005) [9]	75	150	84
Sañudo et al. (1999) [20]	90	180	100
Weighted mean		93	
Current study	50	100	28

Table 4. Incidence of thyroarytenoid connection in the literature

Author [Reference]	Sample size	Sides (n)	Incidence (%)
Sañudo et al. (1999) [20]	90	180	14
Marañillo et al. (2005) [9]	75	150	1
Weighted mean		8.1	
Current study	50	100	9

Cricoid communication. This communication was not encountered in any of the specimens dissected in the current series. However, when Sañudo et al. [20] encountered this communication, a contribution to the mucosa of the posterior surface of the subglottis was observed in 5% of cases.

Communication between the external and the recurrent laryngeal nerves (the “communicating nerve”)

This communication was observed to be an extension of the external laryngeal nerve that passed

through the cricothyroid muscle, to enter the larynx, where it connected with the anterior branch of the recurrent laryngeal nerve. This description concurs with authors such as Sañudo et al. [20] and Marañillo et al. [9]. The incidence of 25% in the current series, differed with the weighted mean of 45.7% calculated from a review of the literature (Table 1). When compared to individual authors, this study compared favourably with Sanders et al. [19] (20%) but differed to Sañudo et al. [20] who documented an incidence of 68%.

Whilst this study did not encounter any significant contribution from the communicating nerve to the larynx, researchers who have extensively studied it noted that it had 2 components [26]. These were a sensory component that appears to be the primary sensory supply to the subglottic mucosa of the vocal cord as well as an intramuscular branch that joins the recurrent laryngeal nerve within the thyroarytenoid muscle (where it then terminates) [26].

Communication between the internal and external laryngeal nerves via a thyroid foramen

In one left hemi-larynx, a connection between the internal and external laryngeal nerves occurred via a thyroid foramen. In addition, the superior laryngeal artery also passed through the foramen. This description concurs with the observations of Sañudo et al. [20]. However, the current study recorded an incidence of 1%, which differs with that conducted by Sañudo et al. [20] who observed this type of communication in 21% of specimens (38/180 sides) and more recently, Sakamoto [18] who also observed communications between the external and internal laryngeal nerves in 21.7%.

CONCLUSIONS

The neural communications that exist in the larynx have been thought to play a role in laryngeal innervation [20]. The results of this study when compared to previous researchers show have shown varying incidences in neural communications. In addition, contributions from these communications have also been observed to various intrinsic laryngeal muscles. The results of this study can be extrapolated to cases where there is residual innervation of paralysed laryngeal muscles. In these cases, the re-innervation may be from any one of the communications mentioned. This study supports the suggestion of the significance of these varying incidences of the neural communications made by Sañudo et al. [20] that "The different prevalences of this complex anastomotic pattern suggest that there are functional differences in the sensory and motor innervation of individual subjects".

REFERENCES

- Berlin DD, Lahey FH (1929) Dissections of the recurrent and superior laryngeal nerves. *Surg Gynecol Obstet*, 49: 109–104.
- Dilworth TEM (1921) The nerves of the human larynx. *J Anat*, 50: 48–52.
- Furlan JC, Brandao L.G, Ferraz AR (2002) Prevalence of Galen's anastomosis: an anatomical and comparative study. *J Laryngol Otol*, 136: 823–825.
- Kambic V, Zargi M, Radsel Z (1984) Topographic anatomy of the external branch of the superior laryngeal nerve. *J Laryngol Otol*, 98: 1121–1124.
- King BT, Gregg RL (1948) An anatomical reason for the various behaviours of paralyzed vocal cords. *Ann Otol Rhinol Laryngol*, 57: 925–944.
- Kreyer R, Pomaroli A (2000) Anastomosis between the external branch of the superior laryngeal nerve and the recurrent laryngeal nerve. *Clin Anat*, 13: 79–82.
- Lemere F (1932) Innervation of the larynx I: Innervation of laryngeal muscles. *Am J Anat*, 51: 417–438.
- Liebermann-Meffert DM, Walbrun B, Hiebert CA, Siewart JR (1999) Recurrent laryngeal nerve and superior laryngeal nerve: A new look with implication for esophageal surgeon. *Ann Surg*, 67: 217–223.
- Marañillo E, León X, Orus C, Orús M, Sañudo JR (2005) Variability in nerve patterns of the adductor muscle group supplied by the recurrent laryngeal nerve. *Laryngoscope*, 115: 358–362.
- Mayet A (1956) Zur innervation des M. Cricothyroideus. *Anat Anz*, 103: 17–20.
- Meng ZH, Li L (1976) Observations of the anatomy of the laryngeal nerves. *Chin Med J (Chin)*, 56: 177–180.
- Migueis A, Ucclay I, Migueis J, Urtasun A, Traissac L (1989) Anse de Galien, étude anatomique chez l'homme. *Rev Laryngol*, 110: 423–425.
- Naidu L, Ramsaroop L, Partab P, Satyapal KS (2012) Galen's "anastomosis" revisited. *Clin Anat*, 25:722–728.
- Nordland M (1930) The larynx as related to surgery of thyroid. *Surg Gynecol Obstet*, 51: 449–459.
- Partab P, Hurrinarain K, Ramsaroop L, Satyapal KS (2006) Atypical anastomosis of laryngeal nerves. *Clin Anat*, 19: 651–656.
- Pichler H, Giesel A (1957) The clinical significance of the ramification of the recurrent laryngeal nerves. *Laryngoscope*, 67: 105–117.
- Reuger RS (1972) The superior laryngeal nerve and the interarytenoid muscle in humans: an anatomical study. *Laryngoscope*, 82: 2008–2031.
- Sakamoto Y (2013) Interrelationships between the innervations from the laryngeal nerves and the pharyngeal plexus to the inferior pharyngeal constrictor. *Surg Radiol Anat*, DOI 10.1007/s00276-013-1102-8.
- Sanders I, Li Y, Biller H (1995) Axons enter the human posterior cricoarytenoid muscle from the superior direction. *Arch Otolaryngol Head Neck Surg*, 121: 754–758.
- Sañudo JR, Marañillo E, Leon X, Mirapeix R.M, Orus C, Quer M (1999) An anatomical study of the anastomosis between the laryngeal nerves. *Laryngoscope*, 109: 983–987.
- Schweizer V, Dorfl J (1997) The anatomy of the inferior laryngeal nerve. *Clin Otolaryngol*, 22: 362–369.
- Scouza RR, Carvalho CAF, Chih CI, Andrads ACH (1981) Divisao precoce do nervo laringeo recorrente e ramo comunicante com o nervo laringeo superior, no homem: estudo étnico e anátomo-patológico. *Rev Hosp Clin*, 36: 258–260.
- Tanaka S, Tanebe M (1986) Glottal adjustment for regulating vocal intensity: an experimental study. *Acta otolaryngol (Stolk)*, 102: 315–324.
- Vogel PH (1952) The innervation of the larynx of man and the dog. *Am J Anat*, 90: 427–447.
- Williams AF (1951) The nerve supply of the laryngeal muscles. *J Laryngol Otol*, 65: 343–348.
- Wu BL, Sanders I, Mu L, Biller HF (1994) The human communicating nerve an extension of the external superior laryngeal nerve that innervates the vocal cord. *Arch Otolaryngol Head Neck Surg*, 120: 1321–1328.