

# The radial artery and its variations: anatomical study and clinical implications\*

A.Y. Nasr<sup>1, 2</sup>

<sup>1</sup>Anatomy Department, Faculty of Medicine, Zagazig University, Zagazig, Egypt

<sup>2</sup>King Abdulaziz University, Jeddah, Kingdom of Saudi Arabia

[Received 24 September 2012; Accepted 10 October 2012]

**Background:** To describe the radial artery and its variants in origin, branching pattern, mode of termination, and measurements of its length and external diameter.

**Material and methods:** One hundred upper limbs of 30 men and 20 women adult cadavers were used in this study. The cadavers were obtained from the Anatomy Department, Faculty of Medicine, King Abdulaziz University, Jeddah, Saudi Arabia. The axillary region, arm, forearm, and hand of each limb were dissected to clarify the course and branches of the radial artery. This anatomical descriptive study was conducted between September 2010 and August 2012 after approval of the Ethical Committee.

**Results:** The mean distance of the normal origin of the radial artery as one of two terminal branches of the brachial artery was  $38.7 \pm 9.5$  mm in men and  $36.5 \pm 8.5$  mm in the upper limbs of women below the intercondylar line, and variant origin of the radial artery was found in eight limbs. The mean of radial artery length was  $226.2 \pm 21.7$  mm in men and  $209.9 \pm 13.9$  mm in women and that of its external diameter was  $3.3 \pm 0.7$  mm in men and  $3.2 \pm 0.66$  mm in women at 1 cm distal to its origin;  $3.1 \pm 0.73$  mm in men and  $3.0 \pm 0.66$  mm in women at 2 cm proximal to the styloid process of the radius. The radial artery showed different branching patterns and three modes of termination.

**Conclusions:** Knowledge of radial artery description and its variants has great importance in different clinical fields and basic medical studies. (Folia Morphol 2012; 71, 4: 252–262)

**Key words:** radial artery, branches, variations, cadaver

## INTRODUCTION

The radial artery (RA) is the smaller of the two terminal branches of the brachial artery (BA) in the cubital fossa, medial to the biceps tendon. It ascends from the BA in the cubital fossa approximately 1.0 cm below the bend of the elbow opposite the neck of the radius and is a more direct continuation of the BA. After its origin it traverses through the lateral aspect of the forearm approaching its lower end where it enters the palm to anastomose with the deep branch

of the ulnar artery to complete the formation of the deep palmar arch. The proximal RA courses underneath the muscle belly of the brachioradialis muscle, and its middle part lies near the superficial branch of the radial nerve. The distal third of the RA becomes superficial and is positioned anterior to the radius and pronator quadratus muscle between the tendons of the brachioradialis and flexor carpi radialis [26].

The RA is currently regarded as a useful vascular site for coronary procedures alternative to femoral

Address for correspondence: Ashraf Y. Nasr, MD, Anatomy Department, King Abdulaziz University, PO Box 80205, Jeddah 21589, Kingdom of Saudi Arabia, tel: +966 (2) 6401000 ext. 20477, fax: +966 (2) 4601000 ext. 20121, e-mail: ashrafnaem2012@yahoo.com

\*This study was done in the Anatomy Department, Faculty of Medicine, King Abdulaziz University, Jeddah, Kingdom of Saudi Arabia.

access due to its superficial course that make it easily accessible and effectively compressed for haemostasis induction, early patient ambulation, and increased post-operative patient comfort. Also it has a relative lack of local vascular complications associated with the femoral approach [6]. Moreover, RA has been used in coronary artery bypass grafting, in cosmetic surgeries as forearm flaps, and in renal dialysis by making an autogenous fistula [21].

The anatomical variations of the upper limb arterial pattern are common and have been previously reported by several investigators [17, 19]. Diversions of the RA from its normal anatomical pattern as regards its origin or its course constitute the largest group of vascular variations of the upper limbs [28]. Such variations may interfere with diagnostic, therapeutic, and surgical interventions [1].

New interest in RA anatomy is being generated due to the increased use in different coronary interventions. The ease of access, high success rate, ease of care for nursing staff, given rich collateral circulation of the human hand, and low risk of thrombosis are the reasons for the popularity of the RA. These anatomic features of the RA are the main determinants for the feasibility of using it as a route for coronary intervention [33]. Moreover, in this condition, the RA had close proximity to the cephalic vein that might produce dangerous complications during the intravenous injection of medications [22]. The variant high origin of the RA, defined as RA arising either from the brachial or axillary artery (AA) proximal to the antecubital fossa, has been found in 2.4% to 14.3% of upper extremities [33, 34]. Opposite origin of the radial and ulnar arteries to the usual arrangement, defined as the origin of the RA from the medial and of the ulnar artery from the lateral side of the brachial artery, has been rarely reported [29]. Absent RA, with an estimated incidence of 0.03%, is rare [5]. The RA is smaller compared to the brachial and femoral arteries. According to Yoo et al. [34], the mean radial inner diameters of patients dictate that about 40.5% of female and 68.3% of male patients can physically accept a 6 Fr arterial sheath (mean radial diameter,  $2.69 \pm 0.4$  mm in males and  $2.43 \pm 0.38$  mm in females).

The study of the anatomic distribution and variations of the RA has great importance to achieve the best results and to avoid possible complications after diagnostic, therapeutic and operative interventions. Thus, the present study aimed to describe the anatomical topography of the RA and determine the variant incidence of its origin, course, relation, branching pattern, and mode of termination in hu-

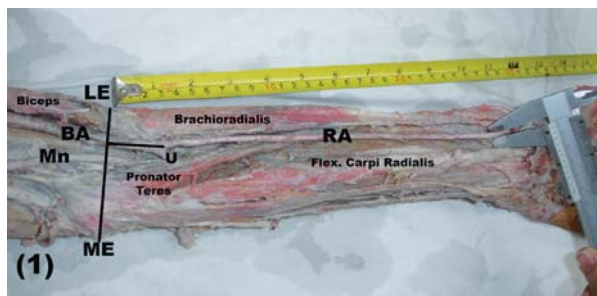
man cadavers with discussion of its morphological and clinical significance.

## MATERIAL AND METHODS

One hundred upper limbs of 50 adult human cadavers (30 males and 20 females) were used in this study. The specimens were obtained from the Anatomy Department, Faculty of Medicine, King Abdulaziz University, Jeddah, Saudi Arabia. The cadavers were placed in a supine position and their upper limbs were abducted to  $90^\circ$  to straighten their arteries and extend their elbow and wrist joints. After thoracotomy a red-coloured latex was injected into the left subclavian and brachiocephalic branches of the aortic arch to clear the course and distribution of RA as well as to give accurate data about its external diameters. The right and left upper limbs of each cadaver were dissected from the axillary region down to the hand including the arm, cubital fossa, forearm, and the anatomical snuffbox. The skin and fasciae of the dissected regions were incised and reflected to expose the deep structures. Both pectoralis major and minor muscles were dissected from their origins and reflected on the lateral side to expose the axillary vessels and branches of the brachial plexus. The biceps muscle was retracted laterally to follow the course and branching pattern of the axillary and brachial arteries and their surrounding nerves. The brachioradialis muscle was displaced laterally to facilitate the handling, mobilisation, and dissection of RA within the forearm. The anatomical snuffbox was dissected to expose the RA down to the first dorsal interosseous space. The course and the branches of the RA in the forearm and hand were carefully dissected; their morphology and variations were recorded. The flowing parameters of RA were measured in both right and left limbs of each cadaver. (1) Its original level in relation to the interepicondylar line of the humerus, (2) its length in correlation with the forearm length, and (3) its external diameter at 1 cm distal to its origin and at 2 cm proximal to the styloid process of the radius. In addition, any variant of its course and distribution and its branching patterns within the forearm and hand and modes of termination were measured. The measurements were taken using a Vernier calliper (0.01 mm accuracy) and measuring strap (Fig. 1). All data were tabulated regarding sex and side of the limb.

### Statistical analysis

Statistical analysis was performed using SPSS 16.0. Any limb with discontinued RA, fractured bone, burn and previous dissection was discarded. All mea-



**Figure 1.** Light photograph of a left female upper limb showing the methods of measurement of the radial artery parameters.

Measurements were expressed as mean ± SD. Continuous variables were compared using Student’s t-test. A p value of < 0.05 was considered statistically significant. The approval of the medical Ethics Committee was agreed by the Institutional Ethics Committee of the Faculty of Medicine, King Abdulaziz University. The study was conducted between September 2010 and August 2012.

### RESULTS

The incidence of normal and variant origin of the RA was summarised (Table 1). The classic origin of the RA, as a one of the two terminal branches of the BA within the cubital fossa below the level of the intercondylar line of the humerus, was seen in 92 out of 100 (92%) upper limbs. This pattern was represented in 55 out of the 60 (91.7%) male upper limbs and 37 out of 40 (92.5%) female upper limbs. However, the abnormal high-origin RA was observed in 8 (8%) out of 100 upper limbs, 5 male and 3 female. This abnormal origin was predominant on the right upper limbs where it was noticed in 5 right (3 male

and 2 female) upper limbs and 3 left (2 male and 1 female) upper limbs. In 7 (7%) out of 100 upper limbs the RA originated from the AA by two different forms while in a left female upper limb (1%) the RA arose from the AA.

**The first variant of RA origin** was seen in 4 limbs where the RA arose from the medial aspect of the upper third of the BA. Thereafter, it passed in close contact to the medial side of the BA within the arm down to the level of the intercondylar line where it crossed both the median nerve and BA superficially to the opposite side. Within the cubital fossa, this abnormal high-origin RA crossed the bicipital tendon superficially from medial to lateral to reach the medial border of the brachioradialis muscle. This artery showed normal course and distribution within the forearm and hand. The course of this limb continued as the ulnar artery (Fig. 2).

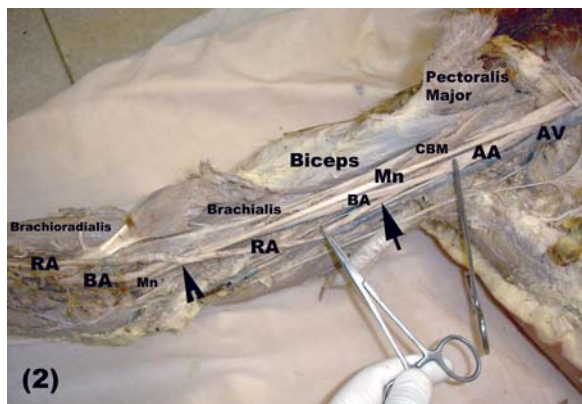
**In the second variant of RA origin**, which was noticed in 3 limbs, the RA originated from the lateral aspect of the upper part of the BA. This abnormal RA crossed the median nerve superficially and descended on its lateral side down to the cubital fossa where it passed alongside the medial aspect of the biceps tendon. Thereafter, it followed the normal course and distribution of the RA within the forearm and the hand. Meanwhile, the BA of this limb had normal course and relations within the arm down to the cubital fossa where it passed deep to the deep head of the pronator teres muscle and continued as the ulnar artery within the forearm (Fig. 3).

A unique variant of RA origin was seen in a left female upper limb. The AA of this limb gave an abnormal arterial trunk from the anterior aspect of its second part at a distance 62 mm from the

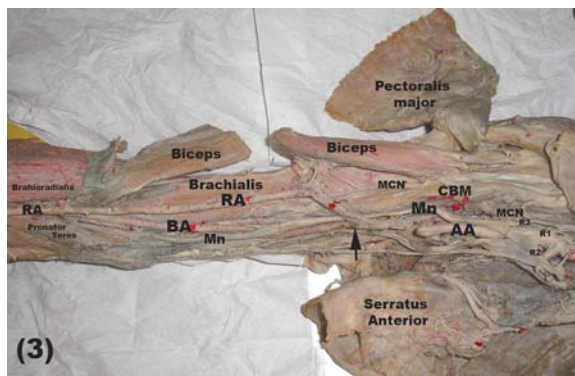
**Table 1.** The incidence of normal and variant origin of radial artery (%)

Origin of radial artery		Male limbs (60)		Female limbs (40)	
		Right (30)	Left (30)	Right (20)	Left (20)
Normal	Number (%)	27 (90%)	28 (93.3%)	18 (90%)	19 (95%)
	Total (%)	91.7%		92.5%	
		92%			
Abnormal	Unilateral	2	1	1	0
	Bilateral	1	1	1	1
	Site	From BA	From BA	From BA	From AA
	Number (%)	3 (10%)	2 (6.7%)	2 (10%)	1 (5%)
	Total number (%)	5 (8.3%)		3 (7.5%)	

AA — axillary artery; BA — brachial artery



**Figure 2.** Light photograph of a right female upper limb showing the abnormal high-origin (black arrow) radial artery (RA) crossing (open arrow head) the median nerve (Mn) and brachial artery superficially. The artery arises from the upper medial side of the brachial artery (BA); AA — axillary artery; AV — axillary vein; CBM — coracobrachialis muscle.

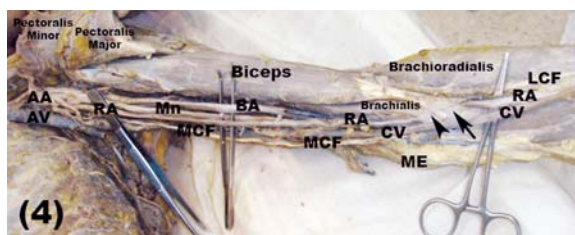


**Figure 3.** Light photograph of a right male upper limb showing the radial artery (RA) originating from the lateral aspect of the upper part of the brachial artery (BA). The median nerve (Mn) passes deep to the RA and crosses the BA; AA — axillary artery; R1, R2, R3 — roots of median nerve; MCN — musculocutaneous nerve; CBM — coracobrachialis muscle.

mid-clavicular point. This trunk gave the lateral thoracic and thoraco-acromial branches and continued on the medial side of the median nerve as an abnormal RA down to the cubital fossa. Through its course within the axilla and arm, this abnormal RA passed superficially between the axillary and brachial arteries on its lateral side and the medial cutaneous nerve of the forearm and the axillary vein on its medial aspect. At the cubital fossa, the abnormal RA crossed both the median nerve and the BA superficially deep to the bicipital aponeurosis and brachialis muscle to become on their lateral side. Thereafter, it passed within the forearm and hand with normal course and distribution (Fig. 4).

Different measurements of the RA were listed (Table 2). From these, we concluded marked differences between male and female measurements, where the mean distance between the intercondylar line of the humerus and the RA origin was  $38.7 \pm 9.5$  mm in males and  $36.5 \pm 8.5$  mm in females. In addition, the mean length of the RA was  $226.2 \pm 21.7$  mm in males and  $209.9 \pm 13.9$  mm in females. Moreover, the external diameter mean was  $3.3 \pm 0.72$  mm in males and  $3.2 \pm 0.66$  mm in females at a distance of 1 cm distal to the origin of the RA while it was  $3.1 \pm 0.73$  mm in males and  $3.0 \pm 0.66$  mm in females at a distance of 2 cm proximal to the styloid process.

In the upper limbs of male cadavers, the measurements of right RA were slightly higher than those of the left ones. The mean distance of RA origin from the intercondylar line of the humerus measured  $38.8 \pm 9.7$  mm in right and  $38.7 \pm 9.6$  mm in left upper



**Figure 4.** Light photograph of a left female upper limb showing the radial artery (RA) originating from the front of second part of the axillary (AA). The RA crosses the median nerve (Mn) and brachial artery (BA) superficially at the cubital fossa deep to the bicipital tendon and brachialis muscle; AV — axillary vein; MCF — medial cutaneous nerve of the forearm; CV — cephalic vein; LCF — lateral cutaneous nerve of the forearm; ME — medial epicondyle.

limbs. The mean length of the forearm from the centre of the lateral epicondyle to the distal end of the styloid process of the radius was  $265.3 \pm 20.1$  mm in right upper limbs and  $264.6 \pm 19.9$  mm in left upper limbs. The length of the right RA was  $226.3 \pm 22.0$  mm, and it was  $226 \pm 21.8$  mm in left upper limbs. The mean of the external diameter of the RA on both right and left upper limbs was  $3.3 \pm 0.7$  mm at a distance of 1 cm distal to its origin while its value was  $3.1 \pm 0.7$  mm at a distance of 2 cm proximal to the styloid process (Table 2).

However, in the upper limbs of female cadavers, the distance between the RA origin and the intercondylar line of the humerus was equal in both right and left upper limbs, and its mean was  $36.5 \pm 8.6$  mm. The mean length of the forearm was  $246.4 \pm 15.9$  mm in right upper limbs and  $246.1 \pm 15.7$  mm in left upper limbs. Moreover, the mean



**Table 2.** The radial artery measurements (mean  $\pm$  SD)

Side	Sex	OLR	FL	RAL	D1	D2	P
Both	Male	38.7 $\pm$ 9.5	265.1 $\pm$ 19.8*	226.2 $\pm$ 21.7*	3.3 $\pm$ 0.72	3.1 $\pm$ 0.73	0.0001 (*)
	Female	36.5 $\pm$ 8.5	246.2 $\pm$ 15.5*	209.9 $\pm$ 13.9*	3.2 $\pm$ 0.66	3.0 $\pm$ 0.66	
Right	Male	38.8 $\pm$ 9.7	265.3 $\pm$ 20.1**	226.3 $\pm$ 22	3.3 $\pm$ 0.7	3.1 $\pm$ 0.7	0.0017 (**)
	Female	36.5 $\pm$ 8.6	246.4 $\pm$ 15.9**	210 $\pm$ 14.2	3.07 $\pm$ 0.5	2.76 $\pm$ 0.49	
Left	Male	38.7 $\pm$ 9.6	264.9 $\pm$ 19.9***	226 $\pm$ 21.8	3.3 $\pm$ 0.7	3.1 $\pm$ 0.73	0.0012 (***)
	Female	36.5 $\pm$ 8.6	246.1 $\pm$ 15.7***	209.8 $\pm$ 14.1	3.02 $\pm$ 0.48	2.74 $\pm$ 0.45	

\*significant difference between male and female ( $p < 0.05$ ); \*\*significant different at  $p < 0.05$  between right male and female limbs; \*\*\*significant different at  $p < 0.05$  between left male and female limbs; OLR — original level of radial artery; FL — forearm length; RAL — radial artery length; D1 — external diameter at 1 cm distal to the origin; D2 — external diameter at 2 cm proximal to the styloid process

length of the RA was  $210 \pm 14.2$  mm in right upper limbs and  $209.8 \pm 14.1$  mm in left upper limbs. The mean of the original external diameter of right RA was  $3.07 \pm 0.49$  mm and those of the left upper limbs was  $3.02 \pm 0.48$  mm. Its value at a distance of 2 cm proximal to the styloid process was  $2.76 \pm 0.49$  mm in the right upper limbs and  $2.74 \pm 0.45$  mm in the left upper limbs (Table 2).

A statistically significant difference was found between the forearm length and RA length of all the upper limbs of the male cadavers with those of the upper limbs of the female cadavers ( $p < 0.001$ ). Moreover, a significant difference was noticed between the length of the forearm of right male upper limbs and those of female upper limbs ( $p = 0.0017$ ), and a significant difference was reported between the forearm length of the left male upper limbs and those of left female upper limbs ( $p = 0.0012$ ). However, no significant difference was observed between all the measurements of right male and that of left male upper limbs or between the measurements of right female and those of left female upper limbs (Table 2).

The branching patterns of the RA within the forearm and hand were fully described (Table 3). The radial recurrent branch was the first branch originating from the RA (Fig. 5). This branch was present in 98 out of 100 (98%) upper limbs, and it was absent in 2 out of 100 (2%) upper limbs. This branch had 2 sources of origin; the most common 1 was the RA. This original pattern was found in 83 out of 100 upper limbs: 50 out of 60 (83.3%) male and 33 out of 40 (82.5%) female upper limbs. Whereas, the variant original source was the BA that gave the origin of recurrent artery in 15 out of 100 upper limbs: 9 male and 6 female upper limbs (Fig. 6). The second branch of the RA was the superficial palmar artery, which originated from the RA at the area of the wrist joint (Fig. 7). This branch

was noticed in 95 out of 100 (95%) upper limbs and was absent in 5 out of 100 (5%) upper limbs. In 4 male and 2 female upper limbs, this branch showed a high origin from the RA. The third branch of the RA was the palmar carpal artery, which was observed in 77 out of 100 upper limbs (Fig. 5): 46 out of 60 male (76.7%) and 31 out of 40 female (77.5%) upper limbs. However, it was absent in 23 out of 100 upper limbs (Fig. 7): 14 out of 60 (23.3%) male and 9 out of 40 female (22.5%) upper limbs.

In the hand, the RA gave the first dorsal metacarpal artery, the princeps pollicis artery, and radialis indicis artery in addition to its terminals. The first dorsal metacarpal artery appeared in 88 out of 100 (88%) upper limbs and was absent in 12 out of 100 upper limbs. In male upper limbs, it was noticed in 53 out of 60 (88.3%) upper limbs while in females it was seen in 35 out of 40 (87.5%) upper limbs. The princeps pollicis artery was seen in all specimens except 1 right male upper limb (99%). In 91 (91%) upper limbs, this branch originated from the RA while in 8 out of 100 upper limbs, it was a branch of the superficial palmar arch of the hand (Fig. 7). The princeps pollicis branch arose from the RA in 54 out of 60 (90%) male upper limbs while it was a branch from the superficial palmar arch in 5 out of 60 (8.3%) male upper limbs. In female cadavers, the princeps pollicis branch originated from the RA in 37 out of 40 (92.5%) upper limbs and arose from the SPA in 3 out of 40 (7.5%) upper limbs. The radialis indicis branch was noticed in 93 out of 100 (93%) upper limbs but it was not present in 7% of the specimens. The origin of this branch had 2 sources: the RA and the superficial palmar arch. The RA was the origin of the radialis indicis branch in 85 out of 100 (85%) upper limbs while the superficial palmar arch gave the origin of the radialis indicis branch in 8 out of 100 upper limbs (Fig. 7). In male upper limbs, the radialis indicis branch origi-

**Table 3.** The incidence of normal and variant origin of radial artery (RA) branches (%)

Branch	All male limbs (%)				All female limbs (%)			
	Present	Absent	RA	Abnormal	Present	Absent	RA	Abnormal
RRA	98.3	1.7	83.3	15	97.5	2.5	82.5	15
SPA	95	5	89	6	95	5	90	5
PCA	77	23	77	0.0	77.5	22.5	77.5	0.0
FDM	88.3	11.7	88.3	0.0	87.5	12.5	87.5	0.0
PP	98.3	1.7	90	8.3	100	0.0	92.5	7.5
RI	93.3	6.7	85	8.3	92.5	7.5	85	7.5
T1	51.5	0.0	0.0	0.0	52.5	0.0	0.0	0.0
T2	45	0.0	0.0	0.0	45	0.0	0.0	0.0
T3	3.3	0.0	0.0	0.0	2.5	0.0	0.0	0.0

Branch	Origin	Male RA (60)				Female RA (40)			
		Right (30)		Left (30)		Right (20)		Left (20)	
		N	%	N	%	N	%	N	%
RRA	From RA	25	83.3	25	83.3	17	85	16	80
	Absent	0.0	0.0	1	3.3	0.0	0.0	1	5
	From BA	5	16.7	4	13.3	3	15	3	15
SPA	From RA	26	86.7	27	90	18	90	18	90
	Absent	2	6.7	1	3.3	1	5	1	5
	High origin	2	6.7	2	6.7	1	5	1	5
PCA	From RA	24	80	22	73.3	16	80	15	75
	Absent	6	20	8	26.7	4	20	5	25
RI	From RA	25	83.3	26	86.7	17	85	17	85
	From SA	3	10	2	6.7	1	5	2	10
	Absent	2	6.7	2	6.7	2	10	1	5
PP	From RA	27	90	27	90	18	90	19	95
	From SA	2	6.7	3	10	2	10	1	5
	Absent	1	3.3	0.0	0.0	0.0	0.0	0.0	0.0
FDM	Present	26	86.7	27	90	17	85	18	90
	Absent	4	13.3	3	10	3	15	2	10
Termination pattern	Normal	16	53.3	15	50	9	55	10	50
	(2) Branch	3	43.3	14	46.7	0.0	45	9	45
	(3) Branch	1	3.3	1	3.3	0.0	0.0	1	5

RRA — radial recurrent artery; SPA — superficial palmar artery; PCA — palmar carpal artery; FDM — first dorsal metatarsal; PP — princeps pollicis artery; RI — radialis indicis artery; T1 — termination pattern I; T2 — termination pattern II; T3 — termination pattern III


nated from the RA in 51 out of 60 (85%) upper limbs, and it was absent in 4 limbs, while the superficial palmar arch gave the origin of this branch in 5 male upper limbs (6.7%). In female upper limbs, the radialis indicis branch was absent in 3 out of 40 (7.5%) upper limbs while it originated from the RA in 34 out of 40 upper limbs and in 3 upper limbs (7.5%) it arose from the superficial palmar arch. In addition to the previous branches, the RA gave from one to three muscular branches to the forearm muscles.

Finally, the RA showed 3 patterns of termination. The first pattern was in the form of a single branch

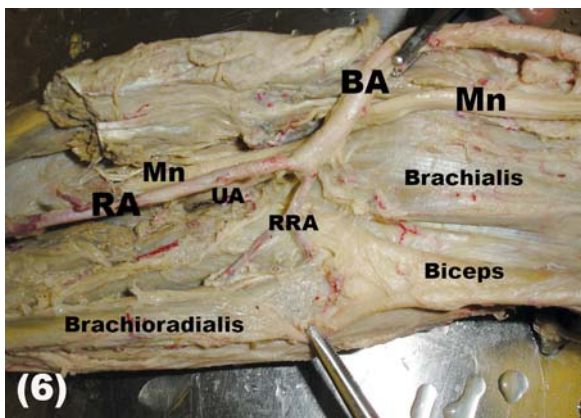
that anastomosed with the deep ulnar branch to form the deep palmar arch. While, in the second pattern, the RA divided into 2 terminal branches. However, in the third pattern of termination, the RA divided into 3 branches. The first (classic) pattern was seen in 52% of the specimens, the second pattern appeared in 45% of the upper limbs, and the third pattern was seen in 3% only (Table 3).

**DISCUSSION**

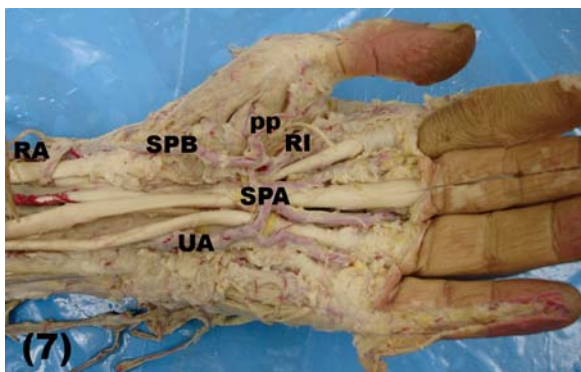
The variation of the original level of the RA may interfere with therapeutic, diagnostic, and surgical



**Figure 5.** Light photograph of a right upper limb showing branches of the radial artery (RA) within the forearm including the radial recurrent artery (RRA), muscular (open arrow heads) and palmar carpal branch (arrow); BA — brachial artery; Mn — median nerve; U — ulnar; AP — abductor pollicis longus tendon; EPB — extensor pollicis brevis tendon; PL — extensor pollicis longus; FCR — flexor carpi radialis.



**Figure 6.** Light photograph of left male upper limb showing the origin of the radial recurrent artery (RRA) from the brachial artery (BA) and trifurcation of the BA; RA — radial artery; UA — ulnar artery; Mn — median nerve.



**Figure 7.** Light photograph of a left hand showing the formation of the superficial palmar arch (SPA) from the ulnar superficial branch (UA) and superficial palmar branch (SPB) of the radial artery (RA). The SPA gives the princeps pollicis (PP) and radial indicis (RI) branches.

procedures. High origin of the RA was the most common arterial variation of the upper limb from either brachial or AA, where its incidence varied from 4.17%

to 15.6% in cadavers and embryos [22] while it ranged from 8% to 24.4% in angiographic studies [29, 30].

In the present study, the incidence of normal origin of the RA was seen in 92 out of 100 upper limbs with left predominance while its abnormal high origin was observed in 8 out of 100 upper limbs with male and right side predominance. The BA was the source of 7 out of the 8 abnormal high-origin RAs while, the RA originated from the AA in only 1 left female upper limb.

In accordance with the results of the present study, an abnormal origin of the RA from the BA was found in 7% to 7.7% of the specimens [29]. However, in the literature, lower incidence of the abnormal origin of the RA from the BA was observed in 2.3% [32], in 2.4% [34], in 2.66% [8], in 3% [1], and in 4.17% [17]. However, the abnormal high origin of RA was observed in 12.5% [18], in 14% [22], and in 23% [21].

Similar to the results of the present study, a variant RA originating from the AA was found in 1% of the specimens [2, 8]. However, a higher incidence of the variant RA was seen in 3.25% [21] and in 2.66% [8].

The pattern and rate of the abnormal RA were different from one race to another; the axillary origin of the RA was seen in 5% of African people while it was seen in 2.7% of the Caucasian population [6]. The incidence range of the high origin RA from the BA varied from 5.9% to 12.1% among Caucasians but it was observed in 2.3% of 304 Korean cadavers [32]. However, its prevalence was 0.33% among Singaporean Chinese Cadavers [4]. The racial difference of the existence of abnormal origin of the radial had no clear explanation. Such abnormal origins of the RA might be the cause of failure of the transradial approach during surgical or radiological interventions. Thus, this variation must be kept in mind during any vascular, reconstructive, cardiac, orthopaedic, or radiological manipulations.

The abnormal course of the RA is of interest to clinicians, particularly surgeons and radiologists. In the present study, the abnormal high-origin RA had a variant relation within the arm especially to the median nerve and the BA and to a lesser extent to the biceps and brachialis muscles. In agreement with the results of the present study, Natsis et al. [17] found 2 cases of high-origin RA with different courses within the arm, as well as 2 cases in which the RA originated from the medial side of the BA above the intercondylar line. These arteries descended in front

of the median nerve at the cubital fossa and crossed it anteriorly below the intercondylar line to pass within the front of the forearm in its normal anatomical course [8].

However, an unusual course of the RA was observed by Pelin et al. [19], who stated that the RA originated from the medial aspect of the upper part of the BA crossing the median nerve twice: once at its original level and secondly in the cubital fossa. Thereafter, the RA descended in its normal anatomical course within the front of the forearm. Similarly, a case of high origin of RA with double crossing the median nerve within the arm was observed [24].

The abnormal course of the RA was not only observed in the arm but also within the anatomical snuffbox as well. Superficial passage of the RA to the tendon of the extensor pollicis longus muscle within the anatomical snuffbox has been previously reported [8, 16]. Moreover, Patnaik et al. [18] found the RA at the base of the 2<sup>nd</sup> metacarpal where it turned distally to pass through the 2<sup>nd</sup> intermetacarpal space between the 2 heads of the 2<sup>nd</sup> dorsal interosseous muscle. Such anomalies were not observed in the present study. In agreement with the case of the abnormal RA of axillary origin of the present study, RA coursing behind the biceps brachii tendon was observed [9]. In the present study, the RA crossed the median nerve and BA superficially deep to the brachialis and biceps muscles at the front of the elbow joint.

The presence of such a superficial RA showed close proximity to the cephalic vein, which might produce dangerous complications during the intravenous injection of medications and might interfere with the palpation of the normal radial pulse at the wrist with production of cannulation failure [16]. Moreover, in this condition, the RA had close proximity to the cephalic vein that might produce dangerous complications during the intravenous injection of medications [22].

Embryologically, the upper limb arteries develop mainly from the lateral branch of the 7<sup>th</sup> cervical intersegmental artery. The arterial trunk grows outwards along the ventral axis line to terminate in the deep palmar plexus in the hand. The proximal part of this trunk gives the axillary and brachial arteries, and its distal part persists as the interosseous artery and the deep palmar arch. The RA sprouts from 2 arterial buds arising from the lateral side of the BA. These buds coalesce with each other while the ulnar artery develops from an arte-

rial bud just above the point at which the median artery arises. Later, the RA establishes a new connection with the main trunk at or near the level of the ulnar artery origin. The upper part of the developing RA stem usually disappears to a large extent [15, 23]. The anomalies of the RA might be due to the persistence of its proximal segment with production of high origin [27]. Although knowledge of the exact factors responsible for each arterial variation is impossible, many changes may occur due to changes in the haemodynamic forces, foetal position within the uterus, genetic predisposition, chemical factors, and developmental arrest at any stage [17, 21].

In the present study, the RA normally originated as one of two terminal branches of the BA at a mean distance of  $38.75 \pm 9.65$  mm (range 21.3–57.7 mm) in male upper limbs and  $36.5 \pm 8.6$  mm (range 22.6–51.5 mm) in female upper limbs below the intercondylar line of the humerus. However, the BA terminated at a mean distance of 2.99 cm (ranging from 1.0 to 4.5 cm) distal to the intercondylar line [18]. Meanwhile, the RA began about 1 cm below the bend of the elbow at the level of the neck of the radius [26]. However, abnormal branching pattern was found in 9% [29] and in 3.2% [22] of the specimens. The discrepancy of this distance might be due to racial difference or the number of specimens.

The results of the present study revealed that the mean length of the RA was  $226.3 \pm 22$  mm in right and  $226 \pm 21.8$  mm in left male upper limbs while in female cadavers it was  $210 \pm 14.2$  in right and  $209.8 \pm 14.1$  mm in left upper limbs. However, the mean length of radial was  $22.99 \pm 3.03$  cm in males and  $1.74 \pm 0.53$  cm in females [1]. Moreover, the range of RA lengths was 20–24 cm in males and 2 cm less in females [7].

The diameter of the RA plays a great role in the success of any angiographic, graft replacement, catheterisation, and bypass operations. In the present study, the external diameter of RA in male cadavers was equal on both right and left upper limbs, where its mean was  $3.3 \pm 0.7$  mm at 1 cm distal to the level of its normal origin and  $3.1 \pm 0.7$  mm at a distance 2 cm proximal to the end styloid process. Meanwhile, in female upper limbs, the mean of the RA external diameter of right upper limbs was slightly higher than that of the left upper limbs, where its mean was  $3.07 \pm 0.5$  mm and  $2.76 \pm 0.49$  mm on the right side and  $3.02 \pm 0.48$  mm and  $2.74 \pm 0.45$  mm on the left side.



The angiographic measurement of the luminal diameter of the RA at 2 cm proximal to the styloid process was  $2.6 \pm 0.5$  mm and its range was 1.6 to 3.8 mm:  $2.69 \pm 0.4$  mm in men and  $2.43 \pm 0.34$  mm in women [33]. However, the mean diameter of right and left RA was  $2.3 \pm 0.4$  mm (1.4–3.6 mm) and  $2.2 \pm 0.4$  mm (1.2–3.1 mm), respectively, in males  $2.3 \pm 0.39$  and in females  $2.11 \pm 0.29$  [28]. However, the luminal inner RA diameter at 1–2 cm proximal to the styloid process using two-dimensional ultrasound was  $2.6 \pm 0.41$  mm [34], which was more than that reported by Shima et al. [25], who, in a study using cadavers, reported that the average diameters of RA in proximal and distal portions were 2.3 and 2.2 mm, respectively. The reason for this discrepancy might be due to using patients for one hand and cadavers for the other one. However, in the Japanese population it was  $3.1 \pm 0.06$  in male and  $2.8 \pm 0.6$  mm in female patients [11]. Knowledge of RA diameter helps cardiologists and radiologists to cannulate various sizes of sheaths during transradial coronary interventions and to improve microsurgical techniques.

Moreover, the mean diameter of the RA at the wrist was measured by electronic digital callipers in presence of complete and incomplete palmar arches. It was  $3.1 \pm 0.2$  mm in the presence of complete arch and  $2.6 \pm 0.3$  mm on the right and  $2.7 \pm 0.2$  mm on the left side of the incomplete palmar arch [5].

Regarding the limb side, the baseline diameter of right RA was  $2.58 \pm 0.38$  mm while whose of the left RA was  $2.71 \pm 0.32$  mm. The authors added that the right RA, representing the dominant side, was significantly smaller than that of the non-dominant side [13]. However, no significant difference was reported in diameter between the left and right radial arteries [20].

Knowledge of the different branching patterns of upper limb arteries has clinical and surgical significance. The branching pattern of the RA and its variations has been rarely studied [10]. In the present study, the radial recurrent artery originated from the RA in 83.3% of male and 82.5% of female specimens and from the BA in 15% the specimens. Meanwhile, it was absent in 2% of the specimens. In disagreement with the results of the present study, the radial recurrent artery was a branch of the BA in 12% of the specimens [8]. Moreover, the palmar carpal artery was absent in 26.7% [8] of cases, while it was absent in 22.5% of the specimens of the

present study. Conversely, the absence of the first dorsal metacarpal was (12%) more than that seen by Gupta et al. [8], who reported that the first dorsal metacarpal artery was absent in 9.3% of specimens. The differences between the results of these 2 studies might be related to the number of specimens used in each.

In the present study, the superficial palmar artery was absent in 5% of cases, and originated from the RA at a higher level in 6% of the specimens. Similar observations have been reported by others [8]. However, the high-origin superficial palmar artery from the RA was found in only 1 case [3]. Another variation was found where the RA gave a 2<sup>nd</sup> dorsal metacarpal artery at the proximal end of the 2<sup>nd</sup> intermetacarpal space [18]. Such an observation was not seen in the present study and was not previously recorded [8].

In the present study, the RA showed three different terminal patterns: the classic termination as a single branch to form a deep palmar arch in 52% of cases, into 2 terminal branches in 45% of cases, and into three terminal branches in 3% of the specimens. However, the second pattern was seen in 52% of cases [9] while the third pattern showed 2 extremes: in 84.6% [2] and 2.7% of cases [8]. Moreover, division of the RA into 4 terminal branches was found in 15.3% of the specimens [2]. The previous pattern of RA termination was not seen in the present study. The difference of the termination pattern of the RA might be related to the number or the race of the cadavers used in the study.

With the progress of diagnostic and surgical techniques, the RA has great clinical significance where it is used in different surgical and radiological procedures such as the radial forearm flap in the reconstructive surgeries of the arm, as a graft for coronary bypass, and in the transradial approach during coronary interventions [19]. The acceptance of the transradial approach became more popular than the transfemoral or transbrachial approaches for coronary procedures as the RA had a superficially safe course for better haemostasis, not surrounded by major veins or nerves, and with good collaterals [30]. Moreover, the RA is used with increasing frequency to replace the great saphenous vein as a coronary bypass graft, with the belief that it provides improved long-term patency [31].

However, abnormal origin or variant course of the RA might produce different clinical effects such

as the inability to measure blood pressure, misinterpretation or difficulties in the angiograph intervention, puncture to the superficially located artery with production of finger gangrene and muscular contraction, iatrogenic damage to the artery during the surgical manipulation in orthopaedic, plastic, or vascular surgeries, or the artery might be mistaken for a vein with production of false intra-arterial injection with severe bleeding or drug poisoning. Thus, the importance of such anatomical variations has grown with the excessive use of RA as a conduit in coronary bypass surgery [10]. However, the compression of the median nerve by variant RA could be confused with other causes of radiculopathy or neuropathies. Thus, knowledge of the exact arterial course and its relation to the nearest peripheral nerve have crucial importance when vascularised nerve homografts are used [14].

The variation of the branching pattern of the RA has great significance in cardiac catheterisation for angioplasty, pedicle flaps, or arterial grafting, where any abnormal positions or divisions must be identified before surgery. Thus, physicians should be aware of this abnormality before initiating the procedure [12]. Further study is advisable to correlate the clinical significant of RA parameters in comparison with those of the femoral artery for cardiac catheterisation, angiography, and coronary bypass operations.

## CONCLUSIONS

Knowledge of normal and variant RA distribution and parameters provide surgeons and radiologists with the ability to make proper decisions that achieve better preoperative evaluation, surgical and radiological interventions, and good postoperative results.

## ACKNOWLEDGMENTS

The author extends deep thanks to Professor Mohamed H. Badawoud, Chairman of the Anatomy Department, Faculty of Medicine, King Abdulaziz University for his great support and guidance. He also appreciates the efforts of all technical staff members.

## REFERENCES

- Bidarkotimath S, Ramakrishna A, Arunachalam K (2012) An anatomical study of primary pattern of arteries of upper limb with relevance to their variations. *NUJHS*, 2: 2249–7110.
- de Rezende MR, Mattar Júnior R, Cho AB, Hasegawa OH, Ribak S (2004) Anatomic study of the dorsal arterial system of hand. *Rev Hosp Clin Fac Med Sao Paulo*, 59: 71–76.
- Dhar P, Lall K (2008) An atypical anatomical variation of palmar vascular pattern. *Singapore Med J*, 49: 245–249.
- Dong Z, Yi Z, Jun S, Eng-Ang L, Yip GW (2010) High origin of radial arteries: a report of two rare cases. *Scientific World J*, 10: 1999–2002.
- Fazan VP, Borges CT, Da Silva JH, Caetano AG, Filho OA (2004) Superficial palmar arch: an arterial diameter study. *J Anat*, 204: 307–311.
- Franchi E, Marino P, Biondi-Zoccai GG, De Luca G, Vassanelli C, Agostoni P (2009) Transradial versus transfemoral approach for percutaneous coronary procedures. *Curr Cardiol Rep*, 11: 391–397.
- Guo WH (2006) Arterial grafting for coronary artery bypass surgery. 2<sup>nd</sup> Ed. Springer, Heidelberg, Berlin.
- Gupta C, Ray B, Dsouza AS, Nair N, Pai SR, Manju M (2012) A morphological study of variations in the branching pattern and termination of the radial artery. *Singapore Med J*, 53: 208.
- Jelev L, Surchev L (2008) Radial artery coursing behind the biceps brachii tendon: significance for the transradial catheterization and a clinically oriented classification of radial artery variations. *Cardiovasc Intervent Radiol*, 31: 1008–1012.
- Joseph J, Ranjit D, Jatin D (2005) Superficial ulnar artery. *Eur J Cardiothorac Surg*, 28: 495–496.
- Loh YJ, Nakao M, Tan WD, Lim CH, Tan YS, Chua YL (2007) Factors influencing radial artery size. *Asian Cardiovasc Thorac Ann*, 15: 324–326.
- Madhyastha S, Murlimanju BV, Jiji P, Saralaya VV, Rai A, Vadgaonkar R (2011) Morphological variants of the human superficial palmar arch and their clinical implications. *Morphol. Sci*, 28: 261–264.
- Madssen E, Petter H, Rune W (2006) Radial artery diameter and vasodilatory properties after transradial coronary angiography. *Ann Thorac Surg*, 82: 1698–1703.
- Malcic-Gurbuz j, Gurunluoglu R, Ozdogmus O, Yalin A (2002) Unique case of trifurcation of the grachial artery: its clinical significance. *Clin Anat*, 15: 224–227.
- Moore KL, Dalley AF (2006) Upper limb. Clinically oriented anatomy. 4<sup>th</sup> Ed. Lippincott Williams & Wilkins, Philadelphia.
- Morris G, Rowe M, Delacure D (2005) Superficial dorsal artery of the forearm: case report and review of the literature. *Ann Plast Surg*, 55: 538–541.
- Natsis K, Noussios G, Paraskevas G, Lazaridis N (2009) Study of two cases of high-origin radial artery in humans. *Eur J Anat*, 13: 97–103.
- Patnaik VVG, Kalsey G, Singla RK (2002) Branching pattern of brachial artery: a morphological Study. *J Anatom Soc India*, 51: 176–186.
- Pelin C, Zagyan R, Mas N, Karabay G (2006) An unusual course of the radial artery. *Folia Morphol*, 65: 410–413.
- Riekkinen HV, Karkola KO, Kankainen A (2003) The radial artery is larger than the ulnar. *Ann Thorac Surg*, 75: 882–884.
- Rodriguez-Niedenfuhr M, Vazquez T, Nearn L, Ferreira B, Parkin I, Sanudo JR (2001) Variations of the arterial pattern in the upper limb revisited: a morphological and statistical study, with a review of the literature. *J Anat*, 199: 547–66.

22. Rodriguez-Niedenführ M, Vazquez T, Parkin IG, Sanudo JR (2003) Arterial patterns of the human upper limb: update of anatomical variations and embryological development. *Eur J Anat*, 7: 21–28.
23. Satyanarayanan N, Sunitha P, Shaik MM, Satyavathidevi P (2010) Brachial artery with high up division with its embryological basis and clinical significance. *IJAV*, 3: 56–58.
24. Shetty D S, Raghu J, Cliwyn S, Braganza S, Nayak B, Somayaji SN (2010) Presence of a median arterial arch associated with high origin of radial artery. *IJAV*, 3: 158–159.
25. Shima H, Ohno K, Michi K, Egawa K, Takiguchi R (1996) An anatomical study of the forearm vascular system. *J Craniomaxillofac Surg*, 24: 293–299.
26. Standring S (2008) *Gray's anatomy: the anatomical basis of clinical practice*. 40th Ed. Churchill Livingstone, Elsevier, Edinburgh, London.
27. Swaroop N, Dakshayani KR (2011) The high origin of radial artery and its clinical significance. *Anatomica Karnataka*, 5: 32–35.
28. Tariq Ashraf, Ziauddin P, Sultana H, Muhammad AM, Fahad S, Javed A (2010) Size of radial and ulnar artery in local population. *J Pak Med Assoc*, 60: 817–819.
29. Uglietta JP, Kadir S (1989) Arteriographic study of variant arterial anatomy of the upper extremities. *Cardiovasc Intervent Radiol*, 12: 145–148.
30. Valsecchi O, Vassileva A, Musumeci G, Rossini R, Tespili M, Guagliumi G, Mihalcsik L, Gavazzi A, Ferrazzi P (2006) Failure of transradial approach during coronary interventions: anatomic considerations. *Catheter Cardiovasc Interv*, 67: 870–878.
31. Vollala VR, Nagahhooshana S, Bhat SM (2008) Trifurcation of brachial artery with variant course of radial artery: rare observation. *Anat Sci Int*, 83: 307–309.
32. Yang HJ, Gil YC, Jung WS, Lee HY (2008) Variations of the superficial Brachial artery in Korean Cadavers. *J Korean Med Sci*, 23: 884–887.
33. Yokoyama N, Takeshita S, Ochiai M, Koyama Y, Hoshino S, Isshiki T, Sato T (2000) Anatomic variations of the radial artery in patients undergoing transradial coronary intervention. *Catheter Cardiovasc Interv*, 49: 357–62.
34. Yoo BS, Yoon J, Ko JY, Kim JY, Lee SH, Hwang SO, Choe KH (2005) Anatomical consideration of the radial artery for transradial coronary procedures: arterial diameter, branching anomaly and vessel tortuosity. *Int J Cardiol*, 101: 421–427.