

# Variant origin of superior polar artery and unusual hilar branching pattern of renal artery with clinical correlation

V. Budhiraja, R. Rastogi, A.K. Asthana

Department of Anatomy, Subharti Medical College, India

[Received 14 August 2010; Accepted 2 November 2010]

*Classically, a single renal artery arising from the abdominal aorta supplies the respective kidney on each side. Near the hilum of the kidney each renal artery divides into anterior and posterior branches, which in turn divide into segmental arteries supplying the different renal segments. A total of 84 formalin fixed cadavers (73 male and 11 female, 168 kidneys in total) constituted the material for the study. During routine abdominal dissection conducted for medical undergraduates, the kidneys and their arteries were explored and variations in morphological patterns of renal arteries were noted. We observed superior polar renal artery in 22.6% cases. Superior polar renal arteries had different sources of origin. In 10.7% of cases it came directly from the abdominal aorta as an accessory renal artery; in 5.4% of cases as a direct branch from the main renal artery; in 3.6% of cases from the superior hilar renal artery (from one of the duplicated renal arteries); and in 3.0% of cases from a segmental branch of the renal artery. We also observed unusual hilar branching patterns of renal arteries, which included a fork pattern in 11.3% of cases, ladder pattern in 7.7% of cases, net pattern in 5.9% of cases, and triplicate in 3.0% of cases. Understanding the anatomy of vascular variations of the kidney is essential for the clinician to be able to perform procedures such as renal transplantation, interventional radiological procedures, and renal vascular operations more safely and efficiently. (Folia Morphol 2011; 70, 1: 24–28)*

**Key words:** kidney, anatomical variations, superior polar artery

## INTRODUCTION

Renal arteries arise from the abdominal aorta below the origin of the superior mesenteric artery, on each side. Near the hilum of the kidney, each renal artery divides into anterior and posterior branches, which in turn divide into a number of segmental arteries supplying the different renal segments. The presence of unusual branching patterns of the renal arteries is not uncommon. In 70% of cases there is a single renal artery supplying each kidney [29]. Renal arteries exhibit a high degree of variation. Most of these varia-

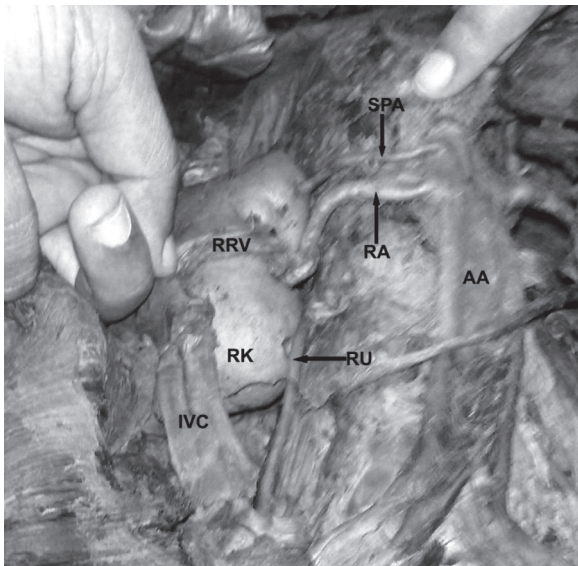
tions remain undiscovered until being noticed during a surgical procedure or they are found by forensic pathologists during autopsy [14]. Awareness of these possible variations of renal arteries is necessary for surgical management during renal transplantation, repair of abdominal aorta aneurysms, urological procedures, and angiographic interventions [16, 18, 25].

## MATERIAL AND METHODS

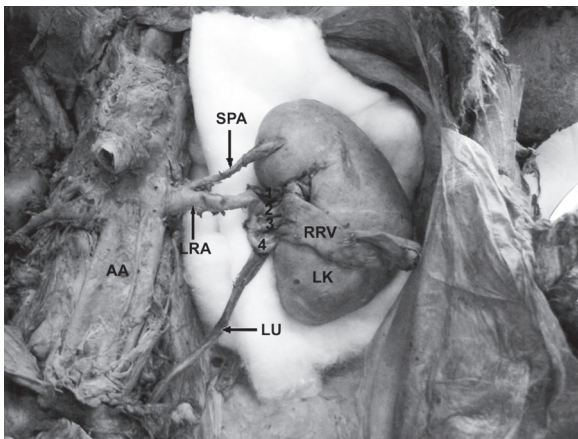
A total of 84 formalin fixed cadavers (73 male and 11 female, 168 kidneys in total) constituted the

---

Address for correspondence: V. Budhiraja, Associate Professor, Department of Anatomy, Subharti Medical College Meerut (U.P.), India, tel: 919 897 244 802, fax: 91121 2439 127, e-mail: [Simranbudhiraja21@gmail.com](mailto:Simranbudhiraja21@gmail.com); [budhirajasimran46@gmail.com](mailto:budhirajasimran46@gmail.com)

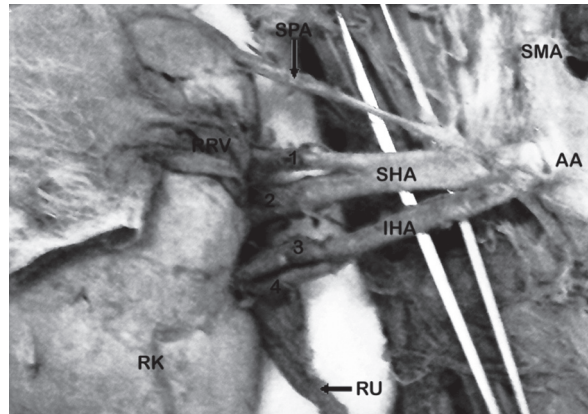


**Figure 1.** Superior polar artery originating from abdominal aorta; RK — right kidney; AA — abdominal aorta; RA — renal artery; RRV — reflected renal vein; IVC — inferior vena cava; SPA — superior polar artery, RU — right ureter.



**Figure 2.** Fork pattern of segmental branches and superior polar artery originating from renal artery; LK — left kidney; LRA — left renal artery; AA — abdominal aorta; SPA — superior polar artery; LU — left ureter; RRV — reflected renal vein; 1, 2, 3, 4 — segmental branches arranged in fork pattern.

material for the study. During routine abdominal dissection conducted for medical undergraduates of the Department of Anatomy, Subharti Medical College, the kidneys and their arteries were explored and variations in morphological patterns of renal arteries were noted. During the course of dissection, various abdominal viscera were removed and preserved as specimens for teaching purposes. Renal veins were also reflected for proper visualization of segmental patterns of renal arteries.



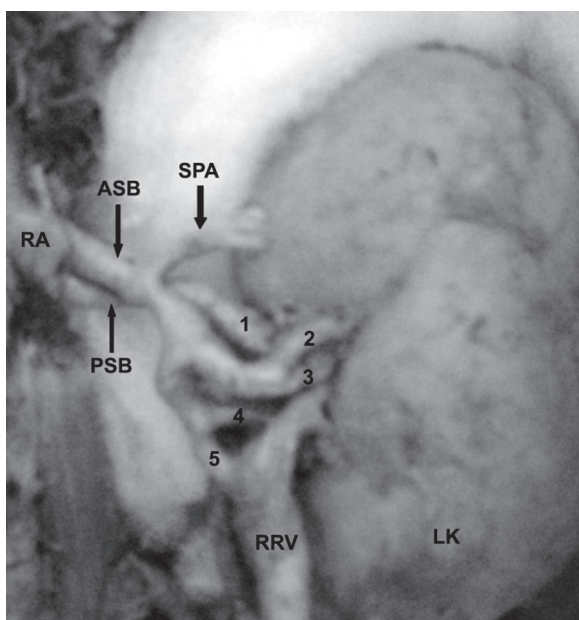
**Figure 3.** Ladder pattern of segmental branches and superior polar artery originating from superior hilar artery; RK — right kidney; AA — abdominal aorta; SMA — superior mesenteric artery; RU — right ureter; SPA — superior polar artery; RRV — reflected renal vein; SHA — superior hilar artery; IHA — inferior hilar artery; 1, 2, 3, 4 — segmental branches arranged in ladder pattern.

## RESULTS

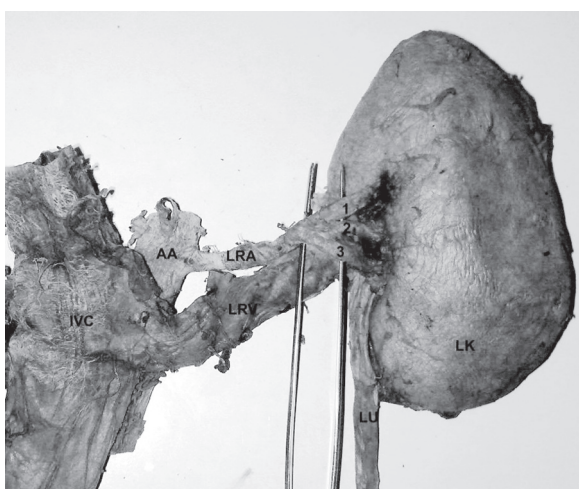
We observed superior polar renal artery in 22.6% (38/168) of cases. The superior polar renal artery had a different source of origin. In 10.7% (18/168) of cases it came directly from the abdominal aorta as an accessory renal artery (Fig. 1); in 5.4% (9/168) of cases it was a direct branch from the main renal artery (Fig. 2); in 3.6% (6/168) of cases it came from the superior hilar renal artery (Fig. 3) (from one of the duplicated renal arteries); and in 3.0% (5/168) of cases from a segmental branch of the renal artery (Fig. 4). We also observed unusual hilar branching patterns of the renal artery, including a fork pattern in 11.3% (19/168) of cases (Fig. 2). In the fork pattern the main renal artery near the hilum of the kidney first dipped and then divided into segmental arteries, which ran parallel to each other. A ladder pattern was observed in 7.7% (13/168) of cases (Fig. 3). In the ladder pattern the main renal artery or superior and inferior renal arteries near the hilum divided into segmental arteries, which were arranged one above the other, like a ladder. A net pattern was found in 5.9% (10/168) of cases (Fig. 4). In the net pattern the renal artery divided into segmental arteries that were arranged in such a way that gaps were present in between them, like a net. A triplicate pattern was present in 3.0% (5/168) of cases (Fig. 5), in which the renal artery divided into three segmental branches at the hilum.

## DISCUSSION

Renal artery variations including their number, source and course are very common. Irregularities



**Figure 4.** Net pattern of segmental branches and superior polar artery originating from segmental branch of renal artery; LK — left kidney; RA — renal artery; ASB — anterior segmental branch; PSB — posterior segmental branch; SPA — superior polar artery; RRV — reflected renal vein; 1, 2, 3, 4, 5 — segmental branches arranged in net pattern.



**Figure 5.** Triplicate pattern of segmental branches; LK — left kidney; AA — abdominal aorta; IVC — inferior vena cava; LRA — left renal artery; LRV — left renal vein; LU — left ureter; 1, 2, 3 — segmental branches arranged in triplicate pattern.

of renal vessels are found in about 35% of cases, the most common being an additional or accessory artery arising above or below the usual renal artery [3]. Dhar and Lal [9] revealed accessory renal arteries in 20% of the specimens with unilateral anomaly in 15% and bilateral in 5% specimens respectively. Accessory renal artery enters the kidney through

hilum, inferior pole or superior pole. There are reports describing accessory renal arteries entering superior pole of kidney [7, 26, 28]. In the present study we observed superior polar renal artery in 22.6% of cases and we also determined various source of its origin.

In 10.7% of cases the superior polar artery originated directly from the abdominal aorta as an accessory or additional renal artery. Sampaio et al. [23] observed its origin from the aorta in 6.8% of kidneys. Bordei et al. [5] reported that in 5 out of 54 cases (9.25%) the supplementary renal artery entered the kidney through the superior pole, similarly to the present study. During development, the kidneys initially lie in the pelvic cavity. As the embryo grows they ascend to reach the lumbar region. When they are present in the pelvic cavity, they take their blood supply from branches of iliac arteries, and as they ascend their blood supply also shifts from the iliac arteries to the abdominal aorta. These accessory arteries are due to the persistence of embryonic vessels which are formed during the ascension of the kidneys [11]. Accessory renal arteries in the form of superior polar arteries, as observed in 10.7% of the cases in our study, also indicate the persistence of embryonic vessels. These accessory renal arteries are terminal vessels where lesions may produce segmental ischaemia with subsequent hypertension [1].

In our opinion it is essential for surgeons to bear in mind the possibility of such additional superior polar arteries before performing any transplantation surgeries, as kidney transplantation with multiple renal arteries has a chance of rejection, tubular necrosis, or poor graft function [6, 10, 12]. It has been reported previously that transplanted kidneys presenting anatomic vascular variations are associated with a significantly higher failure rate than that of kidneys with a single artery, and kidneys with polar vessels have a high primary failure rate due to renal vascular thrombosis [24]. However, even nowadays, to overcome increasing demand for kidney transplantation, living donor grafts have become a major source to maintain the donor pool, and an allograft with multiple arteries has become a necessity [13], so the knowledge of such variations has become even more important.

Sampaio et al. [23] described a superior polar artery originating from the renal artery in 14.3% of cases from 266 kidneys dissected from 133 fixed adult subjects. Das [8] also reported a case of superior polar renal branch from the main renal artery. Saldarriaga et al. [22] described the origin of the superior renal polar branch directly from the renal

artery on the right side in 26 kidneys (17.2%) and in 19 kidneys on the left side (13.5%). A superior polar renal artery was observed on the right side with greater frequency by them. We also observed superior polar renal artery originating from the main renal artery and from the superior hilar renal artery (one of the duplicated renal arteries) in 5.4% and 3.6% of cases, respectively. The percentage of superior polar arteries originating from the renal artery as observed by us was low in comparison to the above-mentioned studies. These superior polar extra-hilar branches of the renal artery can be injured during mobilization or other surgical procedures on the superior pole [23], so such branches should be kept in mind prior to surgery to prevent segmental ischaemia.

There are few reports of the origin of the superior polar artery from the segmental branch [2, 20]. In the present study we observed the superior polar artery emerging from segmental arteries in 3.0% of cases, and entering the upper pole along the medial border. As a result, these arteries have to travel vertically before entering the kidney. According to the report by Beyer and Daily [4], such vertically directed upper polar (superior polar) arteries cause upper pole infarction.

Near the hilum of the kidney each renal artery divides into an anterior and posterior branch, which in turn divide into segmental branches prior to their entrance through the hilum. The hilar pattern of segmental branches of the renal arteries have been discussed previously by a few authors [27, 30]. Nayak [17] described a case in which three renal arteries provided seven segmental branches, supplying one kidney. Among the seven branches, two entered the kidney by piercing through its anterior surface, and the remaining five entered through the hilum. In another case, Rusu [21] mentioned double right hilar renal arteries disposed side by side, the superior hilar and inferior hilar both dividing into two segmental branches each, which were arranged anterior and posterior to the renal pelvis, respectively. We also observed unusual hilar branching patterns of the renal artery, which included a fork pattern in 11.3% of cases, a ladder pattern in 7.7% of cases, a net pattern in 5.9% of cases, and triplicate in 3.0% of cases. In most of the cases these segmental branches arose from the main renal artery some distance before it reached the hilum of the kidney. The knowledge of such an unusual branching pattern of the segmental arteries prior to surgery could be helpful to surgeons, to gain vascular control by

clamping the desired branch because according to Weld et al. [30], selective segmental vascular control may offer more benefits over total hilar control while reducing overall renal ischaemic injury.

We believe that, in order to know the vascular pattern and to plan the appropriate surgical procedure to avoid any vascular complication, multi detector computer tomography, angiography, and arteriography should be performed prior to every nephrectomy [15, 19, 23], and awareness of the above-mentioned variations of the renal arteries is necessary for adequate surgical management in the exploration and treatment of renal trauma, renal transplantation, and urological operations.

## REFERENCES

1. Andersson I, Boijesen E, Hellsten S, Linell F (1979) Lesions of the dorsal renal artery in surgery for renal pelvic calculus, A potential cause of renovascular hypertension. *Eur Urol*, 5: 343–346.
2. Bakheit MA, Motabagani MA (2003) Anomalies of the renal, phrenic and suprarenal arteries: case report. *East Afr Med J*, 80: 497–500.
3. Bergman RA, Afifi AK, Miyauchi R (2010) Illustrated encyclopedia of human anatomic variations. Opus II: cardiovascular system, Arteries, Abdomen, Renal arteries. <http://www.anatomyatlases.org/Anatomicvariants/cardiovascular/Text/Arteries/Renal>.
4. Beyer RW, Daily PO (2004) Renal artery dissection associated with GZ acceleration. *Aviat Space Environ Med*, 75: 284–287.
5. Bordei P, Sapte E, Iliescu D (2004) Double renal arteries originating from the aorta. *Surg Radiol Anat*, 26: 474–479.
6. Brannen GE, Bush WH, Correa RJ, Gibbons RP, Cumes DM (1982) Microvascular management of multiple renal arteries in transplantation, *J Urol*, 128: 112–115.
7. Cicekcibasi AE, Ziylan T, Salbacak A, Seker M, Buyukmumcu M, Tuncer I (2005) An investigation of the origin, location and variations of the renal arteries in human fetuses and their clinical relevance. *Ann Anat*, 187: 421–427.
8. Das S (2008) Anomalous renal arteries and its clinical implications. *Bratisl Lek Listy*, 109: 182–184.
9. Dhar P, Lal K (2005) Main and accessory renal arteries — a morphological study. *Ital J Anat Embryol*, 110: 101–110.
10. Gupta V, Kotgirwar S, Trivedi S, Deopujari R, Singh V (2010) Bilateral variation in renal vasculature. *International journal of anatomical variations*. *IJAV*, 3: 53–55.
11. Hamilton WJ, Mossman HW (1979) In: *Human embryology*. 4th Ed. Mc Millan Press, New York, pp. 392.
12. Harrison LH, Flye MW, Seigler HF (1978) Incidence of anatomical variants in renal vasculature in the presence of normal renal function. *Ann Surg*, 188: 83–89.
13. Kadolani Y, Okamoto M, Nobori S, Kaibara S (2005) Management and outcome of living kidney grafts with multiple arteries. *Surg Today*, 35: 459–466.

14. Krishnasamy N, Rao M, Somayaji SN, Koshy S, Rodrigues V (2010) An unusual case of unilateral additional right renal artery and vein. *Intern J Anat Variation*, 3: 9–11.
15. Kunwabara M, Narumi Y, Takahashi S, Sato Y, Kim T, Murakami T, Nakamura H (2006) Non calculating the relative blood supply ratio of duplicated renal arteries in renal donors, *Radiat Med*, 24: 195–201.
16. Nathan H, Glezer L (1984) Right and left accessory renal arteries arising from a common trunk associated with unrotated kidneys. *J Urol*, 132: 7–9.
17. Nayak BS (2008) Multiple variations of the right renal vessels. *Singapore Med J*, 49: e153–e155.
18. Olsson O, Wholey M (1964) Vascular abnormalities in gross anomalies of kidneys. *Acta Radiol Diagn*, 2: 420–432.
19. Raman SS, Poj CS, Munagsombook K, Schulam PG, Gntsch HA, Lu DS (2007) Surgically relevant normal and variant renal parenchymal vascular anatomy in preoperative 16-MDCT evaluation of potential laproscopic renal donors. *Am J Roentgenol*, 188: 105–114.
20. Rao M, Bhat SM, Venkataramana V, Deepthinath R, Bolla SR (2006) Bilateral prehilar multiple branching of renal arteries: A case report and literature review. *Kathmandu Univer Med J*, 4: 345–348.
21. Rusu MC (2006) Human bilateral doubled renal and testicular arteries with a left testicular arterial arch around the left renal vein. *Rom J Morphol Embryol*, 47: 197–200.
22. Saldarriaga B, Pinto SA, Ballesteros LE (2008) Morphological expression of the renal artery. A direct Anatomical study in a Colombian half-caste population. *Int J Morphol*, 26: 31–38.
23. Sampaio FJ, Passos MA (1992) Renal arteries: anatomic study for surgical and radiological practice. *Surg Radiol Anat*, 4: 113–117.
24. Sanson JR, Hall JR, Barnes AD, Robinson BH, Blainey JD (1978) The significance of vascular anomalies in human renal transplantation. *Proc Eur Dial Transplant Assoc*, 15: 345–351.
25. Satyapal KS, Haffejee AA, Singh B, Ramsaroop L, Robbs JV, Kalideen JM (2001) Additional renal arteries: incidence and morphometry. *Surg Radiol Anat*, 23: 33–38.
26. Shakeri AB, Tubbs RS, Shoja MM, Pezeshk P, Farahani RM, Khaki AA, Ezzati F, Seyednejad F (2007) Bipolar supernumerary renal artery. *Surg Radiol Anat*, 29: 89–92.
27. Shoja MM, Tubbs RS, Shakeri A, Loukos M, Ardalan MR, Khosroshahi HT, Oakes WJ (2008) Perihilar branching patterns and morphologies of renal artery: a review and anatomical study. *Surg Radiol Anat*, 30: 375–382.
28. Singh G, Ng YK, Bay BH (2001) Bilateral accessory renal arteries associated with some anomalies of the ovarian arteries: a case study. *Clin Anat*, 11: 417–420.
29. Standring S (2005) *Gray's anatomy The anatomical basis of clinical practice*. 39<sup>th</sup> Ed. Elsevier-Churchill Livingstone Publishers, London, pp. 1274–1275.
30. Weld KJ, Bhayani SB, Belani J, Ames CD, Hruby G, Landman J (2005) Extrarenal vascular anatomy of kidney: assessment of variations and their relevance to partial nephrectomy. *Urology*, 66: 985–989.