

# Follicular dynamics in neonate vitrified ovarian grafts after host treatment with melatonin

M. Hemadi<sup>1</sup>, G. Saki<sup>1</sup>, S. Shokri<sup>2</sup>, F.M. Ghasemi<sup>3</sup>

<sup>1</sup>Physiology Research Centre, Ahvaz Jundishapur University of Medical Sciences, Ahvaz, Iran

<sup>2</sup>Anatomy Department, School of Medicine, Zanjan University of Medical Sciences, Zanjan, Iran

<sup>3</sup>Anatomy Department, School of Medicine, Gilan University of Medical Sciences, Rasht, Iran

[Received 8 September 2010; Accepted 23 October 2010]

*This study evaluates the effect of melatonin on follicular dynamics in neonate vitrified ovarian grafts. Vitrified ovaries from neonate F1 hybrid mice, candidates for transplantation to treated or non-treated groups, were thawed under standard conditions with or without the addition of 100 µM melatonin, respectively. Following transplantation, melatonin (20 mg/kg/day) or saline solution was injected i.p. into the treated and the non-treated groups, respectively. Vaginal cytology to monitor estrogenic activity together with follicle survival and development in the ovary grafts was examined.*

*The results showed that the sites of transplantation became obvious within the oestrous phase. Histological analysis showed that there was a dynamic of the ovogenesis process in the vitrified ovary grafts. However, in the ovary graft the empty cavity together with jumbled oocyte-granulosa complex in the non-treated group was higher than in the melatonin treated group.*

*Overall, the number of primary follicles in the ovary grafts of both groups remained constant throughout the oestrous period. However, the treated ovary grafts contained more secondary follicles throughout the oestrous period in comparison to non-treated ovary grafts. The antral follicle rates were more marked in the melatonin treated group than in the non-treated group during the oestrous period, whereas at other days of the cycle no significant difference was observed. The fresh corpora lutea rates were significantly higher in the treatment group than in the non-treatment group.*

*The study showed that there is a positive effect with melatonin resulting in more grafts restoring puberty. Furthermore, the associated increase in healthy follicles suggests that melatonin has a preventative ischaemia/antioxidant action and may be useful to follicles. (Folia Morphol 2011; 70, 1: 18–23)*

**Key words:** melatonin, ovaries allograft, vitrification, reactive oxygen species, ovariectomy, oestrous cyclicity

## INTRODUCTION

Ovary banking is a developing method designed to save fertility in females under threat of premature ovarian failure [2, 16, 19]. It involves cryopreservation of the ovaries with the option of transplantation. Reports on the transplantation of cryopreserved ovaries illus-

trate the resumption of the hypothalamic–pituitary–ovarian axis [11], follicle development [4, 21], and even successful pregnancies [5, 22]. However, deficiency of the activity of steroid production drive from recipients relevant to ovariectomy or premature ovarian failure, as well as organ loss due to procedural steps, is expect-

Address for correspondence: G. Saki, PhD, Associated Professor, Physiology Research Centre, Ahvaz Jundishapur University of Medical Sciences, Golestan Avenue, P.O. Box 61355-45, Ahvaz, Iran, tel: +98 916618 1685, fax: +98 611 3332036, e-mail: ghasemsaki@yahoo.com

ed to have had negative effects on the reproductive potential of cryopreserved-warmed ovarian grafts; therefore, the future of ovarian transplantation will depend on follow up and making a healthy situation for it in the host during the post grafting time. Recent reports from studies on improving the quality of ovarian grafts have confirmed that administration of melatonin improved the follicular development of ovarian grafts [6, 7]. Melatonin is a hormone synthesized in the pineal gland and other organs such as lacrimal and retina [13, 17]. Recently it was shown that the ovary can produce melatonin as well [8]. Moreover, it was reported that melatonin reduces the elevated gonadotropins and regulates the disturbance of endocrine oestrous cycle function observed in menopausal females as well as ovariectomized hosts of vitrified ovary grafts into the physiological conditions of mature females [7]. Therefore, melatonin could be considered as a substance to improve the dynamic process of follicles in the ovarian graft during the oestrous period. Previous reports have shown direct effects of variable melatonin regimen on the folliculogenesis and oogenesis of *in vitro* cultured ovarian follicles [1]. Melatonin also protects the ovaries against oxidative damage associated with reperfusion following an ischaemic insult [26]. However, there has been no report on the protective effect of melatonin on follicular dynamic of oestrous cyclicity in vitrified ovarian grafts yet. Therefore, we conducted a study in a mouse model to investigate whether the administration of melatonin (the optimum dose of melatonin from our dose-finding study, unpublished data) before the cryopreservation process and after transplantation has any positive effect on dynamic follicles throughout the oestrous phase.

## MATERIAL AND METHODS

### Drugs

Melatonin (Helsinn Advanced Synthesis SA, Biasca and Sigma Chemicals, Buchs, Switzerland) was used for treatment by *i.p.* (intra-peritoneal) injection.

### Animals

These experiments were carried out in accordance with the Ahvaz University Guide for the Care and Use of Laboratory Animals. Ten-day-old female (CBA × C57Bl/6) F1 hybrid mice were used as ovarian donors and 8–10 week-old females of the same strain were used as ovarian recipients (Pasture Institute of Iran). Recipient mice were randomly assigned either as control (group I) or treated (group II). Group I obtained physiological saline, and Group II received melatonin (20 mg/kg/day). Each of the groups was further dis-

tributed randomly into six subgroups. The recipient mice in each subgroup sacrificed at day diestrous 1 ( $n = 6$ ), prestrous ( $n = 6$ ), estrous ( $n = 6$ ), metestrous ( $n = 6$ ), or diestrous 2 ( $n = 6$ ). As sham, for each subgroup, the same number mice were sham operated: After anaesthesia, the ovaries were visualized and replaced. These sham mice did not receive any graft.

### Ovary vitrification

Intact ovaries of ten-day-old mice were recovered and vitrified as previously published [12], with the following modifications: medium containing 40% ethylene glycol (*v/v*), 30% ficoll 70 (*w/v*), and 1 M sucrose supplemented with foetal bovine serum (EFS40) (Sigma-Aldrich, USA). Whole ovaries were exposed to increasing concentrations of vitrification solution (VS) (12.5, 25, 50, and 100%). The first two steps lasted 5 minutes at room temperature, and the next two for 15 minutes at 4°C. Each of the ovaries was then transferred into 1.8 mL cryogenic vials (Nunc, Roskilde, Denmark) containing EFS40. The vials were transferred directly into liquid nitrogen at -196°C. Before grafting, the ovaries were rapidly warmed in air at room temperature for 30 seconds and then immersed in water at 30–35°C for 5 minutes. The ovaries were removed from the cryovials and placed successively in solutions containing decreasing VS concentrations (50, 25, and 12.5%) and finally washed in  $\alpha$ MEM.

### Melatonin treatment *in vitro*

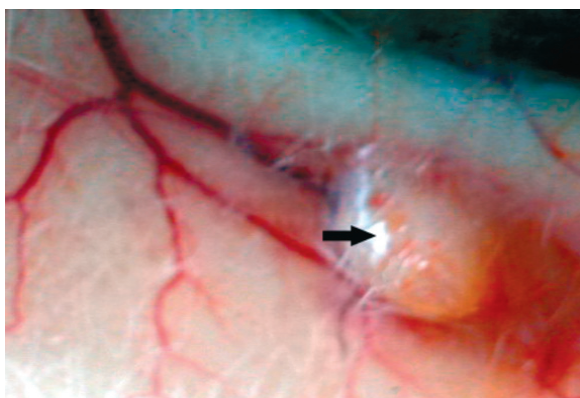
The thawed ovaries were further incubated for 30 minutes in  $\alpha$ MEM plus 10% FBS, with or without 100  $\mu$ M additive melatonin, before being transplanted subcutaneously on the back of ovariectomized recipients of treatment (group II) or no treatment (group I), respectively.

### Ovary transplantation

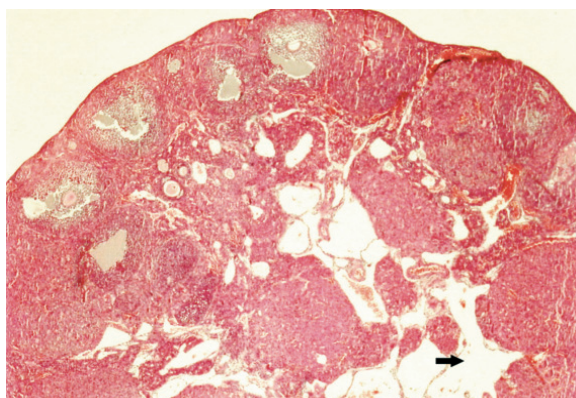
At first, ovariectomy was performed by excision between the uterine horn and the fallopian. The intact vitrified thawed ovaries were subsequently inserted bilaterally into the subcutaneous-site (into adipose; bilaterally adjacent to the midline) on the back of recipient mice. Sham animals were subjected to surgery without implantation of ovary.

### Melatonin treatment *in vivo*

After transplanting, melatonin 20 mg/kg/day was applied by intraperitoneal (*i.p.*) injections in 0.2 mL of 0.9% saline to the host mice (group I) once a day at 18:00 h (1 h before initiation of 12 h dark phase) for up to 48 h. Group II received only saline. Treatment was started 1–4 h after transplantation.



**Figure 1.** Representative micrograph of subcutaneous site of ovary graft in host mice (arrow). Note the presence of revascularisation surrounding the transplant site to provide enough blood to the graft.



**Figure 2.** Histological cross-section of grafted neonate ovary retrieved from treatment recipients 32 days after transplantation: Section of ovary showing normal oogenesis. Note the presence of the empty cavity (arrow) and the messy interstitial appearance, leading to a heterogeneous appearance of the ovary.

### Histology staining

Ovaries fixed in 4% buffered formaldehyde (37% Formaldehyde, Merck, Germany) were embedded in paraffin blocks, and the whole ovary was sectioned serially at 4  $\mu\text{m}$  thickness. Three sequential sections were put on each slide. The slides were stained with haematoxylin and eosin (Sigma-Aldrich, USA).

### Ovarian histology and follicle counting

Follicle count and categorization was carried out as previously published [18], using ovarian serial sections of both groups. With the exception of primordial follicles, both healthy and atretic follicles were included in the study. The follicles were divided into four groups based on their number, the form of the layers of follicular cells, and by the presence (or absence) of an antral cavity: primary follicle (one layer of cuboidal granulosa cells), second follicle (more than one layer of cuboidal granulosa cells without an antral cavity), antral follicles (with an antral cavity), and preovulatory follicle (with a large antral cavity). Within the ovary, two forms of follicle loss can be distinguished [18]. Atretic follicles were detected by granulosa cell apoptosis. Atretic follicles were identified by the presence of pyknotic nuclei of oocyte [3, 14]. In addition, the number of fresh corpora lutea, i.e. corpora lutea formed during the last ovarian cycle, was counted in serial sections of ovaries collected on the day of oestrus. Newly formed corpora lutea can be distinguished from older ones by their irregular size and the morphology of the granulosa luteal cells [18]. All sections were examined by light microscopy. The photographed examined sections (approximately every tenth section) were scored by NIH Image software.

### Statistical analysis

Two-way variance analysis was used to compare the mean numbers of follicles from Group I and Group II. The proportion of follicles in different developmental stages was compared by means of  $\chi^2$  test. Results are expressed as mean  $\pm$  SE. A p value  $< 0.05$  was considered significant.

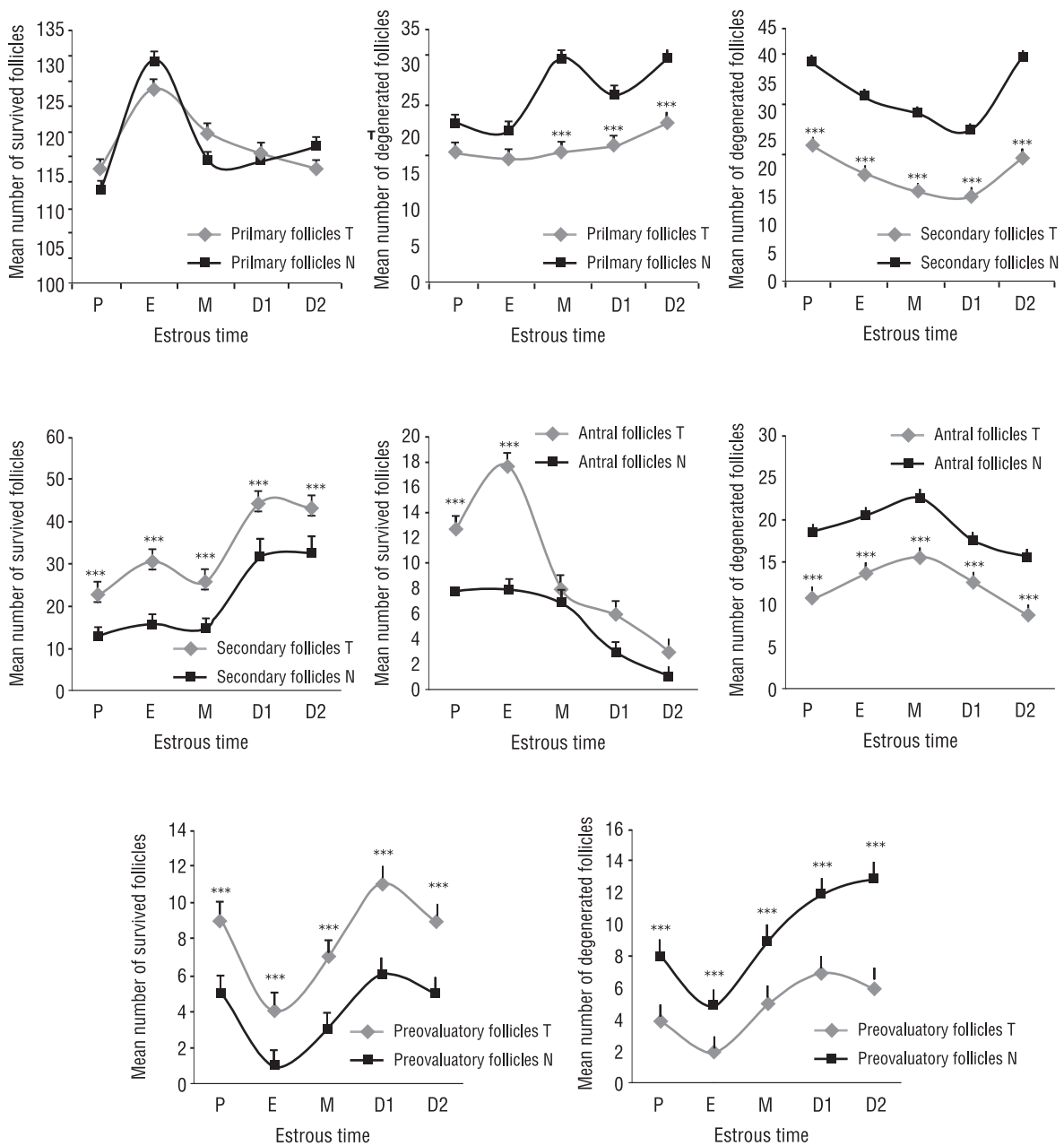
## RESULTS

### General observations of transplanted vitrified-warmed ovaries throughout the oestrous phase

The sites of transplantation were swollen and became obvious within the oestrous phase (Fig. 1). Histological analysis showed complete ovogenesis in the grafts of neonate ovaries, which formerly had primordial follicles. The dynamics of the ovogenesis process were equal to the follicular dynamic which takes place in the mature ovary during the oestrous cycle. However, in the ovary graft the empty cavity together with jumbled oocyte-granulosa complex, sloughing of granulosa cells and the messy appearance of interstitial in non-treated group was higher than in melatonin treated group (Fig. 2).

### Evaluation of the effect of melatonin on ovarian graft follicles within the oestrous phase

An outline of the statistics obtained is shown in Figure 3. Overall, there were significant differences in the total number of follicles obtained from the control ( $n = 321$ ) and melatonin treated ( $n = 556$ ) ovary grafts at the first oestrous phase after trans-



**Figure 3.** Follicular distribution in grafted neonate ovaries on different days of the oestrous period. Data are shown as mean + SEM; p-values compared among treated and non-treated groups; \*\*\*p < 0.001. For comparison to non-treated group; T — treated group; N — non-treated group; P — prestrous; E — estrous; M — metestrous; D1 — 1<sup>st</sup> day of diestrus; D2 — 1<sup>st</sup> day of diestrus.

plantation. When the oestrous cycle in both groups was stratified by the most type of follicles which were observed at certain days of the oestrous cycle, it was shown that secondary follicles and antral follicles were detected at proestrous and oestrous stages in most ovary grafts, respectively. However, the number of primary follicles in ovary grafts of both groups stayed steady throughout the oestrous period (Fig. 3). With respect to the

primary follicles, treated ovary grafts contained more follicles throughout the oestrous period in comparison to non-treated ovary grafts ( $p \geq 0.001$  for secondary follicles during proestrous, oestrous, metestrous, diaestrous  $p \geq 0.001$  for antral follicles within proestrous, oestrous) (Fig. 3). Generally, in the oestrous cycle, the ovary grafts of the treated group had a higher rate of growing follicles than the non-treated group.



### Evaluation of the effect of melatonin on preovulatory follicles

The number of fresh corpora lutea was counted in both groups on the day of oestrous as a reflection of the number of ovulations during the last oestrous phase. The mean number of fresh corpora lutea present was higher in the treatment group ( $9.8 \pm 0.5$ ) than in the non-treatment group ( $7.8 \pm 0.8$ ;  $p \geq 0.05$ ).

## DISCUSSION

Recently it was shown that melatonin administration not only has not been disorder the circadian rhythm of melatonin levels in ovariectomized mice but also may decrease the elevated gonadotropin secretions in the ovariectomized mice to levels similar to those of intact mice [7]. Also, melatonin caused the characteristics of sex steroids to be modified in the ovariectomized mice which received the neonate ovaries as a mechanism that takes place throughout the oestrous cycle of adult intact mice [7].

Moreover, it was reported that melatonin could improve the development of primordial follicles to the next stage and help them undergo the full range of morphological changes associated with oocyte maturation in neonate ovary grafts [6]. The present study revealed that the distribution of variable growing follicles in ovarian grafts which were obtained from melatonin treated/non-treated host mice throughout the oestrous cycle were different as well. Examination of follicles during the oestrous cycle showed that melatonin might increase the number of secondary follicles at the proestrous time, confirming the role of melatonin in initial follicle recruitment [1, 10]. Indeed, in the oestrous phase, the number of antral follicles of ovarian grafts in the non-treated group was lower than those of the melatonin treated group. This implies that oestradiol secretions in non-treated host mice are lower than those of treated mice. Because oestradiol is mainly produced by the antral follicles [20]. Furthermore, the number of corpora lutea, as a reflection of the number of pre-ovulatory follicles at last oestrous period in treated group, was higher than in the non-treated group. The presence of more follicles at the appropriate stage in treated ovarian grafts could explain this enhanced recruitment. However, it is also possible that the lower number of follicles in non-treated ovarian grafts display an increased sensitivity toward follicle stimulating hormone (FSH). Melatonin and its type II receptor dis-

play a similar expression pattern being expressed in growing follicles with higher expression in the secondary and the antral follicles than in the primary follicles [1, 23, 24]. This window of melatonin expression is also reflected by the melatonin serum levels, which showed a small but significant increase during the oestrous period, correlating with the increased number of secondary and antral follicles [15]. Thus, in the non-treated host mice, the lower FSH levels were sufficient to recruit the primary follicles because the absence of melatonin renders the follicles more sensitive to FSH [25]. FSH sensitivity of primary follicles is similar in melatonin treated and non-treated mice because the melatonin type II receptor is not expressed in follicles at this stage [23, 24]. As a result, FSH levels in non-treated host mice are too low to support the follicles for dominance, and a normal number of ovulations ensue. Indeed, a rise in FSH levels in a superovulation scheme demonstrated that treated follicles of ovarian grafts can be rescued and supported to the preovulatory stage, resulting in a large increase in the number of retrieved oocytes in treated mice, compared with non-treated host mice. It has been shown that the increased number of follicles capable of ovulating upon melatonin administration reflects a reduction in the number of follicles undergoing atresia [9]. Indeed, the number of oocytes retrieved in both treated and non-treated mice corresponds with the total number (non-healthy and healthy) of antral follicles observed during oestrous time.

Therefore, further experiments are necessary to identify the mechanisms of the effects of melatonin treatment on follicular dynamics and the secretion of oestradiol in neonate vitrified ovarian grafts after host treatment with melatonin, and we suggest that other researchers identify the precise expression of melatonin type I and II receptors and plasma concentration of oestradiol during the influence of melatonin on the transplantation/fertility complication.

## CONCLUSIONS

In conclusion, our results revealed that a cause-effect relationship between the administration of melatonin and the distribution of variable growing follicles in ovarian grafts during the oestrous cycle may in fact exist. The follow up controls show that melatonin enhanced recruitment, increased follicle-related neurovegetative disturbances, and restored menstrual cyclicity and fertility in host females. At present we can assert that the treatment with me-

latonin produced a remarkable and highly significant improvement of ovarian graft function and positive changes of development follicles towards more preovulatory follicles.

## ACKNOWLEDGEMENTS

This study was supported by a research grant from the Ahvaz Jundishapur University of Medical Sciences and Health service, Ahvaz, Iran (grant No.u-88336).

## REFERENCES

- Adriaens I, Jacquet P, Cortvrindt R, Janssen K, Smits J (2006) Melatonin has dose-dependent effects on folliculogenesis, oocyte maturation capacity and steroidogenesis. *Toxicology*, 228: 333–343.
- Bedaiwy MA, Falcone T (2004) Ovarian tissue banking for cancer patients: reduction of post-transplantation ischaemic injury: intact ovary freezing and transplantation. *Hum Reprod*, 19: 1242–1244.
- Byskov AG (1974) Cell kinetic studies of follicular atresia in the mouse ovary. *J Reprod Fertil*, 37: 277–285.
- Cox S, Shaw J, Jenkin G (2000) Follicular development in transplanted fetal and neonatal mouse ovaries is influenced by the gonadal status of the adult recipient. *Fertil Steril*, 74: 366–371.
- Demeestere I, Simon P, Emiliani S, Delbaere A, Englert Y (2007) Fertility preservation: successful transplantation of cryopreserved ovarian tissue in a young patient previously treated for Hodgkin's disease. *Oncologist*, 12: 1437–1442.
- Hemadi M, Abolhassani F, Akbari M, Sobhani A, Pasbakhsh P, Ahrlund-Richter L, Modaresi MH, Salehnia M (2009) Melatonin promotes the cumulus-oocyte complexes quality of vitrified-thawed murine ovaries; with increased mean number of follicles survival and ovary size following heterotopic transplantation. *Eur J Pharmacol*, 618: 84–90.
- Hemadi M, Saki G (2010) Endocrine function and duration time of estrous cyclicity of the ovariectomized recipient neonate vitrified ovarian grafts mice after treatment with melatonin. *Int J Pharmacol*, 6: 379–385.
- Itoh MT, Ishizuka B, Kuribayashi Y, Amemiya A, Sumi Y (1999) Melatonin, its precursors, and synthesizing enzyme activities in the human ovary. *Mol Hum Reprod*, 5: 402–408.
- Luther JS, Redmer DA, Reynolds LP, Choi JT, Pant D, Navanukraw C, Arnold DR, Scheaffer AN, Borowicz P, Kirsch JD, Weigl RM, Kraft KC, Grazul-Bilska AT (2005) Ovarian follicular development and oocyte quality in anestrous ewes treated with melatonin, a controlled internal drug release (CIDR) device and follicle stimulating hormone. *Theriogenology*, 63: 2136–2146.
- Markantonis SL, Tsakalozou E, Paraskeva A, Staikou C, Fassoulaki A (2008) Melatonin pharmacokinetics in premenopausal and postmenopausal healthy female volunteers. *J Clin Pharmacol*, 48: 240–245.
- Mason JB, Cargill SL, Anderson GB, Carey JR (2009) Transplantation of young ovaries to old mice increased life span in transplant recipients. *J Gerontol A Biol Sci Med Sci*, 64: 1207–1211.
- Mazoochi T, Salehnia M, Valojerdi MR, Mowla SJ (2008) Morphologic, ultrastructural, and biochemical identification of apoptosis in vitrified-warmed mouse ovarian tissue. *Fertil Steril*, 90: 1480–1496.
- Mhatre MC, van Jaarsveld AS, Reiter RJ (1988) Melatonin in the lacrimal gland: first demonstration and experimental manipulation. *Biochem Biophys Res Commun*, 153: 1186–1192.
- Morita Y, Tilly JL (1999) Oocyte apoptosis: like sand through an hourglass. *Dev Biol*, 213: 1–17.
- Nakamura Y, Tamura H, Takayama H, Kato H (2003) Increased endogenous level of melatonin in preovulatory human follicles does not directly influence progesterone production. *Fertil Steril*, 80: 1012–1016.
- Oktay K, Sonmezer M (2004) Ovarian tissue banking for cancer patients: fertility preservation, not just ovarian cryopreservation. *Hum Reprod*, 19: 477–480.
- Pang SF, Brown GM, Grota LJ, Chambers JW, Rodman RL (1977) Determination of N-acetylserotonin and melatonin activities in the pineal gland, retina, Harderian gland, brain and serum of rats and chickens. *Neuroendocrinology*, 23: 1–13.
- Pedersen T, Peters H (1968) Proposal for a classification of oocytes and follicles in the mouse ovary. *J Reprod Fertil*, 17: 555–557.
- Revel A, Schenker J (2004) Ovarian tissue banking for cancer patients: is ovarian cortex cryopreservation presently justified? *Hum Reprod*, 19: 14–19.
- Richards JS (1980) Maturation of ovarian follicles: actions and interactions of pituitary and ovarian hormones on follicular cell differentiation. *Physiol Rev*, 60: 51–89.
- Santos RR, Knijn HM, Vos PL, Oei CH, Van Loon T, Colenbrander B, Gadella BM, Van den Hurk R, Roelen BA (2009) Complete follicular development and recovery of ovarian function of frozen-thawed, autotransplanted caprine ovarian cortex. *Fertil Steril*, 91: 1455–1458.
- Silber SJ, Grudzinskas G, Gosden RG (2008) Successful pregnancy after microsurgical transplantation of an intact ovary. *N Engl J Med*, 359: 2617–2618.
- Soares JM Jr, Masana MI, Erşahin C, Dubocovich ML (2003) Functional melatonin receptors in rat ovaries at various stages of the estrous cycle. *J Pharmacol Exp Ther*, 306: 694–702.
- Sundaresan NR, Marcus Leo MD, Subramani J, Anish D, Sudhagar M, Ahmed KA, Saxena M, Tyagi JS, Sastry KV, Saxena VK (2009) Expression analysis of melatonin receptor subtypes in the ovary of domestic chicken. *Vet Res Commun*, 33: 49–56.
- Tamura H, Nakamura Y, Korkmaz A, Manchester LC, Tan DX, Sugino N, Reiter RJ (2009) Melatonin and the ovary: physiological and pathophysiological implications. *Fertil Steril*, 92: 328–343.
- Turkoz Y, Celik O, Hascalik S, Cigremis Y, Hascalik M, Mizrak B, Yologlu S (2004) Melatonin reduces torsion-detorsion injury in rat ovary: biochemical and histopathologic evaluation. *J Pineal Res*, 37: 137–141.