

# Volumetric evaluation of hemicerebellar changes in migraine patients without aura

N. Gocmen-Mas<sup>1</sup>, O.Y. Kusbeci<sup>2</sup>, H.S. Karabekir<sup>3</sup>, T. Ertekin<sup>4</sup>, A. Yucel<sup>5</sup>, A.C. Yazici<sup>6</sup>

<sup>1</sup>Department of Anatomy, Kocatepe University Faculty of Medicine, Turkey

<sup>2</sup>Department of Neurology, Kocatepe University Faculty of Medicine, Turkey

<sup>3</sup>Department of Neurosurgery, Kocatepe University Faculty of Medicine, Turkey

<sup>4</sup>Department of Anatomy, Erciyes University School of Medicine, Turkey

<sup>5</sup>Department of Radiology, Kocatepe University Faculty of Medicine, Turkey

<sup>6</sup>Department of Biostatistics, Baskent University School of Medicine, Turkey

[Received 24 August 2011; Accepted 19 September 2011]

*Brain balance changes have been recognised in migraine, but cerebellar function between or during attacks has been assessed only in a few studies. Previous studies have indicated that migraine affects cerebellar function. In the present study we aimed to evaluate the hemicerebellar volume changes of patients with migraine without aura (MWOA). Volumetric changes of cerebellar hemispheres were evaluated in terms of asymmetry using stereological methods on magnetic resonance images (MRI) retrospectively. Nineteen patients with MWOA and 18 age- and gender-matched control subjects were included in the study. MRIs were analysed by using the point-counting approach of stereological methods by Cavalier's principle. There was no statistically significant cerebellar atrophy or hemicerebellar asymmetry between the MWOA and control subjects. There was no cerebellar atrophy or asymmetry between the MWOA and age-matched control group. The stereological evaluation of cerebellar asymmetry and atrophy in humans is important for both clinicians and anatomists. The technique is simple, inexpensive, and reliable. (Folia Morphol 2011; 70, 4: 235–239)*

**Key words:** migraine without aura, Cavalier's principle and stereology, magnetic resonance imaging, cerebellum, brain

## INTRODUCTION

Migraine is a common neurovascular disease that affects 10% to 12% of the population and is typically characterised by recurrent attacks, each lasting 4 to 72 hours by definition. The unilateral pulsating pain may be intense enough to interrupt daily activities and worsens with physical activity. Nausea, vomiting, and photo- and phonophobia accompany the moderate to severe pain [24], a series of different neurological focal abnormalities named aura, may occur in close association with the pain,

typically before the headache onset [10, 24]. The International Headache Society (IHS) classifies migraine headaches, among other less frequent subtypes, as migraine with aura (MWA), or migraine without aura (MWOA), according to the presence of aura symptoms [12]. Balance changes and vertigo have been recognised in migraine but cerebellar function between or during attacks was assessed only in a few studies [24].

Ictal and interictal balance abnormalities in treatment-free patients [4, 13], compromised vestibulo-

Address for correspondence: S. Karabekir, MD, Assistant Prof., Kocatepe University School of Medicine, Department of Neurosurgery, Afyonkarahisar, Turkey, tel: +902722463301, fax: +902722463300, e-mail: hskarabekir@hotmail.com

cerebellar function in migraineurs [11], and interictal subclinical cerebellar impairment expressed as a lack of fine coordination [21] indicate that migraine affects cerebellar function [11, 24]. Circulatory changes may take place in the cerebellum during migraine attacks. Following vasoconstricting anti-migraine agent administrations, infarctions have been described in the cerebellum, showing that this area was probably predisposed to ischaemia as compared to other regions [14, 17, 24]. In migraine, decreased perfusion and cerebellar symptoms including dysarthria, ataxia, and dizziness have been described [6, 18, 24].

In the literature there are some reports on migraine as a risk factor for subclinical brain lesions. A Dutch study reported migraineurs to have a disproportionately high prevalence of magnetic resonance imaging (MRI)-documented, asymptomatic cerebellar stroke. Cure and Rothrock evaluated three migraineurs with prolonged status migrainosus complicated by cerebellar infarction [5]. Cerebellar volume changes due to unilateral cerebral lesions which were associated with atrophy of the contralateral cerebellar hemisphere are not rare [1]. Some studies that include neuroradiological information such as paraneoplastic cerebellar degeneration have shown cerebellar atrophy [22]. The objective of this study was to evaluate the cerebellar volume and asymmetry in patients with migraine. The value of this study rests in the fact that there is no study in the literature that investigates cerebellar asymmetry in migraine patients by adopting the stereological technique. In order to fill in this gap, we aimed to utilise the stereological technique to evaluate the cerebellar volume and asymmetry in patients with migraine and to determine the probable volumetric atrophy and asymmetry.

## MATERIAL AND METHODS

### Magnetic resonance image data

Nineteen right-handed patients with migraine without aura, diagnosed by means of IHS criteria [12], were included in the study, retrospectively. A group of eighteen right-handed control group subjects was formed from attendants of the headache outpatient clinic of the Department of Neurology and Neurosurgery and was composed of 18 age-matched subjects whose only health problem was headache due to rhinosinusitis and tension type headache, according to the criteria of the IHS.

The retrospective study was approved by the Local Ethics Committee of Afyon Kocatepe University. According to archive file data, none of the participants was taking medication and all were headache-free for seven days or more at the time of scanning. The clinical evaluation ascertained both the personal and familial history and physical and neurological conditions of the subjects by checking patients' records. Patients who had a lifetime history of neurological illness, migraine with aura, head injury, a history of any chronic medication use, substance or alcohol abuse, epilepsy, schizophrenia, bipolar disorder, major medical illnesses (including cardiac disease and diabetes) were excluded from the study. All studies were performed with a 1.5-T MR machine (Philips Medical Systems, Netherlands).

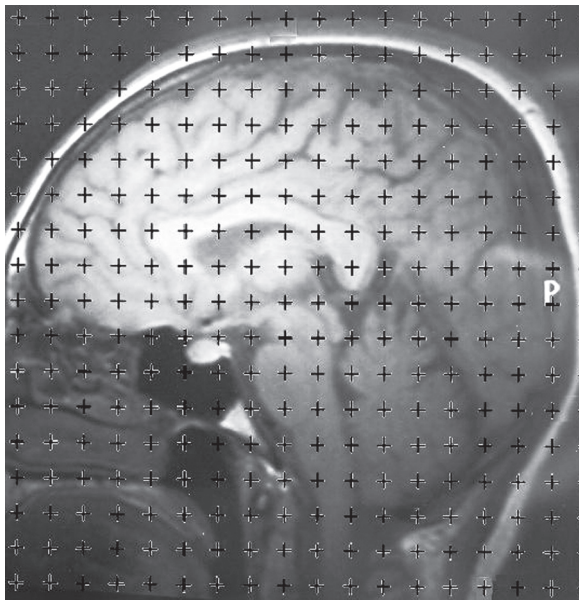
### Stereological analysis

Total cerebellar and hemispheric volumes computed from each image were measured three times by three observers using a stereological method. All measurements were performed blinded to subject details and results of any other measurements. An optimal plan was taken as the smallest diameter of anisotropic structures that can be measured in volumetric analysis of sagittal and axial cranial MRI sections. Original MRIs were exported as tiff image files, which were further subjected to stereological analysis with the aid of Image-J software. A uniform point-grid with a point-associated area of 0.625 cm<sup>2</sup> was randomly superimposed on each MRI using the "Grid" plug-in installed with Image-J. Points hitting the cerebella were manually counted for volume estimation. Hemispheric volumes were also estimated using the Cavalieri's principle of stereological methods as described in previous studies [1, 3, 9]. Volume estimation was accomplished according to previously defined Cavalieri's principle [1, 8, 15] by utilising the formula given below:

$$V = t \times [(SU) \times d/SL]^2 \times \sum P$$

$$V = t \times [(SU) \times d/SL]^2 \times \sum P$$

where, *t* is the section thickness, *SU* is the scale unit (the real length of the scale marked on the MRIs), *d* is the distance between two points in the point grid, *SL* is the scale length (the actual measure of the scale on MRIs), and *P* is the number of points counted. All data have been entered into a previously-prepared Microsoft excel spreadsheet for automatic calculation of the outcomes of the above for-



**Figure 1.** A sagittal magnetic resonance scan with a superimposed point-counting grid for the estimation of volume.

mula and the statistical evaluation parameters including the nugget variance and the coefficient of error (CE).

In order to evaluate hemispheric asymmetry between cerebellar hemispheres, middle sagittal sections were identified by clear visualisation of the cerebral aqueduct. The point counts belonging to the middle section were divided in two and the results were added to total point counts for each hemisphere separately, and thus, a volume value for each cerebellar hemisphere was estimated. The stereological point counting method is demonstrated in Figure 1. Statistical analyses were made afterwards and the results were standardised to generate a normalised database.

**Statistical analysis**

Distributions of the variables were analysed by Shapiro-Wilk normality test. Homogeneity of the groups’ variances was controlled by Levene’s test. Group’s variances were not homogeneous, so parametric test assumptions were not satisfied, and differences between left and right cerebellum volume means of control and vertigo groups according to sex were analysed by Wilcoxon sign test and Mann Whitney U test. Results have been expressed as number of observations (n), mean standard deviation (SD), and median. A p value less than 0.05 was considered as statistically significant. All statistical analyses were performed with SPSS software (Statistical Package for the Social Sciences, version 17.0, SSPS Inc, Chicago, IL, USA).

**RESULTS**

According to the statistical analysis, there were no significant differences among the subjects with respect to age (mean age of migraine subjects:  $46.26 \pm 16.18$  years; control subjects:  $44.00 \pm 16.59$  years,  $p = 0.677$ ). In the migraine and control groups there were no significant differences between the volumes of left and right hemispheres of males ( $p = 0.499$ ,  $p = 0.208$ , respectively) and females ( $p = 0.530$ ,  $p = 0.799$ , respectively). When comparing migraine and control groups, cerebellar hemispheric volumes revealed that there were no statistically significant differences between left hemispheres ( $p = 0.562$ ) and right hemispheres ( $p = 0.132$ ) for males and there were no statistically significant difference between left hemispheres ( $p = 0.510$ ) and right hemispheres ( $p = 0.692$ ) for females. Mean values for hemispheres of cerebellum volume calculated according to stereological point counting method are listed in Table 1.

**Table 1.** Mean volume values (cm<sup>3</sup>) of control and study groups’ cerebellum hemispheres according to gender in migraine without aura

Cerebellum	Control (mean ± SD)		Migrain (mean ± SD)	
	Left hemi cerebellum	Right hemi cerebellum	Left hemi cerebellum	Right hemi cerebellum
Male	N = 8	N = 8	N = 7	N = 7
	$50.995 \pm 4.527$ 51.289	$48.247 \pm 4.734$ 47.105	$53.226 \pm 2.557$ 54.200	$53.226 \pm 2.557$ 54.200
Female	N = 10	N = 10	N = 12	N = 12
	$49.894 \pm 5.984$ 51.651	$49.714 \pm 7.281$ 48.364	$48.754 \pm 4.047$ 49.442	$48.754 \pm 4.047$ 49.442

p < 0.05

## DISCUSSION

Asymmetric and volumetric changes in cerebellar anatomy have been an interesting subject for researchers [3, 19]. However, there is no consensus between authors on the cerebellar asymmetry and volume in healthy individuals [20]. There is only the stereological volumetric study about migraine with aura declared by our study group [25]. Quantitative analysis of MR imaging can improve its diagnostic yield and has the potential to elucidate the aetiology of disease further. However, there is ambiguity and diversity on the definitions of volumetric analysis methods of brain structures in the literature, which are frequently named as "traced", "automatic" (atlas-based), "planimetry", "three-dimensional", etc. Many authors claim that the automatic method is rapid, efficient, and unbiased, and neither subject to the problems of rater drift nor constrained by potentially poor interpreter reliability. However, others noted the traced measurements as "gold standard" against the automatic method [8, 9]. Differing from previous studies, we adopted the stereological measurement technique which was firstly used in evaluation of cerebellar asymmetry by Gocmen-Mas [9]. The stereological technique is simple, reliable, unbiased, and inexpensive, and the adopted point counting approach takes less time as well [8, 20].

During migraine attacks, circulatory changes may take place in the cerebellum [24] and probable predisposition to ischaemia as compared to other regions of the brain was shown in previous studies [14]. Decreased perfusion and cerebellar symptoms, including dysarthria, ataxia, and dizziness, have been described in migraine [6, 18].

Stroke in the posterior circulation has been reported in migraine [14]. The posterior circulation territory, particularly the cerebellum, shows significant increased risk for infarct-like MRI findings compared to the remainder of the nervous system, and in the absence of stroke history the highest risk is in migraine with aura, with at least one attack per month [16, 24]. In the population-based camera study (n = 435), a significantly higher prevalence of white matter hyperintense lesions and cerebellar infarct-like lesions was found in migraine cases, and in total 8.1% of 161 cases with migraine with aura compared with 2.2% of 134 cases with migraine without aura and 0.7% of 140 controls (p = 0.05) had one or more lesion/s in the cerebellar region of the posterior circulation territory of the brain. The percentage of all these lesions in the posterior circula-

tion in migraine with aura, migraine without aura, and controls were 81, 47, and 44%, respectively, and the majority were in vascular border zones [16, 17, 24]. Yilmaz-Kusbeci et al. [25] found no significant differences between the volumes of cerebrum, cerebellum, and the ratio of cerebellum to cerebrum for males (p = 0.05, p = 0.10, and p = 0.64, respectively) and for females (p = 0.18, p = 0.89, and p = 0.24, respectively) in migraine with aura cases. The results suggest that patients with migraine with aura do not have a significant difference in cerebellar and cerebral volumes and cerebellar/cerebral volume ratios compared to the non-migraine group.

Migraine affects cerebellar function [21]. Cerebellar abnormalities (such as cerebellar atrophy, decreased cerebellar blood flow, and cerebellar dysfunction) have also been described in several cases of familial hemiplegic migraine [7, 23]; however, there is no study, to our knowledge, in the literature that evaluates the asymmetrical volume changes by using the stereological technique [9]. In our study, we used the stereological point counting method to evaluate the cerebellar hemispheres of patients, and did not find cerebellar hemispheric asymmetry or atrophy in MWOA patients.

Cavalier's principle of stereological approaches by point counting consists of overlaying each selected section with a regular grid of test points, which is randomly positioned [20]. Cavalier's theorem of systematic sampling in combination with point counting is found to be a reliable, simple, inexpensive, and efficient method for estimating volumes in MR [2].

In this study we evaluated the cerebellar asymmetry and atrophy in migraine patients without aura in comparison to age-matched control subjects. However, we did not find cerebellar asymmetry and atrophy. Obviously, as in all studies, our study also has some limitations, one of the most important of which, to our mind, is the sample sizes of our study and control groups, and we only evaluated MWOA patients. Further studies involving greater numbers of patients and involving migraine with aura and basillar migraine patients would be helpful to extend and support our findings in this study.

## REFERENCES

1. Acer N, Sahin B, Usanmaz M, Tatolu H, Irmak Z (2008) Comparison of point counting and planimetry methods for the assessment of cerebellar volume in human using magnetic resonance imaging: A stereological study. *Surg Radiol Anat*, 30: 335–339.

2. Andreasen NC, Rajarethinam R, Cizadlo T, Arndt S, Swayze VW, Fashman LA, O'Leary DS, Ehrhardt JC, Yuh WT (1996) Automatic atlas-based volume estimation of human brain region from MR images. *J Comput Assist Tomogr*, 20: 98–106.
3. Benegal V, Antony G, Venkatasubramanian G, Jayakumar PN (2007) Gray matter volume abnormalities and externalizing symptoms in subjects at high risk for alcohol dependence. *Addict Biol*, 12: 122–132.
4. Cho AA, Clark JB, Rupert AH (1995) Visually triggered migraine headaches affect spatial orientation and balance in a helicopter pilot. *Aviat Space Environ Med*, 66: 353–358.
5. Cure J, Rothrock J (2007) Prolonged status migrainosus complicated by cerebellar infarction. *Headache*, 47: 1091–1092.
6. Crawford JS, Konkol RJ (1997) Familial hemiplegic migraine with crossed cerebellar diaschisis and unilateral meningeal enhancement. *Headache*, 37: 590–593.
7. Ducros A, Denier C, Joutel A, Cecillon M, Lescoat C, Vahedi K, Darcel F, Vicaut E, Bousser MG, Tournier-Lasserre E (2001) The clinical spectrum of familial hemiplegic migraine associated with mutations in a neuronal calcium channel. *N Engl J Med*, 345: 17–24.
8. Ekinci N, Acer N, Akkaya A, Sankur S, Kabadayi T, Sahin B (2008) Volumetric evaluation of the relations among the cerebrum, cerebellum and brain stem in young subjects: a combination of stereology and magnetic resonance imaging. *Surg Radiol Anat*, 30: 489–494.
9. Gocmen-Mas N, Pelin C, Yazici AC, Zagyapan R, Senan S, Karabekir HS, Sahin B (2009) Stereological evaluation of volumetric asymmetry in healthy human cerebellum. *Surg Radiol Anat*, 31: 177–181.
10. Goadsby PJ (2003) Migraine: diagnosis and management. *Intern Med J*, 33: 436–442.
11. Harno H, Hirvonen T, Kaunisto MA, Aalto H, Levo H, Isotalo E, Somer H, Kallela M, Palotie A, Wessman M, Färkkilä M (2003) Subclinical vestibulocerebellar dysfunction in migraine with and without aura. *Neurology*, 61: 1748–1752.
12. Headache Classification Subcommittee of the International Headache Society (2004) The International Classification of Headache Disorders. *Cephalalgia*, 24: suppl. 1.
13. Ishizaki K, Mori N, Takeshima T, Fukuhara Y, Ijiri T, Kusumi M, Yasui K, Kowa H, Nakashima K (2002) Static stabilometry in patients with migraine and tension-type headache during a headache-free period. *Psychiatry Clin Neurosci*, 56: 85–90.
14. Jayamaha JE, Street MK (1995) Fatal cerebellar infarction in a migraine sufferer whilst receiving sumatriptan. *Intensive Care Med*, 21: 82–83.
15. Kalkan E, Cander B, Gul M, Karabagli H, Girisgin S, Sahin B (2007) Prediction of prognosis in patients with epidural hematoma by a new stereological method. *Tohoku J Exp Med*, 211: 235–242.
16. Kruit MC, van Buchem MA, Hofman PA, Bakkers JT, Terwindt GM, Ferrari MD, Launer LJ (2004) Migraine as a risk factor for subclinical brain lesions. *JAMA*, 291: 427–434.
17. Kruit MC, Launer LJ, Ferrari MD, van Buchem MA (2005) Infarcts in the posterior circulation territory in migraine. The population-based MRI CAMERA study. *Brain*, 128: 2068–2077.
18. Lee TG, Solomon GD, Kunkel RS, Raja S (1996) Reversible cerebellar perfusion in familial hemiplegic migraine. *Lancet*, 348: 83.
19. Robins JB, Mason GC, Watters J, Martinez D (1998) Case report: cerebellar hemi-hypoplasia. *Prenat Diagn*, 18: 173–177.
20. Roberts N, Puddephat, MJ, McNulty V (2000) The benefit of stereology for quantitative radiology. *Br J Radiol*, 73: 679–697.
21. Sandor PS, Mascia A, Seidel L, de Pasqua V, Schoenen J (2001) Subclinical cerebellar impairment in the common types of migraine: A three-dimensional analysis of reaching movements. *Ann Neurol*, 49: 668–672.
22. Scheid R, Voltz R, Briest S, Kluge R, von Cramon DY (2006) Clinical insights into paraneoplastic cerebellar degeneration. *J Neurol Neurosurg Psychiatry*, 77: 529–530.
23. Takahashi T, Arai N, Shimamura M, Suzuki Y, Yamashita S, Iwamoto H, Inayama Y, Kameda Y, Kuroiwa Y (2005) Autopsy case of acute encephalopathy linked to familial hemiplegic migraine with cerebellar atrophy and mental retardation. *Neuropathology*, 25: 228–234.
24. Vincent M, Hadjikhani N (2007) The cerebellum and migraine. *Headache*, 47: 820–833.
25. Yilmaz-Kusbeci O, Gocmen-Mas N, Yucel A, Karabekir HS, Ertekin T, Yazici AC (2010) Evaluation of cerebellar and cerebral volume in migraine with aura: a stereological study. *Cerebellum*, 9: 345–351.