

The role of longitudinal shortening in the general pattern of heart left ventricle contraction

Tomasz Gorycki, Barbara Bobek-Billewicz, Rafal Galazka, Maciej Hermann

Department of Radiology, Institute of Radiology and Radiotherapy, Medical University of Gdansk, Gdansk, Poland

[Received 26 November 1999; Revised 3 January 2000; Accepted 4 January 2000]

This paper constitutes a report of our experience in the assessment of left ventricle contraction using MRI (Philips 0,5T Gyroscan T5/II) and includes a suggestion of the study method directed towards establishing the role of different patterns of ventricle contraction in general ventricle function. In 29 patients, 22 men and 7 women, (average age 55.3) with history of myocardial infarction, electrocardiographically gated MR images encompassing the entire heart in the anatomic long and short axis planes were acquired. Significant positive correlations between long axis shortening and area length ejection fraction were found on four chamber view images: $r = 0.605$ at $p < 0.05$ and on two chamber view images: $r = 0.554$ at $p < 0.05$.

key words: MR studies, myocardium, function

INTRODUCTION

The contraction of the heart left ventricle relies on a combination of wall thickening, circumferential shortening and decreasing of long axis diameter i.e longitudinal shortening. The reduction of left ventricular cavity volume treated as the difference between end diastolic and end systolic volumes is based on both the inward motion of the myocardial wall and longitudinal shortening. Previous studies have shown that the mechanism of inward motion is much more complex than only pure contraction of circumferentially oriented fibres and that it is mostly based on myocardial tethering phenomenon, which relies on interaction between the inner and outer fibre layers having a perpendicular fibre orientation [2,3,11]. This is possible because of specific fibre orientation in the myocardium being spread with fibre angle varying from the endo- to the epi-cardial surface almost by 100° [2,3,12]. The above-mentioned morphologic and physiologic

points cause different segments and sub-segments of the myocardial wall to show shear motions. These shear motions within the myocardium were analysed, first using surgical methods to imbed the radiopaque markers into myocardium, nowadays they are analysed using MR tissue tagging [1,2,11,12,14]. They revealed that ventricular torsion or twisting is caused by systolic contraction of obliquely oriented, left handed, subepicardial fibres and that it seems to act as a mechanism improving general contraction within the myocardium. From this point of view, long axis shortening could be treated as a marker corresponding with ventricle torsion and efficacy of fibre contraction. Beside the complex pattern of myocardial fibres contraction, which causes decreasing of long axis diameter, it is still unclear how strong an influence longitudinal shortening has on left ventricle function and if there is any correlation between longitudinal shortening and short axis contraction [11,12,14].

The use of such a multimodality method as magnetic resonance imaging (MRI) in obtaining cardiac images follows contemporary trends to make the diagnosis in as non-invasive way as possible. In order to optimise the display of cardiac anatomy there is a need to use images oriented along true cardiac axes. At present the complete cardiac examination intended for analysis of left ventricle anatomy and function ought to include: the long axis view parallel to the interventricular septum (two chamber view); long axis view perpendicular to the interventricular septum (four chamber view); and short axis view obtained at multiple levels (outflow, papillary muscles, apex) [4–6,10,14]. Ventricle function has been analysed since the introduction of multi-phase techniques: called single-slice multi-phase technique (SSMP) and multi-slice multi-phase technique (MSMP), which enabled the obtaining of images of one slice or many different slices throughout the cardiac cycle from end diastole to end systole. Substantial reduction of acquisition time was possible thanks to introducing fast spin echo or turbo spin echo imaging (TSE) and echo planar imaging (EPI) techniques [2,3,9,11,13].

MATERIALS AND METHODS

In our study 29 patients (22 men and 7 women; average age — 55.3 years) were examined on Philips 0.5T Gyroscan T5/II, having been directed to the MR examination after echocardiography disclosing serious left ventricle failure in the course of ischaemic disease with history of myocardial infarction involving inferior wall in 11 cases, anteroseptal wall in 18 cases and apical region in 12 cases. In all of them electrocardiographically gated MR images en-

compassing the entire heart were acquired in the anatomic long and short axis planes including: left ventricle outflow tract with SSMP technique (CINE 2D FFE TR750, TE 6.9, FA 40, slice 6 mm), two chamber view with SSMP technique (CINE 2D FFE TR 20, TE 6.9, FA 40, slice 8 mm), short axis view with MSMP technique (CINE MS FE TR 750, TE 6.9, FA3 0, slice 10 mm), four chamber view with SSMP technique (CINE 2D FFE TR 759, TE 6.9, slice 8 mm). Images subjected to analysis represented end diastolic and end systolic phases from two chamber and four chamber views applied using SSMP technique and from short axis views at the basal and mid papillar levels applied using MSMP technique. Every one of the above-mentioned images was analysed with area length ejection fraction scheme (ALEF).

Relationships between 6 variables (percentage shortening of left ventricle long axis from end diastole to end systole and area length ejection fractions measured on phase images along two chamber and four chamber view planes respectively and short axis area length ejection fractions in mid papillar and basal regions) were analysed with linear correlation coefficient „r” after nonlinear correlations were excluded. The test of significance of a correlation coefficient „r” included the size of the sample from which it was computed as well as the distribution histogram.

RESULTS

Shortening of long axis ranged from 1.71 to 34.45%, mean 16.97% on four chamber views and from 2.90 to 28.07%, mean 15.67% on two chamber views. ALEFs ranged from 7.29 to 67.65%, mean 46.97% on four chamber views and from 24.51 to

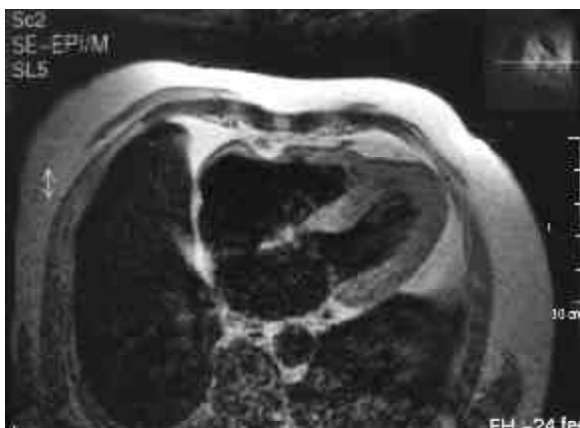

Figure 1. Axial view plane. False thickening of left ventricle myocardial wall because of the partial volume effect

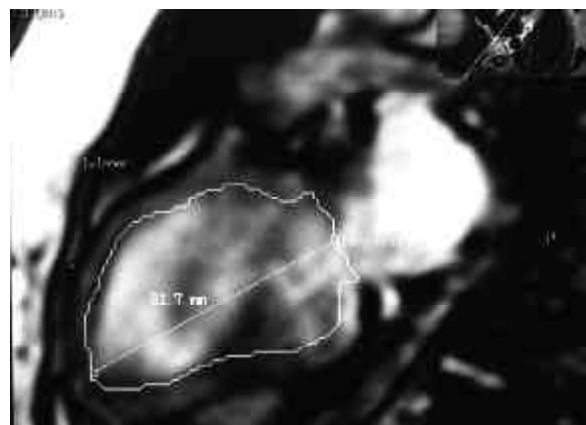


Figure 2. Two chamber view plane. End diastole phase. Left ventricle inner myocardial borderline and long axis are marked

75.85%, mean 44.35% on two chamber views. For short axis images ALEF scores ranged from 21.88 to 84.99%, mean 48.35% at mid papillar level and from 15.01 to 67.19%, mean 51.70% at basal level.

We found quite strong correlations between long axis shortening and ALEF when measured on four chamber view images: $r=0.605$ at $p<0.05$ and a little less strong when measured on two chamber view images: $r=0.554$ at $p<0.05$. As we suspected inversely proportional correlations between long axis shortening and short axis contraction were marked on two chamber view images: $r=-0.379$ for mid papillar region and $r=-0.355$ for basal region as well as on four chamber images: $r=-0.368$ for mid papillar region and $r=-0.289$ for basal region respectively, but they were not significant at $p<0.05$.

DISCUSSION

The accuracy and reproducibility of left ventricle cine MR examination using images oriented along true cardiac axes have been proved by many authors [1,4–7,10,11,13]. Also the use of geometric models based on measurements calculated from two or three sections over the three-dimensional data set was well established as a standard formula for analysing of left ventricle function [1,4,7,8,10–13]. In the present study, images with non-breath-hold technique were applied, which decreased the influence of breath-holding on venous return known to alter ventricular volumes [3,7,10]. Some physiologic differences in ventricular function depend on such factors as ventricular afterload, hydration state, heart rate and blood pressure but their influence within the period of fast acquisition can be treated as minimal [3,7,11,13]. At the beginning MR studies used im-

age planes orthogonal to the thorax, which were not only oblique to cardiac axes, but also their angle with respect to these axes was variable in different patients because of body habitus and level of diaphragm [4–6,8]. Such images were also strongly compromised by partial volume effects [4–6, 8]. Therefore, measurements taken from orthogonal images could not be directly compared between different patients and with measurements from other techniques [4,6]. Nowadays MR heart examination intended for anatomic and functional analysis has to include sections in planes oriented along cardiac axes [4–6,10,14]. It is also important when there is a need to compare MR and echocardiographic images or when obtaining of reliable echocardiographic sections is difficult. The question if there is any correlation between longitudinal shortening and short axis contraction is still open — we found slight inversely proportional correlation but it was not significant in our group of patients.

Significant correlations between long axis shortening and ALEF were marked on both analysed views with a slight tendency to be increased when measured on four chamber plane images, which was probably associated with marked partial volume effect when the apex was not so reliably identified as on two chamber plane images [1–4,7,10,11]. Probably one can expect more strongly correlated relations between longitudinal shortening and short axis contraction in different groups of diseases — like myocardial infarctions and cardiomyopathies separately and similar to correlations between ventricular wall thickening and volumes found in patients suffering from these diseases when their examinations were assessed with heart strain analysis [1–3,

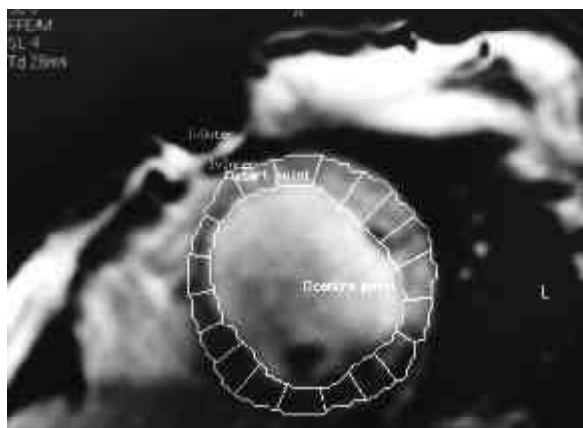


Figure 3. Short axis view plane obtained at papillary level in end diastole phase with inner and outer myocardial borderlines marked within left ventricle

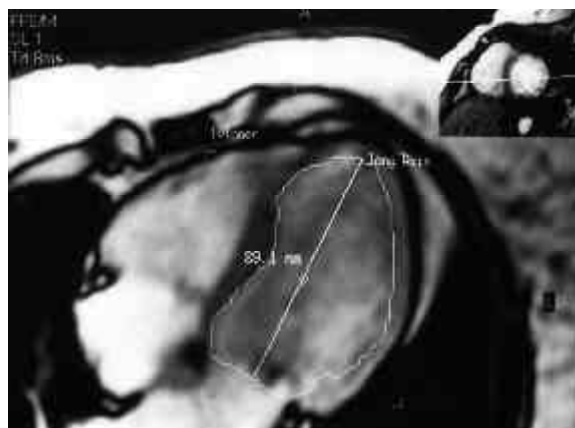


Figure 4. Four-chamber view plane with inner myocardial border line as well as the long axis diameter of the left ventricle

10]. The reason for selecting the two chamber view as a standard plane to measure the long axis shortening is the easy and reliable identification of apex in that plane as well as the fact that two chamber view usually acts as a planscan for short axis slices.

REFERENCES

1. Axel L, Goncalves RC (1992) Regional heart wall motion: Two-dimensional analysis and functional imaging with MR imaging. *Radiology*, 183: 745–750.
2. Beache GM, Wedeen VJ (1995) Intramural Mechanics in Hypertrophic Cardiomyopathy: Functional Mapping with Strain-Rate MR Imaging. *Radiology*, 197: 117–124.
3. Bogaert J (1997) Three-dimensional strain analysis of the human left ventricle. KU, Leuven.
4. Cranney GB, Lotan ChS (1990) Left ventricular volume measurement using cardiac axis nuclear magnetic resonance imaging. *Circulation*, 82: 154–162.
5. Dinsmore RE, Wisner GL (1984) Magnetic resonance imaging of the heart: positioning and gradient angle selection for optimal imaging planes. *AJR*, 143: 1135–1142.
6. Dinsmore RE, Wisner GL (1985) Magnetic resonance imaging of the heart using image planes oriented to cardiac axes. *AJR*, 145: 1177–1183.
7. Dulce MC, Mostbeck GH (1993) Quantification of the left ventricular volumes and function with cine MR imaging: Comparison of geometric models with three-dimensional data. *Radiology*, 188: 371–376.
8. Fisher MR (1985) Multiphasic cardiac magnetic resonance imaging: Normal regional left ventricular wall thickening. *AJR*, 145: 27–30.
9. Higgins ChB, Caputo GR (1993) Role of MR imaging in acquired and congenital cardiovascular disease. *AJR*, 161: 13–22.
10. Pattynama PM, Lamb HJ (1993) Left ventricular measurements with cine and spin echo MR imaging. *Radiology*, 187: 261–268.
11. Sinha S, Mather R, Sintha U, Goldin J, Fonarow G, Yoon H (1997) Estimation of the left ventricular ejection fraction using a novel multiphase, dark-blood, breath-hold MR imaging technique. *AJR*, 169: 101–112.
12. Rogers WJ, Shapiro EP, Weiss JL (1991) Quantification of and correction for left ventricular systolic long axis shortening by magnetic resonance tissue tagging and slice isolation. *Circulation*, 84:721–31.
13. Semelka RC, Tomei E (1990) Normal left ventricular dimensions and function: Interstudy reproducibility of measurements with cine MR imaging. *Radiology*, 174: 763–768.
14. Zerhouni EA, Parish DM (1988) Human heart: Tagging with MR imaging — A method for noninvasive assessment of myocardial motion. *Radiology*, 169: 59–63.