

# The os penis of the frugivorous bat, *Eidolon helvum* (Kerr)

Polycarp U Nwoha, Ademola E Caxton-Martins, Dorothea L Baxter-Grillo

Department of Anatomy and Cell Biology, Obafemi Awolowo University, Ile-Ife, Nigeria

[Received 23 May 2000; Revised 20 June 2000; Accepted 20 June 2000]

*The os penis reported in some species of the mammalian order was observed in the juvenile and adult penes of the frugivorous African bat, Eidolon helvum. The morphology of the os penis in Eidolon helvum differs from that observed in bat species and other mammalian order. In the adult form it is large, disc-shaped and located at the distal segment of the penile organ. The proximal segment of the penis does not contain any bone. In the juvenile bat the os penis is made of two separate bones located longitudinally close to each other at the distal third of the penile tissue. The distal location in both the juvenile and the adult poses a question about the true function of this tissue. The bone may function in Eidolon helvum to support erection of the penis more for micturition than for intromission.*

**key words:** os penis, *Eidolon helvum*, morphology, bat

## INTRODUCTION

The penis is composed mainly of erectile tissue and, when this is distended, the penis serves as an intromittent organ in copulation. The erectile tissue is disposed in three somewhat cylindrical columns: two corpora cavernosa and the corpus spongiosum [6]. Corpora cavernosa form the greater part of the body of the penis and are placed in the dorsolateral part of the organ. Corpus spongiosum terminates in front as an expanded portion, the glans penis, which is demarcated from the main mass of the corpus spongiosum by a well-marked ridge called corona glandis. Corpus spongiosum is traversed throughout its whole extent by the urethra [6]. Erection of the penis is a very necessary prerequisite for the penetration of the vagina. The essential factor in erection is active arteriolar dilatation in the corpora resulting in increasing pressure within the cavernous erectile tissue and obstruction to the venous outflow, so adding to the distention of the erectile tissue [6].

The os penis has been described in few mammals. Williams-Ashman and Reddi [18] stated that it is limited to some eutherian mammalian taxa. In rat it is described as having a distal segment made of cartilage bone and a proximal segment made of membrane bone [1,5,11,12,16,17]. Cunha and Lung [3] and Iguchi et al. [7] have described the presence of os penis and os clitoridis in mice. While the os penis of the male mouse comprised proximal membrane and distal cartilaginous components the os clitoridis of the female comprised only membrane bone. The os penis has also been reported in the American mink and in dog [2,13]. Investigations of a few species of chiroptera have revealed the os penis in the Southeastern Australian little mastiff bat, *Mormopterus planiceps* [8], in the Niger Air Mountain Massif bats *Otonycteris hemprichi* and *Pipistrellus manus* [4]. Os penis is present in some American species of chiroptera but not in the leaf-nosed temperate Southwestern United States bat, *Macrotus waterhousii*, [9]. This means that the bone is not

Address for correspondence: Polycarp Nwoha, Department of Anatomy and Cell Biology, Obafemi Awolowo University Ile-Ife, Nigeria, tel: +036 23 1444, fax: +036 23 1733, e-mail: pnwoha@oauife.edu.ng

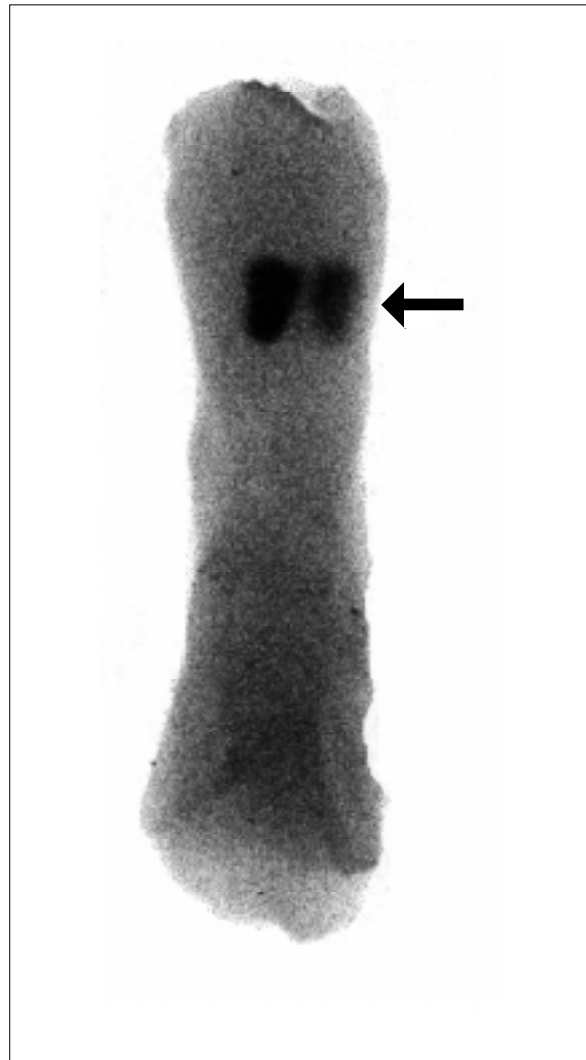
present in all species of bats. Hence, the need to investigate the bone in *Eidolon helvum*, a tropical megachiropteran fruit-eating bat, widely distributed in most parts of Africa, on which no report is yet available. The proximal membranous segment of the os penis is present even at 1<sup>st</sup> day of post-natal life in rat while the distal cartilagenous segment develops later [15]. Rasmussen et al. [14] confirmed that the development of the distal segment is androgen-dependent and develops later in life when androgen expression is adequate for male maturity. This means that the bone may not be present in the young bat. Considering the fact that the os penis is reported to be absent in a male bat species [9] and represented by a single centrally located bone in the adult *Otonycteris hemprichi* and *Pipistrellus manus* [4] there is need to study the morphology of this bone in the juvenile bat. The present study investigated the presence of the os penis in the juvenile and in the adult *Eidolon helvum*.

### MATERIAL AND METHODS

Twenty juvenile and twenty adult male megachiropteran, *Eidolon helvum* weighing approximately 40 g and 180 g respectively, were used in this study. The bats were captured in their roosting colonies on the campus of Obafemi Awolowo University, Ile-Ife, Nigeria and kept in the animal holdings of the Department of Anatomy and Cell Biology, Faculty of Health Sciences, Obafemi Awolowo University, Ile-Ife to recover from their injuries and acclimatise to laboratory conditions. Whilst in the animal holdings they were fed regularly on fruits and provided water *ad libitum*. Each bat was decapitated and the penis carefully dissected out for morphological study using the vital staining of Alizarin red S for calcium (bone) and according to the method of McGee-Russell [10]. Alizarin red S stains newly formed bone tissue.

### RESULTS

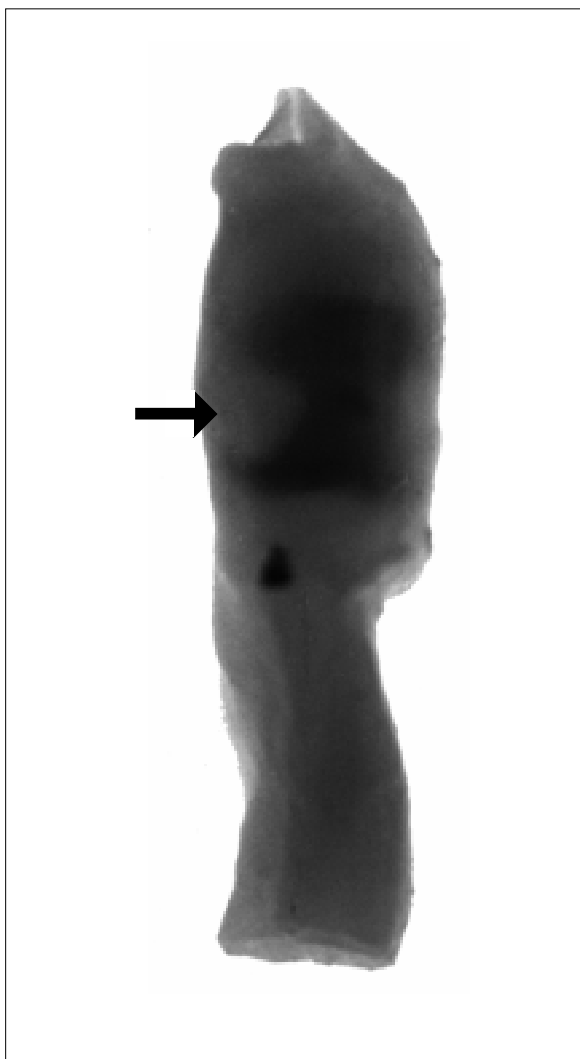
The os penis was stained in the juvenile as well as in the adult *Eidolon helvum*. In the juvenile *Eidolon* the os penis comprised two small bones, paddle-shaped and situated longitudinally in the distal third of the penile organ, close to each other (Fig. 1). The proximal and middle thirds of the penis showed no staining for Alizarin red S. In the adult *Eidolon helvum* the penile organ comprised two parts — a large distal portion and a narrow proximal portion. Alizarin red S stained bone tissue in the proximal segment. The bone is single, large and disc-shaped, occupying almost the entire distal portion. No tissue was stained in the proximal portion (Fig. 2).



**Figure 1.** Photograph of penis of juvenile *Eidolon helvum* (40 g body weight). It shows two pieces of the os penis at the distal third of the tissue (arrow). Staining with Alizarin red S. 1500 x

### DISCUSSION

The presence of the os penis in *Eidolon helvum* suggests that this bone supports the penile organ. This may be necessary to improve the turgidity of this organ during erection. The morphology of the os penis varies in different species of the mammalian order. In rat [15] and in mice [5] it is longitudinal and represented by proximal membranous and distal cartilagenous bones. In mastiff bat Krutzsch and Crichton [8] described it as a single greatly elongated bone. In the *Otonycteris hemprichi* and *Pipistrellus manus* Fairon [4] noted the os penis as single and centrally located in the penis. In the *Eidolon helvum*, reported here, the os penis is single, disc-shaped and distally located. The various morphology and location of the os penis in the adult penile organ suggest that the supporting function may vary



**Figure 2.** Photograph of penis of adult *Eidolon helvum* (180 g). The penis has a larger distal portion and a narrow proximal portion. The os penis is located at the distal portion (arrow). Staining with Alizarin red S. 500 x

from species to species. In some species of the same mammalian order this supporting function may not be necessary. Krutzsch et al. [9] reported that the penile organ of the bat *Macrotus waterhousii* lacked os penis and observed that this was in contrast to other temperate North American bats that had os penis. Perhaps the nature of the erectile tissue differs in the species of bats and so needs to be investigated.

In rat the os penis develops as membrane bone even at day 1 postnatal; the cartilaginous component develops later [15]. In mice the os penis develops as membrane bone proximally at the 5th day postnatal life and cartilaginous bone distally at the 30th day postnatal life [7]. No report of the os penis in the juvenile of chiroptera is available. In the present

work, in the juvenile *Eidolon helvum*, the os penis is paired and distally located in the penile organ. It is not known therefore whether the os penis in the *Eidolon* is a membrane or a cartilage bone. This will require further investigation. The paired bone in the juvenile developed into large single bone in the adult, still maintaining its distal location in the penile tissue and so indicating a similar function in the adult and in the juvenile. This may be to support erection for micturition and not necessarily for intromission.

## REFERENCES

1. Beresford WA, Burkart S (1977) The penile bone and anterior process of the rat in scanning electron microscopy. *J Anat*, 124: 589–597.
2. Bolton LA, Camby D, Boomker J (1996) Aberrant migration of *ancylostoma caninum* to the os penis of a dog. *J S Afr Vet Assoc*, 67: 161–162.
3. Cunha GR, Lung B (1978) The possible influence of temporal factors in androgenic responsiveness of urogenital tissue recombinants from wild-type androgen-sensitive mice. *J Exp Zool*, 205: 181–194.
4. Fairon J (1980) 2<sup>nd</sup> New chiroptera for fauna of the air mountain massif (Niger); *otonycteris hemprichi* and *pippestrellus nanus*. *J Bull Instr Sci Nat Belg Biol*, 52:1–7.
5. Glucksmann A, Cherry CP (1972) The hormonal induction of an os clitoridis in neonatal and adult rat. *J Anat*, 112: 223–231.
6. Hamilton WJ, Boyd D (1976) A textbook of human anatomy. Oxford University Press, UK.
7. Iguchi T, Irisawa S, Uesugi Y, Kusunoki S, Takasugi N (1990) Abnormal development of the os penis in male mice treated neonatally with tamoxifen. *Acta Anat (Basel)*, 139: 201–208.
8. Krutzsch PH, Crichton EG (1987) Reproductive biology of the male mastiff bat, *mormopterus planiceps* (Chiroptera: Molossidae), in Southeast Australia. *Am J Anat*, 178: 352–368.
9. Krutzsch PH, Watson RH, Lox CD (1976) Reproductive biology of the male leaf-nosed bat, *macrotus waterhousii* in southern united states. *Anat Rec*, 184: 611–635.
10. McGee-Russell SM (1958) Histochemical methods for calcium. *J Histochem*, 6: 22–42.
11. Murakami R, Mizuno T (1984) Histogenesis of the os penis and os clitoridis in rats. *Dev Growth Differ*, 26: 419–426.
12. Murakami R, Mizuno T (1986) Proximo-distal sequence of development of the skeletal tissues in the penis of rat and the indicative effect of epithelium. *J Embryol Exp Morphol*, 92: 133–143.
13. Onodera S, Shigehara N, Eto M (1987) Discriminant analysis of the sexual differences of the skeletons in shiba dog (*Canis familiaris*). *Acta Anat Nippon*, 62: 31–32.
14. Rasmussen KK, Vilmann H, Juhl M (1986) Os penis of the rat. V. The distal cartilage process. *Acta Anat (Basel)* 125: 208–212.
15. Vilmann H (1982) Os penis of the rat. lii. Formation and growth of the bone. *Acta Morphol Neerl Scand*, 20: 309–318.

16. Vilmann H (1991) Os penis of the rat. VI. Scanning electron microscopy of the surfaces of the mature bone. *Anat Anz*, 167-172.
17. Vilmann H, Vilmann A (1979) Os penis of the rat. II. Morphology of the mature bone. *Anat Anz*, 146: 483-493.
18. Williams-Ashman HG, Reddi AH (1991) Differentiation of mesenchymal tissues during phallic morphogenesis with emphasis on the os penis: Roles of Androgens and Other Regulatory Agents. *J Steroid Biochem Mol Biol*, 39: 873-881.