

Echocardiographic morphometry of the right chambers of the heart in permanent cardiac pacing

Wojciech Krupa¹, Dariusz Kozłowski¹, Jacek Kubica², Adam Sukiennik²

¹2nd Department of Cardiac Diseases, Institute of Cardiology, Medical University, Gdańsk, Poland

²Department of Cardiology and Internal Medicine, Medical University, Bydgoszcz, Poland

[Received 27 June 2001; Accepted 10 July 2001]

Permanent cardiac pacing is a method of choice in the treatment of specific arrhythmias and conduction disturbances. Clinical studies show that cardiac performance diminished at the site of impulse spreading. It determines local hypertrophy below the position of the pacing lead (early electric activation) with hypertrophic changes in the opposite lying myocardium (late electric activation). It seems that morphological changes, especially research by intravital methods, so relevant in permanent pacing to today's invasive cardiologist, are not understood in full. In connection with this we decided, on the basis on the echocardiographic examination, to evaluate in detail the morphology of the right ventricle and atrium in patients with permanent pacing.

Research was carried out on a group of 124 patients (68 males, 56 females) from 40–93 years of age (avg. 68 ± 14 yrs): 86 patients had implanted pacemakers or AICD (group I), the control group consisted of 38 patients with other cardiac diseases without any pacemaker devices (group II). We measured echocardiographically the following diameters: end-diastolic and systolic diameters of the right ventricle/atrium in short and long axis, diameter of the tricuspid orifice valve and calculated area of the tricuspid orifice based on a special formula. Regarding the morphometric parameters of the right ventricle and right atrium, we confirmed that all diameters of group I were overshooting in correlation to group II. Those differences, such as RVd-short and -long, RVs-long, RVinflow, RA-long and -short, TRId, were statistically significant. Regarding the area of the tricuspid orifice (TRIA), we did not observe any changes in the two examined groups. We concluded that patients with implanted devices have changes in the morphometric parameters of the right ventricle, atrium and orifice, but they do not depend on the duration of pacemaker implantation.

key words: right ventricle, right atrium, tricuspid ring, echocardiography, morphometry, remodelling, pacing

INTRODUCTION

Permanent cardiac pacing is a method of choice in the treatment of specific arrhythmias and conduction disturbances. The newest encompasses implantation not only to the top of the right ventricle's apex,

but also at its outlet and in the area of the membranous septum, where the His bundle is located. Transvenous electrodes are incorporated into the right ventricle by the development of fibrosis around various portions of the lead, resulting in firm attach-

Address for correspondence: Wojciech Krupa, 2nd Department of Cardiac Diseases, Medical University of Gdańsk, ul. Kieturakisa 1, 80–742 Gdańsk, Poland, tel: +48 58 349 39 10, fax: +48 58 301 01 14, e-mail: wkrupa@amedec.amg.gda.pl

ment to the cardiac musculature and other structures. Epstein et al. [2], on the basis of microscopic examinations of a human heart with prior implanted automatic cardioverter-defibrillator (AICD), found that the fibrosis did not spread superficially but deeply. Karpawich et al. [4], on the basis of material consisting of 20 dog hearts, stated that permanent, epicardial right ventricular pacing led to the extension of the right ventricle and tricuspid ring. In literature there are descriptions of the morphological changes in paced hearts, defined as postpacing cardiopathy [5]. The main component of this is the dysfunction and remodelling of the interventricular septum. It was stated on the animal models that the depolarisation wave during the pacing interval spread non-homogeneously [14]. In connection with this, oxygen consumption and the cardiac contractility related to this, i.e. cardiac performance, diminished at the site of the impulse spreading. It determines local hypotrophy below the position of the pacing lead (early electric activation) with hypertrophic changes in the opposite lying myocardium (late electric activation) [15]. It seems that morphological changes, especially research by intravital methods, so relevant in permanent pacing to today's invasive cardiologist, are not understood in full. In connection with this we decided, on the basis of the echocardiographic examination, to evaluate in detail the morphology of the right ventricle and atrium in patients with permanent pacing.

MATERIAL AND METHODS

Research was carried out on a group of 124 patients (68 males, 56 females) from 40-93 years of age (avg. 68 ± 14 yrs). 86 patients had implanted pacemakers or AICD (group I — researched group). Within this group we divided subgroups: IA — with recent implantation i.e. 1.3 ± 2.4 months, IB — with old implantation i.e. 50.7 ± 23.4 months. The control group consisted of 38 patients with other cardiac diseases without any pacemaker devices (group II — control group). In the researched group 32 patients had DDD pacemakers, 25 VVI, 14 VDD and 15 AICD. Indications for implantation were: atrioventricular block (21), sick sinus syndrome (22), chronic atrial fibrillation (25), vasovagal syncope (3) and ventricular fibrillation/tachycardia (15). The time from implantation to the echocardiographic examination was 0.1 months – 208 months (avg. 124 ± 54 months). In order to obtain morphometric parameters of the right ventricle and right atrium we used two-dimensional (2D) echocardiography (Sonos 2000 Hewlett

Packard) in the following echocardiographic views: an apical four-chamber view, a subcostal one and parasternal right ventricular inflow tract view. We measured the following diameters: 1) end-diastolic diameter of the right ventricle in short axis (RVd-short), 2) end-diastolic diameter of the right ventricle in long axis (RVd-long), 3) end-systolic diameter of the right ventricle in long axis (RVs-long), 4) maximal diameter of the right atrium in long axis (RA-long), 5) maximal diameter of the right atrium in short axis (RA-short), 6) end-systolic diameter of the tricuspid annulus (TRId), 7) end-diastolic diameter of the right ventricle inflow tract (RVinflow), 8) area of the tricuspid orifice (TRla) based on the formula:

$$p = \Pi ab$$

p — area of the tricuspid orifice, a — 1/2 of the tricuspid annulus diameter measured from an apical four-chamber view, b — 1/2 of the tricuspid annulus diameter measured from a parasternal right ventricular inflow tract view. Statistical analysis was based on ANOVA calculations. Statistical significance was established when p value < 0.05 .

RESULTS

Regarding the morphometric parameters of the right ventricle and right atrium, using two-dimensional echocardiography, we confirmed that all diameters of the examined research group (group I) were over normal, with the exception of the right ventricle inflow tract. In the control group (group II), only the end-systolic diameter of the right ventricle in long axis (RVs-long) was over normal level (Table 1). The differences, such as RVd-short and -long, RVs-long, RVinflow, RA-long and -short, TRId, were statistically significant. Within the two subgroups (IA and IB) those differences were not significant, but also overshot the normal level, with the exception of RVinflow.

Regarding the area of the tricuspid orifice (TRla) we did not observe any changes in the two examined groups (I and II). However the parameter was significantly higher in the research group in correlation to the control group (2.69 v. 2.31 cm, $p = 0.02$, Tab. 1). It's implicate, that it could be a first step of the post-pacing cardiopathy when the parameter is within normality but differs from the control group.

On the basis of an end-systolic diameter of the tricuspid ring detected from the apical four chamber and parasternal right ventricular inflow tract views, we calculated the area of the tricuspid orifice (TRla) on the basis of the previously mentioned formula ($p = \Pi ab$). On the basis of this calculation we observed that TRla in the group I this diameter was higher

Table 1. Comparison of the right part of the heart parameters between researched and control groups: I — pacing group (IA — with recent implantation, IB — with old implantation), II — control group

	RVd-short	RVd-long	RVs-long	RVinflow	RA-long	RA-short	TRId
Group I	2.91*	7.89*	6.44*	3.35	4.91*	4.05*	2.69
Group II	2.63	7.11	5.66*	2.85	4.37	3.21	2.31
p-value	0.005	0.003	0.0065	0.0023	0.015	0.000002	0.02
Group IA	2.82*	7.98*	6.38*	3.29	4.85*	3.97	2.61
Group IB	3.01*	7.8*	6.51*	3.42	4.97*	4.13*	2.76
p-value	NS	NS	NS	NS	NS	NS	NS

RVd-short — end-diastolic diameter of the right ventricle in short axis; RVd-long — end-diastolic diameter of the right ventricle in long axis; RVs-long — end-systolic diameter of the right ventricle in long axis; RVinflow — end-diastolic diameter of the right ventricle inflow tract; RA-long — maximal diameter of the right atrium in long axis; RA-short — maximal diameter of the right atrium in short axis; TRId — end-systolic diameter of the tricuspid annulus; NS — statistical non significant; *parameters above normal range

than in group II ($5.58 \pm 1.9 \text{ cm}^2$ v. $4.38 \pm 1.77 \text{ cm}^2$). This was statistically significant at p value = 0.03. Within the subdivided group with recent (IA) or old (IB) implantation, the area of the tricuspid orifice was greater as in a whole I group, but the differences between subgroups were not significant (Fig. 1).

DISCUSSION

Implantation of the electrodes to the right ventricle is a commonly used therapeutic procedure in invasive cardiology. Transvenous electrodes are incorporated into the heart using radiological and electrophysiological views [1]. Sometimes, under special circumstances, two-dimensional echocardiography is a method of choice in such a procedure [13]. The most often echocardiography in order to view the course of the electrode in relation to the structures of the right chambers of the heart is used. It is a technique often used to assess the position of the catheter in invasive cardiology, for example: endomyocardial biopsy or electrophysiological study [8, 11].

Special clinical situations are other indications for using this method because it is a more effective procedure than X-ray examination e.g. in aberrantly placed transvenous leads [13] or in pacing in the emergency ward [3]. Pregnancy is the circumstance when it is the only possible control of the localisation of the electrode [8]. Meier et al. [9] stated that by using an echocardiographic examination it was possible to show the lead in 85%. There are differences between morphology and echocardiography in relation to the localisation of the lead. In our previous study it was positioned exactly in the apex in the right ventricle in 84% of cases in comparison with 53% in morphological papers [6, 7]. In the literature concerning cardiac pacing, we have found some papers referring to the morphological changes occurring at the pacemaker lead-valve apparatus interface. Conclusions arising from morphological study seem to find confirmation in echocardiographic data. Paniagua et al. [10], analysing a large number of consecutive echocardiograms, observed that in paced patients the tricuspid regurgitation was both frequent and intensive. We also observed tricuspid regurgitation in a considerable part of the examined patients, in contrast to the population of unpaced patients, but the main point was that all morphometric parameters of the right ventricle and right atrium were greater than in the control group. The same trends were observed within the two subgroups (IA and IB), but they were not significant. In the mentioned paper work the authors did not describe details regarding diameters of the right ventricle and right atrium. Sakai et al. [12], analysing both Doppler echocardiograms and autopsy specimens, revealed a similar prevalence of tricuspid insufficiency but they did not take the point that the prevalence

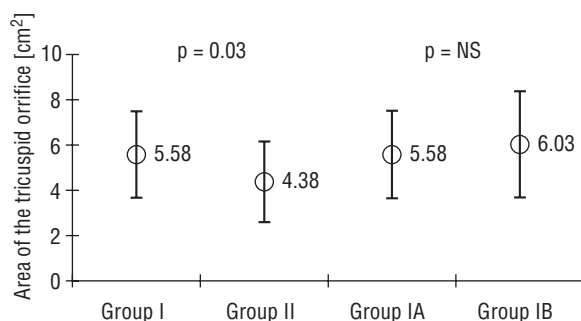


Figure 1. Calculated area of the tricuspid orifice in all examined groups.

of tricuspid regurgitation is connected with age and sex. In contrast, we would like to show any morphological changes that influence tricuspid valve function in comparison with control group. Regarding the area of the tricuspid orifice, we did not observe any changes between examined groups, however the parameter was significantly higher in the research group in correlation to the control group. It's implicate, that it could be a first step of the post-pacing cardiopathy. Additionally, in our patients we did not see changes in the structure of the interventricular septum although more precious conclusions should be obtained using a larger group of patients. In literature we did not find articles about postpacing morphological changes observed using echocardiographic methods, especially in correlation to the pacing mode. It seems that the localisation of the electrode in the interventricular septum may increase the possibility of the development post-pacing cardiopathy. As Krupa et al. [7] observed, the higher occurrence of the location of the lead in DDD/VDD mode versus the VVI may reveal a different mechanism in the remodelling and cardiopathy. On the other hand, we calculated the area of the tricuspid orifice (TRla) based on a special formula and observed that in the pacing group this diameter was higher than in control group, which could implicate the beginning stage of the cardiopathy.

We concluded that patients with implanted devices have changes in the morphometric parameters of the right ventricle, atrium and orifice. The severity of echocardiographic changes is independent of the duration of pacemaker implantation. All changed parameters could influence the development of post-pacing cardiopathy.

ACKNOWLEDGEMENT

This paper was supported by Scientific Grants W-155 and W-734 from the Medical University of Gdańsk.

REFERENCES

1. Brinker J, Midei M, (1996) Techniques of pacemaker implantation. In: Ellenbogen KA (ed.). Cardiac pacing. Blackwell Science, pp. 216–277.
2. Epstein AE, Anderson PG, Kay GN, Dailey SM, Plumb VJ, Shepard RB (1992) Gross and microscopic changes associated with a nonthoracotomy implantable cardioverter defibrillator. *Pacing Clin Electrophysiol*, 15: 382–386.
3. Kaemmerer H, Kochs M, Hombach V (1993) Ultrasound-guided positioning of temporary pacing catheters and pulmonary artery catheters after echogenic marking. *Clin Intensive Care*, 4: 4–7.
4. Karpawich PP, Justice CD, Cavit DL, Chang C-H (1990) Developmental sequelae of fixed-rate ventricular pacing in the immature canine heart: an electrophysiologic, hemodynamic and histopathologic evaluation. *Am Heart J*, 119: 1077–1083.
5. Kozłowski D (1999) Morphology of the atrioventricular junctional area in the aspect of conduction disturbances and reentry phenomenon. *Bold SC, Gdańsk*, 23–50.
6. Kozłowski D, Dubaniewicz A, Koźluk E, Adamowicz A, Grzybiak M, Walczak E, (1997) Possible mechanism of the tricuspid insufficiency in the permanent right ventricular pacing. Morphological study. Proceedings of the 8th European Symposium on Cardiac Pacing, Athens, Greece, Monduzzi Editore.
7. Krupa W, Kozłowski D, Krzywińska-Stasiuk E, Tybura S, Świątecka G (2000) The localization of the electrode in permanently paced heart — an echocardiographical study. *Folia Morphol*, 59: 311–315.
8. Lee MS, Evans SJ, Blumberg S, Bodenheimer MM, Roth SL, (1994) Echocardiographically guided electrophysiologic testing in pregnancy. *J Am Soc Echocardiogr*, 7: 182–186.
9. Meier B, Felner JM, (1982) Two dimensional echocardiographic evaluation of intracardiac transvenous pacemaker leads. *J Clin Ultrasound*, 10: 42–425.
10. Paniagua D, Aldrich HR, Lieberman EH, Lamas GA, Agatston AS (1998) Increased prevalence of significant tricuspid regurgitation in patients with transvenous pacemaker leads. *Am J Cardiol*, 82: 1130–1132.
11. Pierard L, El Allaf D, D'Orio V, Demoulin JC, Carlier J (1984) Two-dimensional echocardiographic guiding of endomyocardial biopsy. *Chest*, 85: 759–762.
12. Sakai M, Ohkawa S, Ueda K, Kin H, Watanabe C, Matsushita S, Kuramoto K, Sugiura M, Takahashi T, Takenaka K (1987) Tricuspid regurgitation induced by transvenous right ventricular pacing: echocardiographic and pathological observations. *J Cardiol*, 17: 311–320.
13. Schwartz C, Nicolosi R, Lapinsky R, Grodman R (1986) Use of two dimensional echocardiography in detection of an aberrantly placed transvenous pacing catheter. *Am J Med*, 80: 133–138.
14. Sedmera D, Grobety M, Reymond C, Baehler P, Kucera P, Kappenberger L (1999) Pacing-induced ventricular remodeling in the chick embryonic heart. *Pediatr Res*, 45: 845–852.
15. van Oosterhout MFM, Prinzen FW, Arts T, Schreuder JJ, Vanagt WY, Cleutjens JP, Reneman RS (1998) Asynchronous electrical activation induces asymmetrical hypertrophy of the left ventricular wall. *Circulation*, 98: 588–595.