

Permanent cardiac pacing and its influence on tricuspid valve function

Wojciech Krupa, Dariusz Kozłowski, Paweł Derejko, Grażyna Świątecka

II Department of Cardiology, Medical University of Gdańsk, Gdańsk, Poland

[Received 20 September 2001; Revised 2 October 2001; Accepted 5 October 2001]

Implantation of transvenous devices is a widespread procedure in clinical cardiology. It is well known that the presence of the electrodes in the cardiovascular system can induce fibrosis or fibrous adhesions between them and cause tricuspid regurgitation. Moreover there are suggestions that the placement of the electrode in the tricuspid orifice may also play a role in the development of tricuspid insufficiency because of the thickening of reactive leaflets and the impairment of their mobility in morphological studies. There are no papers regarding the topography of the electrode in the right ventricle judged by means of transthoracic echocardiography. Moreover in literature we did not meet reports comparing the localisation of the lead on the tricuspid valve function. Therefore we decided to describe the detailed topographic relations between the lead and the structures of the right ventricle in a larger population and we compared the influence of the lead location for tricuspid valve function. Research was carried out on a group of 86 patients (52 M, 34 F), with a mean age of 64.7 ± 14.9 years with permanent cardiac pacemaker or implantable cardioverter-defibrillator (ICD). On the basis of echocardiograms performed we assessed the position of the lead regarding the tricuspid valve leaflets or commissure, and judged the course of the lead beneath the tricuspid valve level. Moreover special attention was focused on the placement of the tip of the electrode. We qualified its position into three categories: apex of the right ventricle, right ventricle outflow tract, and "para-apex" position. The degree of the tricuspid valve insufficiency was assessed by means of semiquantitative method based on the Color-flow Doppler echocardiography. We measured the extension and the area of the tricuspid regurgitant jet using four-gradual scale. We compared the topography of the lead at the level of the valve with its function by means of the presence and degree of its regurgitation. We stated that in 35% of cases the pacing lead was located at the level of the anterior leaflet of the tricuspid valve, in 23% at the level of the septal leaflet and in 12% at the posterior one. Besides in 10% the electrode was placed between the leaflets just over the commissures. On the other hand in the remaining 20% the lead was positioned centrally in the right atrioventricular orifice without adherence to any leaflet. Next we assessed the course of the lead beneath the tricuspid valve level and stated that most frequently (45%) it run just across the centre of the right ventricle, and in other cases was lying along the interventricular septum (in 39% of cases) or along the anterior wall of the right ventricle

(in 16%). The tip of the lead was positioned exactly in the apex of the right ventricle in 74%, in the right ventricular outflow tract in 9% and in 17% its position was "para-apical".

We did not see any statistically significant differences between the presence and intensification of valve regurgitation and topography of the lead.

We concluded that at the level of the tricuspid valve the lead was positioned in the anteroapical part of tricuspid annulus and the proper apical position of the electrode's tip occurred in approximately 75% of cases. Localisation of the electrode at the level of the tricuspid orifice does not influence its insufficiency as detected by Doppler echocardiography.

key words: tricuspid valve, tricuspid regurgitation, echocardiography, pacing, lead's topography

INTRODUCTION

Implantation of transvenous devices (pacemakers, automatic cardioverters-defibrillators) is a widespread procedure in clinical cardiology. The most important criteria applied to proper lead's localisation are electrophysiological recordings and fluoroscopy. In literature echocardiography was used to localise the placement of the lead in many different clinical situations, e.g. in pregnancy [8] or in patients in intensive care wards [7]. On the other hand the good possibility of monitoring the course of the lead in transesophageal echocardiography was utilised during procedures of extraction of the leads [1, 2, 20].

It is well known that the presence of electrodes in the cardiovascular system can induce fibrosis or fibrous adhesions between them [4, 6, 23]. This reaction can refer to every part of the heart's structure but the most frequent include the tip of the lead and the tricuspid valve apparatus [5]. It was suggested that, among other factors, the thickening of the valve's leaflets (as a manifestation of fibrosis) may impair the tricuspid valve function [9].

In morphological study Kozłowski et al. [10] described the localisation of the permanent pacemaker lead in the right ventricle. The authors suggested that the placement of the electrode in the tricuspid orifice may play a role in the development of tricuspid insufficiency because of the thickening of reactive leaflets and the impairment of their mobility. However, Silver et al. [27] and Wafae et al. [28] suggested that differences in morphology of tricuspid valve leaflets and the chordae tendineae anchored in them may predispose to tricuspid regurgitation in some cases also.

In literature we met papers which described the presence of tricuspid insufficiency in permanently

paced patients by means of echocardiographic techniques [22, 24] but other publications did not confirm these conclusions [8,26].

However there are no papers regarding the topography of the electrode in the right ventricle judged by means of transthoracic echocardiography. Moreover in literature we did not meet reports comparing the localisation of the lead and the tricuspid valve function. Our previous study in a group of 12 patients referred to the echocardiographic anatomy only (preliminary character of report) [15].

Therefore we decided to describe the detailed topographic relations between the lead and the structures of the right ventricle in a larger population and compared the influence of the lead location on tricuspid valve function.

MATERIALS AND METHODS

Research was carried out on a group of 86 patients (52 M, 34 F), with a mean age of 64.7 ± 14.9 years with permanent cardiac pacemaker or implantable cardioverter-defibrillator (ICD). Indications for device implantation are shown in Figure 1. The most frequent cause of implantation was atrioventricular block (37 patients), the least frequent was trifascicular block (1 patient).

Pacemakers with DDD mode were implanted in 48.2% of patients (sick sinus syndrome, atrioventricular block, vasovagal syncope), VVI mode in 27.7% (atrioventricular block, chronic atrial fibrillation with bradycardia) and VDD mode in 6% (atrioventricular block). In the remaining 18.1% of cases the ICDs were implanted for management of recurrent ventricular tachycardia or fibrillation

In order to obtain the position of the electrode in the right ventricle we used two-dimensional (2-D)

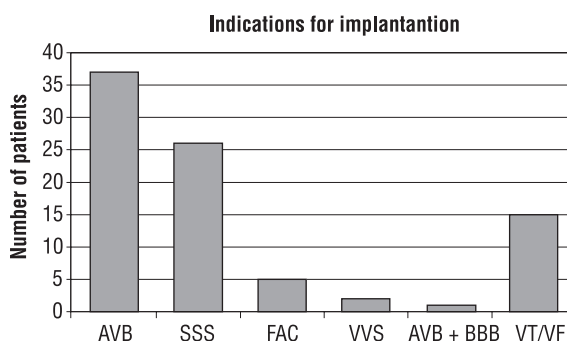


Figure 1. The indications for permanent pacing in group of examined patients; AVB — atrioventricular block, SSS — sick sinus syndrome, FAC — chronic atrial fibrillation with bradycardia, VVS — vasovagal syndrome, AVB+BBB — trifascicular block, VT — ventricular tachycardia, VF — ventricular fibrillation.

echocardiography (Sonos 2000, Hewlett Packard) in the following echocardiographic views: an apical four-chamber view, a subcostal view and a parasternal right ventricular inflow tract view.

On the basis of echocardiograms performed in the above-mentioned views, we assessed the position of the lead regarding the tricuspid valve leaflets or commissure, as we had done in our previous morphological paper [12]. Next we judged the course of the lead beneath the tricuspid valve level. Moreover special attention was focused on the placement of the tip of the electrode. We qualified its position into three categories: apex of the right ventricle, right ventricle outflow tract, and “para-apex” position.

The degree of the tricuspid valve insufficiency was assessed by means of semiquantitative method based on the Color-flow Doppler echocardiography. We measured the extension and the area of the tricuspid regurgitant jet using four-gradual scale for the following values: the extension of jet — I° < 1.5 cm, II° 1.5–3.0 cm, III° 3.0–4.5 cm, IV° > 4.5 cm; the area of jet — I° < 2 cm², II° 2–4 cm², III° 4–10 cm², IV° > 10 cm².

We compared the relation of the topography of the lead at the level of the valve to its function by means of the presence and degree of its regurgitation.

The exclusion criteria from our study were any morphological changes in tricuspid valve apparatus detected during echocardiographic examination, mitral stenosis, aortic stenosis and aortic regurgitation.

Statistical analysis was based on ANOVA calculations. Statistical significance was established when p value < 0.05.

RESULTS

On the basis of the performed echocardiograms we stated that the position of the electrode at the level

Table 1. Characteristics of three patients with a firm electrode’s attachment to the leaflet

Initials	Sex	Age	Leaflet connected with the lead	Time from lead's electroly (months)	Pacing mode
KW	M	63	Posterior leaflet	0.1	VVI
BK	F	73	Anterior leaflet	35	VVI
ZB	F	80	Anterior leaflet	65	VVI

of the tricuspid valve annulus was variable. In 35% of cases (29 patients) the pacing leads were located at the level of the anterior leaflet of the tricuspid valve (Fig. 2), in 23% (19 patients) at the level of the septal leaflet (Fig. 3) and in 12% (10 patients) at the posterior one (Fig. 4). Besides in 9 patients (10%) the electrode was placed between the leaflets just over the commissures — 5 patients over the postero-septal commissure, 2 — anteroposterior commissure and 2 — antero-septal one. On the other hand, in the remaining 17 patients (20%) the lead was positioned centrally in the right atrioventricular orifice without adherence to any leaflet (Fig. 5).

In three patients we observed a firm attachment of the electrode to the leaflet, which caused a distinct mobility of the lead and leaflet together during cardiac cycle. A short characteristic of those cases is shown in Table 1, while echocardiogram is illustrated by Figure 6.

Next we assessed the course of the lead beneath the tricuspid valve level and stated that most frequently (33 patients, 45%) it ran just across the centre of the right ventricle (Fig. 7). In the remaining

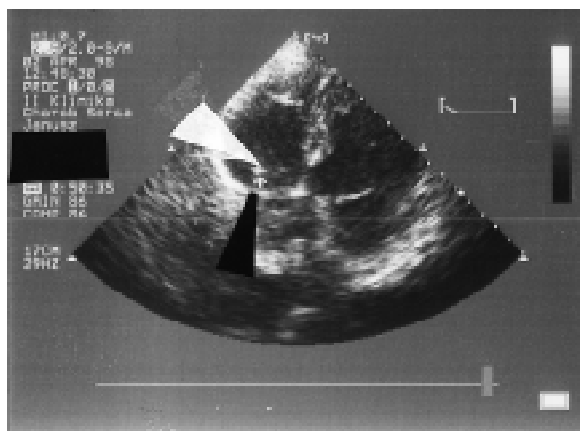


Figure 2. The apical four chamber view; white arrow — electrode, black arrow — the anterior leaflet of tricuspid valve.

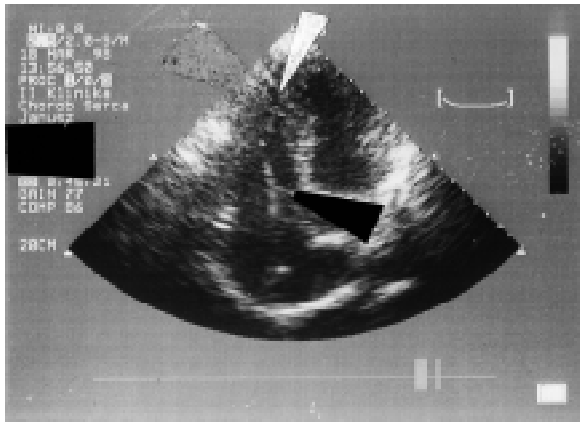


Figure 3. The apical four chamber view (transducer was slightly rotated to better imaging the tricuspid valve); white arrow — the tip of the electrode in the apex of the right ventricle, black arrow — the septal leaflet of tricuspid valve.

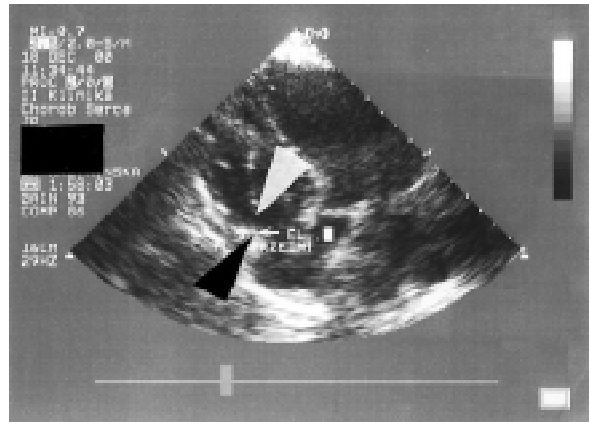


Figure 6. The apical four chamber view. Case of patient with BK initials; white arrow — the lead, black arrow — the anterior tricuspid leaflet.

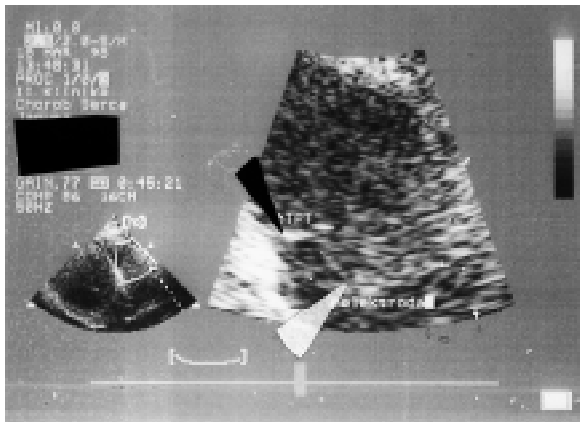


Figure 4. The parasternal right ventricular inflow tract view; white arrow — the lead, black arrow — the posterior leaflet of tricuspid valve.

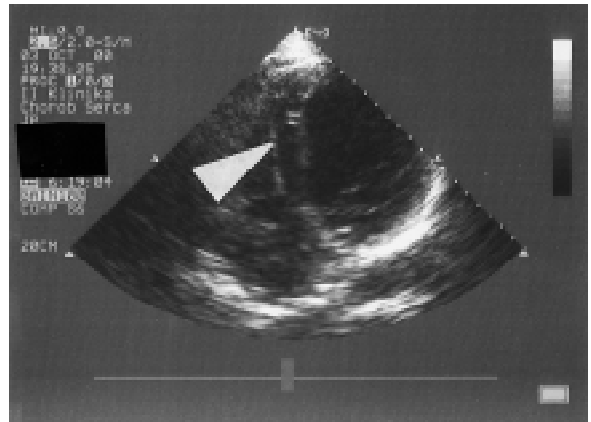


Figure 7. The apical four chamber view; white arrow — the electrode.

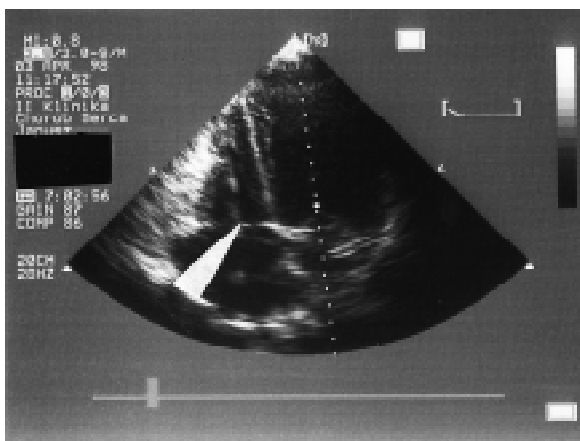


Figure 5. The apical four chamber view; white arrow — the lead which is positioned centrally in the right atrioventricular orifice without adherence to any leaflet.

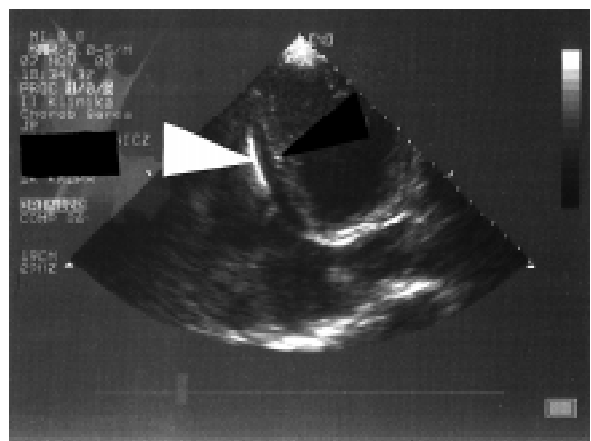


Figure 8. The apical four chamber view; white arrow — the electrode, black arrow — the interventricular septum.

patients the electrode was lying along the interventricular septum in 39% of cases (29 patients, Fig. 8) or along the anterior wall of the right ventricle in 16% (12 patients, Fig. 9).

In a group of patients with central electrode position in the right ventricle its course was different. At the level of the so-called smooth part of the right ventricle that course was homogeneous, but further, at the level of the trabecular part of one, the lead bent in different directions. In 33% (11 patients) it curved toward the interventricular septum (Fig. 3), in 21% (7 patients) toward the anterior wall of the right ventricle (Fig. 10). The invariable course of the lead in this group of patients was observed in 46% (15 patients) of cases.

In 29 patients with septal location of the lead, we stated that the electrode bent to the anterior

wall of the ventricle only in 7% of cases. The course of the lead was unchanged in every patient with anterior location.

On the basis of our observations we stated that during cardiac cycle the electrode demonstrated mobility in the right ventricular cavity only in 5% (4 patients) of examined patients (Fig. 11A, B).

The tip of the lead was positioned exactly in the apex of the right ventricle in 74% (56 patients) of cases (Fig. 3). In the remaining 9% (7 patients) it was implanted to the right ventricular outflow tract (Fig. 12) or in 17% (13 patients) its position was "para-apical". In cases of the latter location we observed that in 85% (11 patients) of cases the tip of the lead was anchored near the apex at the anterior wall of the right ventricle (Fig. 9) or the interventricular septum (Fig. 13).

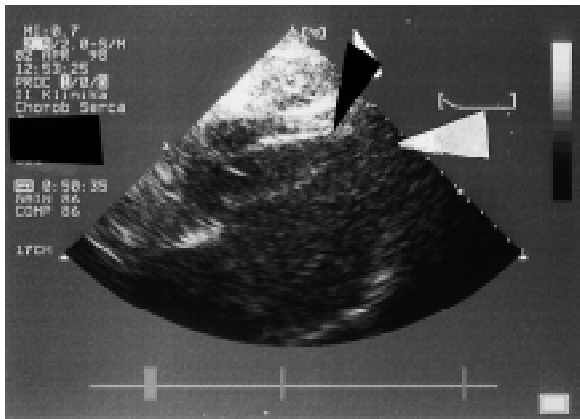


Figure 9. The subcostal view; white arrow — the tip of the electrode in the anterior wall of the right ventricle, black arrow — the apex of the right ventricle.

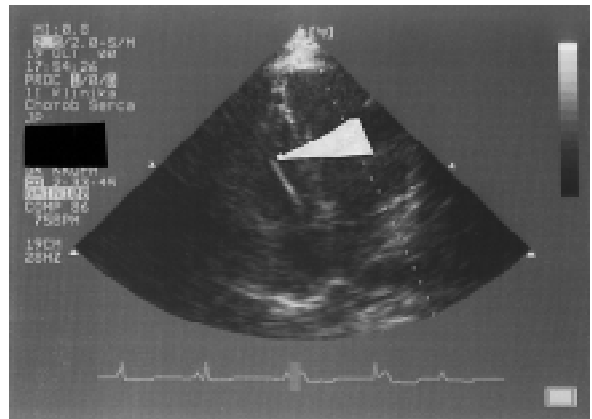


Figure 11A. The apical four chamber view. The lead in the right ventricle — diastole; white arrow — the electrode.

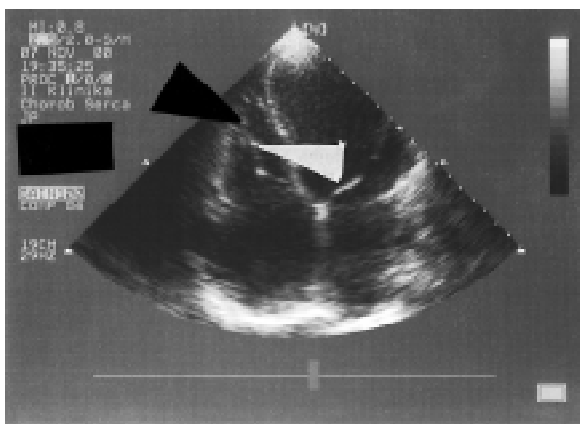


Figure 10. The apical four chamber view; white arrow — the electrode, black arrow — the anterior wall of the right ventricle.

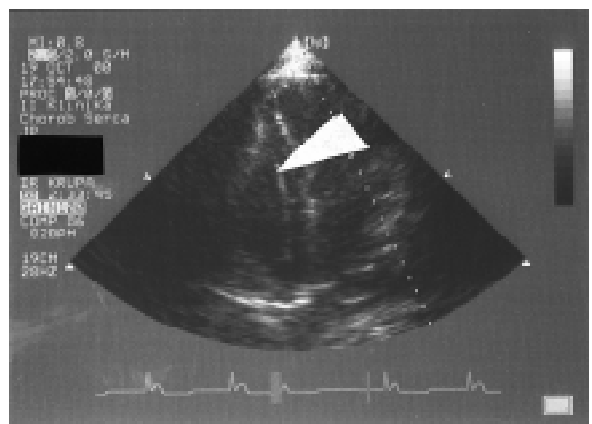


Figure 11B. The apical four chamber view. The lead in the right ventricle — systole; white arrow — the electrode.

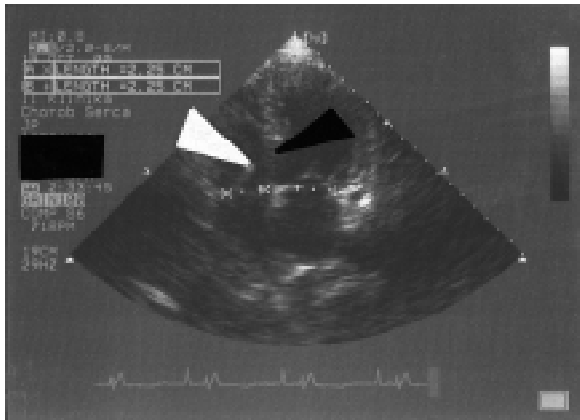


Figure 12. The apical four chamber view. The intended place of implantation is the right ventricular outflow tract; white arrow — the electrode, black arrow — the interventricular septum.

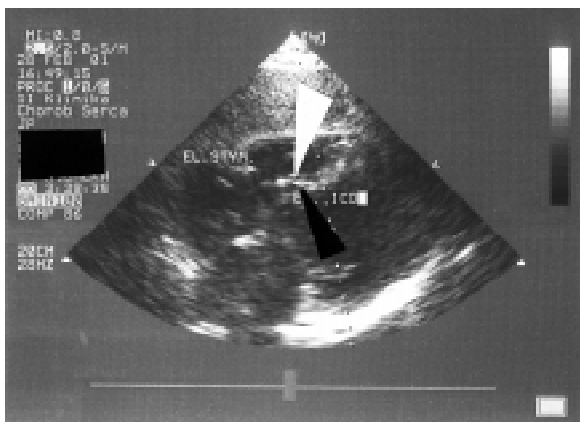


Figure 13. The subcostal view; white arrow — the electrode, black arrow — the interventricular septum.

Based on examination of the presence and degree of intensification of the tricuspid regurgitation by means of Color-flow Doppler echocardiography we assessed the influence of the topography of the lead on valvular regurgitation. We stated presence of tricuspid regurgitant jet in 72.1% (62 patients) of cases. The prevalence of valvular insufficiency according to the electrode localisation at the level of atrio-ventricular orifice was represented as follows: the anterior leaflet — 76% (22 patients) of cases, the posterior one — 90% (9 patients), the septal one — 78% (14 patients), the posteroseptal commissure — 80% (4 patients), the anteroposterior one — 50% (1 patient), central part of the orifice — 45% (12 patients). In the case of the location just over the anteroseptal commissure the tricuspid insufficiency was not detected.

The degree of intensification of the tricuspid regurgitation in relation to the position of the lead at the right atrioventricular valve is shown in Table 2.

We did not see any statistically significant differences between the presence and intensification of valve regurgitation and topography of the lead.

DISCUSSION

The progress in clinical cardiac pacing observed in recent years was started in 1952 by the introduction of the transthoracic ventricle pacing to clinical practice by Zoll et al. [29]. The application of transesophageal, epicardial and finally endocardial cardiac stimulation was a natural consequence of that progress in the next decade. From the late 1960s in literature

Table 2. The incidence and the degree of intensification of tricuspid valve insufficiency according to electrode's localization in the right atrioventricular orifice; TR — tricuspid regurgitation, AL — the anterior leaflet of the tricuspid valve, PL — the posterior leaflet of the tricuspid valve, SL — the septal leaflet of the tricuspid valve, A-S C — the anteroseptal commissure, P-S C — the posteroseptal commissure, A-P C — the anteroposterior commissure

Degree of tricuspid regurgitation	AL	PL	SL	A-S C	P-S C	A-P C	Centrum	p
TR (-)	n=8 27,6%	n=1 10%	n=4 22,2%	0	n=1 25%	n=1 50%	n=4 25%	p=NS
TR I	n=10 34,5%	n=3 30%	n=4 22,2%	0	0	0	n=4 25%	p=NS
TR II	n=8 27,6%	n=4 40%	n=7 38,9%	0	n=1 25%	n=1 50%	n=6 37,5%	p=NS
TR III	n=1 3,4%	n=1 10%	n=2 11,1%	0	n=3 75%	0	n=1 6,25%	p=NS
TR IV	n=2 6,9%	n=1 10%	n=1 5,6%	0	0	0	n=1 6,25%	p=NS
Entire of TR	n=21 72%	n=9 90%	n=14 78%	0	n=4 80%	n=1 50%	n=12 75%	p=NS

there have been met papers from autopsy studies about morphological changes in paced hearts. One of the main described abnormalities was fibrous adhesions between the lead and the endocardium, which could induce some complications and adverse effects, such as the development of a thrombus matched to the electrode or exit block [17, 23]. Huang and Baba [6] described in autopsy fibrous attachments between the lead and tricuspid leaflets in patient with previous auscultated heart murmur typical of tricuspid regurgitation. However the authors of the above-mentioned publications did not describe proofs of significantly impaired function of tricuspid valve.

In contrast Kozłowski et al. [9, 10] stated that in approximately 2/3 of examined hearts these fibrous adhesions caused reactive thickening of tricuspid leaflets and immobilised them. It seems that difficulties in leaflet mobility may impair valve function; however, this conclusion is based on morphological studies only.

In the light of the development of those morphological changes it is important to judge the influence of them on the position of the lead in the right ventricle and on tricuspid valve function. In literature we did not meet papers regarding to echocardiographic detection of the electrode position.

We observed the differences between topography analysed by means of morphology and echocardiography. In the present report at the level of the tricuspid valve annulus most frequently the lead was positioned in the anteroseptal part of the annulus. In contrast to our previous anatomical report, the posterior location was the most prevalent [12]. Moreover, in 20% of cases we observed the lead centrally placed in the tricuspid orifice, which was not stated in morphology. That latter localisation was probably a result of intravital character of echocardiography, with the exception of 3 cases where electrodes were firmly attached with leaflets and moved together with them.

In the right ventricular cavity, the course of the lead included the central part of the right ventricle and interventricular septum in approximately 85% of cases, which is concordant with morphological reports in most cases.

The proper apical location of the tip of the lead was observed in 74% of examined patients in comparison to approximately 50% in anatomical papers. In the instances of the "para-apical" position of the tip of the lead, its location was not concordant with anatomical research — location in the anterior rath-

er than the posterior wall of the right ventricle was predominant in ultrasonic imaging. In the latter case we think that anatomical topography is more precise than echocardiographic, due to the two-dimensional character of the ECHO examination.

The above-mentioned differences between morphology and ultrasonography in relation to the lead's position in the right ventricle may be connected to several factors. Among them, the number of examined patients may play an important role. In our casuistic echocardiographic report, the localisation of the lead was positioned in the posterior part of the tricuspid annulus [13]. In further publications we stated the anterior lead's localisation at the level of the tricuspid valve [15, 16]. In the present report we include the largest numbers of patients whose localisation was assessed as anteroseptal. Other factors which may influence those differences are changes of the electrode's topography during preparation or fixation at autopsy. However on the other hand fibrosis may fix the lead and the endocardium and prevent the dislocation. It should be remembered that the two-dimensional character of ECHO may make precise interpretation of the lead topography difficult.

Other researchers utilised transthoracic echocardiography to detect the position of the lead but rather in the light of assessment of the proper lead's location than topographic analysis. Pierard et al. [21] described endomyocardial biopsies guided echocardiographically. Next Schwartz et al. [25] demonstrated the usefulness of two-dimensional echocardiography in the recognition of the pacemaker lead's dislocation. Meier et al. [19] judged the possibility of the detection of the lead's topography by means of ECHO as 85% of cases, in comparison with 100% regarding fluoroscopy.

In spite of that in literature the best recommended echocardiographic view for imaging the electrode is the subcostal one [3] which we used it along with other views: an apical four-chamber view and a parasternal right ventricular inflow tract view. The adoption of these three echocardiographic views let us image all of the tricuspid valve leaflets and reconstruct the real electrode position

The changes in the electrode's localisation in the right ventricle seem to be very interesting, especially in the light of reports about fibrous adhesions in anatomy. However, we found direct proofs of firm connection between the electrode and the leaflet only in individual cases.

In approximately 25% of cases in the right ventricle the course of the electrode was not homoge-

neous. In cases of central position in the right ventricle the electrode curved toward the interventricular septum. If the lead was positioned near the interventricular septum it curved toward the anterior wall of the right ventricle. Moreover the involvement of the lead within the chordae tendineae observed in morphology [11] may reflect curves of the lead in the right ventricle in echocardiography. However the prevalence of those curves is less than in anatomical observations. It seems that the stability position of the lead in the right ventricle may be equivalent to morphological fibrous adhesions. It is possible that observed single cases of distinct lead's mobility in the right ventricle may implicate the risk factor of dislocation of the electrode. Koźluk et al. [14] assessed the prevalence of the electrode's dislocation on a similar level to ours in cases of lead mobility. These authors published also the risk factors of dislocation, which include operations with cardiopulmonary bypass and organic heart disease with tricuspid regurgitation.

Next we evaluated the influence of the lead position at the level of the tricuspid valve on the presence of tricuspid insufficiency. We did not observe any significant correlation between topography of the lead and tricuspid valve regurgitation. The extension and the area of the regurgitant jet were similar in groups of patients with different localisations of the electrode.

We concluded that transthoracic echocardiography is a good method for the localisation of the ventricular lead position. At the level of the tricuspid valve the lead was positioned in the anteroseptal part of the tricuspid annulus and the proper apical position of the electrode tip occurred in approximately 75% of cases. Localisation of the electrode at the level of the tricuspid orifice does not influence its insufficiency detected by Doppler echocardiography.

ACKNOWLEDGEMENT

This paper was supported by Scientific Grants W-155 and W-734 from the Medical University of Gdańsk.

REFERENCES

- Assayag P, Thuairé C, Benamer H, Sebbach J, Lepout C, Brochet E (1999) Partial rupture of the tricuspid valve after extraction of permanent pacemaker leads: detection by transesophageal echocardiography. *Pacing Clin Electrophysiol*, 22: 971–974.
- Bracke F, Botman CJ, Peels CH, van Gelder LM, Meijer A (1999) Transesophageal echocardiographic evaluation of the tricuspid valve during laser sheath extraction of pacemaker and ICD leads. *Pacing Clin Electrophysiol*, 22: A108.
- Drinkovic N (1983) Subcostal 2D echocardiography in cardiac pacing and intracardiac electrophysiologic studies. *Ultrasound Med Biol, Suppl. 2*: 293–297.
- Epstein AE, Anderson PG, Kay GN, Dailey SM, Plumb VJ, Shepard RB: (1992) Gross and microscopic changes associated with a non thoracotomy implantable cardioverter defibrillator. *Pacing Clin Electrophysiol*, 15: 382–386.
- Furman S, Escher DJW (1968) Retained endocardial pacemaker electrodes. *J Thorac Cardiovasc Surg*, 55: 737–740.
- Huang T-Y, Baba N (1972) Cardiac pathology of transvenous pacemakers. *Am Heart J*, 83: 469–474.
- Kaemmerer H, Kochs M, Hombach V (1993) Ultrasound-guided positioning of temporary pacing catheters and pulmonary artery catheters after echogenic marking. *Clin Intensive Care*, 4: 4–7.
- Kikuchi Y, Shiraishi H, Igarashi H, Yanagisawa M (1996) Insertion of pacing lead via the tricuspid valve does not affect cardiac function and tricuspid valve regurgitation in young dogs. *Acta Paediatr Jpn*, 38: 32–35.
- Koźlukowski D, Dubaniewicz A, Koźluk E, Adamowicz A, Grzybiak M, Walczak E (1997) Possible mechanism of the tricuspid insufficiency in the permanent right ventricular pacing. Morphological study. Proceedings of the 8th European Symposium on Cardiac Pacing. Athens, Greece. Monduzzi Editore, Bologna, 31–35.
- Koźlukowski D, Dubaniewicz A, Koźluk E, Adamowicz A, Grzybiak M, Walczak E, Walczak F, Kosiński A, Woźniak P (1998) The localisation of the electrode in permanently paced heart — a morphological study. *ESS*, 5: 38–44.
- Koźlukowski D, Krupa W, Koźluk E, Dubaniewicz A, Grzybiak M, Adamowicz M, Piwko G, Piszczatowska G, Walczak E, Walczak F (2000) The inflammatory-fibrotic changes of the pacing electrode as a possible mechanism of the tricuspid malfunction. *Folia Cardiol*, 7: 105–110.
- Koźlukowski D, Dubaniewicz A, Koźluk E, Grzybiak M, Krupa W, Kołodziej P, Pazdyga A, Adamowicz-Kornacka M, Walczak E, Walczak F (2000) The morphological conditions of the pacemaker lead extraction. *Folia Morphol*, 59: 25–29.
- Koźlukowski D, Krzywińska-Stasiuk E, Koźluk E, Krupa W, Grzybiak M, Świątecka G (1998) Anatomical and echocardiographic assessment of tricuspid valve insufficiency in permanently paced patients — a preliminary report. *ESS*, 5: 75.
- Koźluk E, Kotliński Z, Łodziński P, Kościelska M, Kubaszek A, Hendzel P, Walczak F, Masiak H, Kępski R, Szufladowicz E, Michalak E, Piątkowska A, Rydlewska-Sadowska W (1999) The clinical characteristics of patients with pacemaker electrode's dislocation — a preliminary report. *Folia Cardiol*, 6 (Suppl. III): 2.
- Krupa W, Koźlukowski D, Krzywińska-Stasiuk E, Tybura S, Świątecka G (2000) The localisation of the electrode in permanently paced heart — an echocardiographical study. *Folia Morphol*, 59: 311–315.

16. Krupa W, Kozłowski D, Krzywińska-Stasiuk E, Tybura S (2000) The localisation of the pacemaker's lead in the right ventricle — an echocardiographic study. 2nd Conference of Clinical Anatomy, Warsaw, Abstracts book, 55.
17. Lagergren H, Dahlgren S, Nordenstam H (1966) Cardiovascular tissue response to intracardiac pacemaking. *Acta Chir Scand*, 132: 696–704.
18. Lee MS, Evans SJ, Blumberg S, Bodenheimer MM, Roth SL (1994) Echocardiographically guided electrophysiologic testing in pregnancy. *J Am Soc Echocardiograph*, 7: 182–186.
19. Meier B, Felner JM (1982) Two-dimensional echocardiographic evaluation of intracardiac transvenous pacemaker leads. *J Clin Ultrasound*, 10: 421–425.
20. Penkala M, Sharma A, O'Neill G, Takeda P, Skadsen A, Vierra E (1999) Transesophageal imaging during laser assisted pacing lead extraction. *Pacing Clin Electrophysiol*, 22: A108.
21. Pierard L, El Allaf D, D'Orio V, Demoulin JC, Carlier J (1984) Two-dimensional echocardiographic guiding of endomyocardial biopsy. *Chest*, 85: 759–762.
22. Postaci N, Eksi K, Bayata S, Yesil M (1995) Effect of number of ventricular leads on right ventricular hemodynamics in patients with permanent pacemaker. *Angiology*, 46: 421–424.
23. Robboy SJ, Harthorne W, Leinbach RC, Sanders CA, Austen WG (1969) Autopsy findings with permanent pervenous pacemakers. *Circulation*, 39: 495–501.
24. Sakai M, Ohkawa S, Ueda K, Kin H, Watanabe C, Matsushita S, Kuramoto K, Sugiura M, Takahashi T, Takenaka K (1987) Tricuspid regurgitation induced by transvenous right ventricular pacing: echocardiographic and pathological observations. *J Cardiol*, 17: 311–320.
25. Schwartz C, Nicolosi R, Lapinsky R, Grodman R (1986) Use of two-dimensional echocardiography in detection of an aberrantly placed transvenous pacing catheter. *Am J Med*, 80: 133–138.
26. Shandling AH, Lehmann KG, Atwood E, Andersh S, Gardin J (1989) Prevalence of catheter-induced valvular regurgitation as determined by Doppler echocardiography. *Am J Cardiol*, 63: 1369–1374.
27. Silver MD, Lam JHC, Ranganathan N (1971) Morphology of the human tricuspid valve. *Circulation*, 41: 333–348.
28. Wafae N, Hayashi H, Gerda LR (1990) Anatomical study of the human tricuspid valve. *Surg Radiol Anat*, 12: 37–41.
29. Zoll PM (1952) Resuscitation of the heart in ventricular standstill by external electric stimulation. *N Engl J Med*, 247: 768–771.