

The arrangement of muscle fibres in the region of the subthebesian fossa in the aspect of atrial flutter

Dariusz Kozłowski^{1, 2}, Adam Owerczuk^{1, 2}, Grzegorz Piwko², Grażyna Piszczatowska², Magdalena Kozłowska², Krzysztof Bigus², Marek Grzybiak²

¹Second Department of Cardiac Diseases, Medical University of Gdańsk, Poland

²Department of Clinical Anatomy, Medical University of Gdańsk, Poland

[Received 15 October 2002; Accepted 28 October 2002]

The typical atrial flutter is the most common supraventricular tachycardia with reentrant circuit. This tachyarrhythmia is based on macroentry wave going around established anatomic landmarks. The reentry in the inferior right atrial wall passes through narrow isthmus, which is the goal for ablative therapy. The isthmus area is bordered anteriorly by the tricuspid valve and posteriorly by the inferior vena cava, coronary sinus, and eustachian ridge. Near to this area we can find anatomical structure, which can be very important during arising, perpetuation and curing of atrial flutter. The concavity, so-called subthebesian fossa [15], is on the way of typical atrial flutters' reentrant circuit.

Regarding the facts mentioned above we decided to examine the morphology and the arrangement of the muscle fibres in this fossa.

Research was conducted on material consisting of 70 human hearts of both sexes from the age of 34 to 72 years. 50 hearts came from patients whose death was not cardiologic in origin. 20 hearts came from humans in whose common atrial flutter was confirmed. We observed the arrangement of muscle fibres in the area of subthebesian fossa. Besides we measured the size and deepness of the subthebesian fossa in both groups of hearts.

We found that regular arrangement of muscle fibres within subthebesian fossa was present in 23 healthy human hearts (46%) and 7 cases (35%) of hearts with atrial flutter. The irregular arrangement of muscle fibres was observed in 27 hearts (54%) of control group and 13 hearts (65%) with dysrhythmia. The thickness of the right atrial wall within the subthebesian fossa was very thin in 8 normal hearts (16%) and in 5 dysrhythmic hearts (25%). The sizes of examined structure were variable in both groups of hearts, and are presented in the table. It seems that the subthebesian concavity can be the substrate for reentrant circuit during atrial flutter, and there could be such special arrangement of muscle fibres, which allows for microreentrant circuit to arise in this area.

key words: typical atrial flutter, macroentry wave, subthebesian fossa

INTRODUCTION

The typical atrial flutter is the most common supraventricular tachycardia with reentrant circuit. In most cases this dysrhythmia occurs in a diseased heart or can be induced by antiarrhythmic drugs. Regarding the source of information about atrial flutter, this dysrhythmia can be divided into type I and type II, typical and atypical, common and uncommon, and clockwise or counterclockwise. However, atrial flutter is the most common reentrant atrial tachycardia [8]. On the basis of current knowledge the terminology can be simplified, because this tachyarrhythmia can be classified on the basis of reentry around established anatomic landmarks [5, 11]. The anterior boundary is the tricuspid annulus [10], and the posterior barriers are the crista terminalis and eustachian ridge [16]. The tachycardia circuit is broad anteriorly and laterally, but it becomes constrained in its course to the right atrium. The area is bordered anteriorly by the tricuspid valve and posteriorly by the inferior vena cava, coronary sinus and eustachian ridge [2]. This narrow isthmus has become a target site for ablative therapy [8], which is the treatment of choice in typical atrial flutter. This procedure is performed by linear lesion in the isthmus mentioned above [12], which allows stopping of the macroreentrant circuit running within the walls of the right atrium.

Near to this area we can find an anatomical structure which can be very important during the arising, perpetuation and curing of atrial flutter. This concavity is located in the neighbourhood of the coronary sinus orifice, tricuspid annulus and vena cava inferior orifice. The concavity, the so-called subthebesian fossa [15], is on the route of typical atrial flutters' reentrant circuit.

This fossa was seen for the first time by Koch [6, 7] at the beginning of the twentieth century, but he did not undertake any research into this structure. The topography of the subthebesian fossa is presented in Figure 1.

In view of the facts mentioned above and the hypothesis that the subthebesian area is a very complex region and an interesting part of the right atrium from the topographical point of view, we decided to examine the morphology and the arrangement of the muscle fibres in this fossa. We think that the subthebesian concavity can be the substrate for reentrant circuit during atrial flutter, and it seems that there is such a special arrangement of muscle fibres, which allows for microreentrant circuit to arise in this area. This could be responsible for slowing of the conduction in subthebesian fossa [19] — this suggestion is based on invasive electrophysiological study. Some authors during active mapping observed critical conduction in this area. This particular area is normally chosen for the ablation procedure

MATERIAL AND METHODS

Research was conducted on material consisting of 70 human hearts of both sexes from the age of 34 to 72 years. Hearts were fixed in a 10% formalin/98% ethanol solution. Only hearts with well-developed subthebesian fossa were chosen for examination. Fifty hearts came from patients whose death was not cardiological in origin and there were no cardiac dysrhythmias according to accessible hospital documentation. This group was indicated as a control group. In these hearts also no pathological changes or congenital disorders were macroscopi-

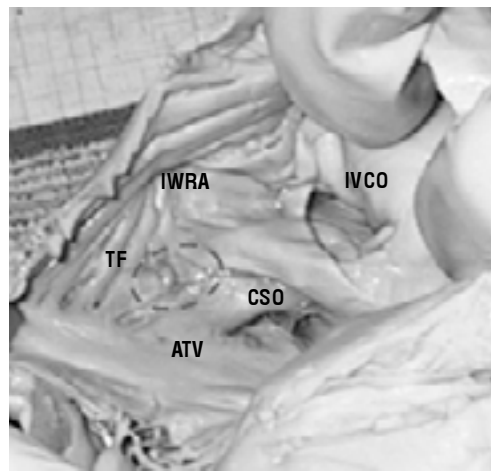
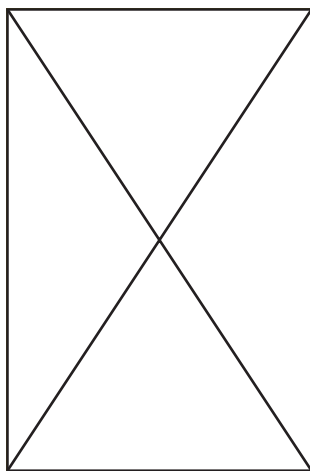


Figure 1. Topography of subthebesian region in relation to the neighbouring structures; IVCO — inferior vena cava orifice, CSO — coronary sinus orifice, ATV — attachment of the tricuspid valve, TF — subthebesian fossa, IWRA — inferior wall of the right atrium, SWRA — septal wall of the right atrium, dotted line represents the border between two atrial walls.

cally found. The remaining 20 hearts came from humans in whom common atrial flutter (with or without atrial fibrillation) was confirmed on the basis of the history and electrocardiograph tracings.

The classic macroscopic methods of anatomical evaluation were used. The inferior and septal walls of the right atria were prepared via a stereoscopic microscope. Due to exact observation, the endocardium in some hearts was eliminated, because of better visualisation of muscle fibres. We observed the arrangement of muscle fibres in the area of the subthebesian fossa. We checked also the thickness of the right atrial wall, because it could have a meaning for the arrangement of muscle fibres. We decided to divide the arrangement of muscle fibres within the subthebesian fossa into two groups: regular and irregular. A regular arrangement was considered when muscle fibres were placed parallel in the whole fossa region, lying longitudinally and rectilinearly. As the irregular group we considered such an arrangement where the muscle fibres were lying chaotically, circuitously or perpendicularly, came one into another, were strangulated and ran in all directions. Our results were documented with a digital camera (Leica), which was helpful in assigning hearts to the regular or irregular group.

We also paid attention if there was regularity between the arrangement of muscle fibres in our groups of hearts and to the sex and age of the hearts.

Besides we decided to check the size and depth of the subthebesian fossa in both groups of hearts

(examined and control). We measured two perpendicular sizes in the inlet plane of the subthebesian fossa, which were going by the middle of this structure (longest size — X, shortest size — Y). We also defined the depth of the fossa. It was the deepest place in the fossa from the inlet plane (depth — Z) (Fig. 2).

Statistic analysis was supported by F-Snedecor and t-Student tests for odd number data. In the situation where distribution was not normal, the differential significance between the two groups was tested using Mann-Whitney-Wilcoxon test. As statistically significant, $p < 0.05$ was considered to be the level of significance.

RESULTS

On the basis of our study we found that a regular arrangement of muscle fibres within the subthebesian fossa was present in 23 healthy human hearts (46%) and 7 cases (35%) of hearts with atrial flutter. As far as an irregular arrangement of muscle fibres was concerned we found that it was present in 27 hearts (54%) of the control group and 13 hearts (65%) with dysrhythmia (Fig. 3, 4).

During examination of the thickness of the inferior wall of the right atrium we found that in some places in the area of the subthebesian fossa muscle tissue was very thin and in some cases it was even pellucid. In normal hearts (control group) thin atrial wall was found in 8 cases (16%), and in hearts with cardiac dysrhythmias it was present in 5 cases (25%) (Fig. 5).

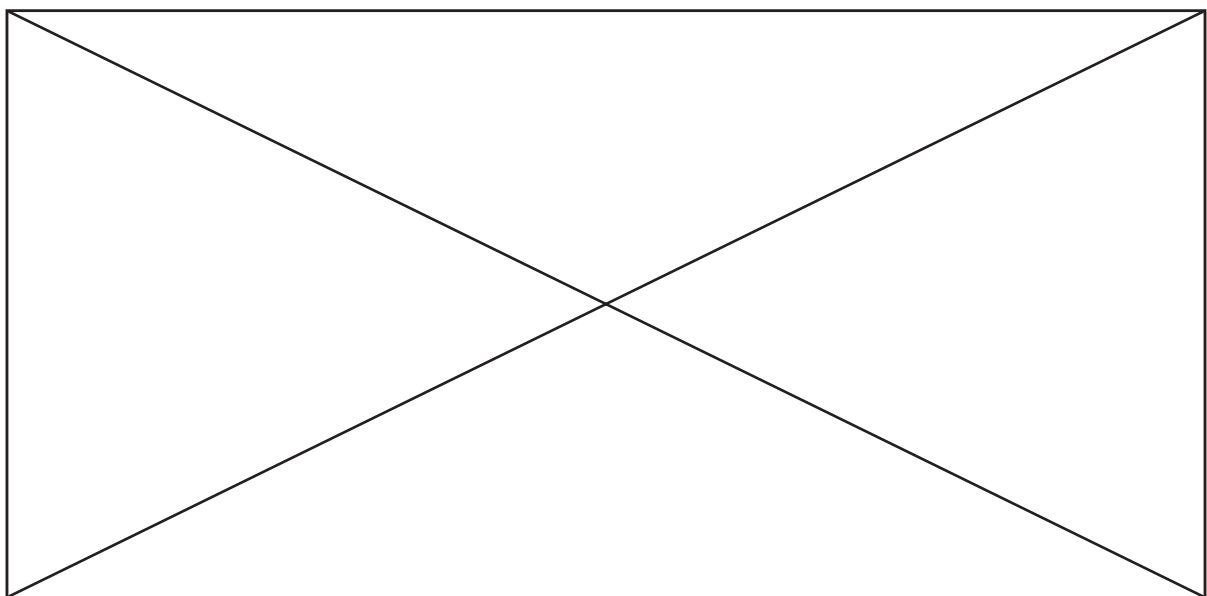


Figure 2. The measured size of subthebesian fossa (draughting scheme).

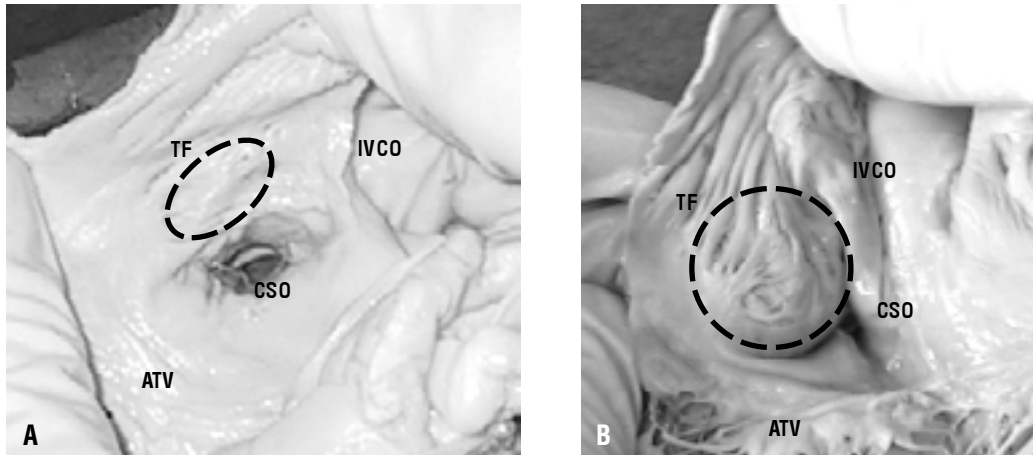


Figure 3. The arrangement of muscle fibres in the subthebesian area (normal hearts). For better visualising subthebesian area was protruded in the opposite direction. **A.** Regular arrangement; **B.** Irregular arrangement; IVCO — inferior vena cava orifice, CSO — coronary sinus orifice, ATV — attachment of the tricuspid valve, TF — subthebesian fossa.

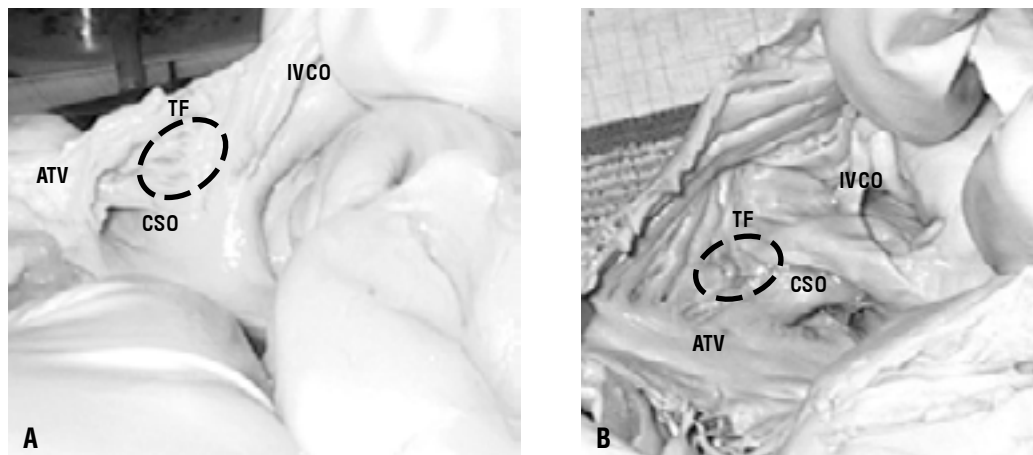


Figure 4. The arrangement of muscle fibres in the subthebesian area (flutter hearts). For better visualising subthebesian area was protruded in the opposite direction. **A.** Regular arrangement; **B.** Irregular arrangement; IVCO — inferior vena cava orifice, CSO — coronary sinus orifice, ATV — attachment of the tricuspid valve, TF — subthebesian fossa.

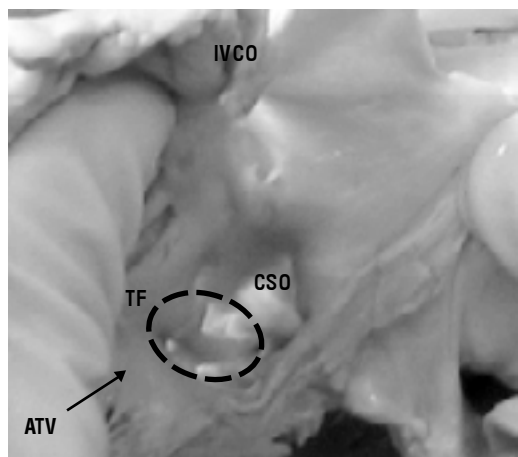


Figure 5. The thin and pellucid muscle tissue in the subthebesian area; 8 normal hearts (16%), 5 hearts with dysrhythmia (25%); IVCO — inferior vena cava orifice, CSO — coronary sinus orifice, ATV — attachment of the tricuspid valve, TF — subthebesian fossa.

We could not find any connection between the arrangement of muscle fibres and the age or sex of hearts, either in the control or examined group.

We did not find also any correlation between the age and sex of examined material and the thickness of the atrial wall in the subthebesian area, in either group of hearts.

The sizes of the examined structure were variable in both groups of hearts. In normal hearts the size X was from 12 to 18 mm (avg. 14.2), the size Y was from 7 to 14 mm (avg. 9 mm) and the size Z was from 2 to 7 mm (avg. 5 mm). In hearts with atrial flutter the sizes were: X — 10 to 17 mm (avg. 13.4 mm), Y — 8 to 12 mm (avg. 9.4 mm) and Z — 2 to 7 mm (avg. 4.5 mm), respectively ($p > 0.05$). The exact data are presented in Table 1.

Table 1. Data representing the results of X, Y, Z parameters in both studied groups — no arrhythmia and atrial flutter group

No.	No arrhythmia group X (n = 50)	Atrial flutter group Y (n = 50)	Z (n = 50)	X' (n = 20)	Y' (n = 20)	Z' (n = 20)
1	14.5	8	3	13	11	4.2
2	13	9.8	2.8	14	8.8	6.2
3	12.5	10	4	13.8	10	3.2
4	14	7.8	5.8	11	10.4	4
5	13	8	4	14	10	4
6	15.6	7	4.8	17	8.8	6
7	15.2	12.8	6.8	11	9	2.8
8	12.2	12	6	16	8	4.2
9	14	11	5	14.2	10	2
10	14.4	8	6	10.8	8.2	3.6
11	12.7	9.4	6	16.2	8.8	3.4
12	18	14	6.2	14	8.4	5
13	16	7.2	3.4	15.4	9	6
14	14.2	7.8	2	12	10	5
15	13	9.6	5.6	11.2	8.2	5.4
16	14	10.2	4	10.8	11.4	6.2
17	12	8.2	5	13	9.2	7
18	14.5	8	2.8	15	11	4.2
19	15	8	6.2	12	9	3.8
20	16.6	9.4	5	12.8	9.4	4
21	15	8.8	6			
22	15.8	11.2	6			
23	13.8	12.8	6.6			
24	13	12	4.8			
25	12.4	8	5.4			
26	12.4	11	5.8			
27	13	8.2	6.4			
28	14.2	9.2	3.2			
29	15.8	7.8	6.6			
30	14.8	9.2	6			
31	15	11	5.8			
32	13.2	7	6.8			
33	16	8.8	5.2			
34	15	8.4	6			
35	12.8	7.2	4.2			
36	13.8	8	7			
37	16	8	5			
38	17.2	11	5.6			
39	15	7	3.4			
40	14.8	7.4	6			
41	14	8	4.2			
42	14.6	8.2	2.8			
43	16	7.2	6			
44	12.8	9	6			
45	13.2	8	5			
46	14	8	3.6			
47	12.2	8.4	4			
48	13.2	10	4			
49	14	7.8	4.6			
50	12	8.2	3.8			
AVG	14,188	9.02	5,004	13.36	9.43	4.51
SD (p > 0.05)	1,403	1,684	1,257	1,876	0,974	1,268

p > 0.05 (non significant)

DISCUSSION

Detailed anatomical knowledge of the subthebesian region may be very important in the electrophysiology of common atrial flutter. Iesaka et al. [4] in their electrophysiological research postulated that in some patients in this area dual isthmus phenomenon may occur, which could be directed to dual septal exits. This is in accordance with our results, because some hearts contained irregular muscle fibre arrangement (more often in atrial flutter group) in the subthebesian, tricuspid annulus and coronary sinus orifice area. Such an irregular placement of muscle fibres might be responsible for disturbances in conduction in this region. Tritto et al. [18], during electrophysiological examination of patients with atrial flutter, also described conduction abnormalities in the region of vena cava inferior ostium (superiorly and inferiorly). We did not examine the area above the inferior vena cava, but only below this structure and we observed many irregularities in muscle fibre arrangement in the majority of hearts with dysrhythmia (65% of cases). In some patients with atrial fibrillation treated with antiarrhythmic drugs, so-called induced-atrial flutter can occur. The ablation of the tricuspid annulus-vena cava inferior isthmus can prevent atrial flutter and decrease future atrial fibrillation occurrence [13]. This indirectly proves the importance and the complexity of the examined area in the light of supraventricular dysrhythmia ablation.

Atrial flutter usually occurs because of changes in the atrial muscle, such as slowing of the conduction of electrical impulses through the atrium [1]. We partly agree with this statement and such a slowing of impulses may be present in the subthebesian area, because of the possibility of an arising microentry wave within this region. According to our results this is most probable in hearts with circular and chaotic arrangement of muscle fibres in the examined fossa., because a microentrant wave may slow down and run in many directions within the area.

Ren et al. [14] examined right atrial wall thickness with high-resolution intracardiac echocardiographic imaging during radiofrequency catheter ablation procedures. The examinations were performed in five anaesthetised closed chest swine. They found that transmural lesion size after ablation correlates with time of application and thickness of wall before procedure. Our results indicate that in the examined group of human hearts the thickness of

the wall in the isthmus area was very thin in some cases (16% — normal hearts, 25% — dysrhythmic hearts). The ablation procedure in such a thin area could be hazardous, because of the possibility of atrial wall perforation with ablative catheter.

As far as the subthebesian fossa in relation to coronary sinus orifice is considered, there are reports that the fashion and shape of the Thebesian valve are the cause of difficulty during insertion of the catheter inside coronary sinus [3, 9, 17]. It would be reasonable to check how the shape of the subthebesian fossa influences the development of the thebesian valve, because according to our results this area on the inferior wall of the right atrium is variable and has different sizes. Furthermore our data suggest that diversity in the stereoscopically measured size of the subthebesian fossa may have clinical importance during ablation procedure.

REFERENCES

1. Callans DJ, Schwartzman D, Gottlieb CD, Dillon SM, Marchlinski FE (1997) Characterization of the excitable gap in human type I atrial flutter. *J Am Coll Cardiol*, 30: 1793–1801.
2. Farré J, Moro C (1998) Ten years of radiofrequency ablation. Futura publishing company, Armonk, NY.
3. Hellerstein HK, Orbison JL (1951) Anatomic variations of the orifice of the human coronary sinus. *Circulation*, 3: 514–523.
4. Iesaka Y, Yamane M, Goya M, Takahashi A, Fujiwara H, Okamoto Y, Soejima Y, Nitta J, Nogami A, Aonuma K, Hiroe M., Marumo F, Hiraoka M (2000) A jump in cycle length of orthodromic common atrial flutter during catheter ablation at the isthmus between the inferior vena cava and tricuspid annulus. Evidence of dual isthmus conduction directed to dual septal exits. *Europace*, 2: 163–171.
5. Kalman J, Olgin JE, Lee RJ, Lesh MD, Saxon LA (1995) The anterior boundary of human atrial flutter: role of the tricuspid annulus. *Circulation*, 92: 401–406.
6. Koch W (1922) *Der funktionelle Bau des menschlichen Herzens*, Urban und Schwarzenberg, Berlin–Wien.
7. Koch W (1907) *Über das Ultimum moriens des menschlichen Herzens. Ein Beitrag zur Frage des Sinusgebietes.* *Beitr Path Anat*, 42: 203–224.
8. Kosinski D, Grubb BP, Wolfe DA, Mayhew H (1998) Catheter ablation for atrial flutter and fibrillation. *Postgraduate Medicine*, 103: 103–110.
9. Kuta W, Grzybiak M., Kosiński A (1998) Valves of the inferior vena cava and coronary sinus of the adult human heart in the light of statistical analysis. *Ann Acad Med Gedan*, 28: 9–21.
10. Olgin JE, Kalman JM, Fitzpatrick AP, Lesh MD (1995) Role of right atrial endocardial structures as barriers to conduction during human type I atrial flutter: activation and entrainment mapping guided by intracardiac echocardiography. *Circulation*, 92: 1839–1848.

11. Olgin JE, Kalman JM, Lesh MD (1996) Conduction barriers in human atrial flutter: correlation of electrophysiology and anatomy. *J Cardiovasc Electrophysiol*, 7: 1112–1126.
12. Reithmann C, Hoffmann E, Steinbeck G (1998) Radiofrequency catheter ablation in atrial flutter and atrial fibrillation. *Archives–Herz*, 4: 209–218.
13. Reithmann C, Hoffmann E, Spitzlberger G, Dorwarth U, Gerth A, Remp T, Steinbeck G (2000) Catheter ablation of atrial flutter due to amiodaron therapy for paroxysmal atrial fibrillation. *E Heart J*, 21: 565–572.
14. Ren JF, Callans DJ, Schwartzman D, Michele JJ, Marchlinski FE (2001) Changes in local wall thickness correlate with pathologic lesion size following radiofrequency catheter ablation: an intracardiac echocardiographic imaging study. *Echocardiography*, 18: 503–507.
15. Sanchez-Quintana D, Yen Ho S, Cabrera JA, Farré J, Anderson RH (2001) Topographic anatomy of the inferior pyramidal space: relevance to radiofrequency catheter ablation. *J Cardiovasc Electrophysiol*, 12: 210–217.
16. Schwartzman D, Callans DJ, Gottlieb CD, Dillon SM, Movsowitz C, Marchlinski FE (1996) Conduction block in the inferior vena caval-tricuspid valve isthmus: association with outcome of radiofrequency ablation of type I atrial flutter. *J Am Coll Cardiol*, 28: 1519–1531.
17. Silver MA, Rowley NE (1998) The functional anatomy of the human coronary sinus. *Am Heart J*, 5: 1080–1084.
18. Tritto M, de Ponti R, Zardini M, Spadacini G, Salerno-Uriarte JA (2002) Bystander cavo-tricuspid isthmus activation during post incisional intra atrial reentrant tachycardia. *Europace*, 4: 91–97.
19. Zipes (2001) *Cardiac Pacing and Electrophysiology*. B. Saunders Comp., 3rd Edition, Philadelphia–Boston.