

Rabbit articular cartilage defects treated with cultured costal chondrocytes (preliminary report)

Janusz Popko¹, Paweł Szeparowicz¹, Bogusław Sawicki², Sławomir Wołczyński³, Jerzy Wojnar¹

¹Department of Pediatric Orthopaedics and Traumatology, Medical University of Białystok, Poland

²Department of Histology and Embryology Medical, University of Białystok, Poland

³Department of Gynecological Endocrinology, Medical University of Białystok, Poland

[Received 27 January 2003; Revised 24 March 2003; Accepted 24 March 2003]

An attempt to repair articular cartilage defects by costal chondrocytes transplantation was made. A full-thickness defect in the rabbit's femoral patellar groove was artificially made. Cultured costal cartilage chondrocytes were then transplanted into the defects and covered with periosteal flaps. Empty defects were used as the control group. Animals were divided into two groups (five rabbits each). They were examined after four and twelve weeks from the day of transplantation, respectively. The reparative tissue was evaluated by macroscopic and histological examinations. The reparative tissues in defects with transplanted chondrocytes had an hyaline-like cartilage appearance and were firmly attached to the surrounding normal cartilage. No trace of newly formed bone was detected. The reparative tissues found in defects that were left empty had a fibrous character. They were loosely connected to the surrounding cartilage and were more compliant than tissues from transplanted defects. Considering these initial findings, the ease of surgical procedures during the harvesting of the costal cartilage and few interventions into the joint make the costal cartilage a promising source of chondrocytes for transplantation. However, this needs to be confirmed on a larger scale over a longer period of time.

key words: articular cartilage repair, costal chondrocytes, transplantation

INTRODUCTION

The intrinsic capacity of cartilage to repair chondral injuries is poor. Many different techniques to induce cartilage repair with the use of cultured chondrogenic cells have been explored. After the improvement of methods for isolating and culturing chondrocytes, many authors have reported positive outcomes of this therapy [3, 10]. Chondrocytes held in place by covering periosteal flaps have been suc-

cessfully used in clinical applications for many years. The results of the first 23 patients treated by this method were reported by Brittberg et al. [4].

The success of chondrocyte transplantation depends on many factors. The harvesting of the cartilage, and the successful digestion and culturing of chondrocytes are very important. Operating procedures are equally significant. The costal cartilage, besides the articular cartilage, is the biggest perma-

Address for correspondence: Janusz Popko MD, PhD, Department of Pediatric Orthopedics and Traumatology, Children's Hospital, ul. Waszyngtona 17, 15-274 Białystok, Poland, tel: +48 85 745 08 96, fax: +48 85 745 08 95, e-mail: jpopko@amb.edu.pl

nent cartilage in the human body. The abundance of this tissue and the ease of surgical procedure during harvesting (i.e., causes less damage to the donor site) allow the costal cartilage to be considered the most useful source of chondrocytes for transplantation. The number of cells available for transplantation is another factor that determines successful healing. Considering the above-mentioned factors and the available literature, we experimentally tried to assess the potential of costal chondrocytes for inducing the repair of full-thickness defect in the articular cartilage of a rabbit femur. The use of the rabbit knee model in assessment of cartilage repair has been widely used by other authors [1, 5, 6, 8].

MATERIAL AND METHODS

Isolation and cultures of chondrocytes

Cartilage slices were taken from the costal cartilage of a four-week old male rabbit (White New Zealand rabbit). Surgical procedures were performed under general combined anesthesia using the intramuscular injection, which contained a mixture of ketamine (Narkamon, 6–10 mg per kilogram of body weight) and xylazine (Xylavet, 2 mg per kilogram of body weight). Cartilage specimens were minced and washed three times in 0.9% sodium chloride. Isolation of chondrocytes was done by using 0.25% collagenase (typ I, Sigma), 0.05 Dnase (Sigma) and 17.5 mM $N\alpha$ -p-tosyl-L-lysine chloromethyl ketone (TLCK, Sigma) in F-12 medium (Sigma) supplemented with 10% FCS as described before [18]. The isolated cells were sifted through a filter with a pore diameter of 25 μ m, pelleted (1500 rpm, 5 min), counted and washed three times in a culture medium. Then, the cells were seeded in a 75 cm² culture flask (Sarstedt, Germany) in Ham's F-12 (Sigma) medium supplemented with 10% FCS and antibiotic (Penicillin, Streptomycin, Amphotericin; ICN Biomedicals). The culture medium was changed every two or three days. The cells were maintained in a monolayer culture until reaching confluence for approximately two weeks. Subsequently, the cells were isolated by trypsin (Sigma) treatment, washed three times in culture medium and collected by centrifugation (1500 rpm, 5 min) and placed in 50 μ l of medium in a sterile syringe.

Transplantation of chondrocytes

Transplantations of costal chondrocytes were performed on twenty-month old male rabbits

(weight 2.5 kg, New Zealand White rabbit). Surgical procedures were performed under general combined anesthesia as described above. After a medial parapatellar incision was made, the patella was dislocated laterally and a full thickness articular cartilage defect was created on the patellar groove of the femur using a scalpel. The size of the defect was 5 × 4 mm in width and 2 mm in depth. The same incision was used for harvesting a free periosteal flap of a size corresponding with the defect on the medial proximal tibia. The flap was sutured to the peripheral cartilage rim of the defect by four 8-0 sutures. After transplanting the cultured chondrocytes, three of the sutures were immediately tied while the fourth was left untied. The chondrocytes were transferred into the defect with a sterile syringe. Finally, the knee was closed in separate layers. In two rabbits from each group, the procedures were repeated on the opposite leg with defects left empty and without periosteal flap as a control. The animals were divided into two groups of five animals each and they were allowed to move freely. The defects were evaluated in both groups after 4 and 12 weeks from the day of operation, respectively.

Macroscopic evaluation

All the animals were killed by cervical dislocation after sedation. The defects in transplanted chondrocytes and those left empty were examined macroscopically. The surfaces of the grafts were inspected for color, integrity, contour and smoothness.

Histological evaluation

After macroscopic observations, the distal part of the femur was excised and fixed with 10% buffered formalin for 6 days. Each specimen was embedded in paraffin. 5 μ m thick sections were cut through the grafted area and stained using hematoxylin-eosin and Azan methods (azocarmine + aniline blau). The histological sections were examined for the quality of the repaired tissue.

RESULTS

Culture of chondrocytes

Approximately 2.0×10^6 cells per dish were seeded. Chondrocytes started forming colonies 2–3 days after seeding. All the cultures reached confluence after approximately fourteen days. Although some cells in the colonies showed a round morphology, more cells had a fibroblast-like morphology.

Macroscopic observations

After 4 weeks from the day of operation, the reparative tissue with defects in the transplanted chondrocytes showed appearances similar to that of the normal cartilage. The defects were covered with a white, glossy and smooth membrane and were firmly connected to the adjacent normal cartilage. The surface of the patellar groove showed a normal contour. The newly formed tissue had an elastic consistency and looked like a cartilage. And it was more compliant than the normal cartilage in the same knee. The defect was filled on the level with the surrounding cartilage.

At twelve weeks, the gross appearance of the reparative tissue changed slightly; its color darkened slightly, it was less glossy and more irregular. But it was still more compliant than the normal cartilage and completely filled the defect.

At four weeks, the defects without transplantation were filled with red semitransparent tissue with discernible edges. The defects were only partially filled. After 12 weeks, irregular surfaces loosely attached to the normal cartilage were present.

Histological evaluation

After four weeks from the day of operation, the defects transplanted with costal chondrocytes were filled with newly formed tissues firmly incorporated into the surrounding normal cartilage. Many chondroblasts with an abundance of extracellular matrix were present (Fig. 1). In deeper layers of the grafts, many dividing chondrocytes showed a tendency to form clusters with some irregularity. Cluster formations were surrounded by an abundance of extracellular matrix with collagen fibers (Fig. 2).

At twelve weeks, the reparative tissues did not drastically change their appearance. Many dividing cells started forming more regular (columnar) formations. The chondrocytes were surrounded by a rich extracellular matrix with many irregularly dispersed collagen fibers (Fig. 3). No trace of newly formed bone was found in any graft at 4 and 12 weeks.

At four weeks, the reparative tissue in the defects without transplanted chondrocytes mostly consisted of fibroblast-like cells. They had structural characteristics of a fibrous connective tissue (Fig. 4).

In specimens of healthy cartilage collected from the same knees from weight bearing surfaces (Fig. 5), many isogenic groups of chondrocytes surrounded by an homogeneous matrix were found. They were less intensively stained and did not have distinguishable collagen fibers.

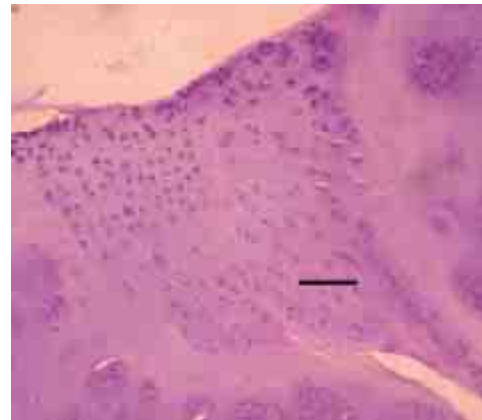


Figure 1. Histological section of the reparative tissue with transplantation of costal chondrocytes, at 4 weeks, showing numerous chondroblasts scattered in the cartilage matrix — see top of photomicrograph, and juvenile chondrocytes — see bottom. Hematoxylin-eosin staining (H-E), scale bar, 200 μm .

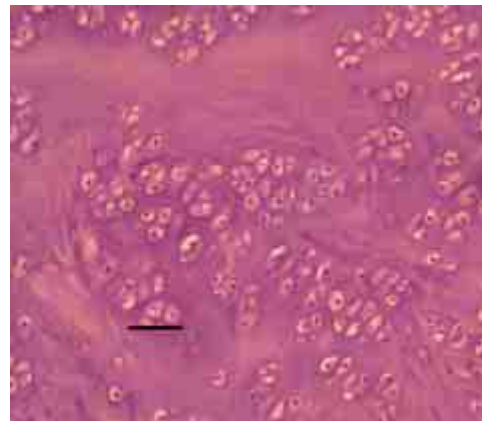


Figure 2. Histological section of the reparative tissue with transplantation of costal chondrocytes, deep layers of scar tissue, at 4 weeks, showing numerous big isogenic groups of chondrocytes, collagen fibers in purple staining, H-E, scale bar, 100 μm .

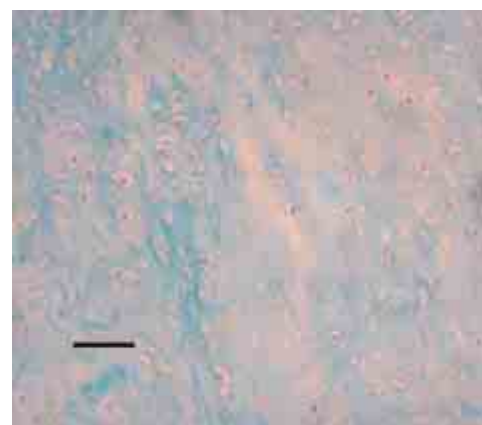


Figure 3. Histological section of the reparative tissue with transplantation of costal chondrocytes, at 12 weeks, showing numerous chondrocytes scattered throughout the collagen fibers (blue staining). Azan staining, scale bar, 100 μm .

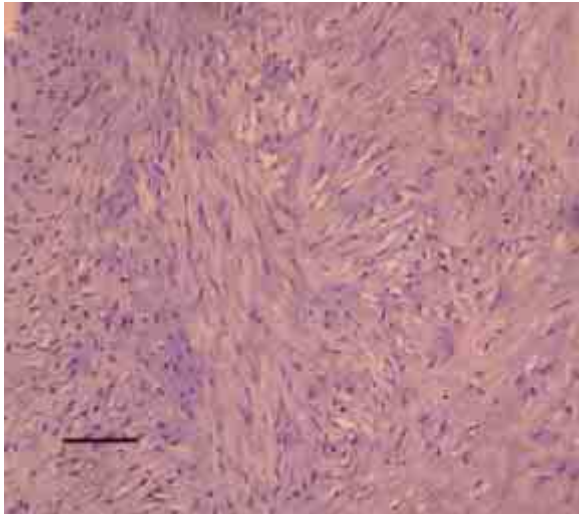


Figure 4. Histological section of the reparative tissue without transplantation of costal chondrocytes, at 4 weeks, showing numerous fibroblast-like cells and histological structure characteristic of loose fibrous connective tissue. H-E, scale bar, 100 μ m.

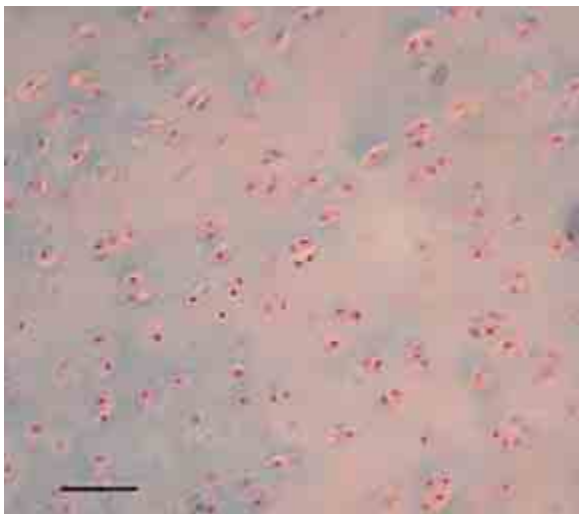


Figure 5. Histological section of normal hyaline articular cartilage collected from operated knee from weight bearing surfaces. Azan staining showed intense staining of the matrix around each isogenic groups of chondrocytes. Note that the collagen fibers present in the matrix have not stained in adult hyaline cartilage, scale bar, 100 μ m.

DISCUSSION

The intrinsic capacity of cartilage to repair chondral injuries is poor. Many different techniques for repair have been explored [4]. Many different cells are considered as potential repair inductors, for example, mesenchymal cells [22], periosteal cells [19] and chondrocytes from the articular cartilage. Most experimental [1, 8, 9, 17, 20] and clinical [5] data

found in the literature concern the use of articular chondrocytes for inducing repair of articular cartilage defects.

Very few publications concerning the potential of the use of costal chondrocytes for inducing repair of articular cartilage defects are available [11, 14]. The costal cartilage arouses the interest of researchers for two reasons. It is, besides the articular cartilage, the largest permanent cartilage in the human body [11], and the ease of the surgical procedure during harvesting (i.e., few interventions into the joint and causes less damage to the donor site). But this raises the question; does the costal cartilage have the same phenotype as the articular cartilage? If this could be proven, then the former would be the most promising source of chondrocytes.

Research concerned with regulation of the endochondral ossification process of costal cartilage started in the sixties. In 1975, Shimomura et al. [21] found that the initiation of osteochondral ossification depends on the zone the costal cartilage is collected from and on the unknown but necessary host mediators. Moskalewski and Bator [16] found that costal chondrocytes from adult dogs (3 to 8 years old) were unable to reconstruct cartilage after transplantation into the soft tissue. However, Kitaoka et al. [11] succeeded in culturing cell lines from the costal cartilage of mice. The cells were able to produce cartilage whose phenotypic characteristics were consistent with the cartilage tissues other than the costal cartilage, i.e., articular cartilage. This explains our attempt to assess the potential of costal chondrocytes for repair of the articular cartilage defects.

In the earlier research, many authors have noted the unstable phenotypic character of chondrocytes in cultures. During serial monolayer cultures, chondrocytes' phenotype is lost [2]. Dedifferentiated chondrocytes change to a fibroblast-like morphology and dramatically alter their synthesis of collagen and proteoglycans. The chondrocytes in our cultures had the same fibroblast-like appearance as that described by other authors [2, 20]. Brittberg et al. [6] proved that this process can be reversed by placing chondrocytes in a three dimensional suspension.

In the present study, a defect transplanted with costal chondrocytes was filled with reparative tissue that resembled hyaline cartilage. O'Driscoll et al. [19] showed the importance of joint motion and weight bearing for grafting results. Therefore, the rabbits in our experiment were allowed to walk freely.

In the present study, at 4 weeks, the reparative tissue was firmly attached to the surrounding carti-

lage, which (as earlier mentioned) is the most important aspect in the cartilage repair. This is more important than the quality of the tissue itself [7]. Good incorporation of the graft is supposed to protect the surrounding cartilage from further deterioration [12]. Cells in reparative tissue formed many big and irregular clusters surrounded by an abundance of matrix. This could be caused by uneven distribution of transplanted chondrocytes into the defect. However, during a long-term observation, Brittberg et al. [6] found that chondrocytes formed more regular columns and the reparative tissue became similar to the normal cartilage. This process was noticed in our study after 12 weeks. The reparative tissue had more regularly placed groups of cells and resembled the normal cartilage collected from the knee of the same rabbit. It is very possible that this would become more evident during longer observations — which we are planning to implement. Many authors have noticed that partial regeneration of the chondral defect can be induced by cells either migrating from the surrounding tissue or from the subchondral bone marrow [3, 10]. However, they are not able to induce healing comparable with that caused by transplanted chondrocytes. Repair tissues in defects left empty were of lower histological quality. They mostly consisted of fibroblasts with structural characteristics of the fibrous tissue (Fig. 5).

In our research, no trace of newly forming bone was detected either at 4 or 12 weeks. This could be caused by an absence of proper mediators necessary to initiate this process [21] in the joint fluid. In experiments conducted by Książek [13] and Malejczyk et al. [15], endochondral ossification occurred quite early, fourteen days after intramuscular implantation of the costal chondrocytes.

Moskalewski and Bator [16] noticed that the yield of chondrocytes per given volume of cartilage is higher when the cartilage is younger. This means that the possibility of a successful transplantation becomes smaller with aging donors. The costal cartilage of young rabbits (four-weeks old), used in our experiment, allowed to obtain a larger amount of chondrocytes. The cells were easy to culture and were able to reconstruct a defect in the articular cartilage. The question whether only young donors should be used for costal chondrocytes transplantation remains open.

We understand that these, however optimistic, findings need further development. We plan to assess the potential of costal chondrocytes for inducing the repair of defects in the articular cartilage on

a larger scale and over a longer period of time. This would also include a more thorough immunohistochemical analysis of the reparative tissue.

ACKNOWLEDGEMENTS

This research was possible thanks to a grant number 387528 from the Medical University of Białystok.

REFERENCES

1. Bentley G, Greer RB III. (1971) Homotransplantation of isolated epiphyseal and articular cartilage chondrocytes into joint surfaces of rabbits. *Nature*, 230: 385–388.
2. Benya PD, Shaffer JD (1982) Dedifferentiated chondrocytes reexpress the differentiated collagen phenotype when cultured in agarose gels. *Cell*, 30: 215–224.
3. Brittberg M (1999) Autologous Chondrocyte Transplantation. *Clin Orthop*, 367S: 147–155.
4. Brittberg M, Faxen E, Peterson L (1994) Carbon fiber scaffolds in the treatment of early knee osteoarthritis. A prospective 4-year follow-up of 37 patients. *Clin Orthop*, 307: 155–164.
5. Brittberg M, Lindahl A, Nilsson A, Ohlsson C, Isaksson O, Peterson L (1994) Treatment of deep cartilage defects in the knee with autologous chondrocyte transplantation. *New Engl J*, 331: 889–895.
6. Brittberg M, Nilsson A, Lindahl A, Ohlsson C, Peterson L (1996) Rabbit articular cartilage defects treated with autologous cultured chondrocytes. *Clin Orthop* 326: 270–283.
7. Buckwalter JA, Rosenberg LC, Coutts R et al. (1987) Articular cartilage: Injury and repair. In: Woo SL-Y, Buckwalter J (eds.). *Injury and repair of the musculoskeletal soft tissues*. Park Ridge, Am Acad Orthop Surg, 465–482.
8. Chesterman PJ, Smith AU (1968) Homotransplantation of articular cartilage and isolated chondrocytes. An experimental study in rabbits. *J Bone Joint Surg*, 50B (1): 184–197.
9. Grande DA, Pitman MI, Peterson L, Menche D, Klein M (1989) The repair of experimentally produced defects in rabbit articular cartilage by autologous chondrocyte transplantation. *J Orthop Res*, 7: 208–218.
10. Katsube K, Ochi M, Uchio Y, Maniwa S, Matsusaki M, Tobita M, Iwasa J (2000) Repair of articular cartilage defects with cultured chondrocytes in Atelokollagen gel. *Arch Orthop Trauma Surg*, 120: 121–127.
11. Kitaoka E, Satomura K, Hayashi E, Yamanouchi K, Tobiume S, Kume K, Obinata M, Nagayama M (2001) Establishment and characterization of chondrocyte cell lines from the costal cartilage of SV 40 large T antigen transgenic mice. *J Cell Biochem*, 81: 571–582.
12. Klompmaker J, Jansen HWB, Veth RPH et al. (1992) Porous polymer implants for repair of full thickness defects of articular cartilage. An experimental study in rabbit and dog. *Biomaterials*, 13: 625–634.
13. Książek T (1983) Bone induction by calcified cartilage transplants. *Clin Orthop Rel Res*, 172: 243–250.
14. Lohman CH, Schwartz Z, Niederauer GG, Carnes Jr DL, Dean DD, Boyan BD (2000) Pretreatment with platelet

- derived growth factor-BB modulates the ability of costochondral resting zone chondrocytes incorporated into PLA/PGA scaffolds to form new cartilage *in vivo*. *Biomaterials*, 21: 49–61.
15. Malejczyk J, Kamiński MJ, Malejczyk M, Majewski S (1985) Natural cell-mediated cytotoxic activity against isolated chondrocytes in mouse. *Clin Exp Immunol*, 59: 110–116.
 16. Moskalewski S, Bator S (1985) Regenerating rib cartilage tentatively used as a source of chondrocytes for transplantation. *Arch Immunol Ther Exp*, 33: 685–692.
 17. Moskalewski S, Hyc A, Grzela T, Malejczyk J (1993) Differences in cartilage formed intramuscularly or in joint surface defects by syngeneic rat chondrocytes isolated from the articular-epiphyseal cartilage complex. *Cell Transplant*, 2: 467–473.
 18. Moskalewski S, Osiecka-Iwan A, Hyc A, Jozwiak A (2000) Mechanical barrier as a protection against re-jection of allogenic cartilage formed in joint surface defects in rats. *Cell Transplant*, 9: 349–357.
 19. O'Driscoll SW, Keeley FW, Salter RB (1986) The chondrogenic potential of free autogenous periosteal grafts for biological resurfacing of major full-thickness defects in joint surfaces under the influence of continuous passive motion. An experimental investigation in the rabbit. *J Bone Joint Surg*, 68A: 1017–1035.
 20. Peterson L, Menche D, Grande D et al. (1984) Chondrocyte transplantation-An experimental model in the rabbit. *Trans Orthop Res Soc*, 9: 218.
 21. Shimomura Y, Yoneda T, Suzuki F (1975) Osteogenesis by chondrocytes from growth cartilage of rat rib. *Calcif Tiss Res*, 19: 179–187.
 22. Wakitani S, Goto T, Pineda SJ, Young RG, Mansour JM, Caplan AI, Goldberg VM (1994) Mesenchymal cell-based repair of large, full-thickness defects of articular cartilage. *J Bone Joint Surg Am*, 76: 579–592.