

Ectopic pancreas: endoscopic, ultrasound and radiological features

Krzysztof Zinkiewicz¹, Wit Juśkiewicz², Witold Zgodziński¹, Justyna Szumiło³, Grzegorz Ćwik¹, Jarosław Furtak¹, Ryszard Maciejewski², Grzegorz Wallner¹

¹Second Department of General Surgery, Medical University, Lublin, Poland

²Department of Anatomy, Medical University, Lublin, Poland

³Department of Pathology, Medical University, Lublin, Poland

[Received 11 June 2003; Accepted 9 July 2003]

Ectopic pancreas, a rare entity, is defined as pancreatic tissue lying outside its normal location without anatomical or vascular connections with the pancreas proper. Most occurrences of heterotopic pancreas are located in the stomach wall, duodenum, small intestine or anywhere in the gastrointestinal tract. The aim of this study was to describe the endoscopic, endosonographic (EUS) and radiological features of these lesions. Management of the ectopic pancreas remains controversial. The authors describe 12 patients and try to recommend different kind of treatment in the light of the symptoms, location and size of the lesions.

key words: heterotopic pancreas, endoscopic resection, endosonography

INTRODUCTION

Ectopic (aberrant, heterotopic, accessory) pancreas (EP) or pancreatic remnant is defined as the presence of well-developed and normally organised pancreatic tissue lying outside its normal location without any anatomical and vascular continuity with the proper pancreas. It may occur anywhere in the gastrointestinal tract. Most frequent locations are the stomach, duodenum or the proximal part of small intestine [1–3, 9]. The lesion is also found in Meckel's diverticulum, the biliary tract, the gallbladder, the liver, the spleen, and other sites within the abdominal cavity. Ectopic pancreas may often remain asymptomatic and is diagnosed incidentally [1, 12]. Occasionally, symptoms may vary according to EP location, size and the involvement of overlying mucosa [10]. Dyspepsia, upper gastrointestinal bleeding, gastric outlet obstruction or inflammatory abdominal mass are the most often reported [1, 11]. The frequency of ectopic pancreas has been estimated

as one per 500 laparotomies and 0.6% to 13.7% of autopsies [3].

MATERIAL AND METHODS

5,260 patients examined with upper gastrointestinal endoscopy during the last four years in the Second Department of General Surgery of the Medical University in Lublin were reviewed retrospectively. Upper gastrointestinal endoscopy was performed in all patients using video endoscopes (Olympus GIV Q-140). Endoscopic ultrasound examination (EUS) was performed using instruments (Pentax 32-FG with Hitachi ultrasound) with sectoral transducer 7.5 MHz. Since October 2002 Olympus echoendoscope GF-UMQ130, 7.5/20 MHz has also been used. Endoscopic ultrasound features of the lesions such as: size, sonographic layer of origin, margin appearance and echogenicity were analysed. The lesion's origin layer in the gastric wall was determined using a five-layer pattern. Upper gastrointestinal rentgenoscopy using a barium contrast

medium was also applied. Therapeutic procedures were performed in local anaesthesia with routine premedication. In each case diagnosis was confirmed by pathological examination. In untreated patients deep biopsy was performed to obtain adequate diagnostic tissue. The lesions removed were divided according to the Heinrich classification (type I — with all elements of normal pancreatic tissue, type II — pancreatic tissue without islet cells, type III — tissue only with pancreatic ducts).

RESULTS

Ectopic pancreas of the upper gastrointestinal tract was diagnosed in 12 out of 5,260 patients examined with upper gastrointestinal endoscopy during last 4 years (0.15%). The mean age of patients was 45 with M/F ratio of 0.67/0.33 (8 women and 4 men, ranging in age from 22 to 64).

Most of the lesions detected were located within the pyloric part of the stomach (8 patients), 2 in the duodenal bulb, and 2 cases of EP were found in the body of the stomach (Fig. 1). In 7 patients unspecific symptoms i.e. dyspepsia, epigastric pain, and nausea were noted but other patients were asymptomatic. In 7 patients lesions were resected endoscopically, 2 patients were referred for surgery and 3 patients refused the treatment. Details of clinical features and pathological type according to Heinrich Classification are shown in Table 1.

DISCUSSION

The pancreas-forming process during gestation is often linked with congenital disorders. The first

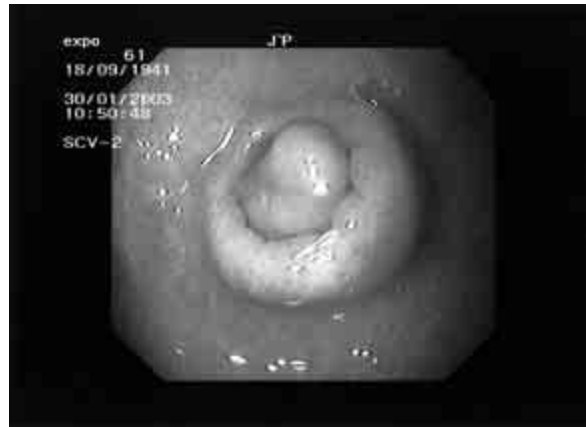

Figure 1. Endoscopic picture of ectopic pancreas in the stomach body.

case of ectopic pancreas was reported by Schultz in 1729. The embryological derivation of heterotopic pancreatic tissue is well described [1]. According to Arey and Haffer's theory the pancreas is formed in the 4th week from three primitive endodermal evaginations (buds) of the anterior intestine. The right ventral evagination fuses with the dorsal one and become the body, tail and upper part of the pancreas head. The lower part of the head and processus uncinatus stems from the left ventral evagination. Before this fusion there is a rotation of the ventral part of the pancreas, during which the buds are in close contact with the distal stomach and proximal duodenum, allowing engrafting of pancreatic germinal cells, from which histological components of the pancreas may develop. One of the evaginations can also remain within the

Table 1. Clinicopathological features of patients with ectopic pancreas

Case	Age	Gender	Location	Symptoms	Therapy	Pathologic type
1	28	Female	Antrum	+	Endoscopy	II
2	34	Male	Pylorus	+	Endoscopy	II
3	56	Female	Pylorus	-	None	I
4	47	Female	Body	+	Endoscopy	II
5	63	Female	Duodenum	-	None	I
6	64	Male	Antrum	-	Endoscopy	II
7	55	Male	Antrum	-	Endoscopy	III
8	39	Female	Pylorus	+	Surgery	II
9	22	Female	Duodenum	+	Endoscopy	II
10	60	Male	Antrum	-	Surgery	I
11	29	Female	Antrum	+	Endoscopy	I
12	39	Female	Body	+	None	II

bowel wall and can be carried along with the longitudinal growth of the intestine. This allows heterotopic tissue to be formed far from the normally located pancreas.

If one of the evaginations remains in the bowel wall, it may be carried along with the longitudinal growth of the intestine and form heterotopic pancreas. Islands of the pancreatic tissue most often are found in the submucosal layer of the gastrointestinal tract. Microscopically, these pancreatic remnants may resemble normal pancreatic parenchyma with organised acini and ducts. Alternatively, pancreatic acini are not present and the lesion is composed of disorganised pancreatic ductal structures admixed with smooth muscle, so called "adenomyomas". The third possibility, termed pancreatic choristoma, applies to the situation in which pancreatic acini are present in a disorganised mass of ducts and smooth muscles [3].

As in our patients, aberrant pancreatic tissue was most often located in the antrum and lower part of the stomach body along the great curvature (Fig. 1, 2). Heterotopic pancreas can be diagnosed by barium contrast as a polypoid lesion and only when a central gland-duct is demonstrated can exact diagnosis be made (Fig. 3) [13]. In endoscopic examination ectopic pancreas was usually diagnosed as a submucosal tumour which was firm and slightly irregular. The diameter of nodules varies from 0.2 to 4.0 cm. The mucosa over the lesion may have a central depression or dimpling and ducts may empty into the lumen at this side.

In recent years endoscopic ultrasonography has been widely used in the diagnosis of digestive diseases especially submucosal lesions. Endosonogra-

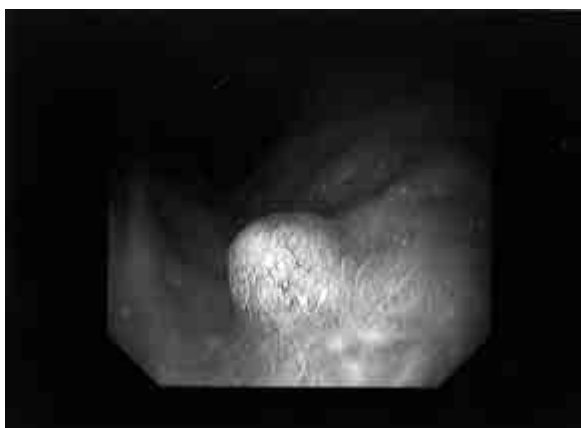


Figure 2. Endoscopic picture of ectopic pancreas in the stomach antrum.

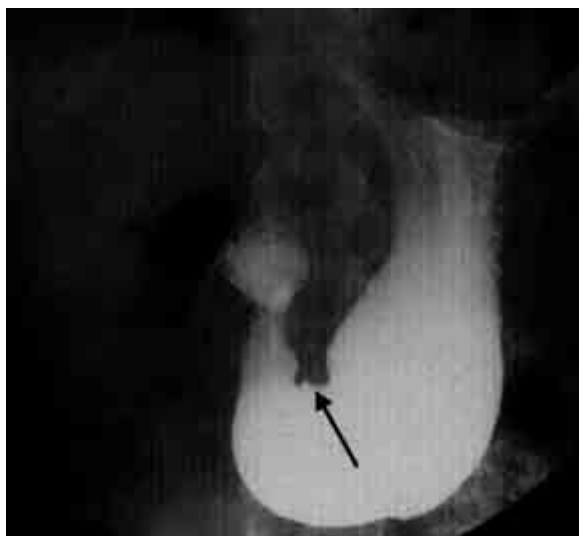


Figure 3. Barium contrast examination.

phy can demonstrate echogenic differences between different types of submucosal tumours and the depth of its invasion. However, histological confirmation is still required for a definite diagnosis. Specimen pathology taken by a standard biopsy forceps is difficult. The submucosal layer can be reached only in 25% of biopsies using routine forceps [4]. Special techniques are needed such as deep biopsy, EUS-guided biopsy or EUS-guided fine needle aspiration (FNA) and combined strip and bite endoscopic biopsy. In six of our patients histological diagnosis was made by endoscopic resection, which was also the means of treatment.

Endoscopic ultrasonography provided the most useful information regarding tumour location within the gastric wall, helped to distinguish other submucosal lesions and allowed the indication for endoscopic treatment to be established [7]. The characteristic EUS image of lesions was hypoechoic with heteroechogenic structure, which was highly suggestive of pancreatic tissue (the granular parenchymal pattern). The normal gastric wall is visualised by EUS as a five-layered structure, which correlates well with the histological layers. Lesions were located within the hyperechogenic submucosa (the third echoendoscopic layer) or in the submucosal and muscularis propria (the third and fourth layers) (Fig. 4, 5). In these cases thickening of the fourth layer was observed due to hypertrophy of the muscularis propria.

Hase et al. [5] described two types of aberrant pancreas, fused and separate. In the latter type pancreatic tissue arose only in the submucosal layer.

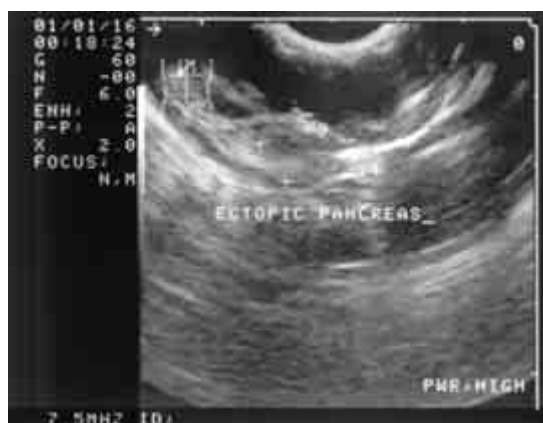

Figure 4. EUS image of the ectopic pancreas (7.5 MHz sectoral probe).

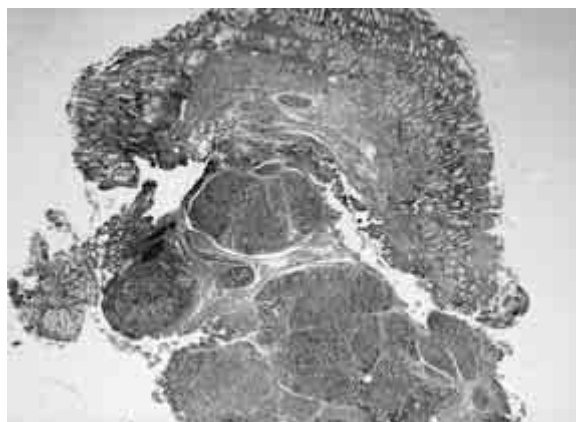


Figure 5. Pathological examination (H+E magn. 40×).

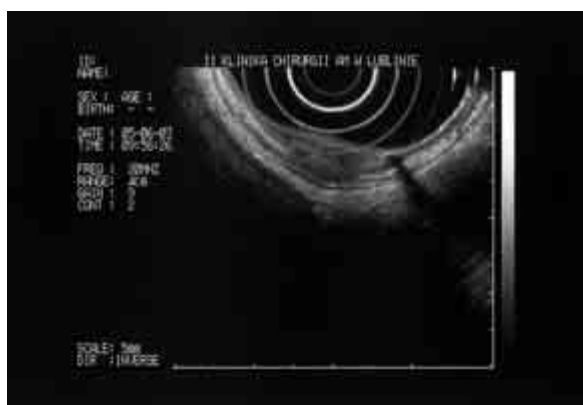

Figure 6. EUS image of the ectopic pancreas (20 MHz rotated probe).

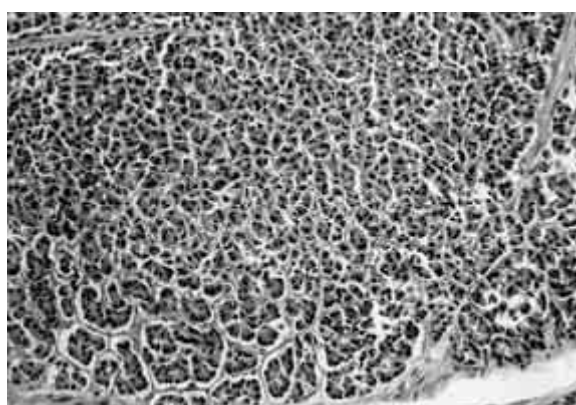


Figure 7. Pathological examination (H+E magn. 400×).

These cases are suitable for endoscopic treatment, as was the case with our patients. The fusion-type pancreatic tissue can be found both in the submucosal layer and the muscularis propria [8]. Three of our patients with deep invasion of pancreatic remnants refused surgical treatment because of the lack of severe symptoms.

Some specimens obtained during endoscopic removal in our study were demarcated by the electric coagulation and cut into pieces, which did not allow for precise examination (Fig. 6, 7).

The need for treatment depends on symptoms and definitive diagnosis, excluding the possibility of malignancy [6, 14]. If any pathological change occurs in the pancreas itself, this also may develop in the ectopic tissue and symptoms may be related to inflammation, cystic dystrophy, abscess formation or malignant change [6]. Endoscopic removal of submucosal lesions is technically diffi-

cult and is regarded as one of the most dangerous endoscopic procedures because of the risk of bleeding and perforation [4]. In our patients endoscopic removal was a safe and successful method of treatment and provided final histological diagnosis. No serious complications and no recurrence over six months' observation were observed. We therefore recommended endoscopic treatment as appropriate in the management of small gastric heterotopic pancreas. Some investigators recommend surgical procedures at the time of diagnosis [4]. Ectopic pancreas diagnosed incidentally does not require operation. Only cases with severe symptoms such as GI bleeding, obstruction or the presence of an inflammatory mass requires surgical resection. Our investigations indicate that the problem of appropriate diagnosis of ectopic pancreas is extremely important from the practical point of view.

REFERENCES

1. Armstrong C, King P, Dixon J, Macleod I (1981) The clinical significance of heterotopic pancreas in the gastrointestinal tract. *B J Surg*, 68: 384–387.
2. Chen C, Yang C, Yeh Y, Chou D, Kuo C (2001) Ectopic pancreas located in the major duodenal papilla: Case report and review. *Gastrointest Endosc*, 1: 121–123.
3. Dolan R, ReMine W, Dockerty M (1974) The fate of heterotopic pancreatic tissue. *Arch Surg*, 109: 762–765.
4. Fleisher DE (1993) Endoscopic resection of gastrointestinal tumours 25: 479–481.
5. Hase S, Nakazawa S, Yoshino J, Kojima Y, Niwa Y, Ohashi S (1989) A study on gastric and small intestinal aberrant pancreas by endoscopic ultrasonography — with special reference to comparison with histological appearance. *Jpn J Gastroenterol*, 86: 1684–1691.
6. Hideki U, Ryuichi D, Koichi H, Akiko S, Kenichiro H, Hiroshi N (1998) Carcinoma arising from ectopic pancreas in the stomach: endoscopic detection of malignant change. *J Clin Ultrasound*, 26: 265–268.
7. Matsushita M, Hajiro K, Okazaki K, Takakuwa H (1997) Gastric inflammatory fibroid polyps: endoscopic ultrasonographic analysis in comparison with histology. *Gastrointest Endosc*, 46: 53–57.
8. Mitsunobo M, Kiyoshi H, Kazuichi O, Hiroshi T (1999) Gastric aberrant pancreas: EUS analysis in comparison with the histology. *Gastrointest Endosc*, 49: 493–497.
9. Pedowski J, Bobko W, Drotlef B, Jachiniński K, Kasprzyk J, Warchoń B (1986) Trzustka dodatkowa w ścianie dwunastnicy. *Wiad Lek*, 39; 22: 1553–1555.
10. Riyaz A, Cohen H (2001) Ectopic pancreas presenting as a submucosal gastric antral tumour that was cystic on EUS. *Gastrointest Endosc*, 53: 675–677.
11. Shaib Y, Rabaa E, Feddersen R, Jamal M, Qaseem T (2001) Gastric outlet obstruction secondary to heterotopic pancreas in the antrum: Case report and review. *Gastrointest Endosc*, 54: 527–530.
12. Sybińska-Szczepanowska B (1964) Trzustka odszczepiona. *Folia Morphol. (Warsz.)*, 15: 449.
13. Theoni Rf, Gudgudas RK (1980) Ectopic pancreas: usual and unusual features. *Gastrointestinal Radiol*, 5: 37–42.
14. Ura H, Denno R, Hirata K, Saeki A, Hirata K, Natori H (1998) Carcinoma arising from ectopic pancreas in the stomach: Endosonographic detection of malignant change. *J Clin Ultrasound*, 26: 265–268.