

# Anastomotic vessels in the retropubic region: Corona mortis

Levent Sarikcioglu<sup>1</sup>, Muzaffer Sindel<sup>1</sup>, Feyyaz Akyildiz<sup>2</sup>, Semih Gur<sup>2</sup>

<sup>1</sup>Departments of Anatomy, Akdeniz University, Antalya, Turkey

<sup>2</sup>Orthopaedics and Traumatology, Faculty of Medicine, Akdeniz University, Antalya, Turkey

[Received 11 March 2003; Revised 4 June 2003; Accepted 4 June 2003]

*Anastomosis between the pubic rami of the inferior epigastric and the obturator arteries has been referred to as the corona mortis. Because anomalous vessels in the retropubic region are at risk in groin or pelvic surgeries, they have an importance not only for general surgery but also for orthopaedics. Because it is hard to distinguish these vessels, they can be injured during ilioinguinal incision, which can lead to massive uncontrolled bleeding. For this purpose, 54 cadaver halves were dissected to determine the occurrence and location of the corona mortis anastomosis. We found venous corona mortis in 11 halves (20.37%). Additionally, in 8 halves (14.81%), the obturator artery originated from the inferior epigastric artery.*

**key words:** corona mortis, obturator artery, inferior epigastric artery

## INTRODUCTION

Anastomosis between the pubic rami of the inferior epigastric and the obturator arteries has been referred to as the corona mortis (crown of death). It is generally considered to be an arterial connection by classical anatomy [10, 11, 20] and orthopaedic textbooks [4]. Less information is available regarding the incidence and location of venous anastomosis. Because such vessels cross the superior pubic ramus and lacunar ligament near the femoral ring, their unexpected presence can become a matter of great concern to the orthopaedic surgeon, urologist, gynaecologist, and general surgeon, any of whom may perform surgical procedures in this area [18]. The tiny anastomoses between the obturator and external iliac system in the retropubic region have been described, but the investigators have neglected to mention that these anastomoses can be life threatening [2, 13].

In many procedures of the retropubic region, attention needs to be paid to the anastomoses located over the superior pubic ramus between the

arterial and the venous system. We therefore planned to evaluate the anastomosis that form the corona mortis in order to measure its average distance from the lacunar ligament and pubic symphysis and to determine whether it is arterial, venous, or both.

## MATERIAL AND METHODS

54 cadaver halves of 27 cadavers (25 male; 2 female) were dissected to determine the occurrence and location of the corona mortis. A vertical incision was made splitting the rectus abdominis muscles. The rectus abdominis muscle was released from the pubic symphysis and reflected laterally. The dissection proceeded laterally along the superior surface of the pubic ramus from the insertion of the rectus abdominis muscle toward the external iliac artery. All vessels were identified as arterial or venous and isolated. After completion of the dissection and identification of all vessels, the distance of each was measured from the pubic symphysis and from the arch of the lacunar ligament. Additionally, the dis-

tance from the lacunar ligament to the anastomotic vessels was also measured.

## RESULTS

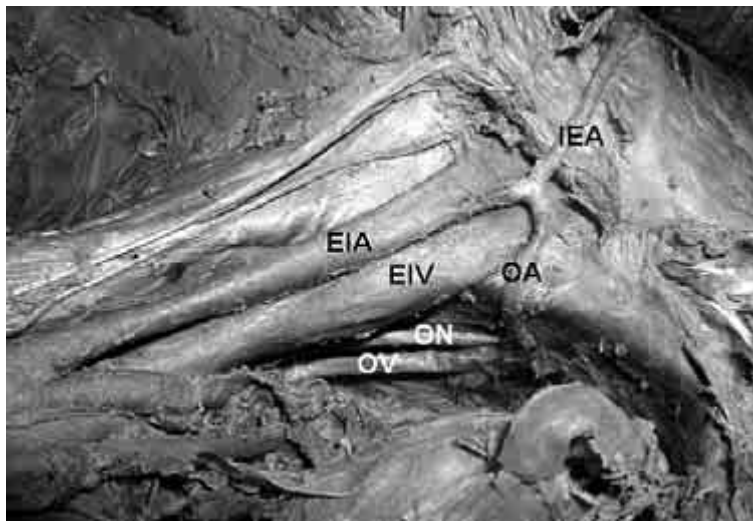
The results of the present study were summarised as follows (Table 1).

All the instances of venous corona mortis were observed in male cadavers. This vessel coursed vertically behind the superior pubic ramus and connected to the obturator vein. This connection was located in the obturator foramen. There was no connection outside the obturator foramen.

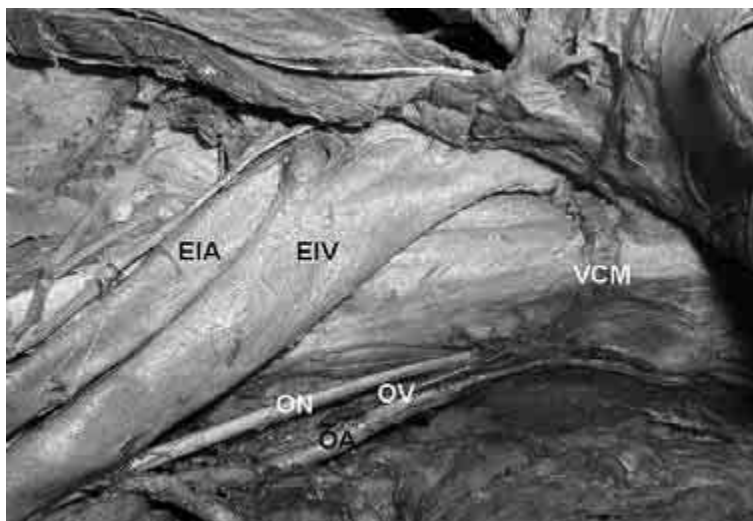
The origin of the obturator artery from the inferior epigastric artery (Fig. 2) was observed in 8 halves (14.81%) In the remaining 46 halves (85.19%) the

**Table 1.** Results of the study

	Halves	
Arterial corona mortis	–	0%
Venous corona mortis (Fig. 1)	11	20.37%
Both	–	0%
No anastomosis	43	79.63%



**Figure 1.** Venous corona mortis; EIA — external iliac artery, EIV — external iliac vein, IEA — inferior epigastric artery, OA — obturator artery, ON — obturator nerve, OV — obturator vein.



**Figure 2.** Origin of the obturator artery from the inferior epigastric artery. VCM — venous corona mortis, EIA — external iliac artery, EIV — external iliac vein, OA — obturator artery, ON — obturator nerve, OV — obturator vein.

obturator artery originated from the internal iliac artery or from its tributaries.

It was found that in 41 halves (76.6%) the inferior epigastric artery originated from the external iliac artery 1.2–2.8 cm above the inguinal ligament. In 13 halves (22.2%), the artery originated from the femoral artery 0.8–1.6 cm below the inguinal ligament.

The distance between the pubic symphysis and the anastomotic vessels was  $39.79 \pm 11.42$  mm. The distance between the lacunar ligament and the anastomotic vessels was  $12.18 \pm 3.55$  mm.

## DISCUSSION

In the literature, there has been no consensus on corona mortis terminology. A small number of classical textbooks [4, 10, 11, 20] used the term "corona mortis" (crown of death). Additionally, some terms (accessory obturator vein, accessory obturator artery [7, 14], aberrant obturator artery [6, 12], and anomalous origin of the obturator artery from the external iliac artery [9]) were used to refer to the corona mortis. Besides these terminological descriptions, Bendavid [1] described a venous circulation network formed by the inferior epigastric, iliopubic, rectus, retro pubic, and communicating rectusopubic veins but did not mention the corona mortis.

The venous corona mortis is usually found in higher frequency than the arterial one [2, 13, 19]. The same finding was also observed in the present study. However, we did not observe any arterial corona mortis. Berberoglu et al. [2] found the venous corona mortis in all cases (14 cases) by anatomical examination, and in 34 of 36 cases by laparoscopic examination. Additionally, it was observed in 35 of 50 cases (70%) by Tornetta et al. [19] and in 26% by Missankov et al. [13]. In the present study, we found the frequency of venous corona mortis less than that reported by Berberoglu et al. [2], Tornetta et al. [19], and Missankov et al. [13]. Because a venous anastomosis is more probable than an arterial one, its importance needs to be appreciated by surgeons in order to avoid venous bleeding.

Since such vessels have a close relation to the lacunar ligament, we measured the average distance between the arch of the lacunar ligament and the anastomotic vessels and found this average to be  $12.18 \pm 3.55$  mm. There is no report of this measurement in the available literature. The distance from the pubic symphysis to the anastomotic vessels was reported as  $62 \pm 12$  mm by Tornetta et al. [19], as

40.4 mm by Berberoglu et al. [2]. We found it to have a lower average ( $39.79 \pm 11.42$  mm) than that reported by Tornetta et al. [19] and approximately the same as that of Berberoglu et al. [2].

Kuran [10], Last [11], and Williams et al. [20] noted that the anastomoses between the obturator branch of the inferior epigastric artery and the pubic branch of the obturator artery are sometimes thick and that injury to this connection may occur during operations for the strangulated femoral hernia. Although it was reported that anastomoses formed by such thick vessels may be hazardous, Odar [15] and Yildirim et al. [21] considered that tiny vessels of this kind constitute a risk.

It has been reported that the frequency of the origin of the obturator artery from the internal iliac artery is 3 to 1 compared with origin from the inferior epigastric artery and the external iliac artery [3]. We found this frequency to be approximately 7 to 1 (8 of 54 halves). Jakubowicz et al. [8] studied the variability in origin and topography of the inferior epigastric and the obturator arteries and found that in 3 out of 75 cases (4%) there was a common trunk for the inferior epigastric and the obturator arteries. Additionally, they reported that the obturator artery originated from the inferior epigastric artery in 2 out of 75 cases (2.6%), and in 1 out of 75 cases (1.3%) from the medial side of the external iliac artery. Berberoglu et al. [2] found in their anatomical study that the obturator artery originated from the inferior epigastric artery in 1 out of 14 cases and in their laparoscopic study in 3 out of 36 cases. Additionally, they found the obturator artery origin from the external iliac artery in 1 out of 14 cases in their anatomical study. In our previous report, we found in 1 case that the obturator artery originated from the external iliac artery accompanied by the venous corona mortis [17]. In the present study, we found the obturator artery originated from the inferior epigastric artery in 8 out of 54 cadaver halves (14.81%).

Missankov et al. [13] studied the variations in the arterial and venous pubic anastomoses and found that 44% of the arterial pubic anastomoses were replaced by an obturator artery arising from the inferior epigastric and 25% by an obturator artery arising from the external iliac artery.

The ilioinguinal approach is appropriate for all fractures including the anterior wall, anterior column, and anterior column with posterior hemitransverse extension. These vessels (arterial, venous or both) that form the corona mortis may be disrupted

as a result of superior pubic ramus fracture [16], and during ilioinguinal approach for acetabulum fractures. Additionally, the unstable pelvic fractures need to be fixed in order to avoid unexpected complications. During the ilioinguinal approach care must be taken of the corona mortis. Every surgeon dealing with direct, indirect, femoral, or obturator hernias, superior pubic ramus fractures, and acetabulum fractures needs to be aware of these anastomoses (arterial, venous, or both). If corona mortis presents, it should be ligated to prevent bleeding, which is difficult to control if it retracts into the pelvis [5, 9, 16, 18]. Additionally, the presence of the abnormal origin of the obturator artery should not be overlooked during these procedures.

### REFERENCES

1. Bendavid R (1992) The space of Bogros and the deep inguinal venous circulation. *Surg Gynecol Obstet*, 174: 355–358 (cited by Berberoglu et al., 2001).
2. Berberoglu M, Uz A, Ozmen MM, Bozkurt C, Erkan C, Taner S, Tekin A, Tekdemir I (2001) Corona mortis: an anatomic study in seven cadavers and an endoscopic study in 28 patients. *Surg Endosc*, 15: 72–75.
3. Bergman RA, Thompson SA, Afifi AK, Saadeh FA (1988) *Compendium of human anatomical variation*. Urban Schwarzenberg, Baltimore, pp. 40–41.
4. Crenshaw AH (1998) *Campbell's operative orthopaedics*. Mosby-year Book Inc, Philadelphia, pp. 2235–2237.
5. de Kleuver M, Kooijman MA, Kauer JM, Veth RP (1998) Pelvic osteotomies: anatomic pitfalls at the pubic bone. A cadaver study. *Arch Orthop Trauma Surg*, 117: 270–272.
6. Fujimoto H, Naito H, Terauchi M (2001) Skin rash in the hypogastric region during a regional chemotherapy for bladder carcinoma: CT and scintigraphic demonstration of a potential collateral pathway between the internal iliac and inferior epigastric arteries. *Eur Radiol*, 11: 1838–1840.
7. Gosling JA, Harris PF, Humpherson JR, Whitmore I, Wilian PLT (1985) *Atlas en couleur d'anatomie humaine*. Medsi (Medicine et sciences internationales), Paris, pp. 5.18.
8. Jakubowicz M, Czarniawska-Grzesinska M (1996) Variability in origin and topography of the inferior epigastric and obturator arteries. *Folia Morphol (Warsz)*, 55: 121–126.
9. Jimenez ML, Vrahas MS (1997) Surgical approaches to the acetabulum. *Orthop Clin North Am*, 28: 419–434.
10. Kuran O (1983) *Sistematik anatomi*. Filiz kitabevi, Istanbul, pp. 306.
11. Last RJ (1984) *Anatomy. Regional and applied*. Churchill Livingstone, Edinburgh, pp. 342.
12. Marsman JW, Schilstra SH, van Leeuwen H (1984) Angiography and embolization of the corona mortis (aberrant obturator artery). A source of persistent pelvic bleeding. *ROFO Fortschr Geb Rontgenstr Nuklearmed*, 141: 708–710.
13. Missankov AA, Asvat R, Maoba KI (1996) Variations of the pubic vascular anastomoses in black South Africans. *Acta Anat*, 155: 212–214.
14. Moore KL (1992) *Clinically oriented anatomy*. Williams & Wilkins, Baltimore, pp. 260.
15. Odar I (1984) *Anatomi*. Ankara University press, Ankara, pp. 453.
16. Routt ML Jr., Simonian PT, Swiontkowski MF (1997) Stabilization of pelvic ring disruptions. *Orthop Clin North Am*, 28: 369–388.
17. Sarikcioglu L, Sindel M (2002) Multiple vessel variations in the retropubic region. *Folia Morphol (Warsz)*, 61: 43–45.
18. Skandalakis LJ, Androulakis J, Colborn GL, Skandalakis JE (2000) Obturator hernia. Embryology, anatomy, and surgical applications. *Surg Clin North Am*, 80: 71–84.
19. Tornetta P, Hochwald N, Levine R (1996) Corona mortis. Incidence and location. *Clin Orthop*, 329: 97–101.
20. Williams PL, Warwick R, Dyson M, Bannister HL (1995) *Gray's anatomy*. Churchill Livingstone, Edinburgh, pp. 1550.
21. Yildirim M, Ozturk A, Sahinoglu K, Pestemalci T, Turut M, Kutoglu T (1996) A. epigastrica inferior orijinli a. obturatoria olgulari. *Morfoloji Dergisi*, 4: 56–58.