

Analysis of the relationship between the inner structure and the magnitude of atherosclerotic plaques

Maria Bogdan¹, Jacek Kubica¹, Elena Weber², Marek Radomski¹, Adam Sukiennik¹, Grzegorz Grzešek¹, Waclaw Kochman³, Anna Jachalska¹, Grzegorz Raczak², Dariusz Kozłowski², Marcin Rychter¹, Mirosław Jabłoński¹

¹Department of Cardiology and Internal Medicine, Medical University, Bydgoszcz, Poland

²2nd Department of Cardiology, Medical University Gdańsk, Poland

³Department of Invasive Cardiology, Medical University, Białystok, Poland

[Received 26 August 2003; Revised 11 November 2003; Accepted 11 November 2003]

The aim of this study was ultrasound evaluation of atherosclerotic plaque morphology in relation to the degree of coronary artery lumen narrowing in patients with ischaemic heart disease.

Intravascular ultrasound was performed on 38 patients (30 men and 8 women) aged 35 to 77 (average age 60 ± 11 years old) with symptoms of ischaemic heart disease. The structure of atherosclerotic plaques with a degree of lumen narrowing of $< 50\%$ (1st group) was distinctly different from the structure of plaques with a degree of lumen narrowing of $50\text{--}75\%$ (2nd group, $p = 0.0045$) and the structure of plaques with a degree of lumen narrowing of $\geq 75\%$ (3rd group, $p < 0.001$). The incidence of soft plaques decreased, whereas the percentage of mixed and hard plaques increased gradually with the increase in the degree of artery lumen narrowing. Significant differences in the incidence of plaque calcification were observed between the groups evaluated with cross-sections of different degrees of lumen narrowing ($p = 0.0032$). The smallest number of calcifications was discovered in the 1st group as compared to the 2nd ($p = 0.0027$) and the 3rd group ($p = 0.0026$).

With a higher degree of lumen narrowing, a lower percentage of eccentric plaques and a higher percentage of concentric plaques were observed. There were more eccentric plaques and fewer concentric plaques in cross-sections of the 1st group as compared to the 2nd group ($p = 0.0056$) and the 3rd group ($p = 0.0018$). A comparison between the 2nd and 3rd groups showed no significant difference in the incidence of eccentric or concentric plaques ($p = 0.5$).

In conclusion, intravascular ultrasound evaluation revealed significant relationships between the structure, presence of calcifications and location of atherosclerotic plaques and the degree of artery lumen narrowing. The incidence of mixed, hard, calcified and concentric plaques increased, whereas the percentage of soft, non-calcified and eccentric plaques decreased gradually with the increase in the degree of artery lumen narrowing.

key words: intravascular ultrasound, coronary arteries, ischaemic heart disease, artery lumen narrowing

INTRODUCTION

Developments in methods of treatment of coronary heart disease have necessitated the search for new modes of artery imaging, allowing for diagnosis as well as a better recognition of the mechanisms of the creation and development of atherosclerotic plaques. From the moment of introduction of intravascular ultrasound (IVUS) into clinical practice *in vivo* assessment of the artery lumen and the structure of vessel wall has been possible.

The aim of this study was ultrasound evaluation of atherosclerotic plaque morphology in relation to the degree of coronary artery lumen narrowing in patients with ischaemic heart disease.

MATERIAL AND METHODS

Intravascular ultrasound was performed in 38 patients (30 men and 8 women) aged 35 to 77, average age 60 ± 11 years old, with symptoms of ischaemic heart disease and scheduled for percutaneous transcatheter revascularisation on the basis of the results of coronary angiography. Ultrasound images were obtained using the intravascular ultrasound system Oracle In-vision with ultrasound catheters Visions Five-64 F/X™ by Endosonics (USA).

The morphology and size of atherosclerotic plaques were analysed in cross-sections of coronary arteries. Examinations of the cross-sections of each coronary artery were performed in individual artery segments. A segment was defined as a section of artery between the two closest side branches or between the ostium of the coronary artery and the first branch. For each segment, at least 3 cross-sections were examined. Ultrasound quantitative and qualitative analysis was performed according to the recommendations of the Study Group on Intracoronary Imaging of the Working Group of Coronary Circulation and of the Subgroup on Intravascular Ultrasound of the Working Group of Echocardiography of the European Society of Cardiology [4].

Quantitative analysis

In each of the cross-sections examined the following quantitative parameters were evaluated:

- TA (total area) — total area of artery cross-section — area limited by outer elastic membrane;
- LA (lumen area) — artery lumen area — area limited by inner elastic membrane.

The areas were measured planimetrically by a computer after manual outlining on the monitor.

On the basis of the planimetric measurements the following parameters were calculated:

- PA (plaque area) — atherosclerotic plaque area — the difference between TA and LA;
- PA% — percentage of total cross-section area occupied by atherosclerotic plaque, identical with the degree of cross-section lumen narrowing [4, 5]. This is calculated according to the following formula:

$$PA\% = \frac{TA - LA}{TA} \times 100\%$$

- EI (eccentricity index) — the ratio of plaque thickness at its thinnest part to its thickness in the opposite wall of the artery. The plaque was qualified as eccentric when $EI < 0.5$ and as concentric when $EI \geq 0.5$.

Analysis of the structure of atherosclerotic plaque

The ultrasound evaluation of the atherosclerotic plaque structure is based on differences in the echogenicity of its elements [2, 4, 5, 7, 9, 10, 16]. According to the commonly accepted division [4], the examined plaques were classified according to their structure in the following way:

- soft atherosclerotic plaques of low echogenicity — more than 80% homogenous of echogenicity lower than that of adventitia; histologically — changes rich in lipids (Fig. 1);
- hard plaques of high echogenicity — more than 80% homogenous of echogenicity higher than that of adventitia, histologically — built mostly of dense connective tissue rich in collagen (Fig. 2);
- mixed plaques, heterogeneous, including elements of low and high echogenicity, without advantage (> 80%) of one type over the other (Fig. 3).

The occurrence of calcifications in atherosclerotic plaques was also evaluated. Calcifications in IVUS

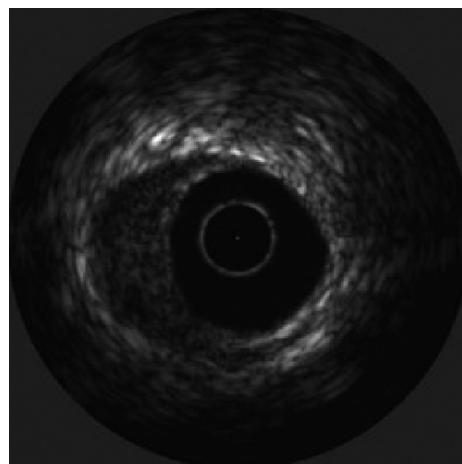


Figure 1. Soft plaque.

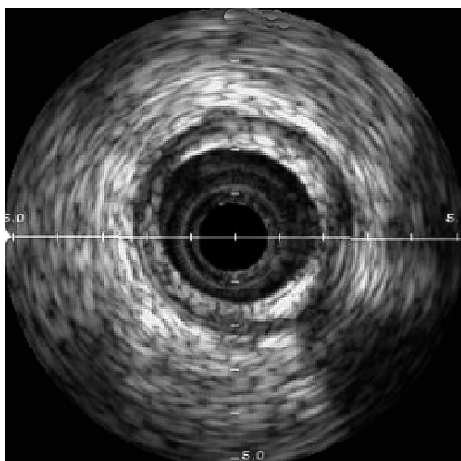


Figure 2. Hard plaque.

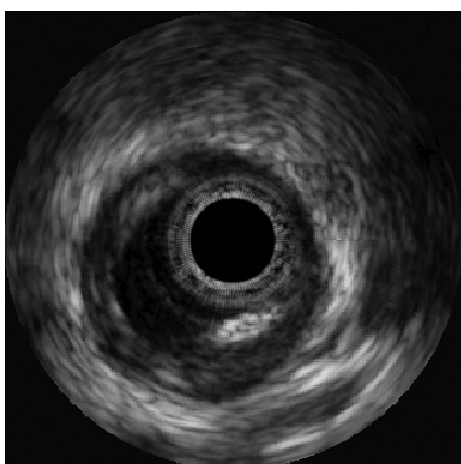


Figure 3. Mixed plaque.

are visible as bright spots of high echogenicity with characteristic acoustic shadow. Depending on the occurrence of calcification, plaques were divided into:

- calcificated plaque;
- non-calcificated plaque.

After performing quantitative and qualitative analysis, cross-sections were divided into three groups depending on the degree of their lumen narrowing (PA%):

- 1st group: PA% < 50%;
- 2nd group: 50% ≤ PA% < 75%;
- 3rd group: PA% ≥ 75%.

Differences between the cross-section groups in the morphology of atherosclerotic plaques were analysed.

Statistic analysis

Statistic analysis was performed based on accepted methods with the use of *Stata* statistics software (version 6.0; 1999).

RESULTS

Among the 38 patients investigated 25 (66%) had hypercholesterolaemia, 14 (37%) arterial hypertension, 8 (21%) type 2 diabetes mellitus and 22 (58%) were smokers. Twenty seven patients (71%) had at least two risk factors of coronary artery disease. Stable angina pectoris was diagnosed in 16 (42%) and unstable angina in 22 (58%) patients. The number of cross-sections in the 1st, 2nd and 3rd. groups was 48, 66 and 45 respectively. The mean degree of lumen narrowing in the listed groups was 40 ± 6%, 60 ± 6% and 84 ± 6%.

The total number of atherosclerotic plaques investigated was 159. On the basis of the IVUS criteria, 72 (45%) plaques were described as soft, 72 (45%) as mixed and 15 (10%) as hard. Calcifications were found in 72 (45%) of them. The spatial distribution of atherosclerotic plaques in the artery wall was estimated on the basis of an eccentricity index. 65% of plaques were classified as eccentric and 35% as concentric.

Analysis of the structure of the atherosclerotic plaques

The structure of atherosclerotic plaques with a degree of lumen narrowing of < 50% was distinctly different from the structure of plaques with a degree of lumen narrowing of 50–75% (p = 0.0045) as well as the structure of plaques with a degree of lumen narrowing ≥ 75% (p < 0.001). Significant differences in the structure of atherosclerotic plaques were also discovered between cross-sections of lumen narrowing 50–75% and ≥ 75% (p = 0.0069). The incidence of soft plaques decreased, whereas the percentage of mixed and hard plaques increased gradually with the increase in the degree of artery lumen narrowing (Fig. 4).

These results were confirmed in the model of multiple logistic regression. In the 3rd group of cross-

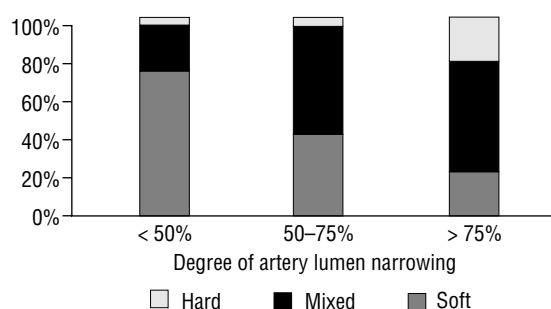


Figure 4. Structure of atherosclerotic plaques depending on the degree of artery lumen narrowing.

sections the probability of the incidence of soft plaques was lower than in cross-sections < 50% (odds ratio 0.11; 95% confidence interval from 0.36 to 0.35; $p < 0.001$). In cross-sections with lumen narrowing degree $\geq 75\%$ and 50–75% the probability of mixed plaque incidence was essentially higher than in cross-sections with a degree of lumen narrowing of < 50% (odds ratio 3.48; 95% confidence interval from 1.38 to 8.77; $p = 0.008$). In the 3rd group of cross-sections the probability of hard plaque incidence was higher than in the 2nd and 1st groups (odds ratio 6.69; 95% confidence interval from 1.43 to 31.28; $p = 0.016$).

Analysis of atherosclerotic plaques calcifications

Significant differences in the incidence of plaque calcifications were observed between the groups of cross-sections with different degree of lumen narrowing ($p = 0.0032$). The smallest number of calcifications was discovered in the 1st cross-section group compared to the 2nd ($p = 0.0027$) and 3rd groups ($p = 0.0026$). On the other hand, the discrepancies in the incidence of plaque calcifications between the 2nd and 3rd groups did not reach the adopted significance degree ($p = 0.37$) (Fig. 5).

The incidence of calcifications depended also on the structure of the atherosclerotic plaques. Calcifications were most often discovered in hard (73%) and mixed plaques (61%). Only 24% of soft plaques contained calcifications. The difference between hard and mixed was not significant, whereas discrepancies between soft and hard plaques ($p < 0.0001$) as well as between soft and mixed plaques ($p = 0.0006$) were statistically significant.

Analysis of spatial distribution of atherosclerotic plaques

Significant statistical discrepancies were noted in the incidence of eccentric and concentric plaques

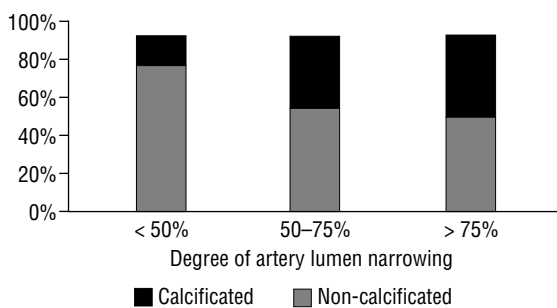


Figure 5. Incidence of atherosclerotic plaques calcifications depending on the degree of artery lumen narrowing.

depending on the degree of artery lumen narrowing ($p = 0.0046$). The higher the degree of lumen narrowing, the lower the percentage of eccentric plaques and the higher that of concentric plaques observed. There were more eccentric plaques and fewer concentric plaques in cross-sections of the 1st group as compared to the 2nd group ($p = 0.0056$) and the 3rd group ($p = 0.0018$). Comparison between the 2nd and 3rd groups showed no significant difference in the incidence of eccentric or concentric plaques ($p = 0.5$) (Fig. 6).

Soft plaques were eccentric in most cases — 78% (56/72). Eccentric soft plaques were relatively fewer than eccentric mixed plaques — 57% (41/72) ($p = 0.007$) or eccentric hard plaques — 40% (6/15) ($p = 0.008$). Differences in the incidence of eccentric and concentric plaques between groups of mixed and hard plaques were not significant ($p = 0.2$).

In the model of multiple logistic regression the results obtained were confirmed. The increase in the degree of artery lumen narrowing was related to the decrease in the probability of incidence of eccentric plaques and the increase in the probability of incidence of concentric plaques. The greatest probability for the incidence of eccentric changes was characteristic for cross-sections with a degree of lumen narrowing of up to 50%. Significantly fewer eccentric plaques were found in cross-sections with more severe stenoses belonging to the 2nd and 3rd groups. For cross-sections of the 3rd group compared to the 1st group, the odds ratio was 0.31; 95% confidence interval from 0.10 to 0.91; $p = 0.034$. For cross-sections from the 2nd group in comparison to the 1st group the odds ratio was 0.34; 95% confidence interval from 0.13 to 0.92; $p = 0.034$.

Hard plaques were concentric in most cases. The probability of discovering eccentric hard plaques as opposed to eccentric soft plaques was low, the odds ratio being 0.16; 95% confidence interval from 0.004 to 0.6; $p = 0.007$.

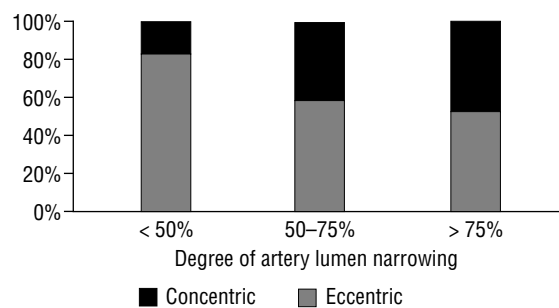


Figure 6. Spatial placing of atherosclerotic plaques depending on the degree of artery lumen narrowing.

DISCUSSION

With the progress of arteriosclerosis the inner structure of atherosclerotic plaques changes. This has been proved by extensive research, which has led to the creation of a histological division of plaques recommended by the Committee on Vascular Lesions of the Council of Arteriosclerosis, the American Heart Association [7]. The results of the ultrasonographic analysis of the morphology of atherosclerotic plaque correlate with this classification.

Most of the plaques in the 1st group of cross-sections (narrowing of the artery lumen up to 50%) were characterised by low echogenicity (soft plaques). Plaques of this type of structure correspond to type I–IV according to the histological classification of AHA [2, 4, 9–11, 13–15, 17, 18].

Early atherosclerotic changes do not narrow the lumen and do not restrict blood flow. Thus such plaques may be invisible in coronary angiography or may only cause luminal irregularities [5, 17].

The degree of lumen narrowing in the 1st group of cross sections amounted to $40 \pm 6\%$ average. Such plaques are usually invisible in coronary angiography. This has been proved by IVUS studies in sections of arteries free from narrowing in angiography [6, 11, 12]. Mintz et al. [12], using ultrasonography, revealed plaques that narrow vessel lumen up to $21 \pm 12.7\%$ average in sections without narrowing in angiography. Most of these plaques were classified as soft. In a paper published by Kubica [11] coronary lumen narrowing assessed by IVUS amounted to $42 \pm 12\%$ average in angiographically healthy vessel segments. Soft plaques were found in half of these segments (53%) and only in 4% were hard plaques found [11]. Erbel et al. [5] similarly discovered atherosclerotic plaques in 54% of coronary segments free from narrowings in angiography. These plaques caused the narrowing of lumen to $38 \pm 8\%$ average as assessed by IVUS. The majority of plaques (over 90%) were classified according to AHA as type II, III (early atherosclerotic plaque), type IV (atheroma), and type Va (fibroatheroma) [5].

In the 1st group of cross-sections atherosclerotic plaques were most often characterised by eccentric placing on the perimeter of the artery wall (83%). This constitutes an additional proof that the plaques narrowing lumen up to 50% are “young” in the majority of cases. The eccentric character of type IV plaques were described by Stary et al., the authors of the histological classification of atherosclerotic plaques [17]. Erbel et al. [5], classifying plaques according to the histological division (AHA classifica-

tion), also underline the eccentric character of type I–IV plaques.

At an early stage of their development, atherosclerotic plaques rarely contain calcifications [17]. The results obtained in this work confirmed this thesis, since calcifications in this group occurred the least frequently.

In cross-sections with lumen narrowing of between 50–75% (2nd group) 55% of atherosclerotic plaques were classified as mixed, 41% as soft and 4% as hard.

Plaque of mixed echogenicity corresponds to the more advanced changes of type V and VI in the histological classification of AHA [17]. Type V contains subtypes Va (fibroatheroma), Vb (calcificated plaque), and Vc (fibrotic plaque). Type VI plaque includes complicated changes, fissured or ulcerated, with inner haematoma or thrombus [1, 3, 17, 19].

The majority of the 41% of the soft changes found in the 2nd group of cross-sections are plaques of type IV or Va. One cannot rule out the fact that some of the soft plaques may be “fresh” thrombus. Hard plaques, on the other hand, are probably changes of type Vc. These observations are in accordance to observations by Erbel et al. [5].

Assuming that arteriosclerosis begins at certain spots on the artery wall, then the concentric nature of changes may mean that the process is more advanced. In cross-sections of the 2nd group the occurrence of concentric plaques was twice as great (42% compared to 17% in the 1st group). This was especially true of mixed and hard plaques (types V and VI according to AHA). Erbel et al. [5] concluded that advanced plaques of type V and VI might be both eccentric and concentric. In the anatomopathological study of Hargartner et al. [8] in cross-sections of coronary arteries with lumen narrowing of 50–75% concentric changes were discovered in 56% of cases, more frequently than in this research.

Plaques from the 2nd group of cross-sections contained double the amount of calcifications as compared to the 1st group. Calcifications and an increased content of connective tissue reflect degenerative changes occurring in the plaques [17]. Calcifications were found in atherosclerotic lesions of all types, especially in hard and mixed plaques. The results obtained are in accordance with research published earlier [11]. It was assumed in this study, that plaques occurring in the 2nd group of cross-sections can mostly be classified to type V or VI according to histological AHA classification [17].

Arteriosclerotic lesions narrowing lumen $\geq 75\%$ in 78% were classified as mixed or hard. In cross-sections of the 1st and 2nd groups plaques of this type have been discovered in 27% and 59% of cases respectively. Plaques discovered in the 3rd group of cross-sections (similarly to the plaques discussed as occurring in the 2nd group of cross-sections) may relate to type V and VI changes according to AHA classification [17]. The higher advancement of changes in the 3rd group as compared to the 2nd group is shown in the higher degree of lumen narrowing as well as the nominally higher occurrence of hard plaques. Hard plaques, with fibrosis, relate to subtype Vc. It is assumed that hard plaques are created from soft plaques in which, due to degenerative or reconstructive processes, connective tissue or calcifications occur [3, 17]. Mixed plaques may present the intermediate stage on the way between soft and hard plaques. These may also be complicated plaques.

Plaque causing lumen narrowing $\geq 75\%$ in ultrasonographic images are often the reason for significant narrowings in angiography.

In the paper published by Erbel et al. [5] the degree of lumen narrowing in IVUS was between $66 \pm 9\%$ average to $72 \pm 13\%$ in artery sections significantly narrowed in angiographic images. The authors classified these plaques as type IV–VI according to the histological classification of AHA.

Kubica [11] ultrasonographically analysed the structure of atherosclerotic plaques in several groups of coronary artery sections selected on the basis of angiographic images. The author showed that among all the groups of sections analysed the largest percentage, in relative terms, of hard plaques and the lowest of soft plaques was noted in sections with significant narrowing qualified for percutaneous interventions. The results of the present study were similar. In cross-sections with significant narrowing (the 3rd group) hard plaques occurred most frequently, whereas soft plaques less frequently as compared to the 1st and 2nd group. The same rule was observed by Mintz et al. [12]. Plaques causing narrowing of artery lumen in IVUS by an average of 85% were more frequently fibrotic (hard) than plaques causing lumen narrowing by an average of around 51%, which were nominally more frequently soft. Similar observations based on post mortem examination of coronary arteries were reported by Hargartner et al. [8]. In cross-sections with the degree of lumen narrowing $\geq 75\%$ (calculated by microscopic planimetry), 76% of plaques were de-

scribed as concentric and as many as half of concentric plaque was fibrotic [8].

In conclusion, intravascular ultrasound evaluation revealed significant relationships between structure, the presence of calcifications, the location of atherosclerotic plaques and the degree of artery lumen narrowing. The incidence of mixed, hard, calcified and concentric plaques increased, whereas the percentage of soft, non-calcified and eccentric plaques decreased gradually with the increase in the degree of artery lumen narrowing.

REFERENCES

1. Badimon J, Fuster V, Chesebro J, Badimon L (1993) Coronary atherosclerosis a multifactorial disease. *Circulation*, 87 (Suppl. II): II3–II16.
2. Coy K, Maurer G, Siegel R (1991) Intravascular ultrasound imaging: a current perspective. *J Am Coll Cardiol*, 18: 1811–1823.
3. Davies M (1998) Atlas of coronary artery disease. Lippincott-Raven Publishers. New York.
4. Di Mario C, Gorge G, Peters R, Kearney P, Pinto F, Hausmann D, von Birgelen C, Colombo A, Mudra H, Roelandt J, Erbel R, on behalf of the Study Group on Intracoronary Imaging of the Working Group of Coronary Circulation and of the Subgroup on Intravascular Ultrasound of the Working Group of Echocardiography of the European Society of Cardiology (1998) Clinical application and image interpretation in intracoronary ultrasound. *Eur Heart J*, 19: 207–229.
5. Erbel R, Ge J, Gorge G, Baumgart D, Haude M, Jeremias A, von Birgelen C, Jollet N, Schwedtmann J (1999) Intravascular ultrasound classification of atherosclerotic lesions according to American Heart Association recommendation. *Cor Art Dis*, 10: 489–499.
6. Ge J, Erbel R, Gerber T, Gorge G, Koch L, Haude M, Meyer J (1994) Intravascular ultrasound angiographically normal coronary arteries: a prospective study in vivo. *Br Heart J*, 71: 572–578.
7. Gussenchouwen E, Esses E, Lancee C, Mastik F, Fritman P, van Egmond F (1989) Arterial wall characteristics determined by intravascular ultrasound imaging: an in vivo study. *J Am Coll Cardiol*, 14: 947–952.
8. Hangartner J, Charleston A, Davies M, Thomas A (1986) Morphological characteristics of clinically significant coronary artery stenosis in stable angina. *Br Heart J*, 56: 501–508.
9. Hodgson J, Reddy K, Suneja R, Nair R, Lesnefsky E, Sheehan H (1993) Intracoronary ultrasound imaging: correlation of plaque morphology with angiography, clinical syndrome and procedural results in patients undergoing coronary angioplasty. *J Am Coll Cardiol*, 21: 35–44.
10. Kimura B, Bhargava V, DeMaria A (1995) Value and limitations of intravascular ultrasound imaging in characterizing coronary atherosclerotic plaque. *Am Heart J*, 130: 386–396.
11. Kubica J (1998) Przydatność ultrasonografii wewnątrznaczyniowej w kardiologii inwazyjnej.

- Porównanie z badaniem angiograficznym. *Via Medica*, Gdańsk.
12. Mintz G, Painter J, Pichard A, Kent K, Satler L, Popma J, Chuang YC, Bucher TA, Sokolowicz LE, Leon MB (1995) Atherosclerosis in angiographically "normal" coronary artery referens segments: an intravascular ultrasound study with clinical correlations. *J Am Coll Cardiol*, 25: 1479–1485.
 13. Nitenberg A, Antoty I (1996) Epicardial coronary arteries are not adequately sized in hypertensive patients. *J Am Coll Cardiol*, 27: 115–123.
 14. Potkin B, Bartorelli A, Gessert J, Neville R, Almagor Y, Roberts W, Leon MB (1990) Coronary artery imaging with intravascular high-frequency ultrasound. *Circulation*, 81: 1575–1585.
 15. Rasheed Q, Dhvale P, Anderson J, Hodgson J (1995) Intracoronary ultrasound-defined plaque composition: computer-aided plaque characterization and correlation with histologic samples obtained during directional coronary atherectomy. *Am Heart J*, 129: 631–637.
 16. Sabate M, Kay I, de Feyter P, van Domburg R, Deshpande N, Ligthart J, Gijzel AL, Wardeh AJ, Boersma E, Serruys PW (1999) Remodeling of atherosclerotic coronary arteries varies in relation to location and composition of plaque. *Am J Cardiol*, 84:135–140.
 17. Stary H, Chandler B, Dinsmore R, Fuster V, Glagov S, Insull W, Rosenfeld ME, Schwartz CJ, Wagner WD, Wissler RW (1995) A definition of advanced types of atherosclerotic lesions and a histological classification of atherosclerosis. A report from the Committee on Vascular Lesions of the Council on Arteriosclerosis, American Heart Association. *Circulation*, 92: 1355–1374.
 18. Tobis J, Mallery J, Mahon D, Lehmann K, Zaleski P, Griffith J, Gessert J, Moriuchi M, Mc Rae M, Dwyer ML (1991) Intravascular ultrasound imaging of human coronary arteries *in vivo*. *Circulation*, 83: 913–926.
 19. Virmani R, Kolodgie F, Burke A, Farb A, Schwartz S (2000) Lessons from sudden coronary death. A comprehensive morphological classification scheme for atherosclerotic lesions. *Arteriosclerosis Thromb Vasc Biol*, 20: 1262–1275.