

A magnetic resonance volumetric study of the temporal lobe structures in depression

Joanna M. Moryś¹, Barbara Bobek-Billewicz², Jerzy Dziewiątkowski¹, Ilona Ratajczak¹, Piotr Pankiewicz³, Olgierd Narkiewicz¹, Janusz Moryś¹

¹Department of Anatomy and Neurobiology, Medical University, Gdańsk, Poland

²Department of Radiology, Medical University, Gdańsk, Poland

³Department of Psychiatry, Medical University, Poland

[Received 24 September 2003; Accepted 20 October 2003]

Depression is one of the most common psychiatric disorders and is associated with considerable morbidity. In recent years structural-imaging technology has provided an opportunity to examine the brain anatomy in patients with the psychiatric illness. 10 patients of various ages and, as the control group, 16 healthy subjects were examined using the MRI method of neuroimaging. The volumes of the following structures were evaluated in the right and left hemispheres: the superior temporal gyrus, the basolateral temporal area (the region including middle temporal gyrus, inferior temporal gyrus and fusiform gyrus), the parahippocampal gyrus, the hippocampal head, the amygdaloid body and the lateral ventricle. The significant difference between the control group and the group with depression concerned the volume of the temporal horn of the lateral ventricle of both hemispheres. In depressed patients the left temporal horn was 49.8% and the right 38.4% larger in comparison with the control group. In the control group there were significant differences between the left and right hemispheres in the volume of all the structures studied, whereas in the group with depression these difference in volume between the hemispheres concerned only the amygdaloid body and the lateral ventricle.

key words: temporal lobe, volumetric study, depression, MRI

INTRODUCTION

The development of neuroimaging techniques provides an opportunity to study the structure of brain in living patients suffering from major mental illnesses. The brain area that is the focus of attention and interest for researchers is the temporal lobe. For a long time the temporal lobe was associated with schizophrenia so there are many studies concerning structural abnormalities of the temporal lobe in this disease. [3–6, 8, 12, 14, 16]. Some authors found that structural brain changes observed in schizophrenia are also frequently seen in patients with affective disorder [15, 20, 25]. Affective disorder

is a very common psychiatric illness but its neuropathogenesis is still poorly understood. Because one of the leading symptoms of depression is mood dysregulation, the research has focused on the limbic structures, abnormalities of which can be possible neuroanatomic substrates of this illness. Neuroimaging findings for affective disorders include a smaller volume of the right hippocampus [26, 27], left amygdala [20] and temporal lobe [1], reduction of gray matter in the left temporal lobe [22, 23] and ventricular enlargement [26, 27]. Structures of the temporal lobe studied in each case are shown on Figure 1.

Address for correspondence: Joanna Moryś, Department of Anatomy and Neurobiology, Medical University, ul. Dębinki 1, 80–210 Gdańsk, Poland, e-mail: jmorys@amg.gda.pl

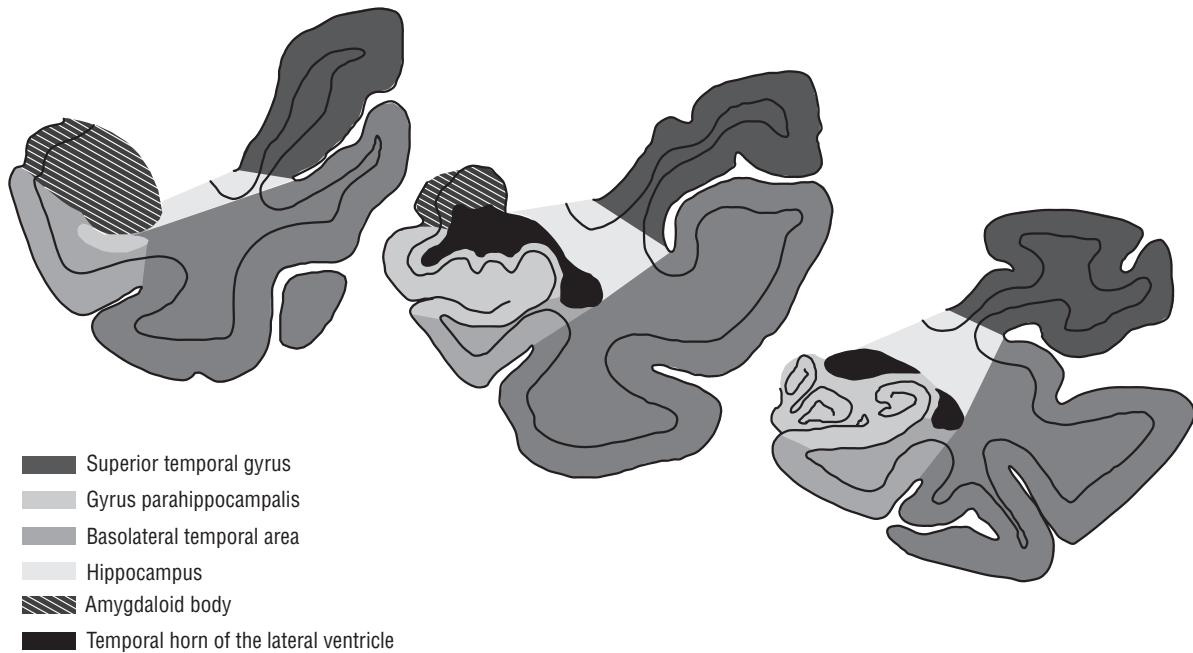


Figure 1. The structures studied on the coronal slices.

MATERIAL AND METHODS

The sample included consecutively recruited patients with a diagnosis of major depression from the Psychiatric Department of the Medical University of Gdańsk.

10 patients aged from 22 to 63 years (mean age 39.8) and 16 healthy subjects aged from 23 to 59 years (mean age 39.3) were examined using the MRI method of neuroimaging. The patients met the ICD-10 [7] criteria for major depression and MR images of their brains were used for evaluation of the volume of the temporal lobe structures. The control group consisted of healthy volunteers without any neurological symptoms of pathological change in the central nervous system and without any distinguishable signs on MR scans.

MR imaging

MRI was performed on an 0.5T superconducting MRI scanner (Gyrosan T5, Philips) with the use of a standard head coil. In the first step the whole brain was evaluated to rule out gross pathology.

The sagittal scout sequence was used to mark the coronal sequence perpendicular to the long axis of the hippocampus (T1W/3D/FFE, TR/TE/FA 30/13/3, Thk/gap 1/0 or 1.5/0, NSA 1).

Stereology

A stereological study was performed on coronal MR images perpendicular to the long axis of the hippocampus by the use of a semi-automatic method on an image analyser, Q500MC working under software QWin on Pentium 233 MHz with 17" SVGA monitor.

The following structures were studied within the space bordered by the anterior pole of the amygdaloid body and the posterior pole of the hippocampal head (Fig. 2): the superior temporal gyrus (STG), the basolateral temporal area (BTA — the region including the middle temporal gyrus, the inferior temporal gyrus and the fusiform gyrus), the parahippocampal gyrus (PAH), the hippocampus (HIP), the amygdaloid body (AA) and the lateral ventricle (LV). Delineations of all the studied structures were performed by a member of the group who is highly experienced in neuroanatomy (Fig. 3).

For the evaluation of the volumes of the structures the Cavalieri formula was applied and the coefficient of error (CE) of these values was calculated according to formulae proposed by Geinisman et al. [11]. The sampling was designed to obtain a CE smaller than 3%.

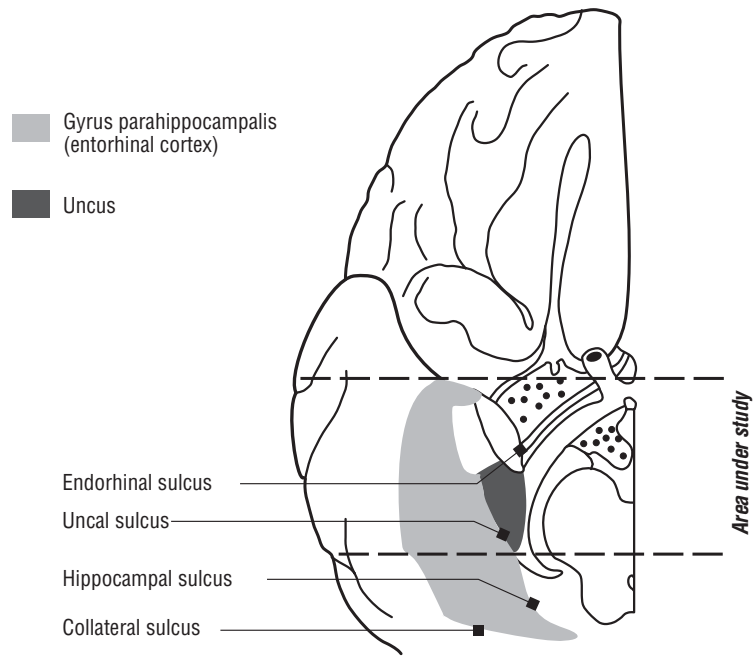


Figure 2. The areas of the temporal lobe under investigation; the ventral surface of the hemisphere.

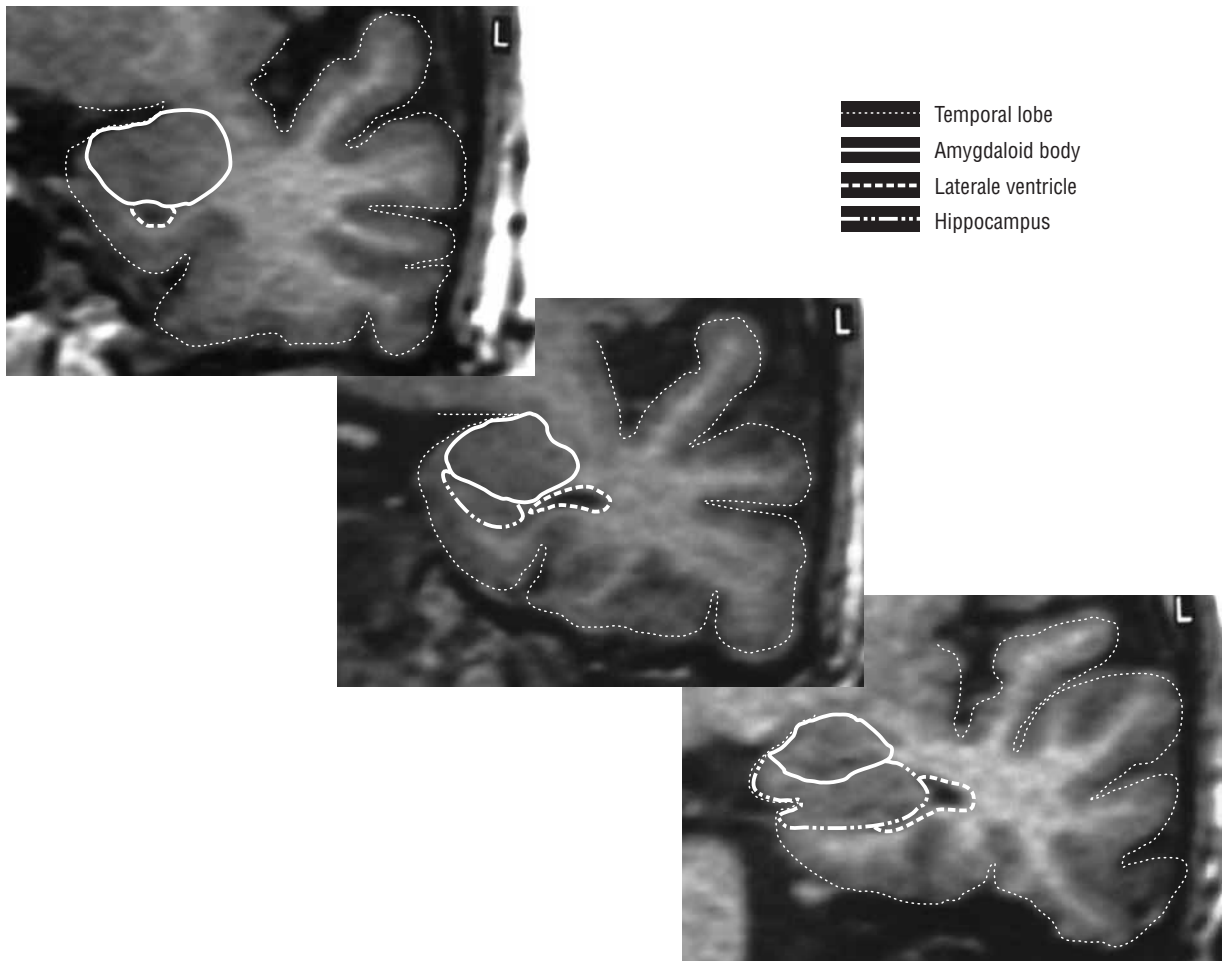


Figure 3. The structures of the temporal lobe measured on coronal MRI slices.

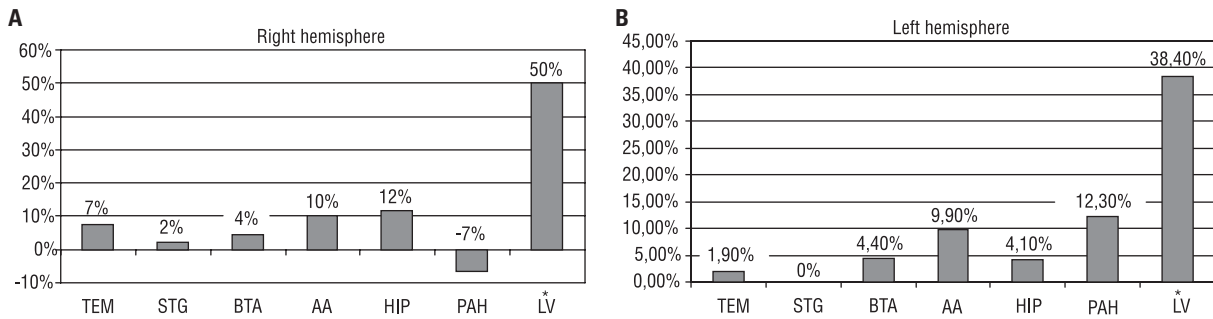


Figure 4. Differences between control group and the group with depression in volume of the structures studied in the right (A) and left (B) hemispheres; STG — superior temporal gyrus, BTA — basolateral temporal area (the region including middle temporal gyrus, inferior temporal gyrus and fusiform gyrus), PAH — parahippocampal gyrus, HIP — hippocampus, AA — amygdaloid body, LV — lateral ventricle; *difference statistically significant.

Statistics

For the statistical analysis of the volumetric changes of temporal lobe structures, ANOVA was used with repeated measures. The diagnosis of depression was the main effect for the evaluation. As a repeated measure — the side of the brain (interhemispheric asymmetry) was used. We have also tested the interaction between different factors. The effect of sex was not evaluated nor was the effect of age was not taken into consideration due to lack of significant differences between the groups ($p = 0.83$).

For each studied structure the quality of fit with normal distribution was checked by means of the Shapiro-Wilk test and the equality of variances by means of Bartlett's test. An analysis of variance was then followed by the *post-hoc* honest significant difference test (HSD) to study the differences between groups. In the case of non-normality and/or the presence of unequal variances, non-parametric analysis was used.

All calculations were carried out on spreadsheets, and statistics were drawn up using two packages (Statistica® v. 5.5, Statsoft, USA, and InStat®, Stat-Graph, USA). For all tests $p < 0.05$ was the level of significance.

RESULTS

The temporal horn of the lateral ventricle is the only structure of those studied, whose volume changed significantly in the group with depression in comparison to the control group. The left temporal horn of patients with depression was 49.8%, larger and the right — 38.4% ($p = 0.01$ and $p = 0.05$, respectively; Fig. 4) in comparison to that of control group. The difference between the left and right side of the ventricle horn was significant for both the

control group ($p = 0.001$) as well as the group with depression ($p = 0.005$), but the interaction effect was not significant.

The effect of the disease upon the volumes of the remaining structures of the temporal lobe (superior temporal gyrus, basolateral temporal area, parahippocampal gyrus, hippocampal head and amygdaloid body) was not significant either for the left or the right hemisphere. Significant differences were found between the hemispheres in the volumes of the structures studied (Fig. 5). Their volume in the control group differed significantly between right and left hemispheres. In contrast, in the group with depression a lack of significant difference was observed between the left and right hemispheres for almost all the structures. Only the amygdaloid body showed any significant difference in volume between hemispheres ($p = 0.005$) and this applied to both the control group and the group with depression.

DISCUSSION

We observed some significant differences in the volume of temporal lobe structures between patients with major depression and the control group. In the group with depression the significantly larger volume concerned the temporal horn of the lateral ventricle in both hemispheres. These could be related to a decrease in the volume of white matter of the temporal lobe. This observation corresponds to the results of Swayze et al. [26] who found a statistically significant increase in the size of the lateral ventricle in bipolar affective disorder. This increase was also found to be more marked in male patients. In spite of the fact that our material included many more female than male patients we observed the same phenomenon. Our study also confirms observations

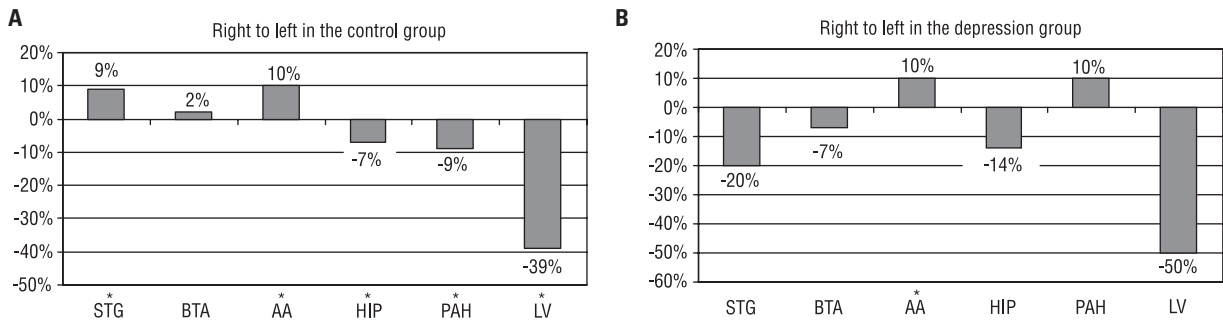


Figure 5. Differences between the right and left hemispheres in the volume of the structures studied in the control group (**A**) and the group with depression (**B**); STG — superior temporal gyrus, BTA — basolateral temporal area (the region including middle temporal gyrus, inferior temporal gyrus and fusiform gyrus), PAH — parahippocampal gyrus, HIP — hippocampus, AA — amygdaloid body, LV — lateral ventricle; *difference statistically significant.

of other researchers [2, 13, 19, 21, 24] that in patients with depression the ventricles are enlarged. However, Jacoby et al. [13] observing enlarged ventricles in patients whose the first episode of depression began later in life suggested that it could also be partly related to their age. Pearlson et al. [20], who studied the volumes of temporal gyri and cerebral asymmetry in schizophrenia and bipolar disorders, found that the values for the right anterior superior temporal gyrus and left amygdala differ from the control values.

In our study a left-right asymmetry in the volume of temporal lobe structures almost disappeared in patients with depression. It was maintained only in the amygdala and temporal horn of the lateral ventricle. That left-right asymmetry is related to cerebral lateralisation, as the temporal lobe is a region closely involved in language-related functions. Altshuler et al. [1] found a significant left-right asymmetry in the volume of the temporal lobes in both patients with bipolar depression and in controls, with the right temporal lobe being larger in both groups.

The only structure studied in our material that holds its left-right asymmetry in patients with depression is the amygdala. Strakowski et al. [25] observed enlargement of the amygdala in patients with bipolar disorder. This could be related to mood liability occurring in depression. Frodl et al. [9, 10] reported enlargement of amygdala volumes in patients in the first episode of major depression and this could be related to higher neural activity, higher metabolism and higher blood flow in the amygdaloid body. Other authors such as Mervaala et al. [17, 18] found that patients with drug-resistant major depression showed significantly smaller right versus left amygdala.

REFERENCES

1. Altshuler LL, Conrad A, Hauser P, Li XM, Guze BH, Denikoff K, Tourtellotte W, Post R (1991) Reduction of temporal lobe volume in bipolar disorder: a preliminary report of magnetic resonance imaging [letter]. *Arch Gen Psychiatry*, 48: 482–483.
2. Beats B, Levy R, Forstl H (1991) Ventricular enlargement and caudate hyperdensity in elderly depressives. *Biol Psychiatry*, 30: 452–458.
3. Bogerts B, Falkai P, Hapts M, Greve B, Ernst S, Taperon-Franz U, Heinzmann U (1990) Post-mortem volume measurements of limbic system and basal ganglia structures in chronic schizophrenics. Initial results from a new brain collection. *Schizophr Res*, 3: 295–301.
4. Bogerts B, Lieberman JA, Ashtari M, Bilder RM, Degreef G, Lerner G, Johns C, Masiar S (1993) Hippocampus-amygdala volumes and psychopathology in chronic schizophrenia. *Biol Psychiatry*, 33: 236–246.
5. Bogerts B, Meertz E, Schonfeldt-Bausch R (1985) Basal ganglia and limbic system pathology in schizophrenia. A morphometric study of brain volume and shrinkage. *Arch Gen Psychiatry*, 42: 784–790.
6. Brown R, Colter N, Corsellis JAN, Crow TJ, Frith CD, Jagoe R, Johnstone EC, Marsh L (1986) Postmortem evidence of structural brain changes in schizophrenia. Differences in brain weight, temporal horn area, and parahippocampal gyrus compared with affective disorders. *Arch Gen Psychiatry*, 43: 36–42.
7. Dąbrowski S (1994) Międzynarodowa Statystyczna Klasyfikacja Chorób i Problemów Zdrowotnych. Rewizja dziesiąta. Klasyfikacja zaburzeń psychicznych i zaburzeń zachowania w ICD-10. Badawcze kryteria diagnostyczne. Uniwersyteckie Wydawnictwo Medyczne „Vesalius”. Instytut Psychiatrii i Neurologii.
8. Falkai P, Honer WG, Alfter D, Schneider-Axmann T, Bussfeld P, Cordes J, Blank B, Schönell H, Steinmetz H, Maier W, Tepest R (2002) The temporal lobe in schizophrenia from uni- and multiply affected families. *Neurosci Lett*, 325: 25–28.
9. Frodl T, Meisenzahl E, Zetzsche T, Bottlender R, Born C, Groll C, Jäger M, Leinsinger G, Hahn K, Möller HJ (2002)

- Enlargement of the amygdala in patients with a first episode of major depression. *Biol Psychiatry*, 51: 708–714.
10. Frodl T, Meisenzahl EM, Zetzsche T, Born C, Jäger M, Groll C, Bottlender R, Leinsinger G, Möller HJ (2003) Larger amygdala volumes in first depressive episode as compared to recurrent major depression and healthy control subjects. *Biol Psychiatry*, 53: 338–344.
 11. Geinisman Y, Gundersen HJG, Van Der Zee E, West MJ (1996) Unbiased stereological estimation of the total number of synapses in a brain region. *J Neurocytol*, 25: 805–819.
 12. Gur RE, Turetsky BI, Cowell PE, Finkelman C, Maany V, Grossman RI, Arnold SE, Bilker WB, Gur RC (2000) Temporolimbic volume reductions in schizophrenia. *Arch Gen Psychiatry*, 57: 769–775.
 13. Jacoby RJ, Dolan RJ, Levy R, Baldy R (1983) Quantitative computed tomography in elderly depressed patients. *Br J Psychiatry*, 143: 124–127.
 14. Jeste DV, Lohr JB (1989) Hippocampal pathologic findings in schizophrenia. A morphometric study. *Arch Gen Psychiatry*, 46: 1019–1024.
 15. Jeste DV, Lohr JB, Goodwin FK (1988) Neuroanatomical studies of major affective disorders. A review and suggestions for further research. *J Psychiatry* 153: 444–459.
 16. Kovelman JA, Scheibel AB (1984) A neurohistological correlate of schizophrenia. *Biol Psychiatry*, 19: 1601–1621.
 17. Mervaala E, Fohr J, Kononen M, Valkonen-Korhonen M, Vainio P, Partanen K, Partanen J, Tiihonen J, Viinamaki H, Karjalainen AK, Lehtonen J (2000) Quantitative MRI of the hippocampus and amygdala in severe depression. *Psychol Med*, 30: 117–125.
 18. Mervaala E, Kononen M, Fohr J, Husso-Saastamoinen M, Valkonen-Korhonen M, Kuikka JT, Viinamaki H, Tammi AK, Tiihonen J, Partanen J, Lehtonen J (2001) SPECT and neuropsychological performance in severe depression treated with ECT. *J Affect Disord*, 66: 47–58.
 19. Pantel J, Schröder J, Essig M, Popp D, Dech H, Knopp MV, Schad LR, Eysenbach K, Backenstrab M, Friedlinger M (1997) Quantitative magnetic resonance imaging in geriatric depression and primary degenerative dementia. *J Affective Disord*, 42: 69–83.
 20. Pearlson GD, Barta PE, Powers RE, Menon RR, Richards SS, Aylward EH, Federman EB, Chase GA, Petty RG, Tien AY (1997) Medial and superior temporal gyral volumes and cerebral asymmetry in schizophrenia versus bipolar disorder. *Biol Psychiatry*, 41: 1–14.
 21. Pearlson GD, Rabins PV, Kim WS, Speedie LJ, Moberg PJ, Burns A, Bascom MJ (1989) Structural brain CT changes and cognitive deficits in elderly depressives with and without reversible dementia ('pseudodementia'). *Psychol Med*, 19: 573–584.
 22. Sheline YI, Sanghavi M, Mintun MA, Gado MH (1999) Depression duration but not age predicts hippocampal volume loss in medically healthy women with recurrent major depression. *J Neurosci*, 19: 5034–5043.
 23. Sheline YI, Wang PW, Gado MH, Csernansky JG, Vannier MW (1996) Hippocampal atrophy in recurrent major depression. *Proc Natl Acad Sci, USA* 93: 3908–3913.
 24. Shima S, Shikano T, Kitamura T, Masuda Y, Tsukumo T, Kanba S, Asai M (1984) Depression and ventricular enlargement. *Acta Psychiatr Scand*, 70: 275–277.
 25. Strakowski SM, DelBello MP, Sax KW, Zimmerman ME, Shear PK, Hawkins JM, Larson ER (1999) Brain magnetic resonance imaging of structural abnormalities in bipolar disorders. *Arch Gen Psychiatry*, 56: 254–260.
 26. Swayze VW, Andreasen NC, Alliger RJ, Ehrhardt JC, Yuh WT (1990) Structural brain abnormalities in bipolar affective disorder. Ventricular enlargement and focal signal hyperintensities. *Arch Gen Psychiatry*, 47: 1054–1059.
 27. Swayze VW, Andreasen NC, Alliger RJ, Yuh WTC, Ehrhardt JC (1992) Subcortical and temporal structures in affective disorders and schizophrenia: a magnetic resonance imaging study. *Biol Psychiatry*, 31: 221–240.