

The effect of angiogenesis inhibitor TNP-470 on the blood vessels of the lungs, kidneys and livers of treated hamsters

Andrzej Myśliwski¹, Jolanta Kubasik-Juraniec², Patrycja Koszałka³, Ewa Szmit¹

¹Department of Histology and Immunology, Medical University, Gdańsk, Poland

²Laboratory of Electron Microscopy, Medical University, Gdańsk, Poland

³Intercollegiate Faculty of Biotechnology, Medical University, Gdańsk, Poland

[Received 26 August 2003; Accepted 29 November 2003]

The growth of solid tumours and their metastases is dependent on the development of new blood vessels (angiogenesis). Therefore angiogenesis inhibitors are potential antitumour drugs.

In our previous studies it was found that the angiogenesis inhibitor TNP-470 given to transplantable melanoma-bearing hamsters can decrease the rate of the tumour growth, although the survival time of the animals treated was not significantly affected. It was found finally that TNP-470 given in the vicinity of the growing tumour can cause complete remission of the melanoma in hamsters treated in this way. To check what side-effects could be evoked by such treatment, an examination of the morphology of the blood vessels of the lungs, kidneys and livers of the treated animals was carried out. It was found that the angiogenesis inhibitor applied did not cause any changes which could be observed by light and electron microscopes in the structure of the examined blood vessels of the treated animals.

Key words: TNP-470, melanoma, hamsters, blood vessels

INTRODUCTION

It is well recognised that angiogenesis has essential significance for the growth of solid tumours [4, 5, 10]. Therefore many angiogenesis inhibitors have been examined as potential antitumour drugs. One of the most promising as a future antitumour drug appears to be the synthetic fumagilin analogue TNP-470 [3, 6–8]. In our previous studies on that compound we achieved some effect in the suppression of the growth of the transplantable melanoma in hamsters. The growth rate of this tumour was significantly decreased but the survival time of the tumour-bearing animals was prolonged only slightly [12, 13]. In our last published studies we found that TNP-470 given in the vicinity of a growing tumour can cause

complete remission of Bomirski Ab amelanotic melanoma and prevent the development of its metastases [14]. The success of such treatment for a fast-growing tumour that is able to kill a hamster in several weeks indicates that TNP-470 can be one of the most effective antitumour drugs. However, there is the problem of side-effects, which in the case of effective antitumour drugs is usually very serious. In our successful studies TNP-470 was given in the vicinity of a growing tumour, so the dose of this compound applied could be comparatively low. Even so, the systemic action of TNP-470 was inescapable. We therefore decided to test the effect of the strong antiangiogenesis inhibitor TNP-470 on the blood vessels of the lungs, kidneys and livers of the treated

Address for correspondence: Prof. Andrzej Myśliwski, Department of Histology and Immunology, Medical University, 80-210 Gdańsk, ul. Dębinki 1, Poland, tel: +48 58 349 14 30, fax: +48 58 349 14 36, e-mail: anmys@amg.gda.pl

hamsters. Since the action of TNP-470 was found to be directed at the endothelial cells [3, 9], our attention was mainly concentrated on the endothelium of the vessels examined.

MATERIAL AND METHODS

TNP-470 was the kind gift of Takeda Chemical Industries (Osaka, Japan). The chemical structure of the compound has been presented by Ingbar et al. [8].

Forty random-bred Syrian (golden) male hamsters were used in the study. They were obtained from the animal colony of the Silesian Medical University (Katowice, Poland) and maintained in our colony on a standard diet and water *ad libitum*. The care and treatment of the animals were in accordance with the "European Convention for the Protection of Vertebrate Animals Used for Experimental and Other Scientific Purposes". The study was approved by the Local Committee for Animal Experiments, Gdańsk, Poland.

Bomirski melanoma variant Ab was maintained by serial passage in the hamsters using the suspension method of tumour transplantation. The natural history and characteristics of this melanoma are described by Bomirski et al. [2]. The tumour cells were always implanted on the right flank of the animals by subcutaneous (s.c.) injection.

TNP-470 in a suspension vehicle composed of 1% ethanol and 5% Arabic gum in a saline was given s.c. at a dose of 30 mg/kg (about 3.9 mg/animal in 500 μ L of vehicle) in the vicinity of the palpable tumour every day for 21 days. The control tumour-bearing animals received injections of vehicle. All animals were sacrificed on the 28th day from the beginning of the experiment.

Sample preparation for histological examination

Small blocks of the organs under examination were put into a 4% formaldehyde solution in PBS. After being washed in water and dehydrated in ethanol, the tissue was embedded in paraffin. Sections of the examined tissues were stained with eosine and haematoxylin. Photographs were taken with a Nikon E800 microscope.

Sample preparation for the electron microscope

The hamsters were anaesthetised by an intraperitoneal injection of pentobarbital sodium (50 mg/kg). The animals were perfused transcardially with 50 ml of 0.9% saline containing 500 heparin units, and then perfused with a fixative composed of 4% paraformaldehyde and 1% glutaraldehyde in a 0.05 M phos-

phate buffer (pH 7.4) containing 0.03% CaCl₂. Blocks of tissues were rapidly removed and post-fixed in the same fixative overnight at 4°C. Next each specimen was briefly rinsed in a 0.1 M phosphate buffer containing CaCl₂ at room temperature, and then post-fixed for 1 hour in 1% osmium tetroxide. After being dehydrated in increasing concentrations of alcohol and propylene oxide, the specimens were embedded in Epon 812. The ultrathin sections were stained with uranyl acetate and lead citrate and examined with a JEM 1200EX II electron microscope.

RESULTS

Lungs

The structure of blood vessels of various sizes from hamsters, both healthy and tumour-bearing ones, which had been treated with TNP-470 did not differ when examined by light microscope from those of untreated animals (Fig. 1). Endothelial cells did not show any symptoms of histological lesions. Also the ultrastructure of the endothelial cells of the lung vessels from the treated hamsters was normal (Fig. 2).

Kidneys

The capillaries of the renal glomerules from animals treated with TNP-470 did not differ from those of the untreated animals, both under a light microscope (Fig. 3, 4) and under an electron microscope (Fig. 5, 6). The larger blood vessels also had a normal structure, both for the treated and the untreated animals.

Livers

The structure of the blood vessels of various sizes, lobular and interlobular (Fig. 7), from the livers of the treated animals was similar to those of the untreated animals and no symptoms of histological lesions were noticeable. The ultrastructure of the endothelium of the examined vessels also seemed to be normal (Fig. 8).

The presence of the tumour in animals had no effect on the structure of the vessels of the examined organs.

DISCUSSION

The results of our studies indicate that the angiogenesis inhibitor TNP-470, which is able to cause a complete remission of a fast-growing tumour, led neither to changes in the structure, nor probably the function, of the blood vessels of such important organs as the lungs, kidneys and livers. The period of treatment with TNP-470 was 21 days, which is short

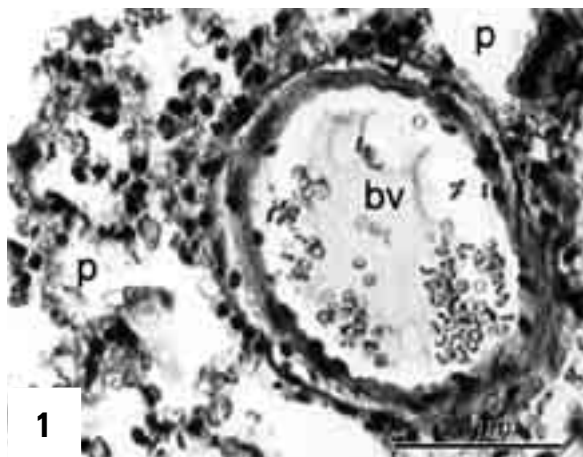


Figure 1. Lung of a melanoma-bearing hamster treated with TNP-470. Cross-section of a branch of the pulmonary artery. Both the endothelium and the thin media are normal in structure; bv — blood vessel, p — lung parenchyma. Staining with eosine and haematoxylin. Bar: 50 μ m.

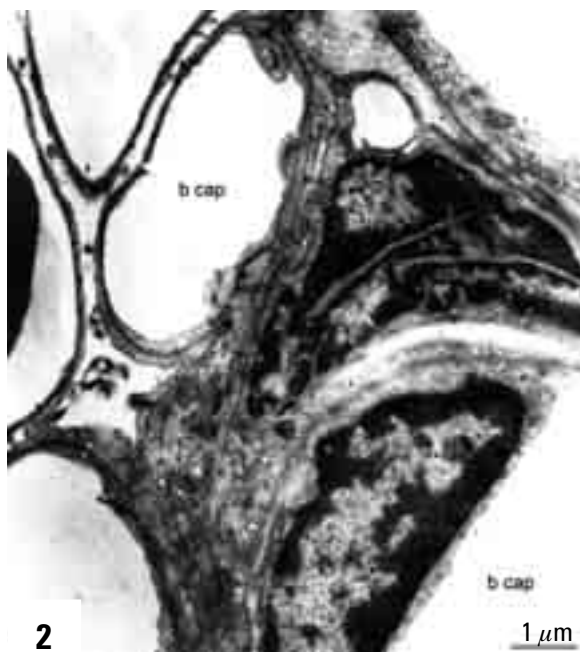


Figure 2. Lung of a melanoma-bearing hamster treated with TNP-470. Cross sections of blood capillaries (b cap) in the lung parenchyma. Blood capillaries demonstrate normal ultrastructure of the endothelium. Bar: 1 μ m.

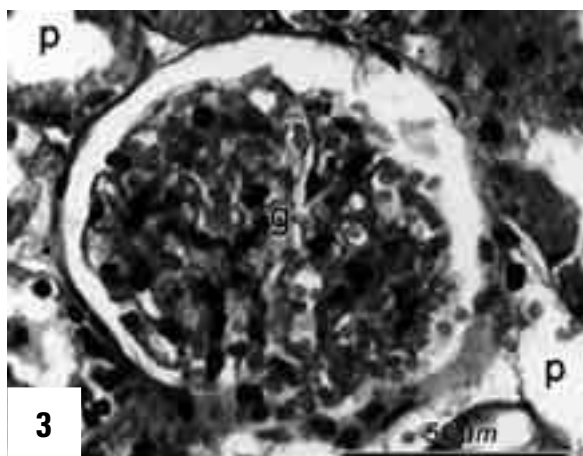


Figure 3. Renal corpuscle of the kidney of a melanoma-bearing hamster treated with TNP-470. Glomerular vessels have normal structure; g — renal glomerule, p — renal parenchyma. Staining with eosine and haematoxylin. Bar: 50 μ m.

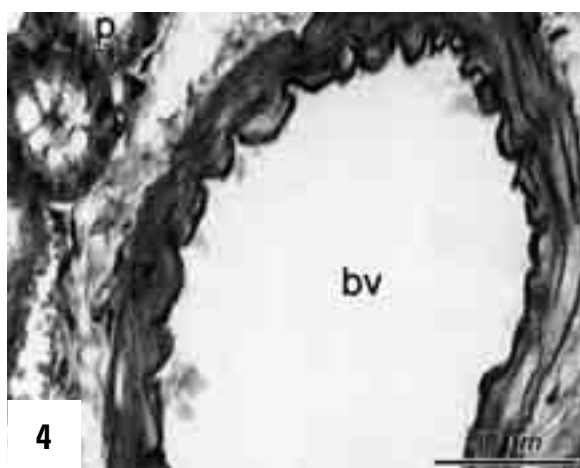


Figure 4. Blood vessel in the renal cortex of a melanoma-bearing hamster treated with TNP-470. Both endothelium and media demonstrate normal structure; bv — blood vessel, p — renal parenchyma. Staining with eosine and haematoxylin. Bar: 50 μ m.

in comparison to the duration of the administration of the antitumour drugs applied in oncology. This was, in any case, sufficient time for recovery for hamsters bearing transplantable melanoma. The good state of the structure of the endothelium and other parts of the blood vessel walls examined by light and electron microscopes did not preclude changes in the function of these vessels. However, if such changes had occurred, they were reversible, since the animals which survived treatment with TNP-470 were examined 5 months after the last injection of that drug and were found to be healthy [14]. The angiogenesis inhibitor TNP-470, therefore, appeared in our

studies to be both effective as an antitumour drug and harmless to the animals treated. These results were achieved with an animal model and, at present, it is difficult to make any claims as to whether such a good effect would be possible in humans. TNP-470 is already undergoing pre-clinical investigations [1, 6] but reports about the side-effects of such treatment



Figure 5. Renal corpuscle of the kidney of a healthy hamster; g cap — glomerular capillary, p — podocyte. Bar: 2 μm.

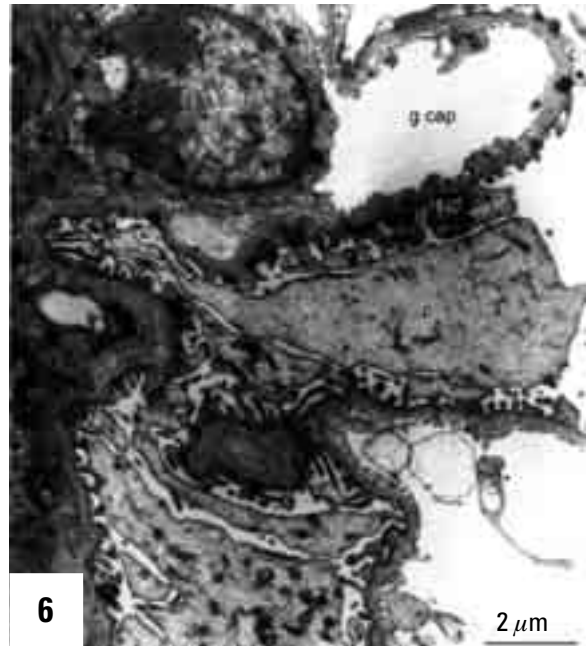


Figure 6. Renal corpuscle of the kidney of a melanoma-bearing hamster treated with TNP-470. Endothelium of the glomerular capillary (g cap) demonstrates normal ultrastructure; p — podocyte. Bar: 2 μm.

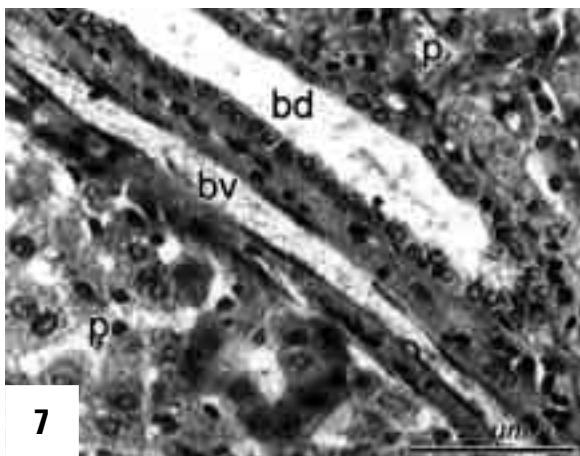


Figure 7. Liver of a melanoma-bearing hamster treated with TNP-470. Longitudinal section of interlobular blood vessel (bv) and interlobular bile duct (bd) surrounded by liver parenchyma (p). The blood vessel demonstrates normal structure. Staining with eosin and haematoxylin. Bar: 50 μm.

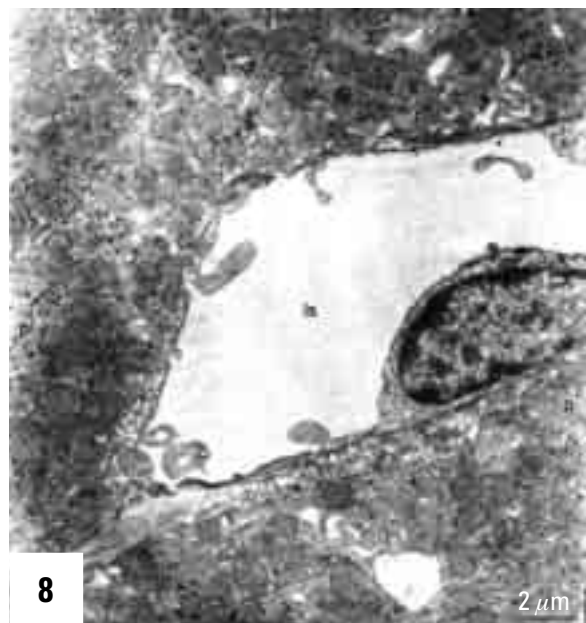


Figure 8. Liver of a melanoma-bearing hamster treated with TNP-470. Cross-section of the liver sinusoid (ls) surrounded by liver parenchyma (p). The endothelium of the sinusoid demonstrates normal ultrastructure. Bar: 2 μm.

in humans are rather scanty and limited to such observations as the occurrence of nausea and fatigue, and the presence of some neurological symptoms which disappeared after therapy was discontinued [6]. Examinations of the effect of TNP-470 on endothelial cells were mainly carried out on endothelial cells cultured *in vitro* [3]. In our studies TNP-470

was given in the vicinity of a growing tumour, so that the dose applied of that compound could be quite low. The systemic action of TNP-470 was un-

avoidable. We decided, therefore, to test the influence that a strong antiangiogenesis inhibitor could exert on the blood vessels of the lungs, kidneys and liver of the hamsters treated with TNP-470. The problem of the possible side-effects of the treatment with TNP-470 is very important since the only partly effective action of that drug in pre-clinical trails induced some research groups to apply a combined treatment with other antitumour drugs, which themselves sometimes cause severe side-effects [6, 11].

The results of our studies and those of other research groups [3, 6] supply evidence that the side-effects evoked by TNP-470 are fairly limited and reversible after treatment, which indicates that this analogue of fumagilin — TNP-470 is a potentially valuable antitumour drug.

REFERENCES

1. Bhargava P, Marshall JL, Rizivi N, Dahut W, Yoe, Figuera M, Phipps K, Ong VS, Kato A, Hawkins (1999) A phase I and pharmacokinetic study of TNP-470 administered weekly to patients with advanced cancer. *Clin Cancer Res*, 5: 1989–1995.
2. Bomirski A, Slominski A, Bigda J (1988) The natural history of a family of transplantable melanomas in hamsters. *Cancer Metastasis Rev*, 7: 95–118.
3. Castronovo V, Belotti D (1996) TNP-470 (AGM-1470): Mechanism of action and early clinical development. *Eur J Cancer*, 32A: 2520–2527.
4. Folkman J (1990) What is the evidence that tumors are angiogenesis dependent? *J Natl Cancer Inst*, 82: 4–6.
5. Folkman J (1992) Tumor angiogenesis and tissue factor. *Nature Med*, 2: 167–168.
6. Gervaz P, Fontollet M (1998) Therapeutic potential of the anti-angiogenesis drug TNP-470. *Int J Exp Pathol*, 79: 359–362.
7. Hotz HG, Reber HA, Hotz B, Sanghavi PC, Yu T, Foitzik T, Buhr HJ, Hines OJ (2001) Angiogenesis inhibitor TNP-470 reduces human pancreatic cancer growth. *J Gastrointest Surg*, 5: 131–138.
8. Ingbar D, Fujita T, Kishimoto S, Sudo K, Kanamaru T, Brem H, Folkman J (1990) Synthetic analogues of fumagilin that inhibit angiogenesis and suppress tumor growth. *Nature*, 348: 555–557.
9. Kusaka M, Sudo K, Matsutani E, Kozai Y, Marui S, Fujita T, Ingbar D, Folkman J (1994) Cytostatic inhibition of endothelial cell growth by angiogenesis inhibitor TNP-470 (AGM-1470). *Br J Cancer*, 69: 212–216.
10. Mahadevan V, Hart IR (1990) Metastasis and angiogenesis. *Acta Oncol*, 29: 97–103.
11. Masunaga S, Ono K, Nishimura Y, Kanamori S, Saga T, Suzuki M, Kinashi Y, Takagaki M, Kasai S, Nagasawa H, Uto Y, Hori H (2000) Combined effects of tirapazamine and mild hyperthermia on anti-angiogenic agent (TNP-470) treated tumors-reference to the effect on intratumor quiescent cells. *Int J Radiation Oncology Biol Phys*, 47: 799–807.
12. Myśliwski A, Szmit E, Szatkowski D, Sosonowska D (1998) Suppression of growth of Bomirski Ab melanoma and its metastasis in hamsters by angiogenesis inhibitor TNP-470. *Anticancer Res*, 18: 441–444.
13. Myśliwski A, Bigda J, Koszałka P, Szmit E (2000) Synergistic effect of the angiogenesis inhibitor TNP-470 and Tumor Necrosis Factor (TNF) on Bomirski Ab melanoma in hamsters. *Anticancer Res*, 20: 4643–4648.
14. Myśliwski P, Koszałka P, Bigda J, Szmit E (2002) Complete remission of Bomirski Ab amelanotic melanoma in hamsters treated with the angiogenesis inhibitor TNP-470. *Neoplasma*, 49: 319–322.