

Development of the descending colon during the human foetal period

Bohdan Gworys¹, Zygmunt Domagała¹, Krystyna Markocka-Mączka²

¹Department of Normal Anatomy, Medical University, Wrocław, Poland

²Department of Gastrointestinal and General Surgery, Medical University, Wrocław, Poland

[Received 21 July 2003; Revised 7 January 2004; Accepted 10 January 2004]

The growth, changes in shape, topography and relation to the peritoneum of the descending colon were assessed on the basis of material taken from 178 fetuses of both sexes, aged from 72 to 236 days of pregnancy. The statistical analysis method demonstrated that the descending colon growth process occurs about a month earlier in female fetuses as compared to male ones. From the statistical point of view, the longitudinal growth of the descending colon significantly slows down in the 7th and 8th months of pregnancy, while the width of this part of the large intestine increases sharply towards the end of the foetal development period. The statistically important process of the descending colon rising over the surface of the left kidney and adrenal gland was noticed in male fetuses. This occurs approximately one month earlier in female fetuses as compared to males. The ascent of this part of the colon is accompanied by a change in its shape from straight, to curved and, finally, to wavy in the oldest age group of male fetuses. The changes in relation to the peritoneum are manifest in a gradual change in the position of this section of the intestine from the intraperitoneal, where more than 40% of the cases examined had a fully movable mesentery, to the extraperitoneal, with 14% of fetuses having a mesentery in the 8th month of pregnancy.

Key words: foetal stage, descending colon variations, morphology

INTRODUCTION

There are few works available on colon morphogenesis in the foetal period. Contemporary publications focus mainly on the early stage of foetal colon morphogenesis [3, 4, 12, 14] or describe methods that provide an estimation only and lack precision, such as the evaluation of intestinal anatomy in *in vivo* radiological tests [6, 7, 10]. This test, conducted on prosectorial material, is mostly concerned with the anatomy of the postnatal period [2, 8, 9, 11]. In the Department and Institute of Normal Anatomy of the Medical University in Wrocław complex examinations of the development of the large intestine have been made. So far these have produced

results regarding the ascending and transverse colon [5, 16]. The current publication constitutes the third part of this study.

The aim of this work was to examine variability in the processes of descending colon development, as well as topographical and peritoneal relations (proportions), shape changes and the growth rate of the descending colon. The observations related to these aspects were analysed in comparison with metrical foetal dimensions and an analysis of the descriptive characteristics was also made. As with the previous publication, the development of the descending colon in the foetal period was analysed with regard to age diversification and sex dimorphism.

MATERIAL AND METHODS

The examination was carried out on 178 human foetuses (90 male and 88 female) aged from 72 to 256 days of pregnancy and grouped in monthly age groups. The age of the foetuses was calculated on the basis of clinical data for menstrual age, followed by verification using our own computer method for assessing foetal age [5, 17]. After the abdominal cavity had been opened, *in situ* measurements were made, using classical anthropometrical methods, of the descending colon and topographical and peritoneal relations were determined. The results obtained, both metrical and descriptive, were statistically analysed with the statistical software package Statistica. The mean values of the characteristics tested were interpolated with Lagrange's method into the central part of the age group to obtain equal intervals between the values of the characteristics in consecutive age groups. This was necessary in order to assess the growth rate of specific characteristics and the differences in growth rate between the sexes (Table 1).

RESULTS

Variability of metrical characteristics

The precise determination of the variability of the measured parameters of the large intestine in the period of ontogenesis under examination is one of the most important factors in the evaluation of the developmental processes. Two developmental peri-

ods may be distinguished for the characteristics of the descending colon examined. The first lasts from the 4th to the 7th month of pregnancy and is marked by a rapid increase in the values of the characteristics, while in the second, lasting from the 8th to the 9th month of pregnancy, the values of the characteristics (particularly the length of the descending colon) become more stable. A statistically important difference was found between the length and width increments of the descending segment of the colon. The length increment in the period of ontogenesis examined was about 269%, whereas the increment of colon width was as high as 320%. The length vs. width indicator of this intestinal segment varies from 0.12 up to 0.25, which is a statistically important difference.

The incremental rate

The incremental rate of metrical characteristics was evaluated with two methods. The absolute increment was measured on the basis of absolute increment analysis at 28-day-long intervals. The relative growth dynamics were evaluated on the basis of the characteristic value for the given age group expressed as a percentage of its value as determined for the group representing the last stage of the foetal period [13] (Fig. 1, 2). The absolute descending colon length increments are characterised by distinctive sex dimorphism. In male foetuses they reach their maximum values in the 7th month of pregnancy, while in the females the maximum increment of descend-

Table 1. Variation in the metrical features of the descending colon. N — group numerical force, X — mean value, X' — mean value interpolated into mean age group, E_x — margin of error, s — standard deviation, A — age in days

Sex	N	A	Length [cm]				Width [cm]			
			X	X'	E _x	s	X	X'	E _x	s
Male	15	98	15.07	13.28	0.83	3.21	1.80	1.54	0.09	0.37
Male	15	126	19.86	19.00	1.04	4.02	2.50	2.37	0.14	0.54
Male	15	154	27.21	23.49	1.56	6.04	3.82	3.72	0.23	0.89
Male	18	182	30.91	31.81	1.65	7.00	5.06	5.29	0.31	1.32
Male	15	210	34.25	34.62	2.52	9.76	5.75	5.98	0.47	1.82
Male	12	238	34.50	34.68	2.43	8.41	7.50	7.83	0.43	1.50
Female	15	98	13.73	12.68	0.70	2.72	1.90	1.72	0.06	0.23
Female	17	126	19.09	18.77	0.74	3.03	2.68	2.63	0.10	0.42
Female	15	154	28.67	28.58	1.70	6.58	4.43	4.35	0.20	0.78
Female	17	182	28.88	29.26	1.72	7.09	5.00	5.61	0.34	1.41
Female	13	210	34.50	34.08	2.28	8.21	6.00	5.71	0.45	1.63
Female	11	238	34.67	34.63	2.44	8.11	7.08	6.92	0.48	1.60

ing colon length occurs a month earlier. In both sexes the increase in length in the 9th month of pregnancy is minimal, not exceeding 1 mm, which may thus be counted as the margin for error.

The width of the descending colon increases uniformly in the prenatal period of ontogenesis investigated, the monthly increments amounting to about 1 mm. In contrast to the previously described characteristic, the width increment rate of the descending colon does not slow down even in the 9th month of pregnancy.

On the other hand the rates of increase of the dimensions of the descending colon are not char-

acterised by any great sex dimorphism. In male foetuses the dimensions reached 90% of their final extent one month earlier than in female foetuses. The length increment of the descending colon slows down in the 7th and 8th months of pregnancy, reaching 70–80% of its final width.

Characteristics of shape

As in the previous works regarding the proximal parts of the descending colon, the following 3 types of descending colon shape were distinguished: straight, arched and wavy (Fig. 3).

As a result of the small quantity of material tested, the variability in shape of the descending colon was evaluated with a sign-test alone. A descending colon which is straight dominates from the statistical point of view. A relatively high percentage of curved descending colons appear in the second trimester of pregnancy. From the 8th month of pregnancy the presence of wavy descending colons (particularly in male foetuses) increases significantly. Therefore the conclusion may be drawn that the shape of descending colon changes during the foetal period from straight to curved to the wavy one characteristic of the early postnatal period.

Topography

It was found that the relation of the descending colon as compared to other organs depended on its filling rate. Usually it is partially or fully covered with the loops of the small intestine. The posterior wall adheres to the connective tissue filling the retroperitoneal cavity. The following location types have been noticed for the descending colon: the high type — the left inflexion of the descending colon reaches the spleen cavity, the intermediate type — the left inflexion of the descending colon lies on the left adrenal gland and the low type — the left inflexion of the descending colon lies on the upper pole of the left kidney.

In the period of foetal development studied a statistically important tendency was observed for the left colon inflexion to ascend gradually. The first segment of the descending colon was located either low or in an intermediate position in 30% to 50% of the cases in the 4th and 5th month of pregnancy. After the 6th month in male foetuses and the 7th month in females the high position was dominant (in more than 90% of cases) (Fig. 4).

The location and shape of the intermediate segment between the descending and sigmoid colons differs greatly. During the tests 3 positions of this segment were registered: a high one — at the level of

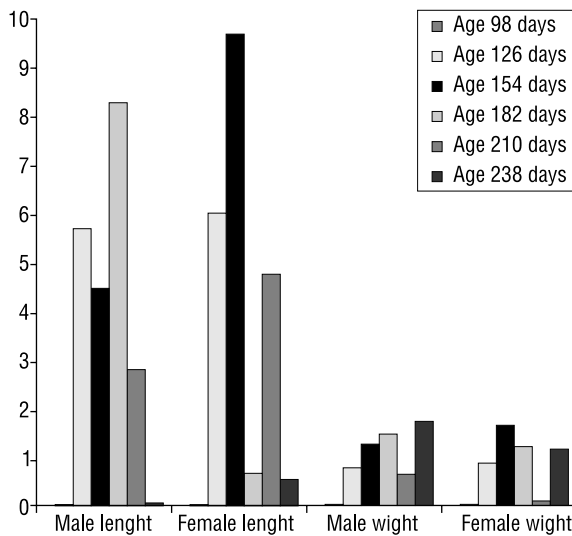


Figure 1. The absolute increment rates of the examined metrical characteristics of the descending colon.

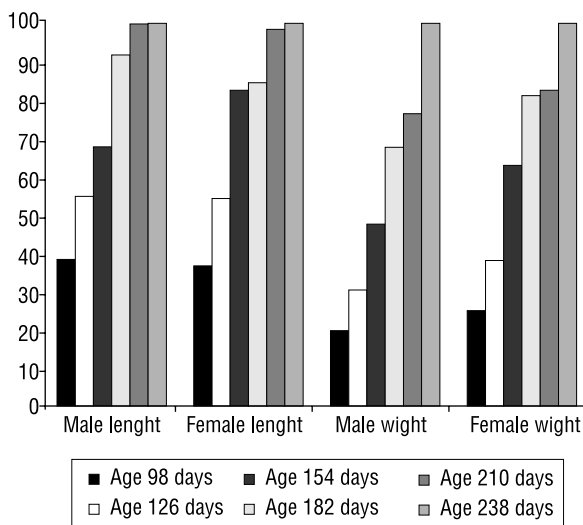


Figure 2. The relative increments in the metrical dimensions of the descending colon.

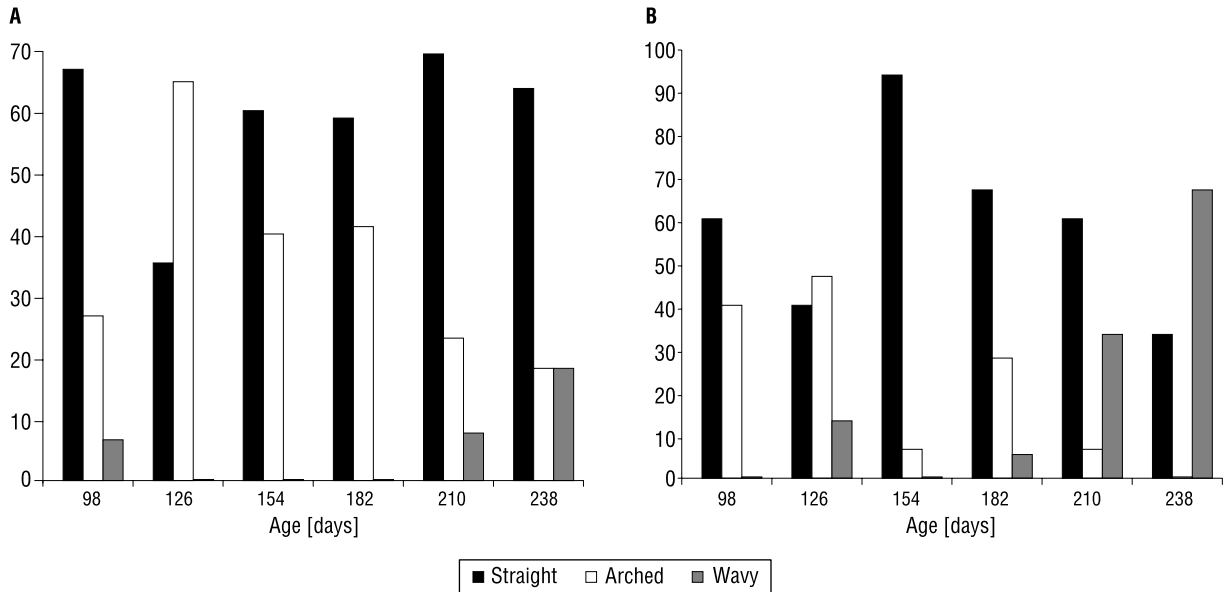


Figure 3 A. Shape variability of the female descending colon; B. Shape variability of the male descending colon.

the lower left kidney pole, an intermediate — at the level of the hip crest and a low — in the iliac fossa. Three types of inflexion were found: acute, intermediate and mild. The statistically important predominance of the acute type of inflexion was demonstrated in all age groups. Moreover, our examinations showed that the distal part of the descending colon gradually rises during prenatal development. This is a statistically important process. In foetuses in the 2nd trimester of pregnancy the distal part of the descending colon is situated on the *fossa et crista iliaca* in 70–90% of cases. In the 3rd trimester the passage

between the descending and sigmoid colons goes up over the surface of the left kidney. The process takes place about one month earlier in female foetuses as compared to male ones (Fig. 5).

Relations to the peritoneum

The examinations showed that in younger foetuses the interperitoneal location of the descending colon is present in 67% of cases, while in 42% of foetuses the descending colon has a fully movable mesentery. During development the percentage of extraperitoneally located descending colons

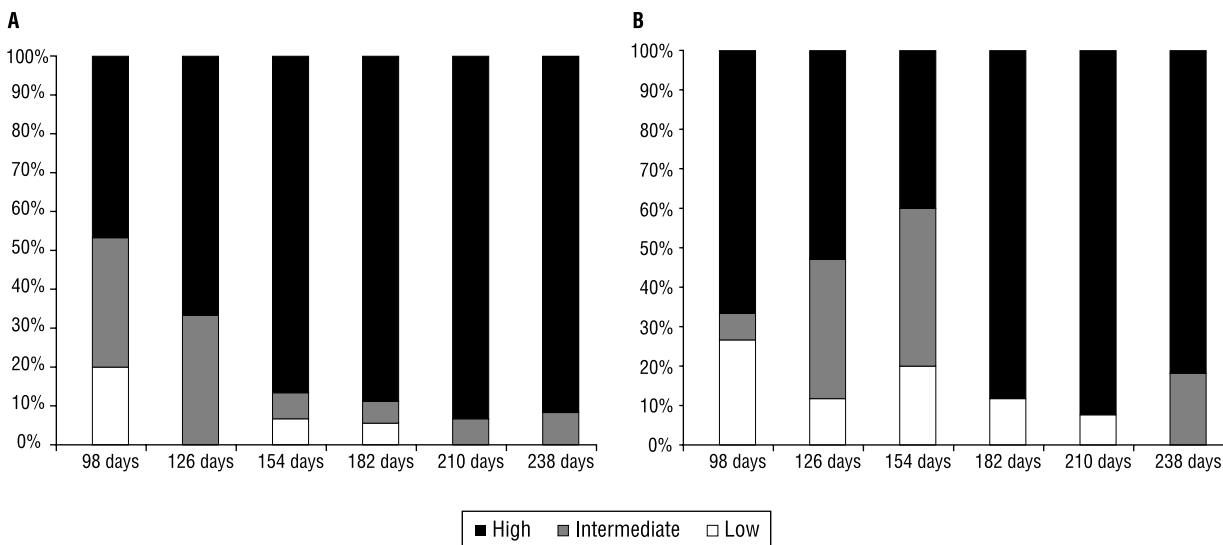


Figure 4 A. The location of the descending colon — male; B. The location of the descending colon — female.

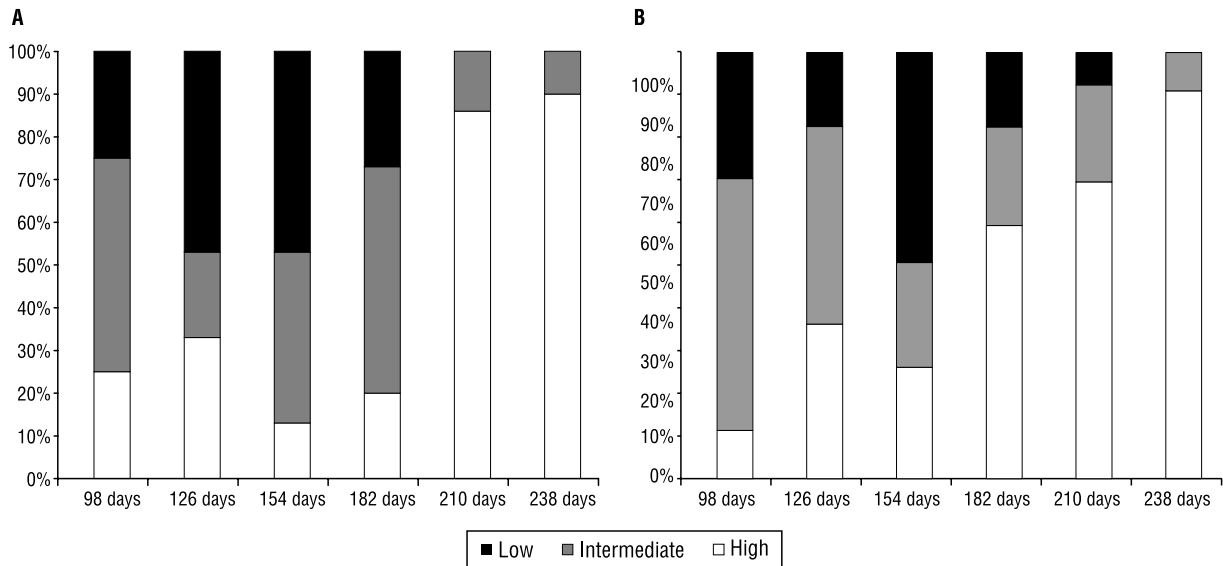


Figure 5 A. The location of the border between the descending colon and the sigmoid colon — male foetuses; **B.** The location of the border between the descending colon and the sigmoid colon — female foetuses.

gradually rises so that in the 8th month of pregnancy it is located interperitoneally and has a fully movable mesentery in no more than 14% of foetuses. However, during the period of prenatal ontogenesis studied as a whole the interperitoneal location is dominant with the presence of a partially accreted mesentery, causing gradual lost of mobility of the descending colon.

DISCUSSION

Our work describing the descending and transverse colons [16] has demonstrated that the increase in the dimensions of the colon in each age group is greater than that for the abdominal cavity (omph-sy). In the case of the descending colon under examination in this work the difference is not statistically important. At the same time it has been proved that the maximum descending colon increments occur earlier than the maximum abdominal cavity increments. The delay in abdominal cavity growth may be caused by the change in the shape of the descending colon from straight to wavy. The wavy shape, especially in male foetuses, is predominant in the labour period. As suggested by Zelikson [15], the change in descending colon shape is also strongly influenced by the growth of the sigmoid colon which, as was found when it was investigated by the present author, increases three times faster than the abdominal cavity during the foetal period. This is suspected as one of the factors responsible for the significant reduc-

tion in free space in the abdominal cavity, where the descending colon is to grow. The significant (statistically important) increment of the transverse and sigmoid colons is also responsible for the change in location and interperitoneal relations of the descending colon. In the younger age groups the distal end of the descending colon reaches the iliac fossa, while its proximal end is located on the left kidney. In foetuses in the 3rd trimester of pregnancy we have noticed a descent of this part of the large colon so that it may, in the proximal segment, even reach the spleen cavity, while in the distal segment it gradually ascends over the lower pole of the left kidney. All of these seem to confirm the conclusions presented in our previous publications [1, 5, 15, 16] regarding the genetically-planned model of colon growth. Nevertheless it is uncertain whether the observed changeability in the shape of the descending colon and its slightly lower increment as compared to other large colon segments nearby results from the genetic "plan" as well or is caused by the limited free space in the abdominal cavity and the faster growth of the other large colon segments.

CONCLUSIONS

1. The incremental process in the dimensions of the descending colon takes place about month earlier at female foetuses as compared to males.
2. There is a statistically significant slowing down of the length increment of the descending

colon in the 7th and 8th months of pregnancy, while the width of this segment of the large intestine increases sharply up to the end of the foetal period of development.

3. The statistically important process of the ascent of the descending colon over the surface of the left kidney and the adrenal gland in the foetal period takes place approximately a month earlier in female foetuses as compared to males.

4. The ascent of this segment of the colon is accompanied by a change in its shape, starting from a straight course, through an arched one and followed by a wavy one in the oldest age groups of male foetuses.

5. The changes in peritoneal relations are exhibited by the gradual transition of this segment of large intestine from its interperitoneal location, where over 40% of cases has a fully movable mesentery, to a percentage of 14% of foetuses with mesentery in the 8th month of pregnancy. The secondary extra-peritoneal location is present in only a few foetuses in the 3rd trimester of pregnancy.

REFERENCES

1. Arey LB (1966) Developmental anatomy. A textbook and laboratory manual of embryology. WB Saunders Company, London, Philadelphia pp. 76–91.
2. Faure JP, Richer JP, Chansigaud JP, Scepti M, Irani J, Ferrie JC, Kamina P (2001) A prospective radiological anatomical study of the variations of the position of the colon in the left pararenal space. *Surg Radiol Anat*, 23 (5): 335–339.
3. Fitzgerald MJ, Nolan JP, O'Neill MN (1971) The formation of the ascending colon. *Ir J Med Sci Jun*, 140 (6): 258–262.
4. Frober R, Kleta U, Linss W (1991) New aspects of the ontogenetic development of the human colon. *Anat Anz*, 173 (4): 215–223.
5. Gworys B, Kurlej W, Lucijan Z, Matysiak I (1983) Estimation of fetal age on the basis of the development of sternum. *Folia Morph (Warsz)*, 42 (2): 139–151.
6. Harris PF, Jones PR, Robertson CS (1976) A radiological study of morphology and growth in the human fetal colon. *Br J Radiol*, 49 (580): 316–320.
7. Harrison KL, Martinez D, Mason G (2000) The subjective assessment of echogenic fetal bowel. *Ultrasound Obstet Gynecol*, 16 (6): 524–529.
8. Hunter W (1928) A note on the development of the ascending colon. *J Anat (London)*, 62: 297–300.
9. Leonidas JC, Valderama E (1998) Development of colon length musculature and haustration after birth and associated malformations. *Abdom Imaging*, 23 (2): 219–220.
10. Nyberg DA, Mack LA, Patten RM, Cyr DR (1987) Fetal bowel. Normal sonographic findings. *J Ultrasound Med*, 6 (1): 3–6.
11. Popmikhailov D, Maleev N (1973) Anomalies in the position of the cecum and ascending colon. *Khirurgiia (Sofia)*, 26 (1): 72–78.
12. Richer JP, Sakka M (1994) Human ontogeny of the left colon. Fetal stage. *Bull Assoc Anat (Nancy)*, 78 (241): 31–35.
13. Waszak M, Cieslik K (2003) Sex dimorphism in development dynamics and in development progression of morphological features in human fetuses. *Folia Morphol (Warsz)*, 62 (1): 33–39.
14. Weaver LT, Austin S (1991) Small intestinal length: a factor essential for gut adaptation. *Gut*, 32 (11): 1321–1323.
15. Zelikson AA (1966) The formation of the sigmoid at the foetal period of intrauterine development in humans. *Dokl Akad Nauk SSSR*, 168 (6): 1434–1435.
16. Ziółkowski M, Gworys B, Porwolik K, Porwolik M (1997) Development of ascending colon in human fetal period. *Folia Morphol (Warsz)*, 56 (4): 253–261.
17. Ziółkowski M, Gworys B, Kurlej W (1988) Estimation of fetal age on the basis of certain measurements and ossification of the sternum. *Folia Morphol (Warsz)*, 47 (1–4): 145–151.