

The topographical anatomy of the round window and related structures for the purpose of cochlear implant surgery

Arkadiusz Paprocki, Barbara Biskup, Katarzyna Kozłowska, Agata Kuniszyk, Dominik Bien, Kazimierz Niemczyk

Banacha Hospital, Medical University, Warszawa, Poland

[Received 1 April 2004; Revised 30 April 2004; Accepted 30 April 2004]

The treatment of total deafness using a cochlear implant has now become a routine medical procedure. The tendency to expand the audiological indications for cochlear stimulation and to preserve the remnants of hearing has brought new problems. The authors have studied the topographical anatomy of the internal structures of the ear in the area where cochleostomy is usually performed and an implant electrode inserted.

Ten human temporal bones were obtained from cadavers and prepared in a formalin stain. After dissection of the bone in the area of round and oval windows, the following diameters were measured using a microscope with a scale: the transverse diameters of the cochlear and vestibular scalae at the level of the centre of the round window and 0.5 mm anteriorly to the round window, the distance between the windows and the distances from the end of the spiral lamina to the centre of the round window and to its anterior margin. The width of the cochlear scala at the level of the round window was 1.23 mm, and 0.5 mm anteriorly to the round window membrane it was 1.24 mm. The corresponding diameters for the vestibular scala are 1.34 and 1.27 mm. The distances from the end of the spiral lamina to the centre of the round window and to its anterior margin are 1.26 and 2.06 respectively. The authors noted that the two methods of electrode insertion show a difference of 2 mm in the length of the stimulated spiral lamina. The average total length of the unstimulated lamina is 2.06 and 4.06 in the two situations respectively.

Key words: cochlear scala, vestibular scala, anatomy, measurements

INTRODUCTION

Cochlear implantation is widely performed as a highly efficient therapeutic method in cases of profound hearing impairment or deafness.

The most widely accepted indications for cochlear implantation are total/subtotal sensorineural hearing loss (SNHL) characterised by pure tone averages (PTAs) of 500, 1000, 2000 Hz of 90 dB or more and a threshold of lower than 60 dB in the free-field with

the best-fitted conventional hearing aid. Speech understanding should be up to 30% in the open-set sentence tests (in best-aided conditions) [7]. There are some patients who can benefit more from cochlear implantation because of preserved perception of low-frequency sounds. For these patients it is vital that implantation is atraumatic and preserves the membrane of the round window intact as well as the patient's residual hearing.

The primary route for implanting the electrode is the scala tympani, because of its easy accessibility by traditional surgical techniques. Different approaches for inserting the electrode into the scala tympani have been described in the literature [1, 2, 5, 10].

There are two main methods of implantation. The first is through the round window and through a small cochleostomy located antero-inferiorly to the round window towards the basal turn of the cochlea. The second leaves the round window intact and preserves the ability to hear. The efficiency of this method depends on the preoperative status of the patient. After entering the scala tympani, an electrode is inserted and the cochleostomy secured with fibrous tissue from the fascia.

Access through the round window has its advantages (such as a wider stimulation surface), but leads to the destruction of remnants of hearing in patients with a rudimentary inner ear function. The insertion of the electrode can also be difficult owing to the presence of the membranous structure known as the "cochlear hook" [9, 12]. In view of this, cochleostomy anteriorly to the round window membrane is widely used. This technique probably leaves some part of the spiral lamina out of stimulation.

Our study was undertaken to evaluate the length of the potentially useful part of the spiral lamina missed when anterior cochleostomy is performed. We also paid attention to the anatomical structures important for ENT surgeons.

MATERIAL AND METHODS

The 10 adult human temporal bones presented in our study were isolated from cadavers and prepared in a formalin stain. The bones differed with respect to side (6 left and 4 right) and gender (7 male and 3 female). There were no anatomical abnormalities in the specimens examined. Firstly, the bones were cross-sectioned in a plane parallel to the medial wall of the middle ear. After dissection of the bone with the diamond burr in the area of the round and oval windows, the inner ear was opened and the following diameters were measured using a microscope with a scale (scale accuracy: 0.05 mm) (Fig. 1): the maximal transverse diameters of the scalae tympani (A) and vestibuli (B) 0.5 mm anteriorly to the round window; the maximal transverse diameters of the scalae tympani (C) and vestibuli (D) at the level of the round window; the minimal distance between the margin of round window and the margin of the oval window (E); the distance between the anterior margin of the round window and the

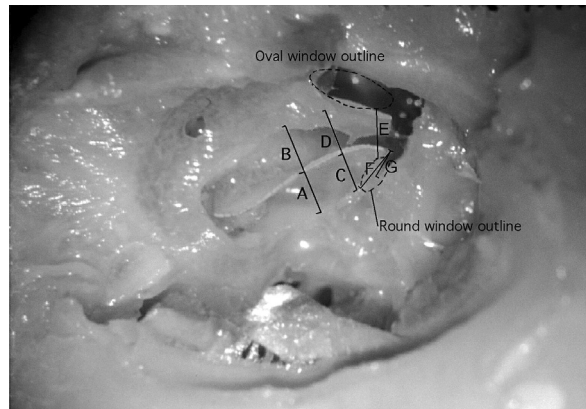


Figure 1. Dissected temporal bone with measurements. The bony wall between the round and oval windows has been removed to visualise the end of the spiral lamina.

end of the spiral lamina (F); the distance between the middle of the round window and the spiral lamina (G).

The phantom electrode of a Nucleus 24 M was then placed either through the round window or through the cochleostomy to assess the comparative length of the unstimulated spiral lamina.

RESULTS

The average width of the scala tympani (A) and the scala vestibuli (B) at the level of the anterior cochleostomy (i.e. 0.5 mm anteriorly to the membrane of the round window) were, 1.24 mm (A), and 1.27 mm (B), respectively. The diameters measured at the level of the round window were similar, with widths of 1.23 mm (C) and 1.24 mm (D) for the scala tympani (C) and scala vestibuli (D), respectively. The insensible greater width of the scala vestibuli results from proximity to the oval window and a slight widening of the space in this area of the cochlea. The shortest distance between the margins of the windows is about 1.34 mm. The values describing the distances between the electrode and the spiral lamina in the case of anterior (F) and posterior (G) cochleostomy are 2.06 mm (F) and 1.26 mm (G), respectively. The last value is loaded with great standard deviation (0.335 mm) (Table 1).

DISCUSSION

The technique of implantation through the round window has been used from the beginning of cochlear prosthetics but now an approach through a small cochleostomy anteriorly to the round window membrane is widely used [8]. Atraumatic insertion of an electrode through the cochleostomy does

Table 1. Results of measurement of examined specimens

No. of the specimen	ST maximal transverse diameter 0.5 mm anteriorly to the RW (A)	SV maximal transverse diameter 0.5 mm anteriorly to the RW (B)	ST maximal transverse diameter at the level of RW (C)	SV maximal transverse diameter (D)	Minimal distance between RW and OW margins (E)	RW anterior margin to the end of SL distance (F)	Middle of the RW to the SL distance (G)
1.	1	1.2	1	1.25	1	1.85	1.3
2.	1	1.45	1.25	1.6	1.75	1.7	1
3.	1	1	1.3	1.05	1.25	1.5	0.75
4.	1.7	1.45	1.3	1.35	1.75	2.05	1.05
5.	1.25	1.35	1.15	1.45	1.5	2.2	1.2
6.	1.5	1.5	1.2	1.4	1.75	2.3	1.55
7.	1.3	1.25	1.2	1.35	1.5	2.75	1.75
8.	1.5	1.2	1.45	1.25	1.1	2.05	1.75
9.	0.75	1.2	1.2	1.4	1.2	2.25	1
10.	1.4	1.1	1.25	1.3	1.5	1.95	1.25
Mean	1.24	1.27	1.23	1.34	1.43	2.06	1.26
SD	0.296	0.164	0.116	0.145	0.279	0.348	0.335

RW — round window, OW — oval window, SL — spiral lamina, SV — scala vestibuli, ST — scala tympani

not destroy the patient's ability to hear spontaneously, especially in the low frequency range. Otherwise, access through the cochleostomy leaves part of spiral lamina without stimulation. This part can be useful as a place for greater stimulation of spiral ganglion cells and should be of benefit to some patients.

The results of the measurements show that the widths of the scala vestibuli and scala tympani are sufficient to insert the electrodes of the most commonly used systems, as the average width exceeds 1.0 mm. There are no differences between the cochlear scala at the level of the round window membrane and the corresponding diameter of the scala vestibuli. Wysocki [13] found that the width of the scala vestibuli reaches approximately 1.6 mm and that of the scala tympani approximately 2.0 mm, which is 0.3–0.7 mm more than the results obtained in our study. All the distances measured by Wysocki [12] were higher when compared with ours. It would seem that this depends on the method (optical measurements vs. cochlear cast in latex). However, the scalae diameters allow the insertion of electrodes into the scala tympani without difficulty (in cases with no history of previous disease leading to ossification of the cochlea). Some authors [4] have proposed the insertion of the electrode into the scala vestibuli in cases where the scala tympani have been obliterated and, from our study, this

seems to be anatomically possible. There is some risk of the complete destruction of Reissner's membrane when the electrode is inserted into the scala vestibuli.

The average distance between the centre of the round window and the spiral lamina is 1.26 mm. Takahashi and Sando's 3D labyrinth reconstruction showed the distance to be similar to this (1.23 mm in average) [11].

The distance between the round window and oval window is important for surgeons performing stapedectomy or other operations in this area, because of the risk of unintended damage to the round window membrane or of opening the vestibule. The average distance on our specimens was 1.43 mm.

Assessment of the point of contact between the electrode and the spiral lamina is based on our empirical findings. Using the phantom electrode of a Nucleus 24 M-type electrode we found that the first contact between the spiral lamina and the lead occurs at least 0.5 mm anteriorly to the margin of the cochleostomy or round window. When cochleostomy is performed within the 1.5 mm distance from the anterior margin of the round window, as indicated by Ganz [3], the anterior margin of the cochleostomy is located 2 mm anteriorly to the round window anterior margin. On the basis of this, the electrode makes contact with the spiral lamina 0.5 mm and 2.5 mm anteriorly

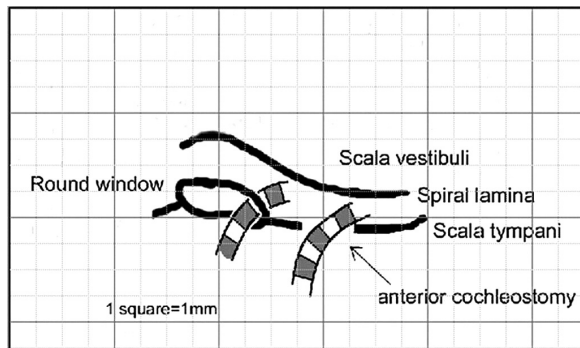


Figure 2. Method of assessment of the contact point between the electrode and the spiral lamina.

only to the round window respectively. The 2 mm difference reflects two electrode contacts (for the Nucleus 24 M-type) (Fig. 2).

There have been no papers to date which describe the dependence between the method of approaching the cochlea and the clinical outcome of the patient. In some publications the inability to anticipate a patient's audiological performance after implantation is pointed out [6], and it is possible that it is, at least in part, correlated with different methods of electrode insertion. An assumption can now be made that an increase in the length of the spiral lamina under stimulation would directly result in a greater number of stimulated spiral ganglionic cells (SGC) because of the variable number of intact cells in different pathologies causing hearing impairment. Otherwise, if there are live SGC in the area of stimulation, the greater number of stimulated cells should improve the patient's outcome.

In view of the fact that publications have reported better results of cochlear implantation in patients with rudimentary hearing before the operation [8], it becomes important to insert the electrode into the cochlea in such a way that the round window membrane is left intact (so preserving the function of the internal ear), at the same time ensuring the most effective stimulation (either by the use of perimodiolar electrodes or by placing the cochleostomy at the minimal safe distance from the round window membrane).

CONCLUSIONS

The width of the scala tympani and scala vestibuli at the level of the anterior and posterior coch-

leostomy allows free insertion of the electrodes of commonly used systems. The selection of the site for cochleostomy should depend on the functional state of the cochlea. Anterior cochleostomy has been preferred by most surgeons to treat non-total hearing loss. In cases with total deafness the best solution would be posterior cochleostomy, which has the great advantage of bringing into use part of the basal lamina, which often remains out of stimulation.

REFERENCES

1. Colletti V, Fiorino FG (2000) New Approach for cochlear implantation: cochleostomy through the middle fossa. *Otolaryngol Head Neck Surg*, 123: 467–474.
2. Franz BK, Clark GM, Bloom DM (1987) Surgical anatomy of the round window with special reference to cochlear implantation. *J Laryngol Otol*, 101: 97–102.
3. Ganz B (1996) Cochlear implant. In: Naumann HH (ed.). *Head and neck surgery*. Vol. 2. Georg Thieme Verlag, Stuttgart, New York, pp. 371–386.
4. Gulya AJ, Steenerson RL (1996) The scala vestibuli for cochlear implantation. *Arch Otolaryngol Head Neck Surg*, 122: 130–132.
5. Kronenberg J, Migirov L, Dagan T (2001) Suprameatal approach: New surgical approach for cochlear implantation. *J Laryngol Otol*, 115: 283–285.
6. Makhdom MJ, Snik AF, van den Broek P (1997) Cochlear implantation: A review of literature and the Nijmegen results. *J Laryngol Otol*, 111: 1008–1017.
7. Niparko JK, Tucci DL, Robbins AM, Kirk KL, Mellon NK (2000) *Cochlear implants: principles and practices*. Lippincott Williams & Wilkins, Philadelphia.
8. Shin YJ, Deguine O, Laborde ML, Fraysse B (1997) Conservation of residual hearing with cochlear implantation. *Rev Laryngol Otol Rhinol*, 118: 233–238.
9. Stridham KR, Robertson JB (1999) Cochlear hook anatomy: Evaluation of the spatial relationship of the basal cochlear duct to middle ear landmarks. *Acta Otolaryngol (Stockh)*, 119: 773–777.
10. Szyfter W, Colletti V, Pruszewicz A, Kopec T, Szymiec E, Kawczynski M, Karlik M (2001) Cochlear implantation through the middle fossa approach. *Otolaryngol Pol*, 55: 389–393.
11. Takahashi H, Sando I (1990) Computer-aided 3D temporal bone anatomy for cochlear implant surgery. *Laryngoscope*, 100: 417–421.
12. Wysocki J (1998) Comparative analysis of surgical approaches used during intracochlear implantation with reference to their safety for the important structures of the temporal bone. *Otolaryngol Pol*, 52: 701–706.
13. Wysocki J (1999) Dimensions of the human vestibular and tympanic scalae. *Hear Res*, 135: 39–46.