

Anatomical and histological data on the ciliary ganglion in the Egyptian spiny mouse (*Acomys cahirinus* Desmarest)

Elżbieta Nowak, Tadeusz Kuder, Aleksander Szczurkowski, Jacek Kuchinka

Department of Comparative Anatomy, Institute of Biology, Świętokrzyski University, Kielce, Poland

[Received 23 January 2004; Revised 1 March 2004; Accepted 2 March 2004]

The morphology and topography of the ciliary ganglion in the Egyptian spiny mouse were studied with use of histochemical and histological techniques. The ciliary ganglion of the Egyptian spiny mouse consisted of between 3 and 4 agglomerations of nerve cells. The largest was situated at the point where the ventral branch of the oculomotor nerve divides into two branches. The next two smaller aggregations were located on the superior and lateral surfaces of the optic nerve where it crossed the oculomotor nerve. From the main agglomerations of neurocytes arose between 3 and 4 intensively stained postganglionic cholinergic fibres. These followed the optic nerve to the eyeball. On the cross-sections of these bundles small agglomerations of neurocytes were observed. These decreased in size to only 2 or 3 cells towards the sclera. The ganglionic neurocytes in the largest ganglion varied from 15 to 30 µm in diameter. They were distributed uniformly over the whole surface of the sections. All the ganglia had connective capsules.

Key words: ciliary ganglion, Egyptian spiny mouse

INTRODUCTION

Anatomical data concerning the ciliary ganglion are extremely important not only for comparative anatomy but also in experimental investigations. It is known that the herpes simplex virus type 1-HIV-1 can be localised in the ciliary ganglion [3]. Using retrograde transport methods it has been possible to discover where the postganglionic autonomic fibres leave the ciliary ganglion and reach the lacrimal gland in the cat [4]. In addition, immunoreactive methods have enabled neurotransmitters to be investigated on the synapse level [10, 24, 29, 35, 40].

Since the ciliary ganglion in man was first described by Schacher in 1701, this nerve structure has been observed and described by several researchers

in several species of vertebrates including reptiles, birds and mammals [25, 36]. In reptiles the ciliary ganglion was first discovered by Lenhossek [26]. In birds this parasympathetic ganglion became one of the most frequently investigated autonomic structures, forming only single cell aggregation [1, 2, 5–7, 12, 28, 30]. This parasympathetic ganglion was seen to contain two kinds of neuronal cell bodies, large and small. Marwitt et al. [27] was the first to term the large and small cells ciliary and choroid neurons. The axons of large neurocytes formed the long ciliary nerve, whereas the axons of small cells formed the short ciliary nerves.

The results of many investigations on mammals revealed that the ciliary ganglia usually formed a large

main ganglion and several smaller cell aggregations, accessory ganglia [11, 17–20]. Only in the mouse was the ciliary ganglion different from the ganglion of other mammals. It was composed of several aggregations of nerve cells and formed a plexo-ganglionic structure around the nerves entering the orbit [21]. Nevertheless, there are no morphological studies (except a congress abstract [38]) of the ciliary ganglion in other species of the *Muridae* family. Because of this, observations have been made on its morphology, topography and cytoarchitectonics in the Egyptian spiny mouse (*Acomys cahirinus*, Desmarest), which belongs to the *Muridae* family, in order to complete the data and to carry out a comparative anatomical analysis.

MATERIAL AND METHODS

The studies were performed on 14 Egyptian spiny mice (*Acomys cahirinus*) of both sexes. The animals were deeply anaesthetised with ether and an intraperitoneal injection of Nembutal (20–40 mg/kg). Both orbit areas were dissected under a binocular microscope. The oculomotor and optic nerves from 10 animals were exposed. The material was then rinsed in a physiological solution and fixed for 30 min in 10% neutral formalin. The further procedures followed the thiocholine method [14] adapted for macromorphological investigation [9]. The whole content of the orbits from 4 animals were taken for histological examination, fixed in 4% neutral formaldehyde, embedded in paraffin and cut on a microtome into 5–8 μm sections (parallel to the equatorial plane of the eyeball). The sections were stained with Harris haematoxylin and eosin and using Nissl's techniques.

RESULTS

Histochemical studies

The ciliary ganglion of the Egyptian spiny mouse is a structure consisting of between 3 and 4 agglomerations of ganglionic neurocytes. The largest is elliptical in shape, 220 μm long and 100 μm wide. It is situated in the place where the ventral branch of the oculomotor nerve divides into two branches (Fig. 1). The first branch went to the straight muscle of the eyeball inferior and the second branch to the oblique muscle of eyeball inferior. The next two smaller and usually oval aggregations (170–200 μm long and 100–140 μm wide) were observed on the superior and lateral surfaces of the optic nerve where it crossed the oculomotor nerve (Fig. 2, 3). They were

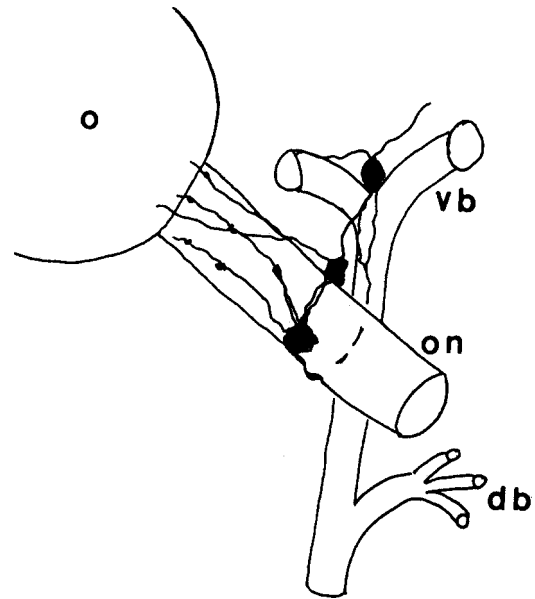


Figure 1. Scheme of topography of the ciliary ganglion in the Egyptian spiny mouse; o — orbita, on — optic nerve, db — dorsal branch of oculomotor nerve, vb — ventral branch of oculomotor nerve.

connected to each other with delicate intensively stained cholinergic fibres. By this means they created a band-like structure around the optic nerve. Furthermore, a small aggregation of nerve cells, 110 μm long and 25 μm wide, was observed on the ventral branch of the oculomotor nerve. From the main agglomerations of neurocytes arose 3 or 4 intensively stained postganglionic cholinergic nerve fibres. These left the cell aggregation and followed

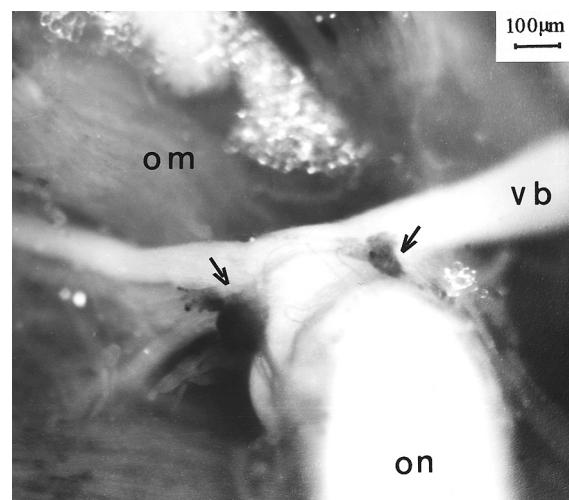


Figure 2. Two aggregations of nerve cells (arrows) on the surface of the optic nerve (on); om — orbit muscle, vb — ventral branch of oculomotor nerve. Thiocholine method.

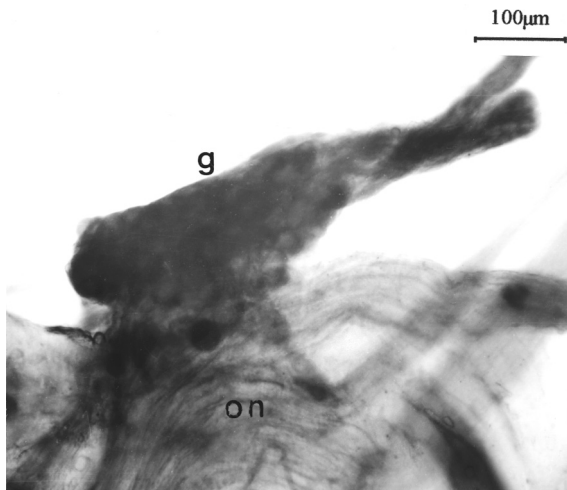


Figure 3. Elongated aggregations of ganglionic cells (g) on the surface of the optic nerve (on). Thiocholine method.

the optic nerve to the eyeball and *tunica adventitia* of the branches of the ciliary artery. For this reason they were interpreted as short ciliary nerves.

Histological studies

Histological examinations showed that the biggest agglomeration of neurocytes consisted of between 30 and 40 nerve cells in cross-section. It differs in shape from individual to individual but is most often triangular or elliptical. Laterally it is covered by the levator muscle of the upper eyelid and medially by the straight muscle of the eyeball inferior. The neurocytes have a compact arrangement, uniform over the whole surface of the sections. They have a large clear nucleus with a central dark nucleolus. The diameter of the neurocytes varied from 15 to 30 µm. A further two smaller aggregations of nerve cells were noticed at the dorsal and lateral surfaces of optic nerve. These consisted of between 10 and 25 nerve cells on the cross-section (Fig. 4, 5) and were located inside the perineurium. The arrangement of the cells was uneven with the nerve cells located mainly on the surface of ganglia. The remaining part was filled up by nerve fibres. Along the optic nerve (from the main ganglion towards the sclera) between 2 and 4 ciliary nerves were observed with small agglomerations of neurocytes (2 to 15 cells on the cross-sections) (Fig. 6). These were decreased in size to only 2 or 3-cell ganglia towards the sclera (Fig. 7). A characteristic feature of all the ganglia investigated was the presence of connective tissue capsules which surrounded the cell aggregations.

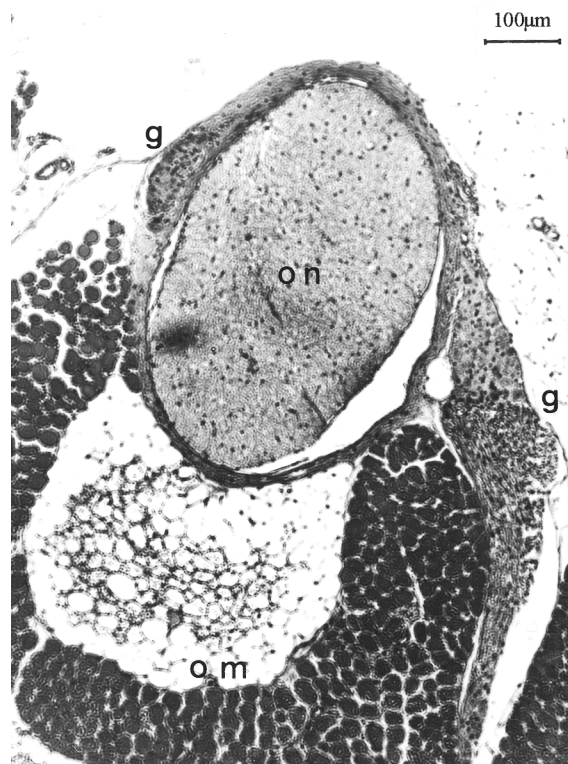


Figure 4. Cross-section through the orbit of the level of two nerve cell aggregations; on — optic nerve, g — ganglia, om — orbital muscle. H and E method.

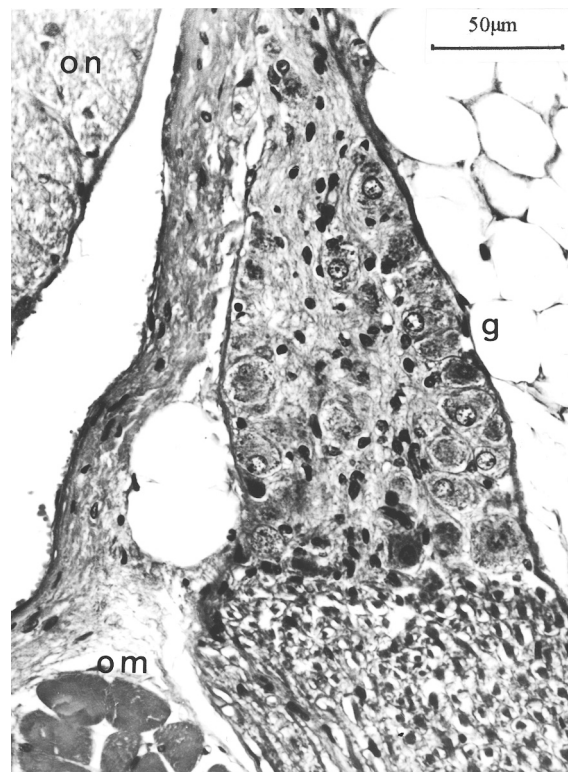


Figure 5. The lateral part of Figure 4 in higher magnification. Abbreviation as in Figure 4.

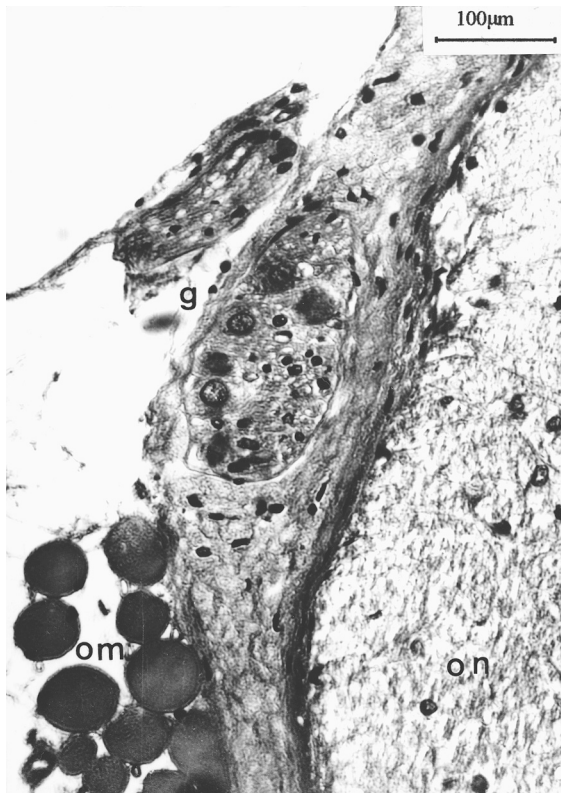


Figure 6. Cross-section through the short ciliary nerve and small accessory ciliary ganglion; g — ganglion, on — optic nerve, om — orbit muscle. H and E method.

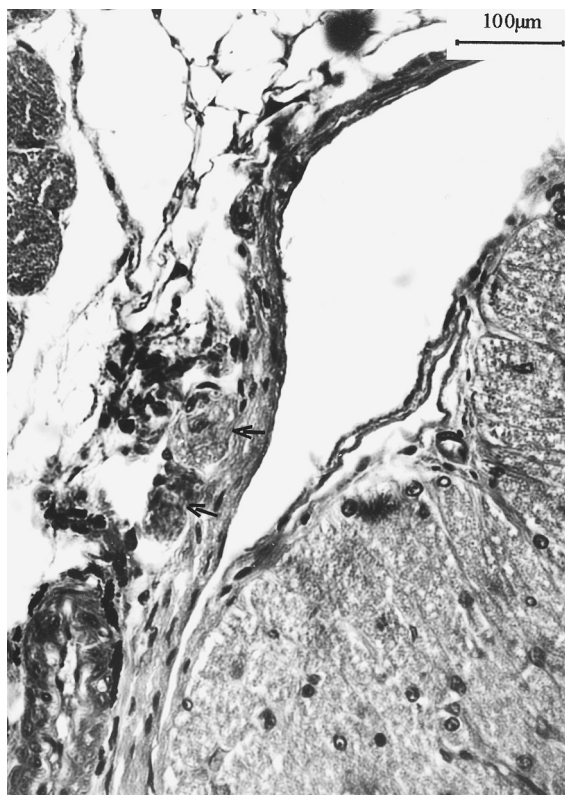


Figure 7. Section through the distal part of the optic nerve near the sclera with two ganglion cells (arrows). H and E method.

DISCUSSION

As the review of the literature indicates, the ciliary ganglion in reptiles is usually a single oval-shaped cluster of neurocytes. Exceptionally, in snakes, it can consist of two parts only [15, 26, 34]. The ciliary ganglion in birds is a large and conical in shape but always a single agglomeration of cells [1, 5, 7, 12, 27, 28, 30].

In most mammals the ciliary ganglion is a single agglomeration of nerve cells topographically connected with the oculomotor nerve [37, 39, 41]. In the cat, dog, horse, sheep, pig, deer, raccoon, marten, mid-day gerbil, rat, rabbit, spotted suslik, macaque and man accessory ciliary ganglia have been found as well as the main ciliary ganglion [8, 11, 13, 19, 23, 31, 33]. These were connected mostly with short ciliary nerves, which varied in size from some single-nerve cells to appreciable aggregations of neurocytes. The accessory ciliary ganglion in a cat consists of 300 cells. These accessory ganglia can probably be found in all species of mammals [17, 19].

The ciliary ganglion in the mouse differs from this structure in most mammals. This is a plexo-ganglion consisting of some (most frequently 5) aggregations of ganglionic cells connected to each other with bundles of postganglionic fibres [21]. The ganglion examined in the Egyptian spiny mouse, although similar to the plexo-ganglionic structure in a mouse, consisted of two large agglomerations of cells localised on both sides of the optic nerve crossing the oculomotor nerve. These two aggregations of neurocytes are connected to each other by a thick bundle of nerve fibres forming a kind of band around the optic nerve. In addition, further agglomerations of cells were found at the point of division of the ventral branches of the oculomotor nerve into a branch to the straight muscle of eyeball inferior and a branch to the oblique muscle of eyeball inferior. The postganglionic fibres, interpreted as the short ciliary nerves, were observed running to the eyeball along the optic nerve. Additional agglomerations of neurocytes, differing in size, were localised along the postganglionic fibres. According to Kuchiiwa's interpretation [19], the main ciliary ganglion in the Egyptian spiny mouse investigated consists of 3 aggregations of cells with additional smaller ciliary ganglia, accessory ciliary ganglia, inside the short ciliary nerves. In spite of some differences, there is similarity in the morphological relations of ciliary ganglion between the Egyptian spiny mouse (*Acomys cahirinus*) and the mouse (*Mus musculus*). This is linked to the close relationship between these two species of family *Muridae*. Moreover, a sim-

ilar morphology and topography of the ciliary ganglion has been observed in the chinchilla (*Chinchilla laniger*) [16]).

Another morphological type of ciliary ganglion was described in the Syrian hamster (*Mesocricetus aureatus*). In this species the ganglionic neurocytes, forming a single structure, were localised both on the surface and inside the oculomotor nerve. Because of this, the ciliary ganglion of the hamster is considerably different from the typical ganglion of other species of mammal [22].

It has been difficult to distinguish precisely between the motor and sympathetic roots of the ciliary ganglion in many species of vertebrate: mouse [21], Syrian hamster [22], rabbit [11] and man [36]. In some species, the sympathetic fibres pass to the eyeball through accessory ciliary ganglia [32].

REFERENCES

1. Abraham A, Stammer A (1969) Über die Struktur und die Innervierung der Augenmuskeln der Vogel unter Berücksichtigung des Ganglion ciliare. *Acta Biol*, 12: 87–191.
2. Blumenthal EM, Shoop RD, Berg DK (1999) Developmental changes in the nicotinic responses of ciliary ganglion neurons. *J Neurophysiol*, 81: 111–120.
3. Bustos DE, Atherton SS (2002) Detection of herpes simplex virus type 1 in human ciliary ganglia. *Invest Ophthalmol. Vis Sci*, 43: 2244–2249.
4. Cheng SB, Kuchiiwa S, Kuchiiwa T, Nonaka S, Nakagawa S (2001) Presence of neuronal nitric oxide synthesis in autonomic and sensory ganglion neurons innervating the lacrimal glands of the cat: an immunofluorescent and retrograde tracer double-labeling study. *J Chem Neuroanat*, 22: 147–155.
5. Cuthbertson S, White J, Fitzgerald ME, Shih YF, Reiner A (1996) Distribution within the choroid of cholinergic nerve fibers from the ciliary ganglion in pigeons. *Vision Res*, 36: 775–786.
6. Cuthbertson S, Zagvazdin YS, Kimble TD, Lamoreaux WJ, Jackson BS, Fitzgerald ME, Reiner A (1999) Preganglionic endings from nucleus of Edinger-Westphal in pigeon ciliary ganglion contain neuronal nitric oxide synthase. *Vis Neurosci*, 16: 819–834.
7. De Stefano ME, Ciofi-Luzzatto A, Mugnaini E (1993) Neuronal ultrastructure and somatostatin immunolocalization in the ciliary ganglion of chicken and quail. *J Neurocytol*, 22: 868–892.
8. Ehinger B, Falck B (1970) Uptake of some catecholamines and their precursors into neurons of the rat ciliary ganglion. *Acta Physiol Scand*, 78: 132–141.
9. Gienc J (1977) The application of histochemical method in the anatomical studies on the parasympathetic ganglia and nerve bundles of postganglionic axons in the sublingual region of some mammals. *Zool Pol*, 26: 187–192.
10. Grimes PA, Koeberlein B, Tigges M, Stone RA (1998) Neuropeptide Y-like immunoreactivity localizes to preganglionic axon terminals in the rhesus monkey ciliary ganglion. *Invest Ophthalmol Vis Sci*, 39: 227–232.
11. Grimes P, Sallman L (1960) Comparative anatomy of the ciliary nerves. *Arch Ophthal*, 64: 81–91.
12. Hammond WS, Yntema CL (1958) Origin of ciliary ganglia in the chick. *J Comp Neurol*, 10: 367–385.
13. Hume RI, Purves D (1983) Apportionment of the terminals from single preganglionic axons to target neurons in the rabbit ciliary ganglion. *J Physiol*, 388: 259–275.
14. Koelle GB, Friedenwald JS (1949) A histochemical method for localizing of cholinesterase activity. *Proc Soc Exp Biol Med*, 70: 617–622.
15. Kosierkiewicz D (1991) Uwagi na temat przywspółczulnego układu nerwowego gadów. *Przegląd Zool*, 35: 215–220.
16. Kuchinka J (2000) The ciliary ganglion in chinchilla (*Chinchilla laniger*, Molina). *Ann Anat Suppl*, 182: 52.
17. Kuchiiwa S (1990) Morphology of the accessory ciliary ganglion of the cat. *Anat Embryol*, 181: 299–303.
18. Kuchiiwa S, Kuchiiwa T, Suzuki T (1989) Comparative anatomy of the accessory ciliary ganglion in mammals. *Anat Embryol*, 180: 199–205.
19. Kuchiiwa S, Kuchiiwa T, Nakagawa S, Ushikai M (1993) Oculomotor parasympathetic pathway to the accessory ciliary ganglion bypassing the main ciliary ganglion by way of the trigeminal nerve. *Neurosci Lett*, 18: 79–82.
20. Kuchiiwa S, Kuchiiwa T, Nakagawa S (1994) Localization of preganglionic neurons of the accessory ciliary ganglion in the midbrain; HPR and WGA-HPR studies in the cat. *J Comp Neurol*, 340: 577–591.
21. Kuder T (1986) The ciliary ganglion in mouse. *Folia Morphol (Warsz)*, 45: 80–85.
22. Kuder T, Szczurkowski A (1987) Morphology, topography and cytoarchitectonics of the ciliary ganglion of Syrian hamster (*Mesocricetus auratus* W. 1839). *Zool Pol*, 34: 23–30.
23. Kuder T, Kuchinka J, Nowak E, Szczurkowski A, Radzimirska M (2003) A comparative study on the morphology and topography of the ciliary ganglion in midday gerbil (*Meriones meridianus*) and turtle (*Agrionemys horsfieldii*). *Ann Anat*, 185: 351–357.
24. Kuwayama Y, Grimes PA, Ponte B, Stone RA (1987) Autonomic neurons supplying the rat eye and the intraorbital distribution of vasoactive intestinal polypeptide (VIP)-like Immunoreactivity. *Exp Eye Res*, 44: 907–922.
25. Lecco TM (1994) Das Ganglion ciliare einiger Carnivoren. Ein Beitrag zur Lösung der Frage über die Natur des Ganglion ciliare. *Z Natur BI*, 1906, 41: 483–504.
26. Lenhosek M (1912) Das Ciliarenganglion der Reptilien. *Arch Mikrosk Anat Entw Mech*, 80: 89–116.
27. Marwitt R, Pilar G, Weakly JN (1971) Characterization of two ganglion cell population in avian ciliary ganglia. *Brain Res*, 25:317–334
28. Nowak E (1998) Morphology, topography and cytoarchitectonics of the ciliary ganglion in the Japanese quail (*Coturnix coturnix v. Japonica*). *Ann Anat Suppl*, 180: 323.
29. Nguyen D, Sargent PB (2002) Synaptic vesicle recycling two classes of release sites in giant nerve terminals of the embryos in chicken ciliary ganglion. *J Comp Neurol*, 448: 128–137.

30. Oehme H (1968) Das Ganglion ciliare der Rabenvogel (*Corvidae*). *Anat Anz*, 123: 271–277.
31. Petela L (1980) Gałęzie łączące zwoju rzęskowego właściwego i zwoju rzęskowego dodatkowego u dzika. *Pol Arch Vet*, 22: 445–451.
32. Poloiko TV (2001) Experimental anatomical data on the structure of retrobulbar nervous plexus in man and various laboratory animals. *Morfologija*, 119: 49–53.
33. Ruskell GL (1971) The distribution of autonomic post-ganglionic nerve fibers to the lacrimal gland in monkeys. *J Anat*, 109: 229–242.
34. Santamaria-Arnaiz P (1959) Le ganglion ciliare chez *Chalcides ocellatus*. *Korph Jb*, 101: 263–278.
35. Sechrist JW, Wolf J, Bronner-Fraser M (1998) Age-dependent neurotransmitter plasticity of the ciliary ganglion neurons. *Mol Cell Neurosci*, 12: 311–323.
36. Sinnreich Z, Nathan H (1981) The ciliary ganglion in man (Anatomical observations). *Anat Anz*, 150: 287–297.
37. Stammer A (1965) Histological and histochemical examinations on the ciliary ganglion of mammals. *Symp Biol Hung*, 5: 93–107.
38. Szczurkowski A, Kuchinka J, Nowak E, Kuder T (2003) The ciliary ganglion in Egyptian spiny mouse (*Acomys cahirinus*, Desmarest). *Ann Anat Suppl*, 185: 330–331.
39. Watanabe H (1972) The fine structure of the ciliary ganglion of the guinea pig. *Archiv Histol Jap*, 34: 261–276.
40. Wigston D J (1983) Maintenance of cholinergic neurons and synapses in the ciliary ganglion of aged rats. *J Physiol*, 344: 223–231.
41. Zhang YL, Tan CK, Wong WC (1994) The ciliary ganglion of the monkey: a light and electron microscope study. *J Anat*, 184: 251–260.