

# Iliolumbar membrane, a newly recognised structure in the back

M. Loukas<sup>1, 2</sup>, R.G. Louis Jr.<sup>1, 3</sup>, B. Van der Wall<sup>3</sup>, B. Hallner<sup>3</sup>, J.J. Tucker<sup>3</sup>, F. Esguerra<sup>3</sup>, G.L. Colborn<sup>4</sup>

<sup>1</sup>Department of Anatomical Sciences, St George's University, School of Medicine, Grenada, West Indies

<sup>2</sup>Department of Education and Development, Harvard Medical School, Boston, MA, USA

<sup>3</sup>Department of Anatomy, American University of the Caribbean, Sint Maarten, Netherlands Antilles

<sup>4</sup>Centers of Surgical Anatomy and Technique, Emory University, Atlanta, Georgia, USA

[Received 10 June 2005; Revised 12 December 2005; Accepted 12 December 2005]

*Despite intensive research in the anatomical sciences for the last two centuries, some structures of the human body still remain controversial or incompletely described.*

*We describe a new membranous fascial anatomical entity, which we refer to as the iliolumbar membrane (ILM). During the 2004–2005 academic semesters at the American University of the Caribbean School of Medicine we dissected 40 human cadavers fixed in formalin-alcohol-phenol solution. Iliolumbar membrane is a thick connective tissue structure, deep to the skin, originating from the fibres of the thoracolumbar fascia at the lateral border of the erector spinae. It runs inferior to the superior border of the iliac crest, lateral to the posterior superior iliac spine, overlying the iliac crest at the level of the 4<sup>th</sup> lumbar vertebra. Iliolumbar membrane terminates within subcutaneous fat, where it divides into multiple layers. All cadavers showed considerable variation in the blending of the membrane's multiple layers with the subcutaneous fat. However, all specimens consistently showed a uniform appearance of ILM at the point of origin. Iliolumbar membrane could be demonstrated objectively by ultrasound examination with a frequency of 7.5 MHz and also with a Stryker endoscope. A hypothesis is put forth, conjecturing that this new structure may have relevance in creating a natural barrier between the musculature of the back and the muscles of the gluteal region, similar to Scarpa's fascia of the anterior abdominal wall.*

**Key words:** thoracolumbar fascia, erector spinae muscles, gluteal region, iliac crest, low back pain, posterior superior iliac spine, lumbar hernia, cluneal nerve

## INTRODUCTION

A well established concept in anatomical textbooks is the existence of fascial membranes, which divide regional musculature into functional groups by defining separate and distinct anatomical compartments. The term "fascia" is used for the dis-

sectible, fibrous connective tissues of the body other than specifically organised structures such as tendons, aponeuroses and ligaments [3]. A fascial sheet may be thickened for either strength or padding, fused with another sheet or split into several layers. It may also be separated from another fascial sheet

by a plane of cleavage. Several sheets may also combine to form compartments for groups of muscles [3]. Although these fascial layers and planes are particularly prominent in the embalmed cadaver, they are also very real and significant structures in the living human. In addition to directing the physiological action of muscles, these fascial planes control and direct the spread of pathological fluids (pus, blood) and may play a crucial role in venous return [16]. One of the best known and most readily definable examples of this type of structure is the lateral intramuscular septum of the thigh.

The thoracolumbar fascia (TLF) is the deep fascial complex that forms the sheath of the erector spinae muscles, which in the lumbar region is considerably thickened. Extending laterally from the transverse processes of the lumbar vertebrae, the two laminae of TLF blend with the aponeuroses of the latissimus dorsi and internal oblique and transversus abdominus muscles. Inferiorly, TLF attaches to the medial crest of the sacrum, the lateral sacral crests, the iliolumbar ligaments and the iliac crests [3]. The attachments of the fascia may play an important role in lifting and load transfer between the trunk and limbs [3].

Although intramuscular septae are present to divide many of the functional muscle groups in the body, no reports could be found either in standard anatomical texts or in the literature which describe any fascial structure(s) between the musculature of the lumbar region and that of the gluteal region. However, despite the apparent lack of fascial support in this region, lumbar herniations tend not to descend into the gluteal region [15]. An anatomical explanation for this clinical behaviour has yet to be elucidated. The aim of this study, therefore, was to explore the fascial layers of the lumbar triangle in search of potential answers to this clinical conundrum.

## MATERIAL AND METHODS

We dissected 40 human cadavers during the academic semesters of 2004 and 2005 at the American University of the Caribbean School of Medicine. These comprised 30 male and 10 female cadavers with a mean age of 69 and a range of 62–81 years. All the cadavers were fixed with formalin-alcohol-phenol solution. None of the selected cadavers for this study, showed any previous history or signs of back surgery, trauma or evidence of scoliosis, kyphosis or lordosis.

Following preliminary examination images from all the dissected specimens were recorded with

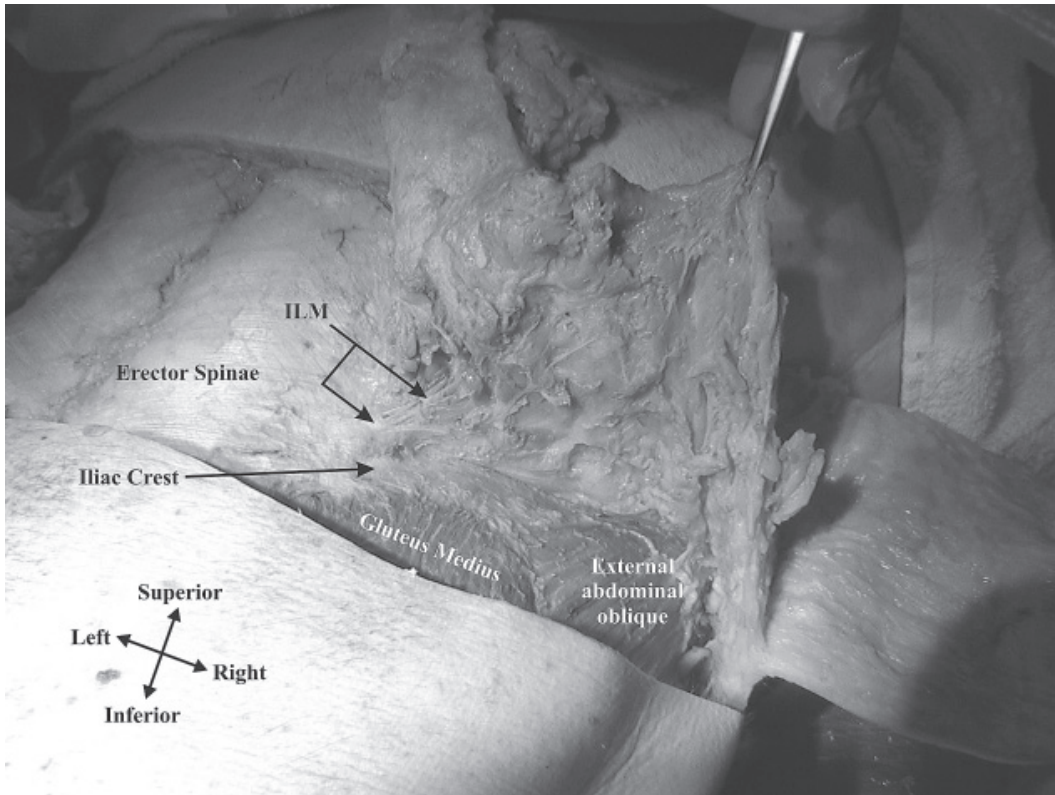
a Sony digital camera (model: Sony Cyber-Shot DSC-f717) and studied using a computer-assisted image analysis system [all measurements were carried out with the Lucia program (1998 edition for Windows), made by Nikon (Laboratory Imaging Ltd., Precoptic Co., Medical and Optical Instruments, Poland)] as previously described [9]. The digital camera was connected to an image processor (Nvidia Riva TNT model 64) with linkage to a mainframe computer. Digitised images of ILM, together with their surrounding structures, were stored in the Lucia program (1152 × 864 pixels), and converted to intensity grey levels from 0 (darkest) to 32 bit (lightest). After applying a standard 1 mm scale to all pictures within the program, Lucia was able to use this information to calculate pixel differences between two selected points (ex. origin-termination). The purpose of the software was to allow easy and accurate translation of pixel differences into metric measurements.

Furthermore, an additional 10 cadavers were examined using a GE General Electric model 3200S ultrasound machine with a 7.5 MHz linear probe. The aforementioned cadavers were also examined using a Stryker laparoscopic unit including a Stryker Quantum 4000 light source, Stryker 3-chip camera system and a Wolf 5 mm × 30 cm 0 degree laparoscope. Images were recorded with ESS image capture and catalogue software.

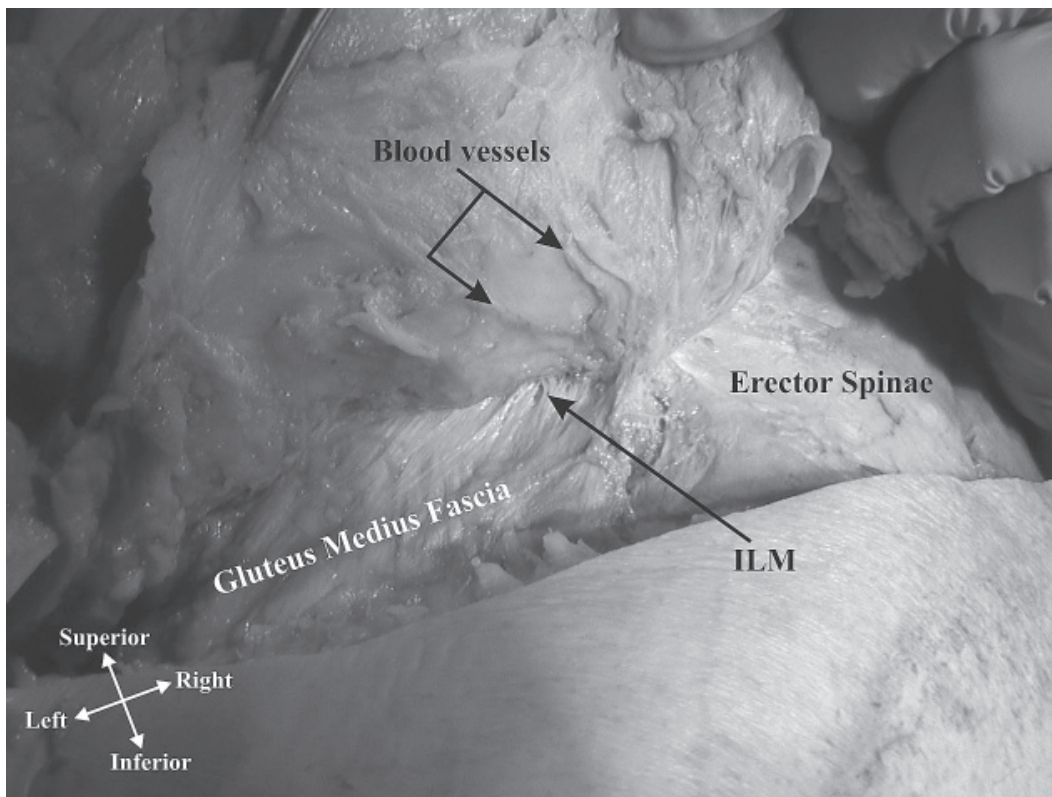
## RESULTS

### Gross anatomy

During anatomical gross dissections of the lumbar triangle the skin was carefully reflected, beginning with a vertical incision at the midline, stretching from the L1 to S1 vertebral levels. A second incision was made horizontally, arising from the inferior extent of the original midline incision and stretching laterally to the mid-axillary line. After exposing and reflecting the superficial fascia, we noticed several layers of what appeared to be fascial septae within the subcutaneous fat. These septae were traced deeply, where they seemed to converge, forming a thick connective tissue membrane, originating from the fibres of the thoracolumbar fascia at the lateral border of the erector spinae. This membrane ran within the transverse plane at the superior border of the iliac crest lateral to the posterior superior iliac spine and resembled a fibrous septum (Figs. 1, 2). The fascial membrane terminated anteriorly within the subcutaneous fat, where it divided into multiple layers, anchoring



**Figure 1.** This figure demonstrates a dissected specimen of ILM, which can be seen arising from the lateral border of the erector spinae muscle and travelling in the transverse plane towards the subcutaneous fascia.



**Figure 2.** This figure demonstrates the fusion of ILM with the superior fibres of the gluteus medius fascia. Evident here are blood vessels within the subcutaneous fat.

within the superficial fascia. On the lateral border ILM had a tendency to blend with the deep fascia over the lateral border of the latissimus dorsi and external abdominal oblique muscles.

All the cadavers showed such variation in the blending of the multiple layers of ILM within the subcutaneous fat that no recognisable pattern could be identified. However, all specimens consistently showed a uniform appearance of ILM at the point of origin. No significant differences were observed between male and female cadavers or with regard to age or race.

In considering the dimensions both thickness and width from the point of origin were measured. The thickness was measured immediately lateral to the point of origin and was found to be < 2 mm. The width of the membrane was measured from the point of origin medially (the lateral border of the erector spinae muscle) towards its point of division into multiple septae within the subcutaneous fat. The mean width was found to be 6.5 cm with a range of 4.8 cm to 8.8 cm. No significant differences in width or thickness were noticed with regard to age, race or gender. We were unable to mea-

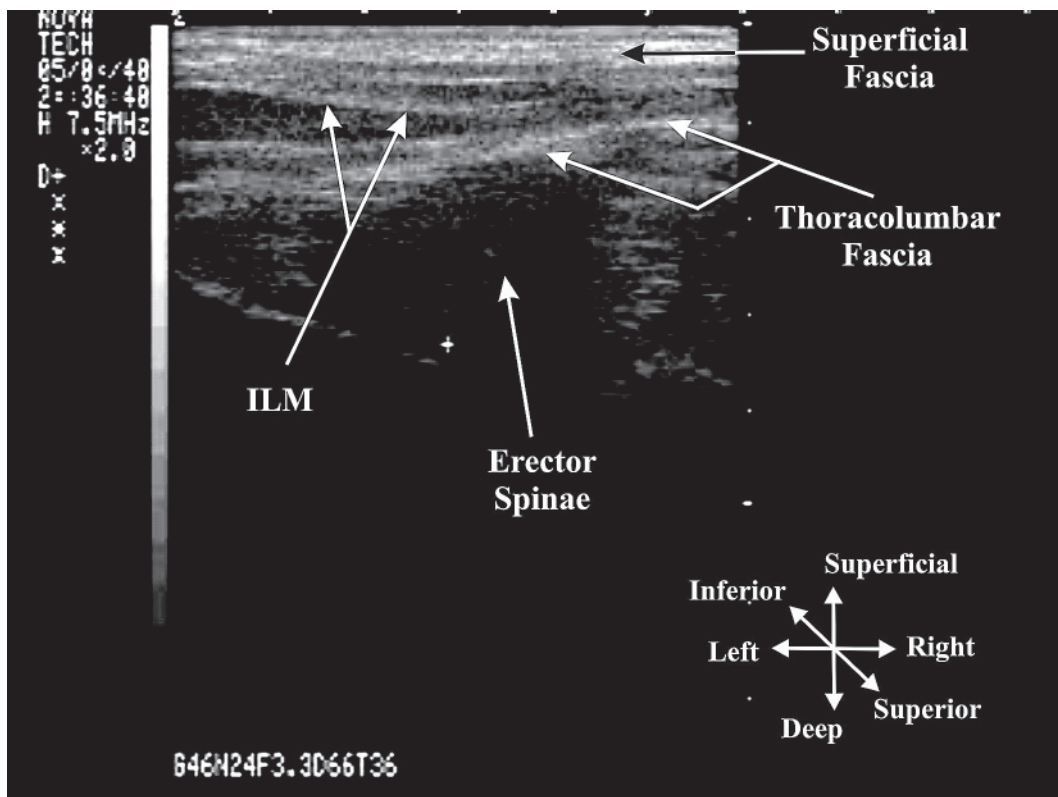
sure the degree of subcutaneous fat and therefore unable to discern any related variations.

**Ultrasonographic findings**

The fascial membrane could be demonstrated objectively by ultrasonographic examination with a frequency of 7.5 MHz (Fig. 3). With the use of the aforementioned reference points the width and thickness of the membrane were measured and found to be within the same ranges as those described grossly.

**Endoscopic findings**

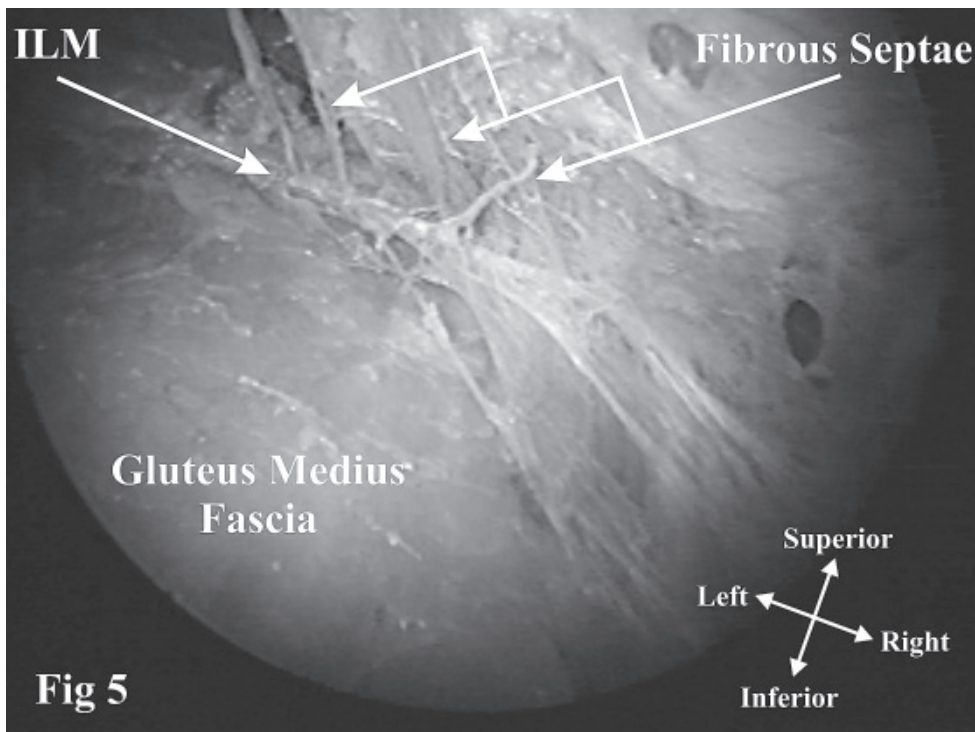
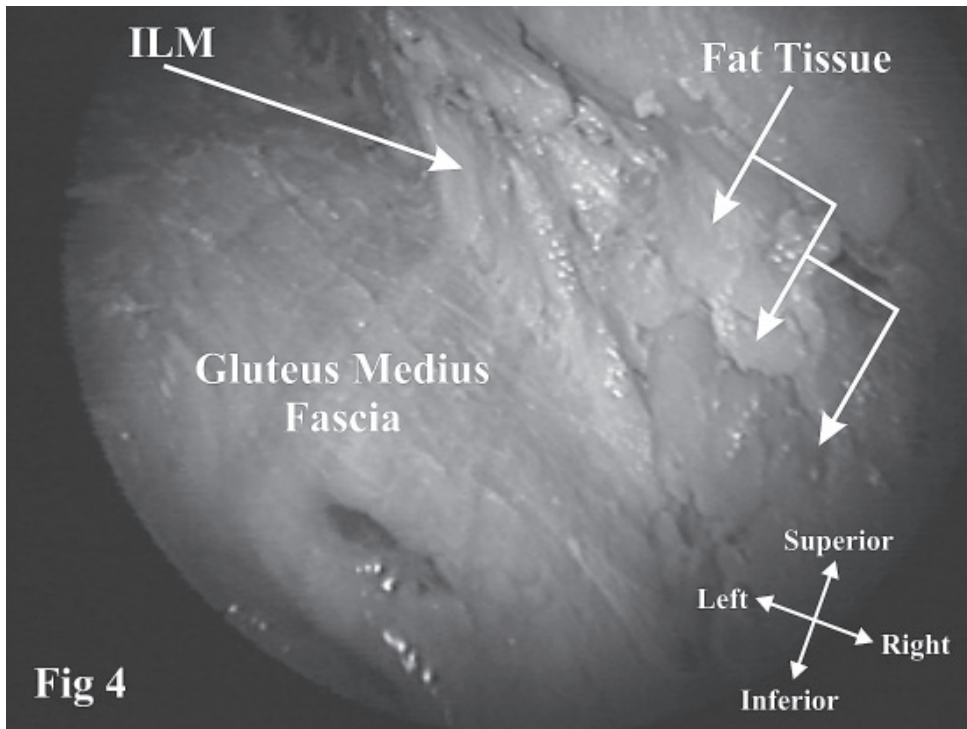
Access to the lumbar triangle was gained using a modified version of a procedure designed for latissimus dorsi flap harvest [8]. Using a 5 mm trocar, a Wolf 5 mm x 30 cm 0 degree laparoscope was inserted through an incision in the scapular line at the level of L5. Two additional trocars were inserted for instrumentation, the first along the posterior axillary line at the level of L4 and the second along the paravertebral line also at the level of L3. With the use of this technique the structure could be clearly visualised bilaterally in all specimens.



**Figure 3.** This figure show an ultrasound image of ILM as demonstrated from a posterior approach. The ultrasound image is a transverse section (horizontal plane) of the muscles of the back (and the associated fascia layers) with the probe placed perpendicular to the horizontal plane. Iliolumbar membrane border appears to be well demarcated from the thoracolumbar fascia inferiorly and the superficial fascia superiorly.

"Iliolumbar membrane" was found to be fused with the superior border of the gluteus medius fascia near its origin at the iliac crest (Figs. 4, 5). Adipose tissue was interspersed among the most su-

perficial fibres of the membrane. Few penetrating blood vessels were observed entering the membrane either superiorly or inferiorly and no innervation was noted.



**Figures 4, 5.** These figures represent endoscopic images of ILM as demonstrated from an inferior approach. Specifically, Figure 4 demonstrates ILM continuity with the gluteus medius fascia, while Figure 5 demonstrates the septation of ILM within the subcutaneous fat.

## DISCUSSION

The lumbar area of the posterior body wall is bounded superiorly by the 12<sup>th</sup> rib, inferiorly by the iliac crest, posteriorly by the erector spinae and anteriorly by the external oblique. In this area the body wall is composed of the following layers: skin, superficial fascia, thoracolumbar fascia, a middle muscular layer including the sacrospinalis, internal oblique and serratus posterior inferior, a deep muscular layer including the quadratus lumborum and psoas major, the transversalis fascia, preperitoneal fat and, most deeply, the peritoneum [15]. On the basis of its location within the lumbar triangle the authors propose a possible description of this structure as the "iliolumbar membrane".

The lumbar triangle is the primary site for lumbar herniation, which can be classified as either superior or inferior, on the basis of its occurrence within the superior and inferior lumbar triangles respectively [15]. Spontaneous lumbar hernias are more common in the superior lumbar triangle, whereas inferior triangle hernias are more common following surgical procedures, such as iliac crest bone graft harvesting [1, 3, 4].

Regardless of their location, lumbar hernias have rarely been known to descend into the gluteal region, even when the size of the herniation is large enough to occupy the entire inferior lumbar triangle. This is in contrast to other body wall herniations, particularly the inguinal, umbilical, or femoral [15]. In consideration of this clinical point, it is possible to hypothesise the existence of an anatomical barrier, which separates the lumbar and gluteal regions, very similar to Scarpa's fascia anteriorly. However, to the best of our knowledge, no such structure has previously been described in the literature.

According to Skandalakis et al. [15], Scarpa's fascia of the lower abdominal anterior abdominal wall possesses regional peculiarities. It is attached to the crest of the ilium and to the pubic symphysis but not to the superior border of the pubic crest. More laterally, Scarpa's fascia is attached to the fascia lata of the thigh. However, Scarpa's fascia is not continuous to the back. We are unaware of the exact anatomical location at which Scarpa's fascia ends laterally to the abdominal wall. We can only suggest that it most likely attaches to the muscular fascia laterally, as it does below to the fascia lata and above to the pectoral fascia. Furthermore, clinically, extravasating fluid from the perineal region can pass superiorly deep to this fascial layer, extending up to the

breast region, although this is limited by the pectoral fascia. There are no reports indicating the passage of fluid into the back.

The anatomical structure of skin ligaments (retinacula cutis) in the head, breast, palmar surface of the hands and plantar skin of the feet are well documented [2, 5, 7, 12, 17, 19]. There is little published evidence, however, that skin ligaments occur in other regions of the body. A recent study by Nash et al. [personal communication] explored the skin ligaments in the upper and lower limbs, as well as the trunk and head and neck. Their results showed that skin ligaments of the trunk are presented as a continuous peripheral network of fibrous connective tissue in the subcutaneous tissue (superficial fascia in our case). The fibre bundles consisted of a collection of retinacular fibres that ran from the external layer of the deep fascia and formed tenuous linkages with the base of the dermis, separating the subcutaneous tissue into two or three layers [13]. It is possible that a skin ligament over the iliac crest is very strong and thick and resembles a tough membrane structure, such as the iliolumbar membrane. Because we have not yet performed histology, we are unable to judge whether this is the case.

Although, the function of ILM is unknown, it has been shown to be continuous and therefore could act as a barrier to the descent of lumbar hernias into the gluteal region. The relative thickness and stability of ILM may operate in conjunction with the iliac crest to stabilise the hernia and prevent rapid expansion inferiorly. The functional role of ILM as a lumbogluteal barrier is exemplified by the case described by Thomas et al. [personal communication] as an inferior lumbar hernia extending to the lower limb though a defect in the iliac crest. It is interesting to note that the cause of the lumbar hernia in that case was related to traumatic injuries sustained in a motor vehicle accident. Unlike most body wall herniations, which occur secondary to increased intra-abdominal pressure, the mechanism of injury in this case could additionally have led to rupture of ILM. The resulting loss of this fascial barrier could have allowed for descent of the hernial contents into the gluteal region. Direct supporting evidence for this role is lacking, although surgical procedures that disrupt both structures show an increased incidence of inferior lumbar hernias [1, 3, 4].

It is also possible, that ILM may serve as barrier against the spread of extravasated fluid and haematomas from the lumbar region inferiorly into the gluteal region.

Furthermore, ILM may be involved in the pathophysiology of chronic low back pain secondary to entrapment of the cluneal nerves. The superior cluneal nerves are lateral cutaneous branches of the dorsal rami of L1, L2, and L3, which cross the iliac crest to supply the skin of the gluteal region [16]. A study by Lu et al. [10] examined the distribution of the superior cluneal nerves and described their topography as it related to TLF. In their study Lu et al. [10] reported that the medial branch of the superior cluneal nerve may become entrapped between TLF and the iliac crest. Clinically it has been considered that a taut palpable band of localised tenderness and referred pain 7 to 8 cm lateral to the midline at the level of the posterior iliac crest is characteristic of entrapment of the superior cluneal nerve [6, 10, 11, 14, 18]. It is therefore possible to hypothesise that cluneal nerve entrapment may also occur as these nerves cross ILM and descend into the gluteal region. It is unknown whether the increased strain of obesity may lead to thickening of ILM and, therefore, increase the possibility of the cluneal nerve entrapment.

In exploring the newly described ILM the present authors hope to have opened a new avenue for further research into the pathophysiology of lumbar hernias and low back pain. We strongly believe that additional studies are needed to investigate the role of this structure and its potential clinical significance.

### Limitations

The present study was unable to explore the histological features of ILM and further investigation is needed to prove the existence of elastin fibres in order to determine if the classification of “membrane” is appropriate. Additionally, we were also unable to measure the degree of subcutaneous fat and therefore determine the existence of any possible correlation related to this data. Furthermore, in calculating the width of ILM, the point of termination was considered to be the point at which ILM was no longer recognisable as a continuous structure. It is possible that during gross dissection of ILM the actual point of termination became obscured as multiple septae arose, confounding morphometric analysis.

### ACKNOWLEDGEMENTS

The authors would like to thank Professor Robert Jordan, Chairman of the Department of Anatomical Sciences at St George’s University, for his valuable comments and suggestions during the preparation of the manuscript.

### REFERENCES

1. Auleda A, Bianchi R, Tibau, Rodriguez-Cano O (1995) Hernia through iliac crest defects: A report of four cases. *Int Orthop*, 19: 367–369.
2. Bojsen-Moller F, Flagstad KE (1976) Plantar aponeurosis and internal architecture of the ball of the foot. *J Anat*, 121: 599–561
3. Clemente CD (1985) *Gray’s anatomy*, 30<sup>th</sup> Ed., Williams and Wilkins, pp. 431.
4. Forrest C, Boyd B, Manktelow R (1992) The free vascularised iliac crest tissue transfer: donor site complications associated with eighty-two cases. *Br J Plast Surg*, 45: 89–93.
5. Furnas DW (1989) The retaining ligaments of the cheek. *Plast Reconstr Surg*, 83: 11–16.
6. Garvey TA, Marks MR, Wiesel SW (1992) A prospective randomized double blind evaluation of trigger point injection therapy for low-back pain. *Spine*, 17: 1474–1480.
7. Gratzner J, Vokt CA, Brenner P (2001) Morphological and functional interface between palmar plates of metacarpophalangeal joints and intrinsic muscles of the hand. *Handchir Mikrochir Plast Chir*, 33: 299–309.
8. Jones DB, Wu JS, Soper NJ (2004) *Laparoscopic surgery principles and procedures*. 2<sup>nd</sup> Ed. Marcel Dekker INC, pp. 495–500.
9. Loukas M, Hullett J, Wagner T (2005) The clinical anatomy of the inferior phrenic artery. *Clin Anat*, 18: 357–365.
10. Lu J, Ebraheim N, Huntoon M, Heck B, Yeasting R (1998) Anatomic considerations of the superior cluneal nerve at the posterior iliac crest region. *Clin Orthop*, 347: 224–228.
11. Maigne JY, Maigne R (1991) Trigger point of the posterior iliac crest; painful iliolumbar ligament insertion or cutaneous dorsal ramus pain? An anatomic study. *Arch Phys Med Rehabil*, 72: 734–737.
12. Nash LG, Phillips MN, Nicholson H, Barnett R, Zhang M (2004) Skin ligaments: Regional distribution and variation in morphology. *Clin Anat*, 17: 287–293.
13. Nava M, Quattrone P, Riggio E (1998) Focus on the breast fascia system: a new approach for inflammatory fold reconstruction. *Plast Reconstr Surg*, 102: 1034–1045.
14. Patten LC, Awad SS, Berger DH, Fagan SP (2004) A novel technique for the repair of lumbar hernias after iliac crest bone harvest. *Am J Surg*, 188: 85–88.
15. Skandalakis JE, Skandalakis PN, Skandalakis LJ (2000) *Surgical anatomy and technique*. 2<sup>nd</sup> Ed. Springer Verlag, pp. 223–228.
16. Standing S, Ellis H, Healy C, Johnson D, Williams A (2005) *Gray’s anatomy: the anatomical basis of clinical practice*. 39<sup>th</sup> Ed. Elsevier, Churchill Livingstone, pp. 1399.
17. Stuzin JM, Baker TJ, Gordon HL (1992) The relationship of the superficial and deep facial fascias: relevance to rhytidectomy and aging. *Plast Reconstr Surg*, 89: 441–451.
18. Yang D, Morris S, Geddes C, Tang M (2003) Neurovascular territories of the external and internal oblique muscles. *Plastic Reconstr Surg*, 112: 1591–1595.
19. Zancolli EA, Zancoli ER (1984) Congenital ulnar drift and camptodactyly produced by malformation of the retaining ligaments of the skin. *Bull Hosp Jt Dis Orthop Inst*, 44: 558–576.