

The morphometry of the accessory leaflets of the tricuspid valve in a four cuspidal model

M. Skwarek¹, J. Hreczecha², M. Dudziak³, J. Jerzemowski⁴, B. Wilk¹, M. Grzybiak³

¹Department of Sports Medicine, the Jędrzej Śniadecki Academy of Physical Education and Sport, Gdańsk, Poland

²Department of Clinical Anatomy, Medical University, Gdańsk, Poland

³Non-invasive Cardiovascular Diagnostic Unit, Institute of Cardiology, Medical University, Gdańsk, Poland

⁴Department of Anatomy and Anthropology, the Jędrzej Śniadecki Academy of Physical Education and Sport, Gdańsk, Poland

[Received 13 March 2007; Revised 3 August 2007; Accepted 15 August 2007]

The tricuspid valve is of great importance because of the progress made in operative techniques and invasive cardiology accidents. This structure is more differentiated during evolution than the mitral valve. Accessory leaflets, their frequency and role are still controversial, despite the fact that they have been known from the beginning of the 20th century. The number of leaflets in the tricuspid valve grows in an evolutionary line, but the rules governing their appearance are still not known. The samples were taken from a group of 107 human adult hearts. The four-cuspidal form of the tricuspid valve was used as the simplest model to show the appearance of accessory leaflets for anatomical and statistical examination. On the basis of the results of this study we conclude that the separation of accessory leaflets is a complex process.

Key words: tricuspid valve, morphometry, right atrioventricular orifice

INTRODUCTION

Understanding of the tricuspid valve remains important because of progress in cardiac surgery, including the partial transfer of the posterior leaflet of the tricuspid valve for repair of the mitral valve [11, 13], tricuspid replacement [4, 5], complications after heart transplantation [7], invasive cardiology [17] and valvuloplasty [24]. Many congenital malformations involve the tricuspid valve [10, 22, 23, 25, 33]. Complications of the right atrioventricular valve because of infection may be an indication for surgical treatment [21, 35].

The tricuspid valve is more differentiated during evolution than the mitral valve [1, 16, 31, 32]. Atavistic features and atypical forms of the tricuspid valve and the distribution of its tendinous chords (*chordae tendineae cordis*) and their connection with

the papillary muscles occur in a small percentage of human hearts [9, 20, 26–33]. The number of cusps in the tricuspid valve increases in an evolutionary line [31, 32], but the rules of division of the main leaflets are unknown. The four-cuspidal form of the tricuspid valve was used as the simplest model for anatomical and statistical examination of the origin of accessory leaflets.

The objectives of the present study were to examine the following:

- the attachment length of the main leaflets (anterior, posterior and septal);
- the attachment length of the accessory leaflets;
- the attachment length in particular walls of the right ventricle (the distances between particular angles of the right ventricle).

Address for correspondence: J. Hreczecha, Department of Clinical Anatomy, Medical University of Gdańsk, Dębinki 1, 80–211 Gdańsk, Poland, tel./fax: +48 58 3491420, e-mail: chanastra@interia.pl

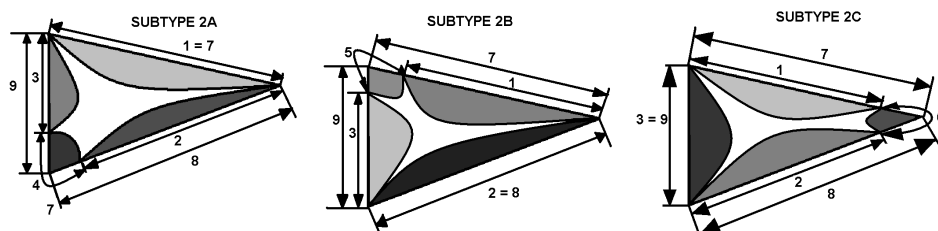


Figure 1. Scheme of location of accessory cusps in subtypes of Type 2.

MATERIAL AND METHODS

The examinations were carried out on 107 human hearts of adults (30 women and 77 men), ranging in age from 18 to 90 years (mean age 41.66 ± 15.87 years), who had died because of non-vascular disease and who did not display congenital malformations or pathological changes. The hearts were formalin-fixed. Dissection was performed according to standard techniques: from the superior vena cava and along the sharp margin of the right ventricle. A group of 45 tricuspid valves, classified according to an earlier scheme [15, 28] as Type 2, was identified. This group contained 11 female and 34 male hearts, ranging in age from 18 to 90 years (mean age 39.63 ± 15.14 years). On the basis of the location of the accessory leaflets, subtypes of Type 2 were identified:

- subtype 2A: an accessory leaflet (Cac) between the posterior cusp (CP) and the septal cusp (CS), a group of 24 hearts;
- subtype 2B: Cac between the anterior cusp (CA) and the CS, a group of 10 hearts;
- subtype 2C: Cac the CA and the CP, a group of 11 hearts.

Afterwards, using a flexible millimetre ruler, the following measurements were made [9] (Fig. 1):

- the attachment length of the main leaflets: anterior [1], posterior [2] and septal [3];
- the attachment length of the accessory leaflets in particular subtypes: 2A [4], 2B [5], 2C [6];
- the length of the tricuspid attachment in particular walls of the right ventricle: anterior [7], posterior [8], and septal [9].

Measurements 1, 2, 3 and 5 for an example of valve type 2B are shown in Figure 2, and measurements 7, 8 and 9 are shown in Figure 3.

The results obtained were statistically analysed by Pearson's analysis and one way analysis of variance (ANOVA; $p < 0.05$).

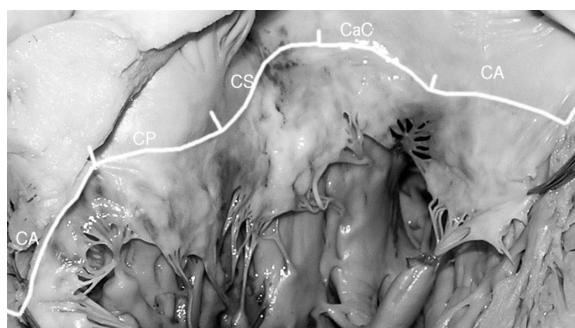


Figure 2. Example of measurements of the attachment leaflets in valve Type 2B. The attachment length of the main leaflets — anterior (CA-cut and shown in 2 parts), posterior (CP), septal (CS) and accessory leaflet (CaC).

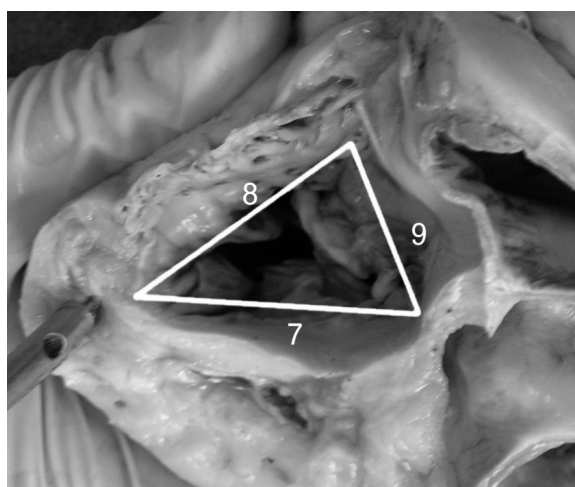


Figure 3. Example of measurements of the tricuspid attachment in particular walls of the right ventricle. Tricuspid attachment in particular walls of the right ventricle — anterior (7), posterior (8), and septal (9).

RESULTS

The length of the anterior wall of the right ventricle (dimension 7) was 34 ± 6.9 mm, the posterior wall (dimension 8) was 31 ± 9 mm and the septal

Table 1. Values and SD of length and percentage of length circuit for main and accessory leaflets

Subtype of valve	Leaflet	Length of leaflet [mm]		Percentage of length circuit	
		Mean	SD	Mean	SD
Subtype 2A	CA (dimension 1)	35.34	8.36	32.35	6.08
	CP (dimension 2)	22.66	6.99	20.85	5.50
	CS (dimension 3)	32.76	7.77	30.99	8.08
	CAC (dimension 4)	16.73	6.96	15.07	5.81
Subtype 2B	CA (dimension 1)	33.85	8.97	30.04	8.87
	CP (dimension 2)	28.4	7.66	25.25	7.09
	CS (dimension 3)	34.36	11.84	29.78	7.62
	CAC (dimension 5)	15.93	4.47	13.94	3.37
Subtype 2C	CA (dimension 1)	35.82	5.21	32.85	3.78
	CP (dimension 2)	25.45	6.93	22.34	5.77
	CS (dimension 3)	30.95	8.29	28.27	6.37
	CAC (dimension 6)	15.14	4.57	13.89	4.08

Table 2. Correlation between length of accessory leaflets and main leaflets adhering to them

Subtype 2A	CS	CAC	CP	CAC	CS	CP
Pearson	-0.2009		0.2940		-0.5495	
p	70.00%		77.58%		85.00%	
Subtype 2B	CA	CAC	CS	CAC	CA	CS
Pearson	-0.1900		0.6358		0.2511	
p	54.55%		82.79%		60.50%	
Subtype 2C	CA	CAC	CP	CAC	CA	CP
Pearson	0.3238		0.3313		-0.3533	
p	66.92%		67.42%		68.89%	

wall (dimension 9) was 29.32 ± 4.74 mm. Table 1 presents the mean values and SD of the length and percentage of length circuit for the main and accessory leaflets in particular subtypes of the four-cuspidal form of the tricuspid valve.

Table 2 presents the statistical results for the correlation between the length of the main and accessory cusps shown in the column heading and the length of particular walls of the right ventricle in particular subtypes of type 2.

Strong negative correlations (Pearson: -0.549) were noticed between CP and CS and between CS and CAC in subtype 2A.

In subtype 2B a high positive correlation was observed between CS and CAC, while lower correlations were noticeable between these and CA, these being positive between CA and CS and negative between CA and CAC.

A small negative correlation between CA and CP was observed in subtype 2C.

Table 3 presents the statistical results for the ratio of the sum of the attachment lengths for the main and accessory leaflets shown in the column heading and the length of the tricuspid attachment in particular walls of the right ventricle. On the basis of the statistics shown in Table 2 we reach the following conclusions:

- subtype 2A: the correlation between the accessory leaflet and the septal part of the tricuspid valve is stronger than that between the septal leaflet and the septal part of the attachment;
- subtype 2B; there is a strong negative correlation between the anterior part of the attachment and the accessory leaflet;
- subtype 2C: no statistically significant correlation was observable.

Table 3. Correlation between accessory leaflets and main leaflets adhering to them

Subtype 2A	CAC	CS	CS + CAC	CAC	CP	CP + CAC
Pearson	0.3017	0.0414	0.2572	0.4048	0.3242	0.4524
p	88.00%	18.00%	82.00%	95.20%	87.00%	97.10%
Subtype 2B	CAC	CA	CA+ CAC	CAC	CS	CS+ CAC
Pearson	-0.7576	0.2206	-0.1528	0.3196	0.6092	0.5730
p	98.69%	45.71%	32.56%	72.94%	92.90%	91.33%
Subtype 2C	CAC	CP	CP + CAC	CAC	CA	CA + CAC
Pearson	-0.3831	-0.3531	-0.4439	-0.194	0.1410	0.0809
p	75.47%	70.97%	82.39%	4.46%	31.61%	18.61%

The correlations between the anterior, posterior and septal parts of the attachment of the tricuspid valve and accessory leaflets were calculated. The statistics obtained showed no clear correlation which could explain which leaflets divided into main and accessory cusps. The correlations are comparable and the thesis that accessory cusps originate from different main leaflets may be accepted.

DISCUSSION

The tricuspid valve is a heterogeneous structure. The leaflets of the tricuspid valve develop from endocardial cushions and the myocardium, which comes from two sources, namely the tricuspid gully complex and the supraventricular crest [15]. The number of leaflets in the tricuspid valve increases during evolution [6, 19, 31, 32], but the rules of this process are unknown. Atavistic features and atypical forms of the tricuspid valve and the distribution of the tendinous chords and their connection with the papillary muscles occur in a small percentage of human hearts [9, 20, 26, 27, 29, 31, 32, 34]. Bi-divisible leaflets are also observed in some primates [31, 32]. On the basis of this, the thesis was put forward that the accessory leaflet had separated from the main leaflet.

We based our thesis on our findings, which showed that, if accessory cusps are separated directly from the main leaflets, there is a correlation between the length of the accessory and maternal main leaflets and the attachment length of the analogical wall of the right ventricle, and also that there is no correlation between the length of an accessory and another main leaflet adhering to it and the wall of the right ventricle.

On the basis of the results of this study we conclude that the separation of accessory leaflets is a complex process and that it is impossible to make explicit connections with the main leaflets from which

the accessory ones have separated. The explanation of the mechanism of the separation of accessory leaflets may be linked to the question of the different sources of the tissues which form the cusps and their non-synchronised phylo- and ontogenetic development [1, 2, 6, 9, 19]. The role of differences in tension in particular parts of the tricuspid valve during leaflet formation is unknown [14, 18].

The mechanism of the separation of the accessory cusps is a complex process and demands further study of groups of human foetal hearts and the hearts of other primates. This will be the subject of our next study.

REFERENCES

1. Anderson RH, Benson R, Wilcox MD (2000) Reply. *Ann Thorac Surg*, 69: 1990.
2. Anderson RH, Webb S, Brown NA, Lamers W, Moorman A (2003) Development of the heart: (2) Septation of the atriums and ventricles. *Heart*, 98: 949–958.
3. Benninghoff A (1933) Herz. In: Goppert E (ed) *Handbuch der vergleichenden Anatomie der wirbeltiere*. Vol. VI. Urban and Schwarzenberg, Berlin–Wien: 346–389.
4. Cardarelli MG, Gammie JS, Brown JM, Poston RS, Pierson RN 3rd, Griffith BP (2005) A novel approach to tricuspid valve replacement: the upside down stentless aortic bioprosthesis. *Ann Thorac Surg*, 80: 507–510.
5. Carrier M, Hebert Y, Pellerin M, Bouchard D, Perrault LP, Cartier R, Basmajian A, Page P, Poirier NC (2003) Tricuspid valve replacement: an analysis of 25 years of experience at a single center. *Ann. Thorac. Surg*, 75: 47–50.
6. Cayré R, Valencia-Mayoral P, Coffe-Ramirez V, Sánchez-Gómez C, Angelini P, De la Cruz MV (1993) The right atrioventricular apparatus in the chick heart. *Acta Anat*, 148: 27–33.
7. Crumbley AJ, Van Bakel AB (1994) Tricuspid valve repair for biopsy-induced regurgitation after cardiac transplantation. *Ann Thorac Surg*, 58: 1156–1160.
8. Dimas VV, Grifka RG, Fraser CD Jr (2004) Combined tricuspid valvuloplasty and superior cavopulmonary anastomosis for repair of traumatic tricuspid valve injury. *Tex Heart Inst J*, 31: 418–20. Comment in: *Tex Heart Inst J* (2005) 32: 114; author reply 114.

9. Dudziak M (1984): Budowa pierścienia włóknistego zastawki przedsionkowo-komorowej prawej serca u człowieka w rozwoju osobniczym. Rozprawa doktorska. Gdańsk.
10. Hartyanszky I, Prodan Z, Kiraly L, Mihalyi S, Bodor G, Tamas C, Lozsadi K (2005) Challenges in the surgical management of hearts with functional single ventricle. *Orv Hetil*, 33: 1721–26.
11. Hvass U, Juliard JM, Assayag P, Laperche T, Pansard Y, Chatel D (1996) Tricuspid autograft for mitral-valve repair. *Lancet*, 347: 659–661.
12. Jastrzębski C (1926) O zmienności kształtu zastawki trójdziałnej serca i o otworach wrodzonych w jej płatkach. *Kosmos, Seria A. Biologia*, 51: 191–198.
13. Khoury GE, d'Udekem Y, Noirhomme P, Verhelst R, Rubay J, Dion R (2000) Transfer of the posterior leaflet of the tricuspid valve to the mitral valve. *J Heart Valve Dis*, 9: 350–352.
14. Kilner PJ, Yang GZ, Wilkes AJ, Mohiaddin RH, Firmin DN, Yacoub MH (2000) Asymmetric redirection of flow through the heart. *Nature*, 6779: 759–761.
15. Kosiński A, Kuta W, Grzybiak M, Ciszkowicz M, Kamiński R (2000) Morfologia zastawki trójdziałnej w sercu człowieka dorosłego i innych naczelnych. *Przegląd Medyczny*, 2: 80.
16. Lamers WH, Virágh S, Wessels A, Moorman AFM, Anderson RH (1995) Formation of the tricuspid valve in the human heart. *Circulation* 91, 111–121.
17. Langberg JJ, Man KC, Vorperian VR, Williamson B., Kalbfleisch SJ, Strickberger SA, Hummel JD, Morady F (1993) Recognition and catheter ablation of sub-epicardial accessory pathways. *JACC* 22: 1100–1104.
18. Lomholt M, Nielsen SL, Hansen SB, Andersen NT, Hasenkam JM (2002) Differential tension between secondary and primary mitral chordae in an acute in vivo porcine model. *J Heart Valve Dis*, 11: 337–345.
19. Lu Y, James TN, Bootttsma M, Terasaki T (1993) Histological organization of the right and left atrioventricular valves of the chicken heart and their relationship to the atrioventricular Purkinje ring and the middle bundle branch. *Anat Rec*, 235: 74–86.
20. Łukaszewska-Otto H (1970) Zmienność budowy zastawki przedsionkowo-komorowej prawej u człowieka. Rozprawa habilitacyjna. Akademia Medyczna w Warszawie, Warsaw.
21. Miki K, Maekura R, Higara T, Hirotani A, Hashimoto H, Kitada S, Miki M, Yoshimura K, Naka N, Motone M, Fujikawa T, Takashima S, Kitazume R, Kanzaki H, Nakatani S, Watanuki H, Tagusari O, Kobayashi J, Ito M (2005) Infective tricuspid valve endocarditis with pulmonary emboli caused by *Campylobacter fetus* after tooth extraction. *Intern Med*, 10: 1055–1059.
22. Oppido G, Napoleone CP, Ragni L, Turci S, Loforte A, Angeli E, Gargiulo G (2006) Double orifice tricuspid valve in an infant with tetralogy of Fallot *Ann Thorac Surg*, 81: 1121–1123.
23. Radermecker MA, Somerville J, Li W, Anderson RH, de Leval MR (2001) Double orifice right atrioventricular valve in atrioventricular septal defect: morphology and extension of the concept of fusion of leaflets. *Ann Thorac Surg*, 7: 358–360.
24. Sharieff S, Sagir T, Shah-e-Zaman K (2005) Concurrent percutaneous valvuloplasty of mitral and tricuspid valve stenoses. *J Invasive Cardiol*, 17: 340–342.
25. Siebert FM, Lorenzo FJM, Rojas TM, Becerra PE, Martinez EF, Dans CA (1981) Tricuspid atresia with hypoplasia of aortic isthmus in absence of transposition of great vessels. *An Esp Pediatr*, 14: 117–121.
26. Skwarek M, Dudziak M, Hreczecha J, Grzybiak M (2006) The connection between the papillary muscles and leaflets of the tricuspid valve. *Folia Morphol*, 65: 322–328.
27. Skwarek M, Dudziak M, Hreczecha J, Grzybiak M (2006) The morphology of right atrioventricular valve in the human adult heart. *Folia Morphol*, 65: 105–113.
28. Skwarek M, Hreczecha J, Grzybiak M, Kosiński A (2005) Unusual anatomical features of the right atrioventricular valve. *Folia Morphol*, 64: 183–187.
29. Skwarek M, Hreczecha J, Grzybiak M, Kosiński A (2004) Remarks on the morphology of the papillary muscles of the right ventricle. *Folia Morphol*, 64: 176–182.
30. Sutton JP III, Yen Ho S, Vogel M, Anderson RH (1995) Is the morphologically right atrioventricular valve tricuspid? *J Heart Valve Dis* 4: 571–575.
31. Szostakiewicz-Sawicka H, Grzybiak M (1981) Zgodność rozwoju osobniczego niektórych cech budowy serca z przypuszczalnym kierunkiem ich rozwoju w antropogenezie. *Morfologia, podręczniki, skrypty AWF. Seria: Monografie*, 199: 9–16.
32. Szostakiewicz-Sawicka H (1967) Zastawka przedsionkowo-komorowa prawa u naczelnych. Rozprawa habilitacyjna. *Acta Biol Med Soc Sc Gedan*, 11: 545–589.
33. Victor S, Nayak VM (2000) Tricuspid valve is bicuspid. *Ann Thorac Surg*, 69: 1989–1990.
34. Wafae N, Hayashi H, Gerola LR, Vieira MC (1990) Anatomical study of the human tricuspid valve. *Surg Radiol Anat*, 12: 37–34.
35. Yamashita S, Noma K, Kuwata G, Miyoshi K, Honaga K (2005) Infective endocarditis at tricuspid valve following central venous catheterization. *J Anesth*, 19: 84–87.