

# The clinical anatomy of the cephalic vein in the deltopectoral triangle

M. Loukas<sup>1, 2</sup>, C.S. Myers<sup>1</sup>, Ch.T. Wartmann<sup>1</sup>, R.S. Tubbs<sup>3</sup>, T. Judge<sup>1</sup>,  
B. Curry<sup>1</sup>, R. Jordan<sup>1</sup>

<sup>1</sup>Department of Anatomical Sciences, St. George's University, School of Medicine, Grenada, West Indies

<sup>2</sup>Department of Education and Development, Harvard Medical School, Boston MA, USA

<sup>3</sup>Department of Cell Biology and Pediatric Neurosurgery, University of Alabama at Birmingham, AL, USA

[Received 19 June 2007; Revised 3 January 2008; Accepted 7 January 2008]

*Identification and recognition of the cephalic vein in the deltopectoral triangle is of critical importance when considering emergency catheterization procedures. The aim of our study was to conduct a cadaveric study to access data regarding the topography and the distribution patterns of the cephalic vein as it relates to the deltopectoral triangle. One hundred formalin fixed cadavers were examined. The cephalic vein was found in 95% (190 right and left) specimens, while in the remaining 5% (10) the cephalic vein was absent. In 80% (152) of cases the cephalic vein was found emerging superficially in the lateral portion of the deltopectoral triangle. In 30% (52) of these 152 cases the cephalic vein received one tributary within the deltopectoral triangle, while in 70% (100) of the specimens it received two. In the remaining 20% (38) of cases the cephalic vein was located deep to the deltopectoral fascia and fat and did not emerge through the deltopectoral triangle but was identified medially to the coracobrachialis and inferior to the medial border of the deltoid. In addition, in 4 (0.2%) of the specimens the cephalic vein, after crossing the deltopectoral triangle, ascended anterior and superior to the clavicle to drain into the subclavian vein. In these specimens a collateral branch was observed to communicate between the cephalic and external jugular veins. In 65.2% (124) of the cases the cephalic vein traveled with the deltoid branch of the thoracoacromial trunk. The length of the cephalic vein within the deltopectoral triangle ranged from 3.5 cm to 8.2 cm with a mean of  $4.8 \pm 0.7$  cm. The morphometric analysis revealed a mean cephalic vein diameter of  $0.8 \pm 0.1$  cm with a range of 0.1 cm to 1.2 cm. The cephalic vein is relatively large and constant, usually allowing for easy cannulation. (Folia Morphol 2008; 67: 72-77)*

**Key words:** cephalic vein, subclavian vein, axillary vein, deltopectoral triangle

## INTRODUCTION

Modern anatomy textbooks describe the superficial venous drainage of the upper extremity as being directed dorsally, beginning with the longitudinally oriented dorsal and palmar digital veins, which empty

into the dorsal metacarpal veins [18, 27]. These in turn coalesce to form a dorsal venous arch. It is the radial continuation of the latter that is termed the cephalic vein [7, 8]. At the wrist, the cephalic vein crosses superficial to the anatomical snuff box.

In the forearm the cephalic vein travels upward along the anterior border of the brachioradialis muscle. It anastomoses with the basilic vein by an obliquely crossing median cubital vein at the level of the elbow in 84% of cases [1, 2]. Leaving the antecubital fossa, it ascends in a groove along the lateral border of the biceps brachii until the proximal third of the arm, where it passes between the deltoid and pectoralis muscles (the deltopectoral triangle) [1]. At the lateral aspect of the deltopectoral groove, the cephalic vein is located superficially in a fat pad lying horizontally and separating the two muscles [5].

Although descriptions of the cephalic vein are typically brief and lacking in detail in anatomy text books [5, 18, 27], it is important clinically. Central venous access can be achieved by cannulating various veins [12]. Most commonly access is achieved at the bedside through the subclavian, femoral, brachiocephalic and cephalic veins [12]. Traditionally, central venous catheters in the upper limb and head and neck, are inserted "blindly" using various anatomic landmarks such as the clavicle, sternal notch, sternocleidomastoid and the carotid artery.

The cephalic vein is suitable for central venous access, pacemaker and defibrillator implantation [4, 19]. Furthermore, the cephalic vein cut-down method is associated with a lower incidence of complications than subclavian puncture with a success rate of approximately 80% [4, 22, 23]. Recently the cephalic vein has been used as a carotid patch as an alternative to the great saphenous vein [9].

Identification and recognition of the cephalic vein in the deltopectoral triangle is of critical importance when considering emergency procedures [1]. However, reports indicate that the cephalic vein is commonly not found within the deltopectoral groove or that surgeons have difficulty in identifying its location despite the use of ultrasound devices [4]. Therefore, the aim of our work was to conduct a cadaveric study to make data available regarding the topography and distribution patterns of the cephalic vein as it relates to the deltopectoral triangle.

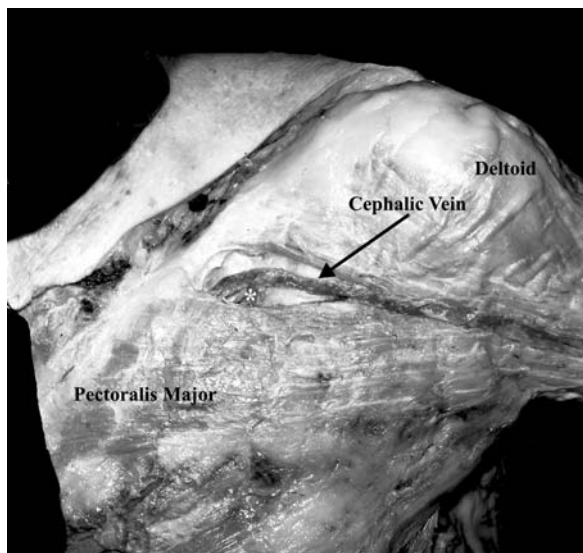
## MATERIAL AND METHODS

The anatomy of the cephalic vein was examined in 50 human cadavers during the gross anatomy course at Harvard Medical School (2005) and in 50 cadavers during the gross anatomy course at St George's University School of Medicine in Grenada (2005–2006). Of the specimens examined 44 were female and 56 were male with an age range of 65–83 years and a mean age of 70. The specimens were without any


grossly evident shoulder pathologies or surgical procedures affecting the cephalic vein or deltopectoral triangle. All the cadavers were routinely fixed in a formalin/phenol/alcohol solution. In order to correct for individual examiner variability, each specimen was examined by three co-authors independently, ML, CM and TJ. Each specimen was dissected as follows: a medial to lateral incision was made along the upper edge of the clavicle and around the most cranial part of the deltoid muscle; secondly, an incision was made around the pectoralis major muscle. The skin and superficial fascia were incised to reveal the deltopectoral triangle. In addition, the skin over the upper limb was removed in order to identify the origin and course of the cephalic vein.

Following preliminary examination, images from all the dissected specimens were recorded with a Nikon digital camera (model: Coolpix S5) and studied using a computer-assisted image analysis system [Lucia software 5.0 (2000, edition for Windows XP), made by Nikon (Laboratory Imaging Ltd.)]. The digital camera was connected to an image board (Nvidia GeForce 6800 GT) and linked to a computer. Digitized images of the cephalic vein, together with the surrounding structures, were stored in the Lucia program (2048 × 1536 pixels), and converted to intensity gray levels from 0 (darkest) to 32 bit (lightest). After a standard 1 mm scale had been applied to all pictures, the program was able to use this information to calculate pixel differences between two selected points, such as the origin and termination of a given vein, as previously described [15]. The purpose of the software was to allow easy and accurate translation of pixel differences into metric measurements.

Specifically, the distance of the cephalic vein within the deltopectoral triangle was measured. Additionally, at the midpoint of the cephalic vein in the deltopectoral triangle the vessel was transected, the lumen photographed and the diameter (diametrically opposite endothelial surfaces) measured. Furthermore, we measured the depth of the cephalic vein at the midpoint of the deltopectoral triangle. We define the depth as the longitudinal distance from the skin to the surface of the cephalic vein at the midpoint of the deltopectoral triangle. We also measured the surface area of the deltopectoral triangle and related it to the morphology and location of the cephalic vein. Two or three dissections were planned and performed without following the regular designs specifically for publication purposes (see also Figures for details).



**Figure 1.** A cephalic vein emerging superficially in the lateral portion of the deltopectoral triangle receiving in tributary within the deltopectoral triangle. The asterisk indicates the tributary joining the cephalic vein.

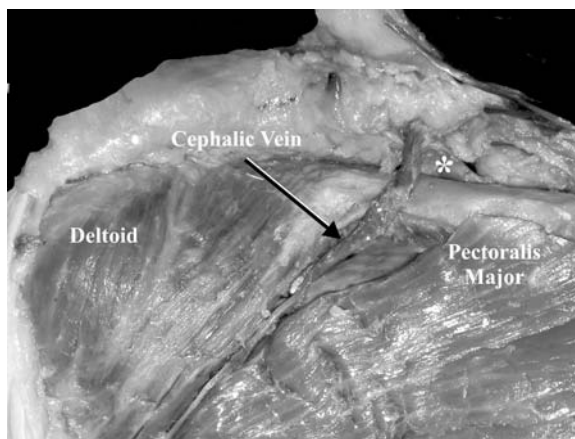


**Figure 2.** A cephalic vein receiving two tributaries within the deltopectoral triangle. The asterisks indicate the tributaries joining the cephalic vein.

## RESULTS

The cephalic vein was found in 95% (190 right and left) of the specimens, while in the remaining 5% (10) the cephalic vein was absent.

In 80% (152) of cases the cephalic vein was found emerging superficially in the lateral portion of the deltopectoral triangle. In 30% (52) of the 152 cases the cephalic vein received one tributary (Fig. 1) within the deltopectoral triangle, while in 70% (100) it received two (Fig. 2). With regard to the symmetry



**Figure 3.** An example of a specimen in which the cephalic vein, after crossing the deltopectoral triangle, ascends anterior and superior to the clavicle to drain into the subclavian vein. The asterisk indicates the junction of the cephalic vein with the subclavian.

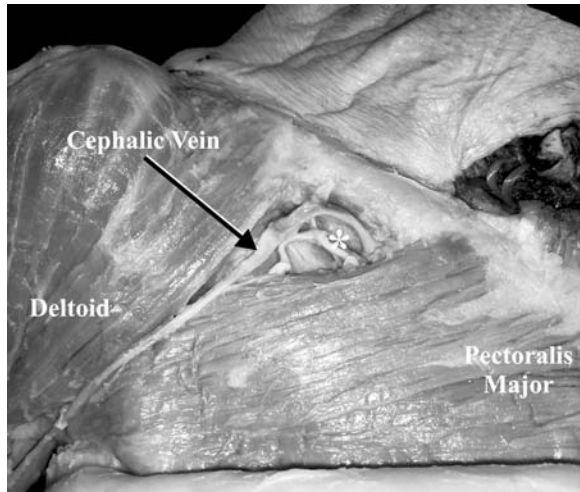
of the cephalic vein patterns, it was noted that 70% of the specimens appeared to be symmetrical.

In the remaining 20% (38) of cases, the cephalic vein was located deep to the deltopectoral fascia and fat and did not emerge through the deltopectoral triangle but was identified medially to the coracobrachialis and inferior to the medial border of the deltoid.

In addition, in 4 (0.2%) of the specimens the cephalic vein, after crossing the deltopectoral triangle, ascended anterior and superior to the clavicle to drain into the subclavian vein (Fig. 3). In these specimens a collateral branch was observed to communicate between the cephalic and external jugular veins. All the specimens observed were present unilaterally, with two right and two left specimens. In 65.2% (124) of the cases the cephalic vein traveled with the deltoid branch of the thoracoacromial trunk (Fig. 4).

An accessory cephalic vein was identified in 75% of cases. In 42% of cases the accessory cephalic vein arose as a small venous radicle in the distal part of the dorsal surface of the forearm. In 31% of cases the accessory cephalic vein arose from the ulnar end of the dorsal venous surface. In 15% of cases the accessory cephalic vein arose from the dorsal venous arch and in the remaining 12% of cases the accessory cephalic vein arose from the radial border of the forearm.

The depth from the surface of the skin to the cephalic vein was variable and ranged from 0.14 cm to 0.45 cm with a mean of  $0.32 \pm 0.11$  cm. The length of the cephalic vein within the deltopectoral triangle



**Figure 4.** An example of a specimen in which the cephalic vein travels with the deltoid branch of the thoracoacromial trunk. The asterisk indicate the tributaries joining the cephalic vein.

**Table 1.** The mean values with standard deviations and morphometric analysis of the cephalic vein (mean in cm)

Diameter of cephalic vein	$0.8 \pm 0.12$
Deltopectoral triangle to jugular notch	$15.2 \pm 4.31$
Deltopectoral groove	$12 \pm 3.22$
Cephalic vein to acromion	$10 \pm 1.64$
Cephalic vein to clavicle	$3 \pm 1.13$
Jugular notch to acromion	$21 \pm 2.34$

ranged from 3.5 cm to 8.2 cm with a mean of  $4.8 \pm 0.71$  cm. Morphometric analysis revealed a mean cephalic vein diameter of  $0.8 \pm 0.12$  cm with a range of 0.1 cm to 1.2 cm. The surface area of the deltopectoral triangle had a mean of  $7.34 \text{ cm}^2 \pm 2.21$  cm with a range of  $4.78 \text{ cm}^2$  to  $10.43 \text{ cm}^2$ . The distance between a midpoint between the deltopectoral triangle and the jugular notch had a mean of  $15.2 \pm 4.31$  cm with a range of 10.22 cm to 21 cm. The deltopectoral groove had a mean length of  $12 \pm 3.22$  cm with a range of 8.2 cm to 16.7 cm. The mean distances between the cephalic vein and the acromion process of the scapula and the clavicle were  $10 \pm 1.64$  cm (with a range of 7.2 cm to 13.5 cm) and  $3 \pm 1.13$  cm (with a range of 2.1 cm to 5.2 cm) respectively. The distance from the jugular notch to the acromion process had a mean of  $21 \pm 2.34$  cm with a range of 17.2 cm to 26 cm (Table 1). There was no significant difference in the length or diameter of the cephalic vein in relation to the race, gender,

age or institution of origin of the cadavers (Student's t-test;  $p > 0.05$ ).

## DISCUSSION

The cephalic vein, defined as the vein originating in the radial end of the dorsal venous arch, winds around the radial border of the forearm and passes proximally along the arm to the shoulder region [5]. According to Bergman et al. [2], the cephalic vein has been found to be of two types. In most cases at the level just distal to the bend of the elbow it gives rise to the median cubital vein, which continues in the bicipital sulcus and deltopectoral triangle to its termination into the axillary vein. In 16% of cases it receives the median cubital vein from the median antebrachial vein. The termination of the cephalic vein shows little variation. However, Bergman et al. [2] described the cephalic vein as potentially crossing the distal third of the arm to join the basilic vein. The other type of cephalic vein becomes continuous with the median cubital vein and thus terminates in the basilic vein. In the study of Reid and Taylor [24] one of their specimens showed bilateral absence of the cephalic vein. Le Saout et al. [13] reported the absence of the cephalic vein in four out of 74 cases.

Our morphometric analysis revealed a significantly greater diameter for the cephalic vein when compared to the study of Reid and Taylor [24] (a mean of 5.4 cm) and that of Le Saout et al. [13]. This disparity is probably a reflection of the different methods of detection and the varying criteria that each study used to measure the diameter of the cephalic vein as well as the anatomical diversity of the vessels being studied.

Interestingly, and as seen in our study, the cephalic vein may connect to the external jugular vein with a branch anterior to the clavicle, as reported by Standring [27] and Poirier and Charpy [21]. Le Saout et al. [13] were able to detect five cases in which the cephalic vein connected with a collateral branch of the external jugular.

Clinically, the cephalic vein is the most secure route for introducing permanent pacemaker/defibrillator leads and should be attempted first [3]. However, this vein is not always present and using it requires practice [3]. Despite its clinical relevance, the current literature contains only a small quantity of data describing the morphology and morphometry of the cephalic vein. In our study the cephalic vein was found bilaterally in most specimens and was most often seen along the lateral

portion of the deltopectoral triangle. This suggests that clinicians may consider identifying the cephalic vein along the lateral aspect of the deltopectoral groove. In addition, the deltopectoral groove is identified by a strip of fat in which the cephalic vein is embedded [1].

The cephalic vein is particularly well suited for IV drugs: its constant presence and large size make it easy to cannulate [29]. Limitations on the depth from the skin to the cephalic vein were variable and dependent on the general obesity of the cadaver.

Although in clinical practice, percutaneous venous punctures are approached via the subclavian vein, many studies analyzing the cephalic vein cut-down approach have shown an absence of immediate preoperative complications [17]. For this reason this should be considered a sounder approach for such procedures as implantable venous access devices [6]. In addition, subclavian and internal jugular vein percutaneous approaches carry a well-documented risk of serious complications. Of these, pneumothorax is the most important and frequent problem, with an incidence ranging from 1% to 4% [6]. Neri et al. [19] showed that the insertion of a permanent pacing lead through the cephalic vein with the help of a hydrophilic guidewire is highly successful, even when direct insertion or the use of a standard guidewire has failed. Use of this technique may enhance the overall success rate of lead insertion through the cephalic vein and may help to improve the acute and long-term results of permanent cardiac pacing [8].

According to Khan and Simms [9], using the cephalic vein for a carotid patch is superior to using the long saphenous vein, not only because it has the ideal size, wall thickness and handling characteristics, but also because it preserves the leg veins for future cardiovascular interventions. Moreover, compared to prosthetics, a cephalic vein patch is cheaper and less susceptible to bacterial colonization [9].

Autogenous saphenous veins have been the preferred conduit for infrainguinal arterial reconstruction since they were first used by Kunlin in 1949 [10]. However, according to the literature, suitable saphenous veins may be lacking in 25–50% of patients requiring lower extremity arterial reconstruction, when the veins are less than 4 mm in diameter [25]. This knowledge strengthens the arguments for surgeons using the cephalic vein as a suitable alternative, if not as the procedure of choice [17].

The cephalic cut-down should be considered the option of first choice because of the reduced rate of

acute complications, reduced incidence of conductor fractures, reduced insulation breaches and reduced cost of care [8].

Radiographically, venography has for some time been considered the standard of care in assessing the veins of the upper limb; however, its usage has been limited owing to its invasiveness [11]. Furthermore, the studies of Laissy et al. [11] and Turnel-Rodrigues et al. [28] reported that magnetic resonance venography of the upper arm veins above its lower third could not be achieved without a body coil. A major issue according to these studies is the small diameter of the cephalic vein. On the other hand, ultrasonographic guidance is becoming a popular technique for identifying the cephalic vein for the purpose of inserting different types of catheter [26, 30].

The surgeon's ability to recognize and identify the anatomical variations of the cephalic vein will reduce the occurrence of iatrogenic complications when surgery is performed in and around the deltopectoral triangle. A more complete knowledge of the relationships of the cephalic vein will allow surgeons to develop a safer, more complete surgical plan and help to prevent postoperative complications.

The significance of our findings is that, although the cephalic vein is almost always present in the general vicinity of the deltopectoral triangle, in 20% of the cadavers surveyed the cephalic vein was found to lie deep to the muscle and thus did not lend itself to venous catheterization.

In conclusion, the cephalic vein is large and constant, usually allowing for easy cannulation. Before puncture of the cephalic vein this vessel should be carefully palpated [14]. Since 1984 visualization of the targeted vein by ultrasound and real-time needle guidance has also been available [12]. Either of these techniques will prove to be useful for cephalic vein procedures.

### LIMITATIONS OF THE STUDY

According to Planken et al. [20], the diameter of the cephalic vein is highly variable between subjects and often from day to day in the same subject, depending on such variables as hydration or body position. We were unable in our study to observe such differences in our cadaveric material. We were also unable to measure the degree of subcutaneous fat accumulation in the cadavers in order to quantify its relationship with the depth of the cephalic vein in the deltopectoral triangle, as previously described [16].

## REFERENCES

1. Au FC (1989) The anatomy of the cephalic vein. *Am Surg*, 55: 638–639.
2. Bergman R, Thompson SA, Afifi AK (1988) *Compendium of Human Anatomic Variation*. Urban and Schwarzenberg, Inc. Baltimore, MD, pp. 90–91, 431.
3. Camous JP, Raybaud F, Lest I, Benoit PH (2005) Introduction of permanent cardiac stimulations/defibrillation leads via the retro-pectoral veins. *Pacing Clin Electrophysiol*, 28: 324–325.
4. Chen JY, Chang KC, Lin YC, Chou HT, Hung JS (2004) Feasibility and accuracy of pre-procedure imaging of the proximal cephalic vein by duplex ultrasonography in pacemaker and defibrillator implantation. *J Interv Card Electrophysiol*, 10: 31–35.
5. Clemente CD (1985) *Gray's anatomy*. 30<sup>th</sup> American ed. The Veins, Lea and Febiger, Philadelphia, pp. 820–821.
6. Di Carlo I, Barbagallo F, Toro A, Sofia M, Lombardo R, Cordio S (2005) External jugular vein cutdown approach, as a useful alternative, supports the choice of the cephalic totally implantable access device placement. *Ann Surg Oncol*, 12: 1–4.
7. Hallock G (1993) The cephalic vein in microsurgery. *Microsurgery*, 14: 482–485.
8. Hollinshead WH (1966) *Anatomy for surgeons*. Vol. 3. 2<sup>nd</sup> ed. Harper and Row, NY, pp. 344, 357, 397.
9. Khan RSA, Simms M (2005) Cephalic vein for carotid patching. *EJVES Extra*, 9: 35–36.
10. Kunlin J (1951) Le traitement de l'ischémique arteritique par la greffe veineuse longue. *Rev Chir (Paris)*, 70: 206–236.
11. Laissy JP, Fernandez P, Karila-Cohen P, Delmas V, Dupuy E, Chillon S, Mignon F, Schouman-Claeys E (2003) Upper limb vein anatomy before hemodialysis fistula creation: cross-sectional anatomy using MR venography. *Eur Radiol*, 13: 256–261.
12. LeDonne J (2005) Percutaneous cephalic vein cannulation (in the deltopectoral groove), with ultrasound guidance. *J Am Coll Surg*, 200: 810–811.
13. Le Saout J, Vallee B, Person H, Doutriaux M, Blanc J, Nguyen H (1983) Anatomical basis for the surgical use of the cephalic vein (V. Cephalica). 74 anatomical dissections. 189 surgical dissections. *J Chir (Paris)*, 120: 131–134.
14. Lirk P, Keller C, Colvin J, Colvin H, Rieder J, Maurer H, Moriggl B (2004) Unintentional arterial puncture during cephalic vein cannulation: case report and anatomical study. *Br J Anaesth*, 92: 740–742
15. Loukas M, Louis RG Jr, Hullet J, Loiacano M, Skidd P, Wagner T (2005) An anatomical classification of the variations of the inferior phrenic vein. *Surg Radiol Anat*, 27: 566–574.
16. Loukas M, Kapos T, Louis RG Jr, Jones A (2006) Gross anatomical, CT and MRI analyses of the buccal fat pad with special emphasis on volumetric variations. *Surg Radiol Anat*, 28: 254–260.
17. Mathes SJ, Nahai F (1997) *Reconstructive surgery, principles, anatomy and technique*. Vol. 1. Section 8F Radial Forearm, Churchill Livingstone, Philadelphia, pp. 775–802.
18. Moore KL, Dalley AF II (eds.) (2006) *Clinically oriented anatomy*. 5<sup>th</sup> ed. Lippincott Williams & Wilkins, Baltimore, pp. 748–749.
19. Neri R, Cesario AS, Baragli D, Monti F, Danisi N, Glaciale G, Gambelli G (2003) Permanent pacing lead insertion through the cephalic vein using an hydrophilic guidewire. *Pacing Clin Electrophysiol*, 26: 2313–2314.
20. Planken PN, Keuter XH, Hoeks AP, Kooman JP, van der Sander FM, Kessels AG, Leiner T, Tordoir JH (2006) Diameter measurement of the forearm cephalic vein prior to vascular access creation in end-stage renal disease patients: graduated pressure cuff versus tourniquet vessel dilatation. *Nephrol Dial Transplant*, 21: 802–806.
21. Poirier P, Charpy A (1909) *Traite d anatomie humaine*. Masson et Cie 2, Paris.
22. Povoski SP (2000) A prospective analysis of the cephalic vein cutdown approach for chronic indwelling central venous access in 100 consecutive cancer patients. *Ann Surg Oncol*, 7: 496–502.
23. Povoski SP (2002) Cephalic vein cutdown approach for long term indwelling central venous access. *Arch Surg*, 137: 746–747.
24. Reid CD, Taylor GI (1984) The vascular territory of the acromioclavicular axis. *Br J Plast Surg*, 37: 194–212.
25. Seeger JM, Schmidt JH, Flynn TC (1987) Preoperative saphenous and cephalic vein mapping as an adjunct to reconstructive arterial surgery. *Ann Surg*, 205: 733–739.
26. Sofocleous CT, Schur I, Cooper SG, Quintas JC, Brody L, Shelin R (1999) Sonographically guided placement of peripherally inserted central venous catheters: review of 355 procedures. *Am J Roentgenol*, 170: 1613–1616.
27. Standing S (2005) *Gray's anatomy*. 39<sup>th</sup> ed. Chapter 50. Upper Limb. Elsevier, Churchill, Livingstone, Edinburgh, pp. 885–857.
28. Turmel-Rodrigues L, Bourquelot P, Raynaud A, Beyssen B (2000) Hemodialysis fistula preoperative MR venography: a promising but partial view. *Radiology*, 214: 302–303.
29. Vialle R, Pietin-Vialle C, Cronier P, Brillu C, Villapaderna F, Mercier P (2001) Anatomic relations between the cephalic vein and the sensory branches of the radial nerve: How can nerve lesions during vein puncture be prevented? *Anesth Analg*, 93: 1058–1061.
30. Webre DR, Arens JF (1973) Use of cephalic and basilic veins for introduction of central venous catheters. *Anesthesiology*, 38: 389–392.