

Local differences in the position of the mental foramen

H. Yeşilyurt¹, A. Aydınlioğlu², A. Kavaklı³, N. Ekinci⁴, C. Eroğlu⁴, M. Hacıalioğulları⁴, S. Diyarbakırlı¹

¹Department of Anatomy, School of Medicine, Atatürk University, Erzurum, Turkey

²Department of Anatomy, Yüzüncü Yıl University, Van, Turkey

³Department of Anatomy, Fırat University, Elazığ, Turkey

⁴Department of Anatomy, Erciyes University, Kayseri, Turkey

[Received 19 April 2007; Revised 3 January 2008; Accepted 7 January 2008]

The mental foramen has been reported to vary in position in different ethnic groups. Repeated failures during injections and operative procedures involving the mental foramen suggest the presence of local differences in a given population. The aim of the present study was to investigate possible local differences of the mental foramen in Eastern Anatolian individuals in the Turkish population. The present investigation is based on the examination of 70 adult mandibles. The study consisted of three measurements, to include the relations of the mental foramen to the following: 1) the lower teeth; 2) the body of mandible; 3) the mandibular symphysis and posterior border of the ramus of the mandible.

The most common position of the foramen was in line with the longitudinal axis of the second premolar tooth (relation IV), at the midpoint of the mandibular body height and at 1/3.5 of the distance from the mandibular symphysis to the posterior border of the ramus.

Local differences of the mental foramen may occur in a population. Prior to surgery knowledge of the most common location of the foramen peculiar to a local population may enable effective mental block anaesthesia to be provided. (Folia Morphol 2008; 67: 32–35).

Key words: mandible, mental foramen, mental nerve, premolar

INTRODUCTION

According to textbooks of anatomy, the mental foramen (MF) is located below the interval between the premolar teeth, or the second premolar, from which emerge the mental nerve and vessels [14]. However, variations in the location of the foramen have been reported. It may occur between the apices of the lower premolars, below the apex of the second premolar and below the apex of the lower second premolar [3, 10, 12, 13, 15]. It is suggested that there are repeated failures to locate the mental foramen for injections and other operative procedures. On the other hand, data from various ethnic groups, for example Tanzanian [15], Thai [3], Chinese [13],

British [10], Indian [4], Kenyan African [7] and Saudi Arabian [2], vary concerning the location of the MF. A review by Green [5] demonstrated a clear racial trend in the position of the MF. All the variations above suggest the possibility of local differences in a population. A study including Central Anatolian individuals from Turkish population has already been reported [1]. In this article a new series of variations of the MF from Eastern Anatolian individuals in the Turkish population is presented and the possibility of local variation of the MF is investigated. Our literature review failed to find any study that addressed local variation in the foramen. The clinical significance of the MF is also briefly reviewed.

MATERIAL AND METHODS

This study was carried out over a three-year period in the Department of Anatomy, Atatürk, Yüzüncü Yıl, Fırat and Erciyes University, Turkey. It is based on examination of 70 adult mandibles, most of which were course materials for our medical students and were obtained from cadavers of Eastern Anatolian origin, while the others were from a collection available in our departments. The materials selected were of undetermined age and sex, as these were not recorded at the time of acquisition. The mandibles, without bone resorption and mostly from adult skulls, were of good dentition and pre-mortem tooth loss was very low. To make comparison with the findings of previous studies, the present study consisted of three measurements, the relations of the mental foramen to 1) the lower teeth, 2) the body of mandible, and 3) the mandibular symphysis and posterior border of the ramus [1, 10, 12, 13].

We also investigated differences between the right and left sides for the MF using the Mann-Whitney U-test statistical analysis.

Relation to the lower teeth

The position of the MF was measured in relation to the mandibular teeth. The position of the MF was recorded as lying in line with the long axis of a tooth or interdental space in one of five relations: I — anterior to the first premolar, II — the first premolar, III — between the premolars, IV — the second premolar, V — posterior to the second premolar, VI — the first molar (Fig. 1). The relation of the lower teeth was determined by visual examination.

Relation to the body of the mandible

To determine this relation, the standard horizontal plane defined by Marrant was used [10, 13]. Briefly, the mandible was placed on a horizontal surface, to which the lower border of the mandible comes into greatest contact when vertical pressure is applied to the second molar teeth. The following distances were determined by using calliper measurements [13]: the distance (cb) from the alveolar crest (c) to the lower border of the mandibular body crossing the MF (b); the distance (ib) between the inferior border of the foramen (i) and the lower border of the mandibular body (b) (Fig. 2).

Relation to the mandibular symphysis and the posterior border of the ramus

In order to relate the MF to a fixed point on the body of the mandible, the symphysis menti was taken

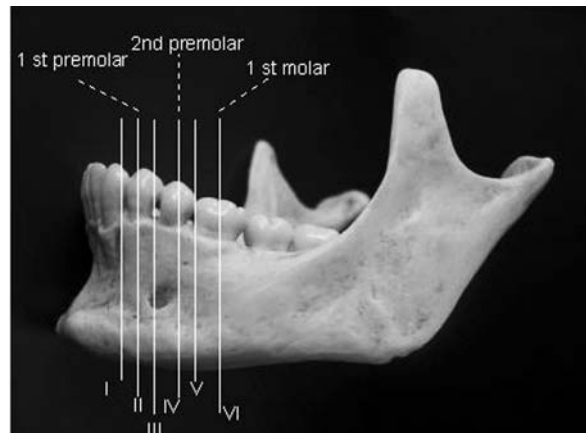


Figure 1. The relation of the mental foramen to the lower teeth as relations I–VI.

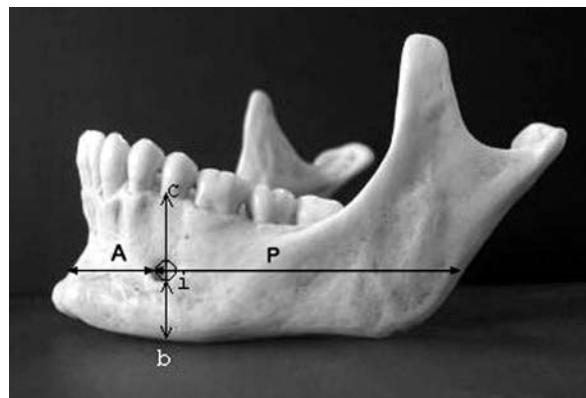


Figure 2. The relation of the mental foramen to the body of the mandible. Alveolar crest (c), distance between inferior border (ib) of the foramen (i) and the lower border of the mandible (b). The relation of the mental foramen to the symphysis menti and posterior border of the ramus. A and P — anterior and posterior chord distances.

as the convenient point of reference in the present investigation because of its early fusion. This relation was determined as a two-chord distance (anterior and posterior, A and P), as defined by Santini and Land [10] using calliper measurements. A plane parallel to Marrant's standard plane was selected by using the height of the most anterior tip of the MF. The midline of the symphysis was obtained by anatomical appreciation. The height from the standard plane to the foramen was indicated at the midline and at the point where this plane crossed the posterior border of the ramus. The distance between the most anterior tip of the MF and the midline anteriorly, chord A and the distance from the most anterior tip of the MF to the point on the posterior border of the ramus at the level of the selected line horizontally, chord P, were measured. The size of the mandible was assessed as the sum of these two chord distances (A + P) (Fig. 2).

Table 1. The relation of the mental foramen to the lower teeth, N = 70 (%)

	I	II	III	IV	V	VI
Right	0	4 (5.7%)	24 (34.3%)	39 (55.7%)	3 (4.3%)	0
Left	0	5 (7.1%)	18 (25.7%)	43 (61.4%)	4 (5.7%)	0

RESULTS

In our study, significant differences in the MF between the right and left sides were not shown statistically by Mann-Whitney U-test ($p > 0.05$).

Relation of mental foramen to the lower teeth

Relation I and relation VI were observed neither on the right nor the left side (0%). The other relations were found on the right and left respectively to be as follows: relation II, 5.7% and 7.1%; relation III, 34.3% and 25.7%; relation IV, 55.7% and 61.4%; relation V, 4.3% and 5.7% (Table 1).

Relation to the body of the mandible

The following mean values (mm) for this relation were found on the right and in left respectively: cb, 19.94 and 20.10; ib, 9.44 and 9.46 (Table 2). The ratio of cb/ib was approximately 2/1. In other words, the MF was found at the midpoint of the mandibular body height.

Relation to the mandibular symphysis and the posterior border of the ramus

The mean values of A + P in mm were found to be 67.76 on the right and 67.64 on the left (see Table 2, in detail). The ratio of A + P/A was found to be approximately 1/3.5 on both sides.

DISCUSSION

The present study is unique in that local variations were investigated in a population. Our study indicated the presence of local differences in the MF in the Turkish population.

Variations in the position of the mental foramen in relation to the lower teeth

In our study the most common position of the MF relative to the mandibular teeth was in line with the longitudinal axis of the second premolar tooth (relation IV). Textbooks and some published reports give the position as between the first and second premolar teeth [1, 5, 8, 10]. However, various investigations have reported the position as most commonly below the second premolar [6, 9, 11, 13]

Table 2. The relation of the mental foramen to the body of the mandible, and to the mandibular symphysis and posterior border of the ramus (n = 70)

Variable	Side	N	Mean	SD
cb	Right	70	19.94	11.94
	Left	70	20.10	12.09
ib	Right	70	9.44	5.837
	Left	70	9.46	5.877
A	Right	70	19.18	11.19
	Left	70	19.37	11.33
P	Right	70	48.58	29.03
	Left	70	48.27	28.86

For abbreviations see text and Figure 2

and posterior to the second premolar. The present investigation does not show a location in terms of relation I (anterior to the first premolar). A previous study were also not reported relation I and II [13].

On the other hand, previous studies have indicated that the MF shows racial and ethnic variations. The most common positions reported were 1) below the second premolar tooth (relation IV) in Chinese [5, 10, 13], Kenyan Africans [9] Nigerians [6] and Mongoloid populations [5], 2) posterior to the second premolar (relation V) in Caucasoid [5] and Zimbabwean [7] populations, and 3) between the premolars (relation III) in Negroid [5], British [10], Central Anatolian [1] and North American white populations [8]. Close ratios for the relation III and IV positions were found in the Saudi population [2]. Adult black Zimbabwean mandibles also showed right/left differences related to the most common positions, relation IV on the right side and relation V on the left.

Variations of the mental foramen in relation to the body of the mandible

Our results for cb and ib (Table 1) were smaller than those reported in the literature concerning adult mandibles for Chinese and Central Anatolian

populations [1, 13]. Our findings in relation to the body of the mandible also showed local variations in the Turkish population. The smaller values from the present study might be due to the habit of chewing among Eastern Anatolian individuals.

Variations of the mental foramen in relation to the mandibular symphysis and the posterior border of the ramus

The values for A, P and A + P/A were found to be smaller than those of Chinese, British, Central Anatolian and Zimbabwean populations [1, 7, 10, 13]. Our findings for this relation indicated a local differentiation in the present population as well. The ratio A + P/A indicates that the MF lies at 1/3.5 of the distance from the mandibular symphysis to the posterior border of the ramus. This ratio from the other studies was reported as 1/4 [7, 12, 13]. The position of the MF in relation to the anterior/posterior was reported symmetrically in the studies mentioned above and also in the present investigation. Among Nigerians, however, asymmetrical location of the foramen was reported more frequently in females. A right MF was more frequently located posteriorly than the left [6]. According to Green [5], the relative position of the foramen may be influenced by factors such as age, mesiodistal tooth size and attrition of the proximal surface. In the present investigation we chose adult mandibles in order to prevent mesial drifting influencing the results, and compared the adult group from the study with the Central Anatolian group [1].

Clinical significance

The variability of the position of the foramen should always be considered when diagnosing radiographic periapical areas and when performing periodontal or endodontic surgery in the area from the canine to the mesial root of the first molar [10]. The ratio A + P/A might be a more reliable and provides an additional or alternative method to the relative location to the lower teeth. This method may prevent the occurrence of damage to the mental nerve. In performing mental block anaesthesia, on the other hand, knowledge of the ratio of cb/ib is of clinical importance in order to insert the needle into the most common location of emergence of the mental nerve. In this area, therefore, the dentist can begin accurate surgery, such as treatment of a laceration wound or a flap operation [13].

CONCLUSIONS

The present investigation suggests that local differences in mental foramen position may occur in a population. These may be related to the feeding habits of different regions and may subsequently affect mandible development. Pre-operative radiographs and additional radiographs from different angles if necessary should be taken to locate the mental foramen prior to surgery. Knowledge of the most common location of the mental foramen peculiar to a local population may also enable effective mental block anaesthesia to be provided.

REFERENCES

1. Aktekin M, Celik HM, Celik HH, Aldur MM, Aksit MD (2003) Studies on the location of the mental foramen in Turkish mandibles. *Morphologie*, 87: 17–19.
2. Al Jasser NM, Nwoku AL (1998) Radiographic study of the mental foramen in a selected Saudi population. *Dentomaxillofac Radiol*, 27: 341–343.
3. Boonpiruk N (1975) Location of mental foramen in Thai skulls. *J Dent Assoc Thai*, 25: 295–302.
4. Gershenson A, Nathan H, Luchansky E (1986) Mental foramen and mental nerve: changes with age. *Acta Anat*, 126: 21–28.
5. Green RM (1987) The position of the mental foramen: a comparison between the southern (Hong Kong) Chinese and other ethnic and racial groups. *Oral Surg Oral Med Oral Pathol*, 63: 287–290.
6. Kekere-Ekun TA (1989) Antero-posterior location of the mental foramen in Nigerians. *Afr Dent J*, 3: 2–8.
7. Mbajiorgu EF, Mawera G, Asala SA, Zivanovic S (1998) Position of the mental foramen in adult black Zimbabwean mandibles: a clinical anatomical study. *Cent Afr J Med*, 44: 24–30.
8. Moiseiwitsch JR (1998) Position of the mental foramen in a North American, white population. *Oral Surg Oral Med Oral Pathol Oral Radiol Endod*, 85: 457–460.
9. Mwaniki DL, Hassanali J (1992) The position of mandibular and mental foramina in Kenyan African mandibles. *East Afr Med J*, 69: 210–213.
10. Santini A, Land MA (1990) A comparison of the position of the mental foramen in Chinese and British mandibles. *Acta Anat*, 137: 208–212.
11. Shankland WE (1994) The position of the mental foramen in Asian Indians. *J Oral Implantol*, 20: 118–123.
12. Tebo HG, Telford IB (1950) An analysis of the variations in position of the mental foramen. *Anat Rec*, 107: 61–66.
13. Wang TM, Shih C, Liu JC, Kuo KJ (1986) A clinical and anatomical study of the location of the mental foramen in adult Chinese mandibles. *Acta Anat*, 126: 29–33.
14. Williams PL, Warwick R, Dyson M, Bannister LH (1989) *Grays anatomy*. 37th ed. Churchill Livingstone, London, UK, pp. 367.
15. Zivanovic S (1970) Some morphological characteristics of the East African mandible. *Acta Anat*, 77: 109–119.