

# Gross anatomy of the intestine and its mesentery in the nutria (*Myocastor coypus*)

W. Pérez<sup>1</sup>, M. Lima<sup>1</sup>, A. Bielli<sup>2</sup>

<sup>1</sup>Área de Anatomía, Facultad de Veterinaria, A. Lasplaces 1620, 11600 Montevideo, Uruguay

<sup>2</sup>Área de Histología y Embriología, A. Lasplaces 1620, 11600 Montevideo, Uruguay

[Received 1 July 2008; Accepted 11 October 2008]

*The intestines and mesentery of the nutria (Myocastor coypus) have not been fully described. In the present study 30 adult nutrias were studied using gross dissection. The small intestine was divided into the duodenum, jejunum and ileum as usual. The duodenum started at the pylorus with a cranial portion, which dilated forming a duodenal ampulla. The ileum was located within the concavity of the caecum and attached to the coiled caecum by means of the iliocaecal fold. The ascending colon had two ansae, one proximal and one distal. The proximal ansa was fixed to the caecum by the caecocolic fold. The base of the caecum and a short proximal part of the ascending colon belonging to the proximal ansa were attached to the mesoduodenum descendens. The distal ansa of the ascending colon had a proximal part which was sacculated and a distal part which was smooth. The two parts of the distal ansa of the ascending colon were parallel and joined by a flexure of variable localisation. The smooth part of the distal ansa of the ascending colon was attached to the initial portion of the descending colon by a peritoneal fold. The short transverse colon was directly attached to the mesoduodenum and greater omentum. In conclusion, we have described the anatomy of the intestines of the nutria and its mesentery in detail, and provided a nomenclature list adapted to the Nomina Anatomica Veterinaria. (Folia Morphol 2008; 67: 286–291)*

**Key words:** animal anatomy, Rodentia, digestive system, peritoneal folds

## INTRODUCTION

The digestive anatomy has been studied in only a few species of the order Rodentia. The species of this order differ in their intestinal anatomy [3, 4, 9, 12, 14–20], and the caecum in particular shows large differences [12].

The intestinal anatomy [13, 19, 22] and digestive physiology [5, 8, 21] of the nutria has been studied previously, showing that morphologically the large intestine resembles that of other caviomorphs, notably the guinea pig [19]. Wagner [22]

divided the large intestine of the nutria only into caecum, large colon and small colon. Snipes et al. [19] did not use the Nomina Anatomica Veterinaria (NAV) [6] terms, because the main topics of their study were the histology and physiology of the large intestine. On the basis of their results they differentiated a proximal and a distal colon. Bonfert [3] already used the terms of the NAV (colon ascendens, transversum and descendens) not only for the nutria but also for many other rodent species. With respect to arterial irrigation, just one

Address for correspondence: W. Pérez, Área de Anatomía, Facultad de Veterinaria, A. Lasplaces 1620, 11600 Montevideo, Uruguay, tel: ++59 82 623 41 63, fax: ++59 82 628 01 30, e-mail: vetanat@gmail.com

publication exists to our knowledge [7], describing the distribution of the mesenteric arteries and their branches. In this publication the authors refer to the caecum, colon ascendens (with a long ansa formed by two segments linked at a flexure), colon transversum and colon descendens. There is thus no consensus on the anatomical nomenclature for this species.

The description of the mesentery of the nutria requires concise definitions, particularly with respect to the divisions of the intestine. We have found two other studies that mention parts of the mesentery of the nutria. Bonfert [3] mentioned the ileocaecal fold and Wagner [22] described the mesentery of the nutria as “a wide fan-shaped fold of peritoneum originating from the outer curvature of the duodenum and supporting the greater portion of the large colon”. Hullar et al. [5] concluded that the digestive anatomy and physiology of the nutria and the rabbit are similar. Pérez et al. [10] have described the peritoneal folds of the rabbit, and a NAV-adapted nomenclature has been suggested for the different parts of the intestine, with the ascending colon being the most complex portion [11]. It is therefore the objective of this work is to give a complete and detailed description of the anatomy of the intestine of the nutria, including its mesentery, with a defined nomenclature, in order to improve existing knowledge of this species.

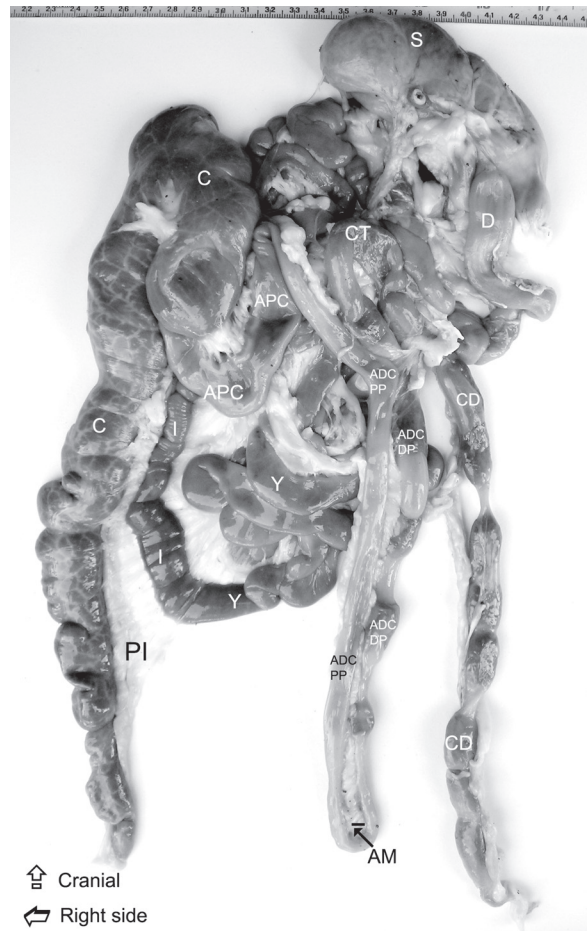## MATERIAL AND METHODS

The study was performed using 30 healthy two-year-old adult nutrias (25 females and 5 males) of a mean body weight of 5.5 kg. All the animals were bought from a breeding farm licensed by the Ministry of Livestock and Agriculture. They were euthanised with an overdose of sodium thiopental administered intravenously. Twenty five animals were promptly dissected without fixation and the other five were previously fixed by arterial perfusion with 10% formalin. Terms were used in agreement with the NAV [6]. After the intestines had been dissected and analysed, a list of NAV-adapted terms was compiled with reference to these organs.

## RESULTS

### Divisions of the intestine

The small intestine was divided into the duodenum, jejunum and ileum (Fig. 1). The duodenum started at the pylorus with a cranial, dilated portion

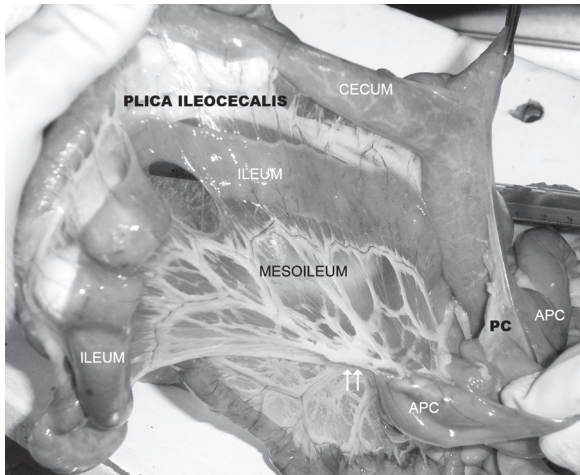


**Figure 1.** Ventral view of the isolated intestine of the nutria; S — stomach; D — duodenum, Y — jejunum, C — caecum, I — ileum, APC — ansa proximalis coli, ADC, PP — ansa distalis coli, proximal part; ADC, DP — ansa distalis coli, distal part, CT — colon transversum, CD — colon descendens, PI — plica ileocaecalis, AM — mesocolon ascendens of the distal ansa.

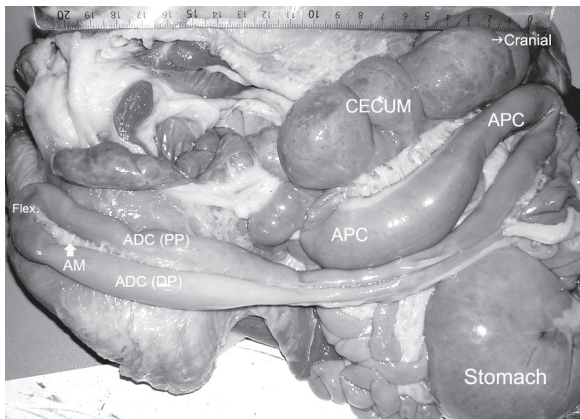
directed to the right and forming a duodenal ampulla. The following portions of the duodenum were the cranial flexure and the descending duodenum, which ended at the caudal flexure. From the caudal flexure the duodenum ran cranially as the ascending portion.

The jejunum extended up to the beginning of the ileocaecal fold. The ileum (Fig. 2) was located within the concavity of the caecum.

The abdominal part of the large intestine was divided into the ascending colon, transverse colon and descending colon. The caecum and the ascending colon were the most voluminous sections of the intestine of the nutria. The caecum (Fig. 1, 3) had a coiled proximal part composed of the base and the body and an elongated distal part that ended



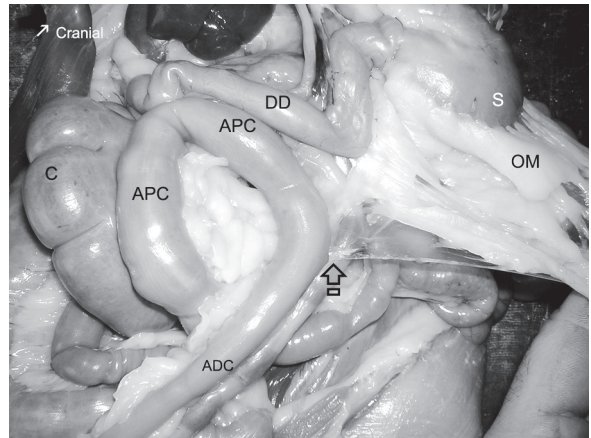
**Figure 2.** Left ventral view of the caecum, ileum, ansa proximalis coli and their mesentery; white arrows — initial point of attachment of the mesocolon ascendens to the mesoileum, APC — ansa proximalis coli, PC — plica caecocolica.



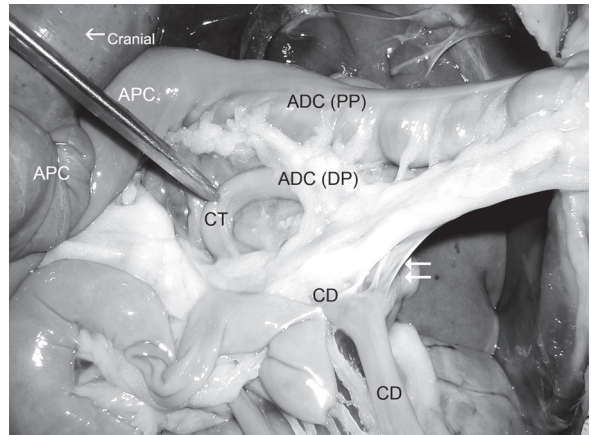
**Figure 3.** Left ventral view of the caecum and ascending colon; APC — ansa proximalis coli, ADC — ansa distalis coli: PP — proximal part, DP — distal part, Flex. — apical flexure of the distal ansa; AM — mesocolon ascendens of the distal ansa.

at the apex. The caecum also had two taeniae and approximately 30 haustra that increased in size towards the base.

The ascending colon had two ansae, a proximal and a distal one (Fig. 1, 3, 4). The proximal ansa (Fig. 3, 4, APC) was located in the right half of the abdomen and was more voluminous than the distal ansa. The distal ansa (Fig. 3, ADC) was composed of two parallel parts merged in an apical flexure (Fig. 3, Flex.) of variable topographic localisation and folded back over each other. The proximal part had haustra pouches (Fig. 5, ADC, PP) and the distal part was smooth (Fig. 3, ADC, DP).



**Figure 4.** Left caudoventral view of the stomach, greater omentum and intestine; S — stomach, DD — descending duodenum, C — caecum, OM — omentum majus, APC — ansa proximalis coli, ADC — ansa distalis coli, arrow — greater omentum united with the ascending mesocolon of the ansa distalis coli.



**Figure 5.** Ventral view of the three parts of the colon. Cranial side is at the left of the picture; APC — ansa proximalis coli, ADC — ansa distalis coli: PP — proximal part, DP — distal part, CT — colon transversum, CD — colon descendens, white arrows — peritoneal fold between distal part of the ansa distalis coli and the colon descendens.

The haustra were evident at the proximal part of the distal ansa at its free border, while the mesocolic border was smooth. The apical flexure (Fig. 3, Flex.) connecting both parts of the distal ansa of the ascending colon could be found either cranially in the sternal region or caudally near the cranial pelvic aperture, either at the right or at the left side of the abdomen.

The distal ansa was followed at the level of the right colic flexure by the short transverse colon (Fig. 5, CT), which turned left around the cranial mesenteric



artery. The transverse colon was irrigated by the middle colic artery, which was a branch of the cranial mesenteric artery. Finally, the transverse colon was continued at the left flexure of the colon by the descending colon (Fig. 5, CD).

The descending colon ran straight at the level of the roof of the abdomen, from the left flexure of the colon until it fused with the rectum at the left side of the ascending duodenum.

In accordance with what we observed and the criteria of the NAV, we made the following list of items for the nomenclature of the intestine of the nutria:

#### INTESTINUM TENUE

##### Duodenum

- pars cranialis;
  - ampulla cranialis;
- flexura duodeni cranialis;
- pars descendens;
- flexura duodeni caudalis;
- pars ascendens;

##### Jejunum

##### Ileum

#### INTESTINUM CRASSUM

##### Cecum [Caecum]

- basis ceci [caeci]
- corpus ceci [caeci]
- apex ceci [caeci]
- curvatura ceci [caeci] major
- curvatura ceci [caeci] minor
- taenia ceci [taeniae caeci]
- haustra ceci [caeci]

##### Colon

- colon ascendens
  - ansa proximalis coli
  - ansa distalis coli
    - pars proximalis
    - flexura
    - pars distalis

Flexura coli dextra

Colon transversum

Flexura coli sinistra

Colon descendens

##### Rectum

#### Mesentery and peritoneal folds of the intestine

The duodenum was sustained by the mesoduodenum, with the pancreas being included in the mesoduodenum and in the deep wall of the greater omentum. The base of the caecum and the mesocolon of the proximal ansa of the ascending colon adhered to the mesoduodenum. The right

border of the greater omentum (Fig. 4, OM) was also attached to the mesoduodenum. The ascending duodenum was attached to the descending mesocolon by the duodenocolic fold, which had an average length of 4.1 cm at its free border.

The jejunum was sustained by the mesojejunum, which contained the jejunal vessels between its sheets. In 15 of the 30 nutrias investigated, the terminal portion of the jejunum was folded back over the initial portion of the ileum, with both parts joined by a peritoneal fold, formed from both the mesentery and the ileocaecal fold. Thus there was a 4.0 cm deep peritoneal recess between the terminal portion of the jejunum and the initial portion of the ileum.

The ileum was attached to the concave border of the caecum by the ileocaecal fold (Fig. 1, 2). The length of the free border of the ileocaecal fold measured on average 11.7 cm and had a maximum width of 2.0 cm at its central part.

The base of the caecum adhered to the mesoduodenum, its caecocolic fold attached to the proximal ansa of the ascending colon, and its ileocaecal fold attached to the ileum, the latter providing an indirect connection to the mesentery (mesoileum). The caecocolic fold measured 2.5 cm in length at its free border (Fig. 2, PC). This gave access to a peritoneal recess that opened caudally and was 2.5 cm deep.

In all the animals examined the ascending mesocolon was short. The mesocolon of the proximal ansa of the ascending colon and the mesoduodenum joined cranially. The ascending colon was therefore situated near the descending duodenum (Fig. 4, APC and DD). The ascending mesocolon of the proximal ansa was attached in its caudal part to the mesentery (mesoileum). Consequently, the ansa proximalis was fixed to the mesentery (Fig. 2, white arrows), giving an indirect connection to the caecum and to the rest of the ascending colon.

The ascending mesocolon, which linked both parts of the distal ansa, was extremely narrow, especially at the opposite end of the flexure that joined both parts (Fig. 1, 3, AM). The ascending mesocolon of the distal ansa adhered cranially to the greater omentum (Fig. 4, black arrow). The smooth distal part of the distal ansa of the ascending colon (Fig. 1, 5, ADC, DP) attached to the initial portion of the descending colon distal to the transverse colon by means of a peritoneal fold, which was 2.3 cm long at its free border (Fig. 1, 4).

The greater omentum was attached to the transverse colon, which was attached to the mesoduodenum. The transverse mesocolon was short. The descending colon was held by a wide mesentery and by the duodenocolic fold.

## DISCUSSION

This work is a further contribution to the anatomy of the nutria. We described the anatomy of the intestines and the mesentery of the nutria in detail and provided a list of items for the nomenclature of the intestine adapted to the NAV.

Comparing the rabbit and the nutria, we found that the duodenal ampulla [2] is much more evident in the nutria. In contrast, the ileal ampulla or sacculus rotundus, the last portion of the ileum that is markedly extended in the rabbit [2], is not present in the nutria.

In the rabbit, the ileum, caecum and part of the ascending colon are coiled together, forming a spiral with one and a half loops [2]. However, in the nutria, only part of the caecum and ileum were coiled, completing three quarters of a turn; the ascending colon was separated from these two viscera, except by the attachment given by the short caecocolic fold.

The caecum of rodents has been divided into the ampulla caeci (basis caeci), corpus caeci and apex caeci [12, 14–20]. In the nutria we recognised the same parts. The fact that the caecum was voluminous, with well-developed taeniae and haustra, is in agreement with the general trend in rodents [4, 12].

The colon, in particular the ascending colon, has received less attention in studies on rodents. Wagner [22] named the ascending colon the great colon and the descending colon the small colon. Snipes et al. [19] suggested that the use of the terms “ascending”, “transverse” and “descending” colon should be avoided. We found that the parts of the intestine were well differentiated topographically. This is in accordance with the terms established by the NAV [6], and correlates with the distribution of the branches of the cranial mesenteric artery [7]. Thus we decided to divide the colon of the nutria into the ascending, transverse and descending colon, in agreement with the terms used by Machado et al. [7].

Snipes et al. [20] subdivided the colon into two sections, the proximal and the distal colon, the border between the two being the apical flexure of a long parallel loop. According to Snipes et al. [19], the proximal colon of the nutria included the proximal ansa of the ascending colon and half of the dis-

tal ansa, and the colon started as a funnel shaped extension from the caecum which was named the proximal ansa of the ascending colon.

According to Wagner [22] the first 28–30 cm of the large colon was sacculated because of two longitudinal bands or taeniae coli. These taeniae were observed neither by us nor by Snipes et al. [19]. The distal ansa described by us is what Snipes termed the “parallel loop”. Machado et al. [7] also mentioned the distal ansa as the only ansa of the colon. The distal colon of Snipes et al. [19] included the non-sacculated distal half of the distal ansa of the ascending colon, the transverse colon and the descending colon.

The fact that the mesocolon of the proximal ansa of the ascending colon was united cranially to the left sheet of the mesoduodenum has previously been mentioned before [22] as follows: “the greater portion of the large colon is supported by a mesentery which originates from the outer curvature of the duodenum”.

According to Machado et al. [7], the transverse colon of the nutria was cranial to the root of the mesentery, and irrigated by the middle colic artery. Wagner [22] and Snipes et al. [19] did not mention the transverse colon in their study about the nutria, and nor did Alogninouwa et al. [1] mention it in the grasscutter. In the present study, the descending colon corresponds to what Wagner [22] called the small colon. However, Wagner [22] described its mesentery as simple, and did not mention a duodenocolic fold.

## ACKNOWLEDGEMENTS

The authors acknowledge the assistance of Dr. Daniel Olazábal and Prof. Nathalia Ruffato, and thank Marcus Clauss (University of Zurich, Switzerland) for comments on the manuscript.

## REFERENCES

1. Alogninouwa T, Agba KC, Agossou E, Kpodekon M (1996) Anatomical, histological and functional specificities of the digestive tract in the male grasscutter (*Thryonomys swinderianus*, Temminck 1827). *Anat Histol Embryol*, 25: 15–21.
2. Barone R (1997) Anatomie comparée des mammifères domestiques. Splanchnologie I. Appareil digestif, appareil respiratoire. Vol. 3. 3<sup>rd</sup> Ed. Vigot Frères, Paris.
3. Bonfert A (1928) Vergleichende Untersuchungen über die Homologie der Darmteile bei Nagetieren unter teilweiser Berücksichtigung der arteriellen Blutversorgung. *Anat Anz*, 65: 369–398.
4. Kotze SH, van der Merwe EL, O’Riain MJ (2006) The topography and gross anatomy of the gastrointestinal tract of the cape dune mole-rat (*Bathergus suillus*). *Anat Histol Embryol*, 35: 259–264.

5. Hullar I, Fekete S, Gippert T (1992) How do coypu and rabbit digest the same feedstuffs? *Scientifur* 16: 298–302.
6. International Committee on Veterinary Gross Anatomical Nomenclature (ICVGAN) (2005) *Nomina Anatomica Veterinaria (NAV)*. 5<sup>th</sup> Ed. ([http://www.wavamav.org/Downloads/nav\\_2005.pdf](http://www.wavamav.org/Downloads/nav_2005.pdf)).
7. Machado GV, Gonçalves PR, Parizzi A, de Souza JR (2006) Padrão de divisão e distribuição das artérias mesentéricas no rato-do-banhado (*Myocastor coypus* — Rodentia: Mammalia). *Biotemas*, 19: 59–63.
8. Marounek M, Skrivan M, Brezina P, Hoza I (2005) Digestive organs, caecal metabolites and fermentation pattern in coypus (*Myocastor coypus*) and rabbits (*Oryctolagus cuniculus*). *Acta Vet Brno*, 74: 3–7.
9. Nieters M, Schnorr B, Kressin M (2003) Der Rumpfdarm des Burunduk (*Eutamias sibiricus*, Laxm. 1769). Makroskopische und lichtmikroskopische Untersuchungen. *Anat Histol Embryol*, 32: 161–168.
10. Pérez W, Möller R, Martin E (2005) Peritoneal Folds of the Rabbit (*Oryctolagus cuniculus*). *Anat Histol Embryol*, 34: 167–170.
11. Pérez W, Möller R, Martin E (2007) Suggested nomenclature for the cecum and ascending colon of the Rabbit. *Anat Histol Embryol*, 36: 389–395.
12. Perrin MR, Curtis BA (1980) Comparative morphology of the digestive system of 19 species of Southern African myomorph rodents in relation to diet and evolution. *S Afr J Zool*, 15: 22–33.
13. Shen Ping, Wen Xing Hao, Dong Shu Zen, Li Zi Yi, Chen Tai Long (1999) Microscopic structure and submicroscopic structure of digestive tract in the *Myocastor coypus*. *Chi J Vet Sci*, 19, 508–510.
14. Snipes RL (1979) Anatomy of the cecum of the vole, *Microtus agrestis*. *Anat Embryol*, 157, 181–203.
15. Snipes RL (1979) Anatomy of the cecum of the dwarf hamster (*Phodopus sungorus*). *Anat Embryol*, 157: 329–346.
16. Snipes RL (1981) Anatomy of the cecum of the laboratory mouse and rat. *Anat Embryol*, 162: 455–474.
17. Snipes RL (1982) Anatomy of the guinea-pig cecum. *Anat Embryol*, 165: 97–111.
18. Snipes RL (1982) Anatomy of the cecum of the gerbil *Meriones unguiculatus* (Mammalia, Rodentia, Cricetidae). *Zoomorphology*, 100: 189–202.
19. Snipes RL, Hörnicke H, Björnhag G, Stahl W (1988) Regional differences in hindgut structure and function in the nutria, *Myocastor coypus*. *Cell Tiss Res*, 252: 435–447.
20. Snipes RL, Nevo E, Sust H (1990) Anatomy of the caecum of the Israeli mole rat, *Spalax ehrenbergi* (Mammalia). *Zool Anz*, 224: 307–320.
21. Takahashi T, Sakaguchi E (2000) Role of the furrow of the proximal colon in the production of soft and hard feces in nutrias, *Myocastor coypus*. *J Comp Physiol*, 170: 531–535.
22. Wagner JA (1963) Gross and microscopic anatomy of the digestive system of the nutria, *Myocastor coypus bonariensis* (Geoffroy). *J Morphol*, 112: 319–333.