

# Morphometry of the pterional and pterional-orbitozygomatic approaches to the basilar artery bifurcation by the use of neuronavigation systems: a new technical concept

J. Dzierżanowski, P. Słoniewski, M. Rut

Department of Neurosurgery, Medical University of Gdańsk, Poland

[Received 2 June 2008; Accepted 23 August 2008]

*Much attention has been paid in the neurosurgical literature to optimising the approaches to intracranial pathology. The aims of the innovations reported are to increase the safety of operations by reduction of brain retraction and to improve exposure of the neurovascular structure in the operating area. It was our intention to investigate whether an image-guided frameless stereotactic system is suitable in morphometric studies based on the analysis of the pterional and the cranio-orbitozygomatic approaches to the basilar artery bifurcation (BAB).*

*We analysed 60 virtual models of pterional craniotomy and the same number of those extended by orbitozygomatic osteotomy, created using computer tomography in the neuronavigation system. It was decided to calculate the percentage change of the cranial area of exposure, the depth of the surgical corridor and the angle of view to the bifurcation of the basilar artery. Three positions of the BAB (normal, high and low) were examined for each model of craniotomy.*

*In the material analysed, after the extension of the pterional craniotomy by orbitozygomatic osteotomy, the cranial area of exposure for 60 models of cranio-orbitozygomatic craniotomies increased by a mean of 39.28% (from 30.89% to 48.06%). The decrease in the depth of the surgical corridor for a normal-lying BAB was 19.16%, for a high-lying BAB 19.09% and for a low-lying BAB 19.12%. The mean changes in the individual BAB locations did not differ significantly in statistical terms ( $F = 0.011$ ;  $p = 0.99$ ). The mean increase in the cranial angle of attack for a normally located BAB was  $10.72^\circ$ , for a high-lying BAB  $11.1^\circ$  and for a low-lying BAB  $10.31^\circ$ . The post-hoc test showed significant differences in the angle of attack between a normal and a low-lying BAB ( $p = 0.034$ ) and a high and a low-lying BAB ( $p = 0.00007$ ).*

*Neuronavigation systems, already well-known for their intraoperative use, can also be useful in morphometric studies, and the advantages of this method are the practically unlimited number of results which can be analysed in detail and the repeatability of the technique. The pterional-orbitozygomatic approach compared to the pterional increases the working area, minimises retraction of the brain, shortens the working distance, enables instruments to be used more easily, widens the angle of view and improves the visibility of the anatomical structures in the working area, especially for a high-lying BAB. (Folia Morphol 2008; 67: 267–272)*

**Key words:** morphometry, neuronavigation system, basilar bifurcation aneurysms, pterional approach, orbitozygomatic approach

## INTRODUCTION

Much attention has been paid in the neurosurgical literature to optimising surgical approaches [12, 13, 15, 16, 18, 21, 24]. Changes in such parameters as the working area and the angle of view into anatomical structures after extension by orbitozygomatic osteotomy are aspects of this that are analysed most frequently. The published measurements for the neurosurgical approaches are based on the assumption that quantification will be useful for the surgeon in deciding which approach is the best for any particular case.

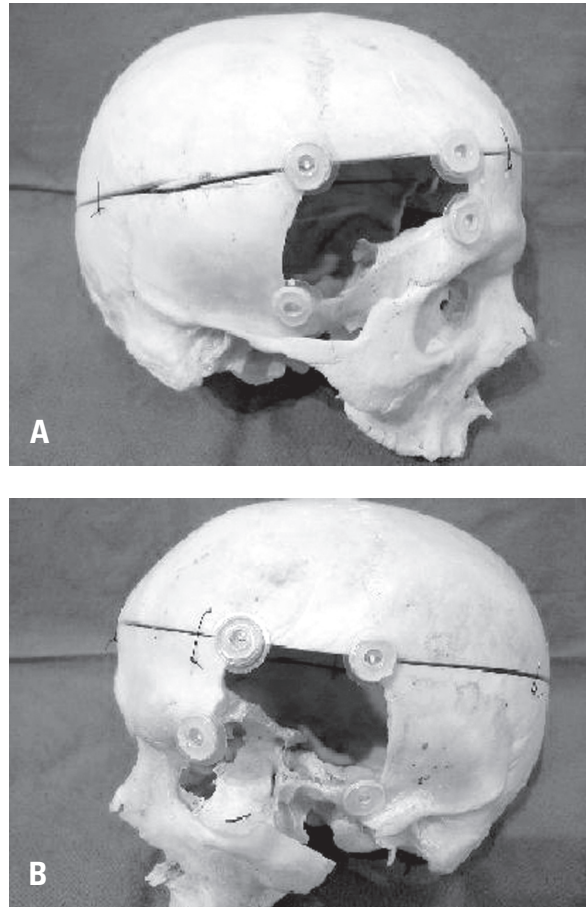
The aim of this anatomical study is to present a new concept using an image-guided frameless stereotactic system *in vivo* for analysing morphometric surgical approaches on the basis of the pterional (PT) and pterional-orbitozygomatic (POZ) approaches to the basilar artery bifurcation (BAB) by means of preoperative computer tomography (CT) images. We have measured the percentage change in "the cranial area of exposure", the depth of the "cranial surgical corridor" and "the cranial angle of attack" in degrees, when a pterional craniotomy was extended to an orbitozygomatic osteotomy. Our goal was to measure the parameters of a surgical approach in relation to high, normal and low-lying bifurcations.

## MATERIAL AND METHODS

Sixty virtual models of PT and POZ craniotomies were analysed using CT scans and a neuronavigation system. All images were made with the GE Medical System and the neuronavigation Stealth Station, Medtronic Treonä with Cranial 5 software.

Virtual models of craniotomies were created by precise studies of approaches on the skulls as shown in Figure 1A and 1B. Extreme points of craniotomy were marked and their solid location then studied. Analogous points were marked on the bone reconstruction in navigation. After the connection of these points we obtained a broad outline of the PT, which was increased by the orbitozygomatic part. The model of the surgical approach defined is clear and simple to use in further calculations (Fig. 2). We analysed only the benefits after extensive craniotomy, with no absolute values of the surgical window or the angle of attack.

The change in the depth of the cranial surgical corridor was measured along the trajectory of the approach to the BAB along the lesser wing of the sphenoid bone. For each model of craniotomy we examined three locations of the BAB. The BAB was considered normal when was located at the level of



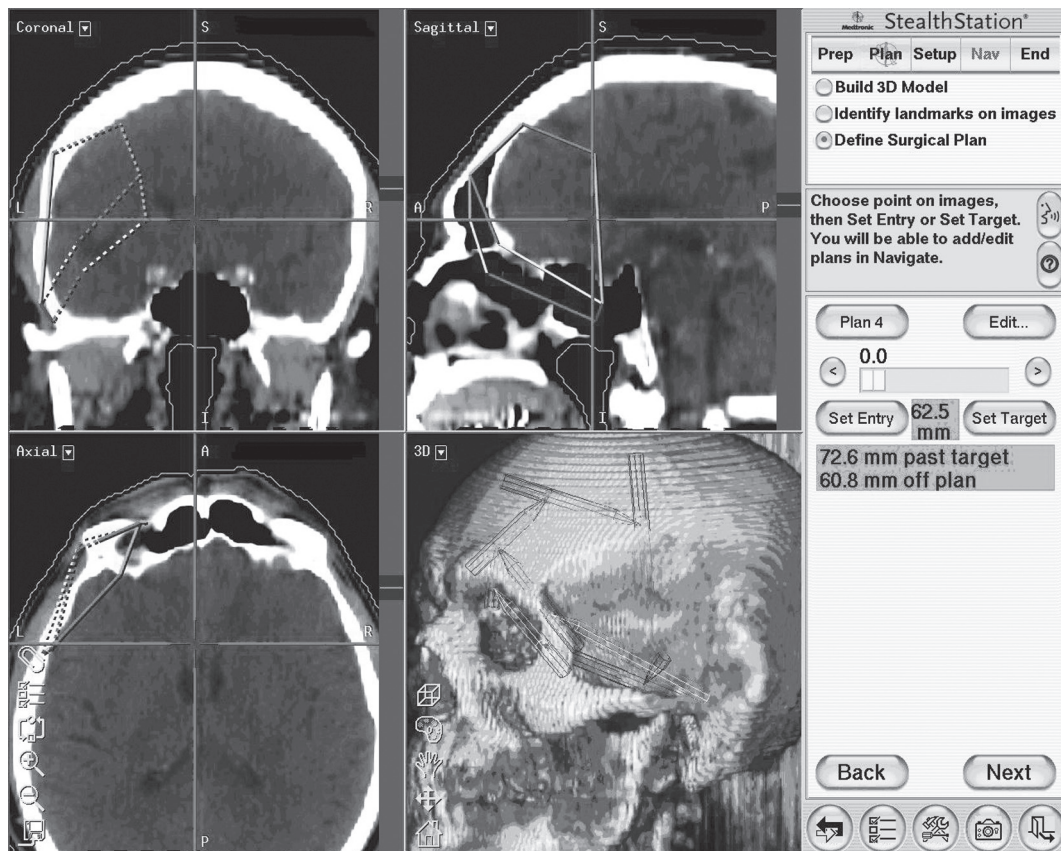
**Figure 1.** The pterional craniotomy (A) and pterional-orbitozygomatic craniotomy (B); extreme points of the craniotomy were marked and their solid location was analysed. The results were used to create the virtual craniotomies in the neuronavigation station.

the line connecting the anterior and posterior clinoids, a high bifurcation being more than 5 mm above this line and a low bifurcation more than 5 mm below this line on the basis of other authors' experience [1, 22].

The increase in the cranial angle of attack was measured along the wing of the sphenoid bone. This is the angle between the lower planes of PT and POZ craniotomies.

### Statistical analysis

The statistical analysis was performed using STATISTICA 7.0. software. Statistical comparisons between the various measurements, such as the cranial window of exposure, the cranial angle of attack and the depth of the cranial corridor, were performed using repeated-measurement analysis of variance followed by the Kolmogorov-Smirnov, Lilliefors and Lavenea tests and post-hoc analysis



**Figure 2.** Image showing the building of a virtual model of craniotomies using the bone reconstruction of patients' heads in the neuronavigation system. We defined and connected the extreme points of these two approaches in three projections: sagittal, coronal and axial.

(ANOVA). In all cases  $p \leq 0.05$  was considered significant.

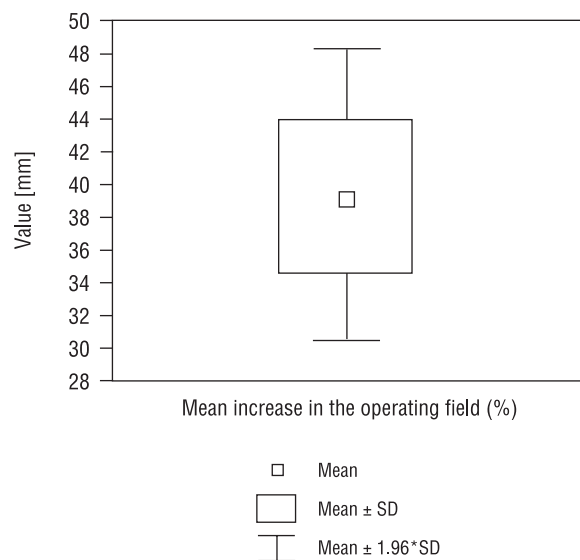
### RESULTS

The cranial area of exposure or the superficial external window of exposure for all the models of craniotomies was larger for the POZ approach by a mean of 39.28% (from 30.89% to 48.06%), and differences in the working window were statistically significant (Fig. 3)

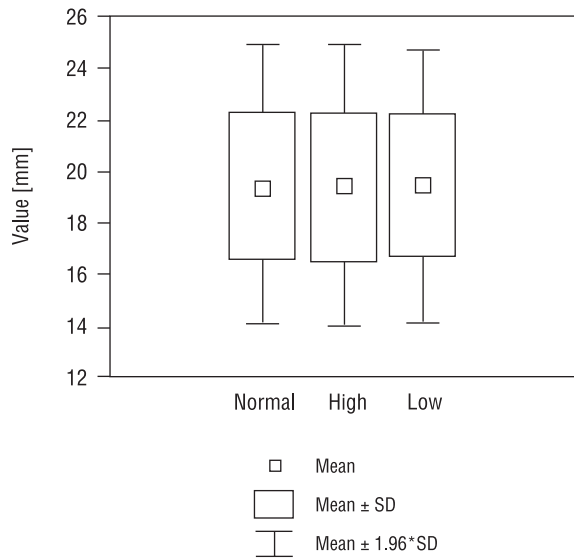
The mean decrease in the depth of the cranial surgical corridor (the distance from the surface of the craniotomy to the BAB) for the normal-lying BAB was 19.16%, for a high-lying BAB it was 19.09% and for a low-lying BAB 19.12% (Fig. 4).

The mean changes in the depth of the cranial surgical corridor in the individual BAB locations (high, normal and low) did not differ in a statistically significant way  $F(2.117) = 0.011$ ;  $p = 0.991$  (Fig. 4, 5).

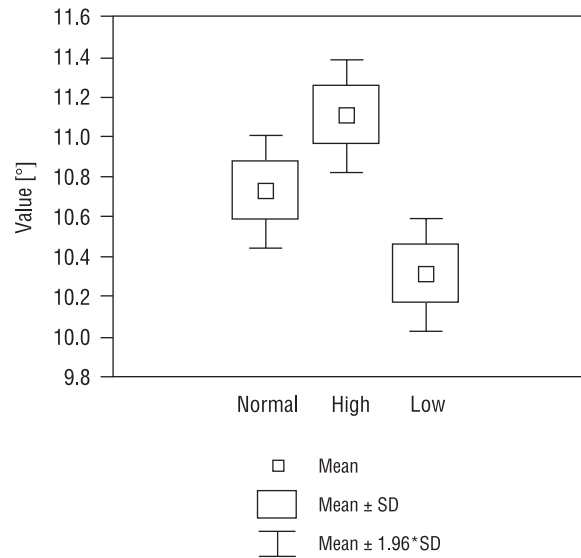
In converting a PT approach to a POZ approach we found that the increase in the cranial angle of



**Figure 3.** Graph of the percentage increase in the total cranial area of exposure after extension pterional craniotomy of the orbitozygomatic part.



**Figure 4.** Graph of the percentage decrease in the depth of the cranial surgical corridor after extension pterional craniotomy of the orbitozygomatic part for high, normal and low-lying basilar bifurcations.



**Figure 5.** Graph showing the mean increase in the cranial angle of attack in the basilar artery bifurcation (BAB) after the extension pterional craniotomy of the orbitozygomatic part for three BAB locations (high, normal and low-lying).

attack for a normally located BAB was a mean of  $10.72^\circ$ , for a high-lying BAB  $11.10^\circ$  and for a low-lying BAB  $10.31^\circ$  (Fig. 5). With the use of a *post-hoc* NIR test significant differences were demonstrated between the angles of attack of the normal and low-lying BABs ( $p = 0.034$ ) and the high and low-lying BABs ( $p = 0.001$ )

## DISCUSSION

The history of neuronavigation systems (frameless stereotactic systems) is short and dates back to the early 1990s. Their utilisation provides for continuous monitoring of the position of microsurgical instruments in the working area with reference to the nerve structures. It also facilitates decision-making about the total excision of the pathology, especially when it is located in the neighbourhood of "the eloquent structures". Because of this, the risk is reduced of complications associated with extension of the approach, the manipulation of microsurgical instruments, bleeding decreases and the duration of the operation [3, 5, 10, 14, 25].

The majority of morphometric studies have been performed *in vivo* using cadaveric heads [6, 7, 11, 19, 20, 22]. Although they seem to have faithfully rendered operative conditions, some authors reveal their limitation in anatomical studies [7, 11]. This arises for the following reasons. Cadaveric heads are

chemically fixed, which causes a difference in the stiffness and resistance of tissues [7, 11]. Spatial relationships change due to the lack of blood circulation or cerebrospinal fluid. Either the range of osteotomy or the retraction of the brain with spatulas in reaching the aneurism can be maximal and almost limitless, which cannot be repeated in *in vivo* conditions. The limitation is also in the small number of anatomical preparations [11], which, with some variability in anatomical structure, determines the type of statistical analysis.

The advantage of this study is the practically unlimited number of results which can be analysed in detail. The measurements were not performed *in vivo* for three reasons. Firstly, an additional adjustment with the active microprobe could cause complications for patients and might extend the operative time. Secondly, the working of the system is linked to errors. The registration error is not more than 2–3 mm, which is calculated by a computer at the beginning of the work after the registration of 47 chosen points from the surface of the patient's head. Additionally, the error may be increased by any interoperative changes connected with the rotation of the head, which is immobilised in the three-point headholder during the craniotomy [14], brain oedema or brain shift because of the force of gravity or after the release of cerebrospinal fluid [17].

Thirdly, it would be impossible to calculate how much the parameters (the cranial angle of attack, the cranial area of exposure, the depth of the cranial surgical corridor) have changed in relation to the extent of the craniotomy with respect to an individual patient.

The results obtained show that the increase in the cranial area of exposure for the pterional craniotomy after orbitozygomatic osteotomy is between 30.89% and 48.06% (mean 39.28%). We emphasise that this value should not be interpreted as an increase in the real working area, which, being situated deeply in the surgical corridor is also limited by neurovascular structures. The orbitozygomatic osteotomy to the skull base causes only the possibility of better visualisation. The same concerns the depth and angle of attack of the surgical corridor or area. Similar results were obtained by Schwarz et al. [20], who have shown that the increase in the area of exposure in approaching the basilar tip target in orbitozygomatic osteotomy was 39–51%. Unfortunately, the authors do not disclose what the relation was of the BAB to the posterior clinoid process.

In ideal conditions the depth of the surgical approach corresponds to the distance from the surface of the craniotomy to the neck of the aneurysm. However, during the operation the surgeon's hands are situated above the brain surface. The relationship between the side of the approach and the left- or right-handedness of the surgeon is also important. The following factors increase the depth of the surgical approach, so that the term "depth of the surgical corridor" as presented in previous studies is relative. This is why we have introduced the term "cranial surgical corridor," the distance from the lower edge of both craniotomies (the skull base) to the BAB moving along the trajectory of approach (the wing of the sphenoid bone). In the calculation presented the decrease in the cranial surgical corridor is about 19%. According to Andaluz et al. [2], who measured the morphometric dependence of pterional and orbitopterional craniotomies, the orbitopterional approach shortened the distance from 62 mm to 54 mm, with a mean of 13%. The authors concluded that a shorter distance to the target point results in improved illumination and observation for more precise surgical movements [2].

The mean increase in the cranial angle of attack for a normally located BAB was 10.72°, for a high-lying BAB 11.10° and for a low-lying BAB 10.31°. We found that the increase in cranial angle of attack is statistically significant for high and low-

-lying BABs and for normal and low-lying BABs. Sindou et al. [23] in an anatomical study using 11 cadaveric heads demonstrated that the orbitozygomatic osteotomy in combination with a pterional craniotomy increased the angle of view by 10° in reaching the basilar bifurcation along the sylvian fissure. Chanda and Nanda [4] (test performed with 5 preparations) reported a 13°–14° increase in the angle of view for the BAB. Unfortunately the change in the angle value with regard to the anatomical variety of the BAB location in relation to the posterior clinoid process has not been analysed in any previous study. This is similar to the results found by Gonzalez et al. [11], who quantitatively assessed different variations of the pterional, orbitozygomatic and maxillar approaches to determine the working area and the angle of attack in three virtual triangles in the anterior cranial fossa. They showed an increase in the angle of attack for the anterior clinoid process of  $10.2 \pm 0.7^\circ$  after extending the pterional craniotomy of an orbitozygomatic osteotomy. Figueiredo et al. [8] compared the angle of approach and area of exposure to the ACoA offered by the pterional, orbitopterional and orbitozygomatic approaches before and after gyrus rectus resection. The vertical angle, defined as the main craniocaudal axis of the approach perpendicular to the cranial base, increased significantly between the PT and POZ approaches by 10.2° before gyrus rectus resection [8].

## CONCLUSION

Neuronavigation systems, already well-known for their intraoperative use, can also be useful in morphometric studies, and the advantages of this method are the practically unlimited number of results which can be analysed in detail and the repeatability of the technique.

Morphometric studies provide much information that is useful for the analysis of surgical approaches, but the clinical value of precise measurements with descriptive statistics needs careful judgment. There are *in vivo* studies that are linked to errors which do not take into consideration all aspects of the operation.

We conclude that the pterional-orbitozygomatic approach compared to the pterional increases cranial area, minimises retraction of the brain, shortens the depth of the surgical corridor, enables surgical instruments to be used more easily, widens the angle of view and improves the visibility of the anatomical structures in the working area, especially for a high-lying basilar artery bifurcation.

## REFERENCES

1. Abdel-Aziz KM, van Loveren HR, Tew JM (1999) The Kawase approach to retrosellar and upper clival basilar aneurysms. *Neurosurgery*, 44: 1225–1236.
2. Andaluz N, von Loveren HR, Keller JT (2003) Anatomic and clinical study of the orbitopterional approach to anterior communicating artery aneurysms. *Neurosurgery*, 52: 1140–1149.
3. Benardete EA, Leonard MA, Weiner HL (2001) Comparison of frameless stereotactic systems: accuracy, precision and application. *Neurosurgery*, 49: 1409–1416.
4. Chanda A, Nanda A (2002) Anatomical study of the orbitozygomatic transsellar-transcavernous-transclinoidal approach to the basilar artery bifurcation. *J Neurosurg*, 97: 151–160.
5. Dorward NL, Alberti O, Palmer JD (1999) Accuracy of true frameless stereotaxy. *J Neurosurg*, 90: 160–168.
6. Erturk M, Kayalioglu G, Ozer MA (2003) Morphometry of the anterior third ventricle region as a guide for the subfrontal (translaminaterminalis) approach. *Neurosurgical Rev*, 26: 249–252.
7. Evans JJ, Hwang YS, Lee JH (2000) Pre- versus post-anterior clinoidectomy measurements of the optic nerve, internal carotid artery and opticocarotid triangle: a cadaveric morphometric study. *Neurosurgery*, 46: 1018–1023.
8. Figueiredo EG, Zabramski JM, Deshmukh P, Crawford NR, Spetzler RF, Preul MC (2006) Comparative analysis of anterior petrosotomy and transcavernous approaches to retrosellar and upper clival basilar artery aneurysms. *Neurosurgery*, 58 (ONS suppl. 1): ONS13–ONS21.
10. Germano IM, Villalobos H, Silvers A (1999) Clinical use of the optical digitizer for intracranial neuronavigation. *Neurosurgery*, 45: 261–270.
11. Gonzalez LF, Crawford NR, Horgan M (2002) Working area and angle of attack in three cranial base approaches: pterional, orbitozygomatic and maxillary extension of the orbitozygomatic approach. *Neurosurgery*, 50: 550–557.
12. Hakuba A, Liu S, Nishimura S (1986) The orbitozygomatic infratemporal approach: a new surgical technique. *Surg Neurol*, 26: 271–276.
13. Heros RC, Lee SH (1993) The combined pterional/anterior temporal approach for aneurysms of the upper basilar complex. Technical note. *Neurosurgery*, 33: 244–251.
14. Hill DL, Maurer Cr Jr, Maciunas RJ (1998) Measurement of intraoperative brain surface deformation under a craniotomy. *Neurosurgery*, 43: 514–528.
15. Kato Y, Sano H, Behari S (2002) Surgical clipping of basilar aneurysms: Relationship between the different approaches and the surgical corridors. *Minim Invas Neurosurg*, 45: 142–145.
16. Krisht AF, Kadri P (2005) Surgical clipping of complex basilar apex aneurysms: a strategy for successful outcome using the pterional transzygomatic transcavernous approach. *Neurosurgery*, 56 (ONS suppl. 2): ONS261–ONS273.
17. Nabavi A, McL Black P, Gering DT (2001) Serial intraoperative magnetic resonance imaging of brain shift. *Neurosurgery*, 48: 787–798.
18. Sano K (1980) Temporopolar approach to aneurysms of the basilar artery and around the distal bifurcation. *Neurol Res*, 2: 361–367.
19. Sato S, Sato M, Oizumi T (2001) Removal of anterior clinoid process for basilar tip aneurysm: clinical and cadaveric analysis. *Neurol Res*, 23: 298–303.
20. Schwartz MS, Anderson GJ, Horgan MA (1999) Quantification of increased exposure resulting from orbital rim and orbitozygomatic osteotomy via the frontotemporal transsylvian approach. *J Neurosurg*, 91: 1020–1026.
21. Sekhar LN, Kalia KK, Yonas H (1994) Cranial base approaches to intracranial aneurysms in subarachnoid space. *Neurosurgery*, 35: 472–483.
22. Seoane E, Tedeschi H, de Oliveira E (2000) The pretemporal transcavernous approach to the interpeduncular and prepontine cisterns: microsurgical anatomy and technique application. *Neurosurgery*, 46: 891–899.
23. Sindou MP, Alaywan M (1994) Fronto-temporal approaches with removal of the orbital rim and/or the zygomatic arch: surgical technique, microsurgical anatomy and clinical applications. In: Samii M (ed) *Skull base surgery: anatomy, diagnosis and treatment*. Basel, Karger, pp. 739–741.
24. Sindou M, Emery E, Acevedo G (2001) Respective indications for orbital rim, zygomatic arch and orbitozygomatic osteotomies in the surgical approach to central skull base lesions. Critical, retrospective review in 146 cases. *Acta Neuroch*, 143: 967–975.
25. Zieliński P, Dierżanowski J, Słoniewski P (2003) Neurosurgical stereomorphometry in vivo-method description and error measurement. *Folia Morphol*, 62: 71–73.