

# Anatomy of the posterior cruciate ligament

A. Chwaluk<sup>1</sup>, B. Ciszek<sup>2</sup>

<sup>1</sup>Department of Anatomy, External Faculty of Physical Education in Białą Podlaska, Academy of Physical Education in Warsaw, Poland

<sup>2</sup>Department of Anatomy, Centre of Biostructure Research, Medical University of Warsaw, Poland

[Received 16 June 2008; Accepted 18 October 2008]

*The purpose of the study was to explain the architecture of the posterior cruciate ligament because the views on its structure presented in the literature are inconsistent — from those considering it as indivisible to those presenting it as a multifascicular structure. Twenty formalin-fixed ligaments from human knee joints were tested using the preparation technique. All posterior cruciate ligaments clearly divided into the anterolateral bundle and the posteromedial bundle (20/20). In all ligaments, 2 fascicles were identified in the posteromedial bundle (20/20). In most cases, 2 fascicles were also seen in the anterolateral bundle (14/20). Less commonly, it consisted of multiple fascicles (6/20). (Folia Morphol 2009; 68, 1: 8–12)*

**Key words:** knee joint, anterolateral bundle, posteromedial bundle

## INTRODUCTION

The posterior cruciate ligament (PCL) originates at the internal surface of the medial condyle of the femur, it goes slightly posteriorly, laterally, and downwards, and has its insertion at the posterior intercondylar area of the tibia. The terminal insertion also extends a few millimetres on the adjacent posterior surface of the tibia [1, 7, 9]. The PCL has a primary function in resisting posterior translation of the tibia on the femur and a secondary role in limiting external, varus, and valgus rotations [4, 10].

Views on the architecture of the posterior cruciate ligament are inconsistent. The inconsistencies refer to the ligament anatomy — whether it is indivisible [5, 8, 21], or its structure is more complex, or even multifascicular [3, 4, 11]. The clinical posterolateral complex of PCL includes (except for the posterior cruciate ligament) the anterior and posterior meniscofemoral ligaments (AMFL, PMFL) [14]. The explanation of the structure seems significant from a clinical point of view. In the past, the reconstruction of the cruciate ligament was only performed

using a single bundle, just replacing the anterolateral bundle (AL-PCL). At present, techniques using two bundles to reconstruct the anterolateral and the posteromedial (PM-PCL) bundles are preferred [12, 19].

## MATERIAL AND METHODS

The study was performed on the material of 20 human knee joints from the collection of the Department of Anatomy of the Medical University of Warsaw. The preparations were knee joints of adults who had no gross pathologies of the osteoarticular system of the lower limbs, or from lower limbs amputated due to pathologies of an area of the lower limb other than the knee region. The knee joints were fixed in formaldehyde solution. The capsuloligamentous structures of the knee joint were removed, excluding the posterior cruciate ligament, the lateral meniscus, and the possible meniscofemoral ligaments. Osteoligamentous blocks were cut; the blocks contained the medial condyle of the femur and a wedge-shaped section from the proximal end of the tibia. The posterior cruciate ligaments were

---

Address for correspondence: A. Chwaluk, Department of Anatomy, External Faculty of Physical Education in Białą Podlaska, Akademicka 2, 21–500 Białą Podlaska, Poland, tel. +48 83 342 87 36, e-mail: [agnieszka.chwaluk@awf-bp.edu.pl](mailto:agnieszka.chwaluk@awf-bp.edu.pl)

**Table 1.** Structure of posterior cruciate ligament (PCL) and occurrence of meniscofemoral ligament (MFL)

No. of knee	Side	Structure of PCL bundles					Occurrence of MFL	
		Anterolateral bundle			Posteromedial bundle		Anterior meniscofemoral ligament	Posterior meniscofemoral ligament
		Centr.	Ant.	Ant.-lat.	Ant.-med.	Post.-lat.		
I	R	x		x	x	x	x	
II	L		Multifasc.		x	x		x
III	R	x	x		x	x	x	x
IV	R		Multifasc.			Parallel	x	x
V	L	x	x			Parallel		
VI	L		Multifasc.		x	x	x	
VII	R	x	x			Parallel	x	x
VIII	R	x		x		Inversed*	x	
IX	R	x		x	x	x	x	x
X	R	x	x		x	x	x	
XI	L	x		x	x	x	x	
XII	L	x	x		x	x	x double	
XIII	L		Multifasc.		x	x	x	
XIV	L	x	x		x	x	x	x
XV	L	x	x			Parallel	x	x
XVI	L	x		x	x	x	x	x
XVII	R		Multifasc.		x	x	x	
XVIII	L	x		x		Inversed*	x	x
XIX	L	x	x		x	x	x	x
XX	R		Multifasc.		x	x		

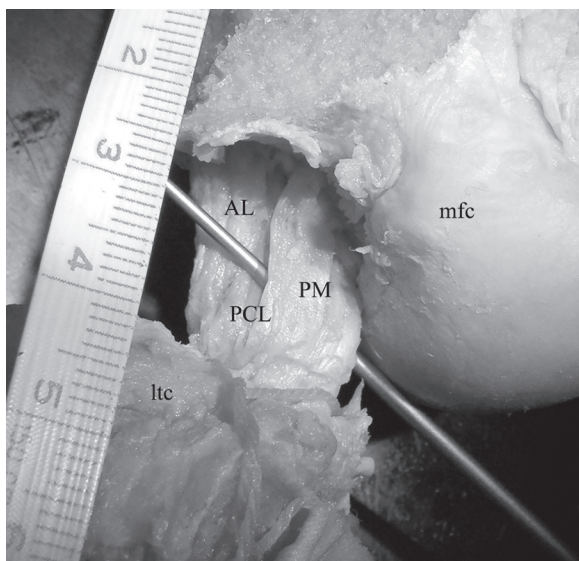
\*PM: anterolateral and posteromedial fascicles

prepared using an operation microscope with microsurgical instruments.

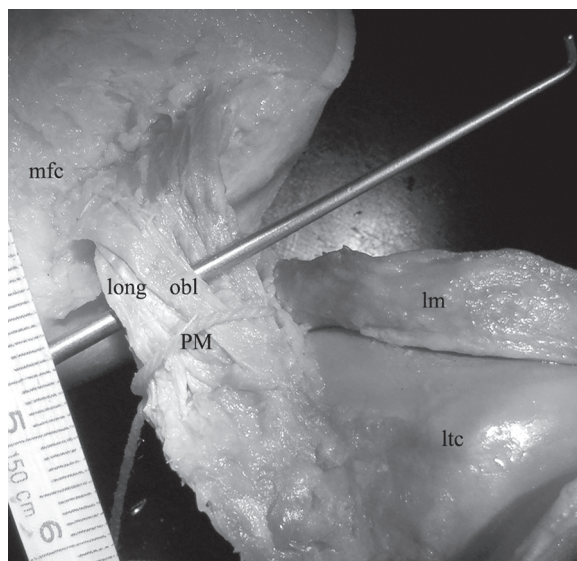
## RESULTS

Nine right and eleven left posterior cruciate ligaments were examined (Table 1). All ligaments divided into at least 2 bundles: anterolateral (AL) and posteromedial (PM) (Fig. 1). In 14 cases, the AL bundle divided into a further 2 parts. These was a larger fascicle located more centrally (central) and a smaller anterior part which accompanied it either only anteriorly (anterior; 8 cases), or anteriorly and laterally (anterolateral; 6 cases). These 2 fascicles could be separated mainly at the femoral insertion, and the lower it was, the more difficult it was to separate the central fascicle (Fig. 2). In the remaining 6 cases, the anterolateral bundle of the posterior

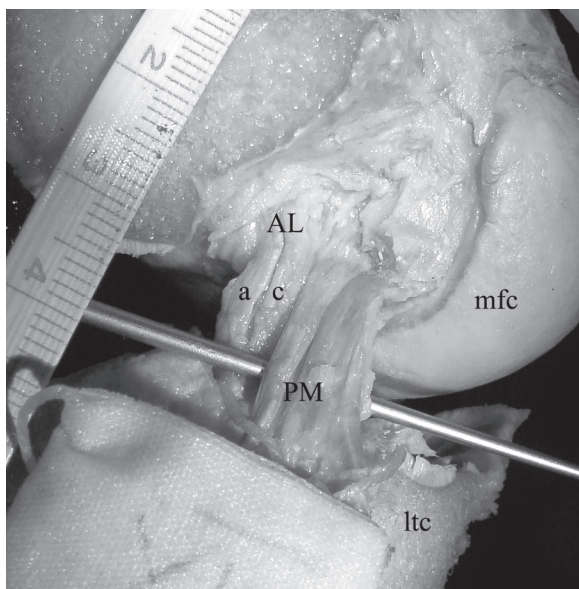
cruciate ligament consisted of many parallel fascicles (multifascicular). The PM bundle always consisted of 2 parts. One part was usually positioned more vertically, i.e. longitudinally, and was located medially, and the other part was positioned more diagonally and was located laterally. In these knees, the fascicles were mutually arranged one behind the other: the longitudinal one anteriorly (anteromedial) and the oblique one posteriorly (posterolateral; 14 cases) (Fig. 3). In 4 knee joints, the 2 fascicles forming the posteromedial bundle of the posterior cruciate ligament went parallel to each other (medial and lateral) (Fig. 4), and in the remaining joints the longitudinal fascicle was positioned behind the oblique fascicle (anterolateral and posteromedial; 2 cases). On the medial condyle of the femur, the insertion of the longitudinal part was




**Figure 1.** Posterior cruciate ligament (PCL); AL — anterolateral bundle, PM — posteromedial bundle, mfc — medial femoral condyle, ltc — lateral tibial condyle.



**Figure 3.** Posteromedial bundle of posterior cruciate ligament — posteromedial bundle (PM); long — longitudinal fascicle, obl — oblique fascicle, ltc — lateral tibial condyle, mfc — medial femoral condyle, lm — lateral meniscus.



**Figure 2.** Anterolateral bundle of posterior cruciate ligament (PCL) — anterolateral bundle (AL); a — anterior fascicle, c — central fascicle, PM — posteromedial bundle of PCL, mfc — medial femoral condyle, ltc — lateral tibial condyle.



**Figure 4.** Posteromedial bundle of posterior cruciate ligament (PCL) — posteromedial bundle (PM) — parallel fascicles; AL — anterolateral bundle of PCL, mfc — medial femoral condyle, ltc — lateral tibial condyle.

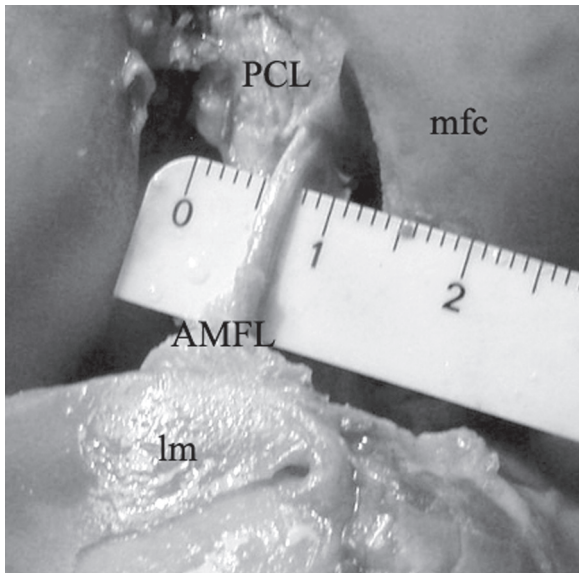
located more anteriorly, reaching the intercondylar fossa, and the oblique part had its insertion more inferiorly. The 2 fascicles divided most easily at the tibial insertion. In 17 cases, the posterior cruciate ligament was accompanied by the anterior menisocofemoral ligaments (Fig. 5), and in 11 cases the posterior menisocofemoral ligaments (Fig. 6).

## DISCUSSION

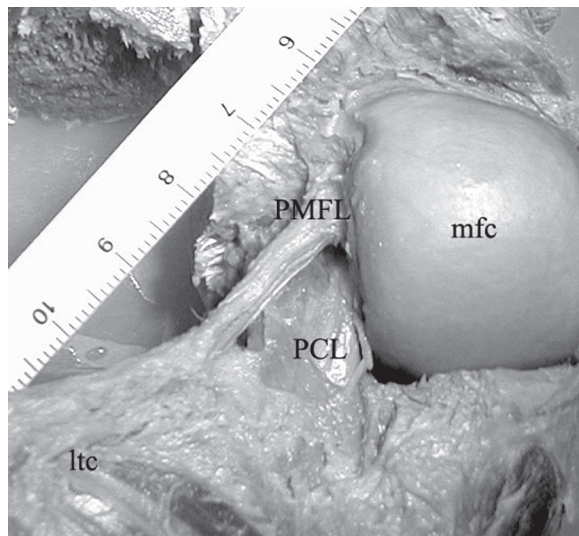
### Division of posterior cruciate ligament based on its arrangement

Views on the structure of the posterior cruciate ligament may be classified as those regarding the ligament as indivisible and those presenting it as





**Figure 5.** Anterior menisofemoral ligament (AMFL); mfc — medial femoral condyle, lm — lateral meniscus; PCL — posterior cruciate ligament.



**Figure 6.** Posterior menisofemoral ligament (PMFL); mfc — medial femoral condyle, ltc — lateral tibial condyle, PCL — posterior cruciate ligament.

composed of many fascicles. Some investigators claim that the PCL has a monofascicular structure [5, 7, 8]. A similar view was presented by Satku et al. [21], according to whom, although the cruciate ligaments have anterolateral and posteromedial fibres, they are not clearly separated. More commonly, the posterior cruciate ligament is believed to have a complex structure. According to Girgis and

Marshall [9], the PCL consists of 2 parts but they are inseparable. The most common view presents the ligament as a structure containing 2 separated bundles which are sometimes referred to as the anterior and posterior parts: aPC and pPC [19], and usually as the AL-PCL and PM-PCL [2, 6, 13–15, 20, 23]. Some authors even found the 2 bundles to have a different ultrastructure [11]. Other anatomists believe that the division of the PCL into 2 bundles is too simple. Trent and Kurosawa et al. [17, 22] divide the PCL fibres into the anterior, middle, and posterior fascicles. Some authors identify, as in this study, the posterior oblique fascicle of the posterior cruciate ligament, which has nothing in common with the posterior menisofemoral ligament (PMFL) because it clearly attaches to the tibia [16]. The posterior fibres of the posterior cruciate ligament forming the oblique part should not be mistaken for the PMFL, which goes diagonally from the posterior margin of the initial insertion of the PCL on the femur to the lateral meniscus or the tibia near the terminal insertion of the PCL [1, 5]. Harner and Hoher [12] consider the posterior menisofemoral ligament as one of the three components of the PCL. Many authors also describe the posterior cruciate ligament as a continuum of fibres. In this case it consists of 4 regions: anterior, central, posterior longitudinal, and posterior oblique [4]. Makris et al. [18] divide the ligament into 4 fascicles: anterior, central, posterior longitudinal, and posterior oblique. In this study, however, the separation of the anterior and the central part was not possible in some cases.

#### **Division of posterior cruciate ligament based on its function**

Even if the ligament is viewed as a single bundle, tensions in individual ligament fibres differ during movement. Some authors believe that there is a bundle which is constantly stretched [21]. From among the two bundles, the anterolateral PCL is stretched while flexed, relaxed while extended, and the posteromedial PCL is visibly stretched while extended and slightly relaxed while flexed [9, 11, 12, 14, 15]. Fuss divides the ligament into three functional groups: fibres stretched in transitional positions, fibres stretched in full extension, and fibres stretched in full flexion [8].

In the case of division of the PCL into 4 elements: anterior, central, posterior longitudinal, and posterior oblique, the anterior fibres are totally relaxed in full extension, the central fibres are less stretched

than the anterior compartment, and the posterior longitudinal and oblique fibres are stretched. During flexion the anterior and central fibres become stretched, with the posterior fibres becoming slightly relaxed. With increasing knee flexion, the posterior bundle stretches again, the anterior bundle remains stretched, and the central bundle shows no signs of relaxation [18]. However, functional aspects were not the subject of this study.

### ACKNOWLEDGEMENTS

The study was performed as part of the internal study plan (BW. III/18) of the External Faculty of Physical Education in Biała Podlaska of the Academy of Physical Education in Warsaw, Poland.

### REFERENCES

1. Amis AA, Gupte CM, Bull AM, Edwards A (2006) Anatomy of the posterior cruciate ligament and the meniscomfemoral ligaments. *Knee Surg Sports Traumatol Arthrosc*, 14: 257–263.
2. Baek GH, Carlin GJ, Vorgan TM, Woo SL-Y, Harner CD (1998) Quantitative analysis of collagen fibrils of human cruciate and meniscomfemoral ligaments. *Clin Orthop*, 357: 205–211.
3. Barton TM, Torg JS, Das M (1984) Posterior cruciate ligament insufficiency. A review of literature. *Sports Med*, 1: 419–430.
4. Covey DC, Sapega AA (1993) Injuries of the posterior cruciate ligament. *J Bone Joint Surg*, 75A: 1376–1386.
5. Dommelen van BA, Flower PJ (1989) Anatomy of the posterior cruciate ligament. A review. *Am J Sports Med*, 17: 24–29.
6. Edwards A, Bull AM, Amis AA (2007) The attachments of the fiber bundles of the posterior cruciate ligament: an anatomic study. *Arthroscopy*, 23: 284–290.
7. Fuss FK (1989) Anatomy of the cruciate ligaments and their function in extension and flexion of the human knee joint. *Am J Anat*, 184: 165–176.
8. Fuss FK (1991) The restraining function of the cruciate ligaments on hyperextension and hyperflexion of the human knee joint. *Anat Rec*, 230: 283–289.
9. Girgis FG, Marshall JL (1975) The cruciate ligaments of the knee joint. Anatomical, functional and experimental analysis. *Clin Orthop*, 106: 216–231.
10. Grood ES, Stowers SF, Noyes FR (1988) Limits of movement in the human knee. *J Bone Joint Surg*, 70A: 88–97.
11. Harner CD, Baek GH, Vorgan TM, Carlin GJ, Kashiwaguchi S, Woo SL-Y (1999) Quantitative analysis of human cruciate ligament insertions. *Arthroscopy*, 15: 741–749.
12. Harner CD, Hoher J (1998) Evaluation and treatment of the posterior cruciate ligament injuries. *Am J Sports Med*, 26: 471–482.
13. Harner CD, Livesay GA, Kashiwaguchi S, Fujie H, Choi NY, Woo SL-Y (1995) Comparative study of the size and shape of human anterior and posterior cruciate ligaments. *J Orthop Res*, 13: 429–434.
14. Harner CD, Xerogeanes JW, Livesay GA, Carlin GJ, Smith BA, Kusayama T, Kashiwaguchi S, Woo SL-Y (1995) The human posterior cruciate ligament complex: an interdisciplinary study. *Am J Sports Med*, 23: 736–745.
15. Hughston JC, Bowden JA, Andrews JR, Norwood LA (1980) Acute tears of the posterior cruciate ligament. Results of operative treatment. *J Bone Joint Surg*, 62A: 348–450.
16. Inderster A, Benedetto KP, Klestil T, Kunzel KH, Gaber O (1995) Fiber orientation of posterior cruciate ligament: an experimental morphological and functional study, Part 2. *Clin Anat*, 8: 315–322.
17. Kurosawa H, Yamakoshi K-I, Yasuda K, Sasaki T (1991) Simultaneous measurement of changes in length of the cruciate ligaments during knee motion. *Clin Orthop*, 265: 233–240.
18. Makris CA, Georgoulis AD, Papageorgiou CD, Moebius UG, Soucacos PN (2000) Posterior cruciate ligament architecture: evaluation under microsurgical dissection. *Arthroscopy*, 16: 627–632.
19. Race A, Amis AA (1998) PCL reconstruction: *in vitro* biomechanical comparison of “isometric” versus single and double-bundle “anatomic” grafts. *J Bone Joint Surg*, 80B: 173–179.
20. Race A, Amis AA (1994) The mechanical properties of the two bundles of the human posterior cruciate ligament. *J Biomech*, 27: 13–24.
21. Satku K, Chew CN, Seow H (1984) Posterior cruciate ligament injuries. *Acta Orthop Scandinav*, 55: 26–29.
22. Trent PS, Walker PS, Wolf B (1976) Ligament length patterns, strength and rotational axes of the knee joint. *Clin Orthop*, 117: 263–270.
23. Zaffagnini S, Martelli S, Garcia L, Visani A (2004) Computer analysis of PCL fibres during range of motion. *Knee Surg Sports Traumatol Arthrosc*, 12: 420–428.