

The functional anatomy of hip abductors

A. Al-Hayani

Department of Anatomy, Faculty of Medicine, King Abdul Aziz University, Jeddah, Saudi Arabia

[Received 25 November 2008; Accepted 11 April 2009]

The gluteal region was dissected in 18 adult cadavers. The attachments, directions, and orientations of the fibres of the tensor fasciae latae, gluteus medius, and gluteus minimus muscles were noted. The gluteus medius was found to be formed of three distinct parts, while the gluteus minimus was formed of two parts only; each part of these muscles had its separate innervations from the superior gluteal nerve. The tensor fasciae latae muscle arose from the anterior part of the outer lip of the iliac crest and was attached to the iliotibial tract slightly below and in front of the greater trochanter. The direction of the fibres of the anterior and middle parts of the gluteus medius and the anterior part of the gluteus minimus suggested that they have vertical pull and initiate abduction which is then completed by the tensor fasciae latae. The function of the posterior parts of the gluteus medius and minimus, being parallel to the neck of the femur, would be stabilization of the femoral head in the acetabulum during the different stages of the gait cycle. By resolving the line of action of the tensor fasciae latae muscle, it was found to help the muscle to fix the hip and femur together during the stance phase and to counteract the weight of the body during standing position. (Folia Morphol 2009; 68, 2: 98–103)

Key words: gluteus medius, gluteus minimus, tensor fasciae latae, hip abductors

INTRODUCTION

Knowledge of the accurate anatomical and bio-mechanical environment of the hip joint is of considerable importance to health care professionals. The designs of surgical procedures and implants to reconstruct diseased hips could be significantly improved if one had an appreciation of the mechanical environment in which the reconstructed hip must function during gait and other daily activities [4].

Many authors have described the anatomy, mechanics, and functional performance of the hip muscles and abductor mechanism [1–8]. Some of the experimental studies reported by these authors present observations that reveal the disparity between the functional reality and the biomechanical model of the system.

The studies by Jensen and Davy [9] on the muscle line of action, Clark and Haynor [4] on the anatomy of the abductor muscles of the hip, and Soderberg and Dostal [10], Lyons et al. [11], and Wilson et al. [12] on fine wire electromyographic investigation of the abductor muscles provided the anatomy, mechanics, and functions of these muscles.

However, a review of these papers revealed the absence of satisfactory anatomical and dynamic models to explain adequately the findings of these studies and thus did not allow those authors to draw valid conclusions.

The purpose of this study was to define the attachment and direction of fibres, and to resolve their line of action on the hip joint as well as their role in gait cycle and support of body weight.

MATERIAL AND METHODS

A total of 18 adult formalin-embalmed cadavers (36 gluteal regions, 18 right and 18 left) of different age and sex were obtained from the dissecting room of the Department of Anatomy of the Faculty of Medicine of King Abdul-Aziz University, Jeddah, Saudi Arabia. The current study was carried out in the mortuary of the Faculty of Medicine, King Abdulaziz University. The study was ethically approved by the Bioethics Committee of the Faculty of Medicine, King Abdulaziz University.

The attachments of the gluteus medius, gluteus minimus, and tensor fasciae latae muscles were determined proximally and distally. The shapes of the muscles and the direction and orientation of their fibres were defined. The superior gluteal nerve and its branches were traced from the greater sciatic notch and followed into the muscles.

The direction of the fibres of the tensor fasciae latae muscles, and their relative position and attachment to the iliotibial tract and to the hip joint were noted. The anterior and lateral projection of the fibres of the tensor fasciae latae were compared with the mechanical axis of the femur and with the line of the body resolved from the centre of the sacroiliac joint.

The direction of the posterior fibres of the gluteus medius and minimus and their line of action was compared to the mechanical axis of the neck of femur, and their effect on the hip joint was considered.

RESULTS

The proximal attachment of the gluteus medius was found to be from the outer surface of the ala of ilium, between the iliac crest and the posterior gluteal line above and the anterior gluteal line below, and from the overlying deep fascia. The muscle bulk had three distinct parts (anterior, middle, and posterior) which were of unequal sizes (Figs. 1, 2). The anterior part was the largest; it had fibres running almost vertically from the ala of ilium to the ridge on the lateral aspect of the greater trochanter (Fig. 3).

Distally, the anterior part overlapped the middle and posterior portions (Fig. 1).

The fibres of the middle part tended to be more vertically oriented (Figs. 1, 2). They distally overlapped the posterior part (Fig. 1). The fibres of the posterior part were parallel to the neck of the femur (Fig. 4).

The gluteus minimus was attached proximally to the outer surface of the ala of ilium between the anterior and inferior gluteal lines. The muscle bulk had two distinct parts (anterior and posterior) making up a fan shape (Fig. 5).

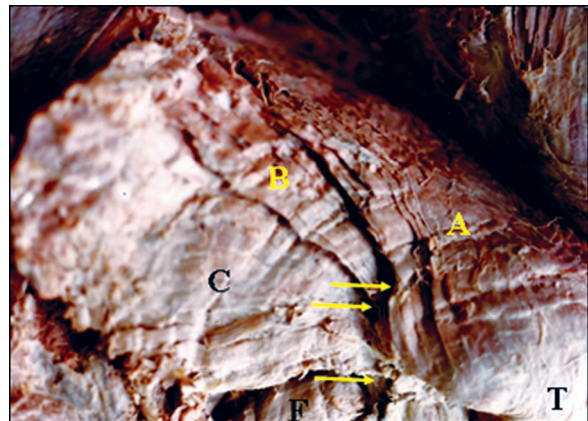


Figure 1. A photograph of a specimen showing the three distinct parts of the gluteus medius muscle anterior part (A), middle part (B), and posterior part (C). Notice that they overlap each other near their insertion (arrows). The greater trochanter (T) and piriformis muscle (F) can be seen.

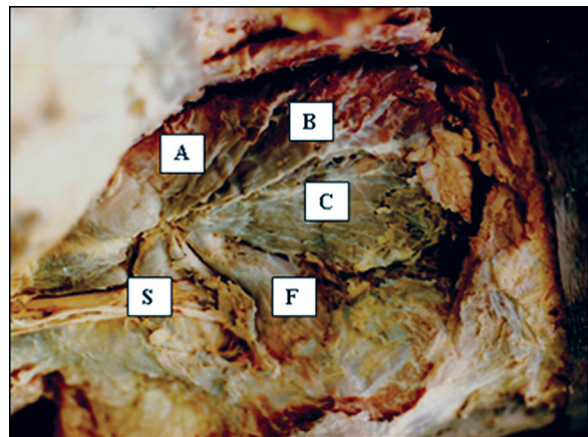


Figure 2. A photograph of a specimen showing the three parts of the gluteus medius muscle anterior part (A), middle part (B), and posterior part (C). Notice that the fibres of the anterior and middle parts are nearly vertical, while those of the posterior part are nearly horizontal. The piriformis muscle (F) and the sciatic nerve (S) can be seen.

The anterior part had vertically directed fibres running from the ilium to the greater trochanter. Its distal end blended with that of the anterior part of the gluteus medius and shared its attachment to the ridge on the lateral aspect of the greater trochanter (Fig. 5).

The posterior part was formed of nearly horizontal fibres; its distal end passed deep into that of the anterior part to be attached to the anterior aspect of the greater trochanter (Fig. 5).

The inferior division of the superior gluteal nerve ran between the gluteus medius and minimus muscles and gave off separate branches to each of the three parts of the gluteus medius and to the two parts of the gluteus minimus (Fig. 6).

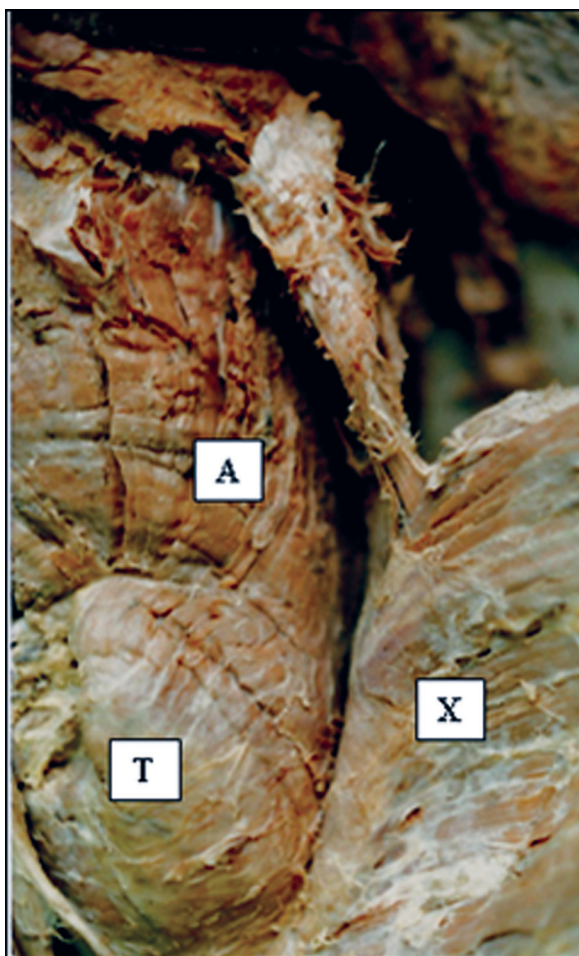


Figure 3. A photograph of the anterior part of the gluteus medius (A) attached to the ridge on the outer surface of the greater trochanter (T). Notice its vertically directed fibres. The gluteus maximus muscle (X) is reflected laterally.

More frequently, the branch to the posterior part of the gluteus medius arose in the greater sciatic notch (Fig. 7).

The tensor fasciae latae muscle was found to arise from the most anterior part of the outer lip of the iliac crest. Its fibres ran nearly vertically to be attached to the anterior aspect of the iliotibial tract slightly below and in front of the greater trochanter of the femur (Fig. 8).

A projection of the line of action of the posterior part of the gluteus medius muscle showed that the fibres were parallel to the axis of the neck of the femur (Fig. 4). A projection of the line of action of the tensor fasciae latae muscle in anterior and lateral views was found to be parallel to the mechanical axis of the femur and to the line of body weight drawn vertically from the centre of the sacroiliac joint (Figs. 9, 10).

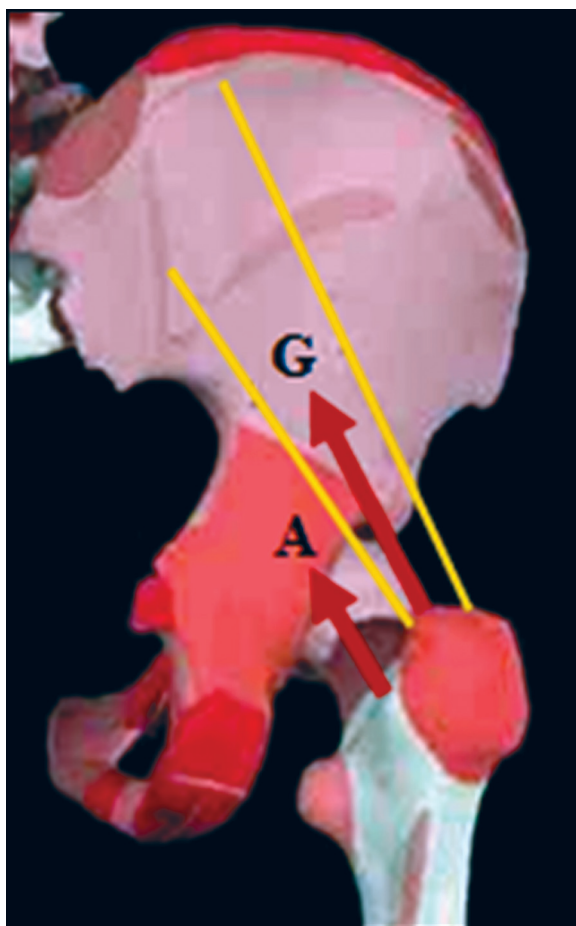


Figure 4. A diagram showing the line of action of the posterior part of the gluteus medius muscle (G). Notice that its fibres are parallel to the axis of the neck of the femur (A).

DISCUSSION

The classical description of the anatomy of the gluteus medius and minimus considered them as a single mass with one innervation for each muscle and on-off mass action. Functionally, they were defined as hip abductors [13–15].

The present study shows that the gluteus medius and minimus are segmented muscles with a separate innervation for each part. This anatomical configuration suggests a different function for each part rather than a total single muscle action.

Relying on a computer based model, Soderberg and Dostal [10] concluded that for geometrical reasons there are three segments to the gluteus medius muscle. They confirmed their conclusion electromyographically. They found that the gluteus medius was active in the stance phase and that the three parts of the muscle fire sequentially. The posterior part fired first at the beginning of the stance phase (heel strike) and continued until the point of

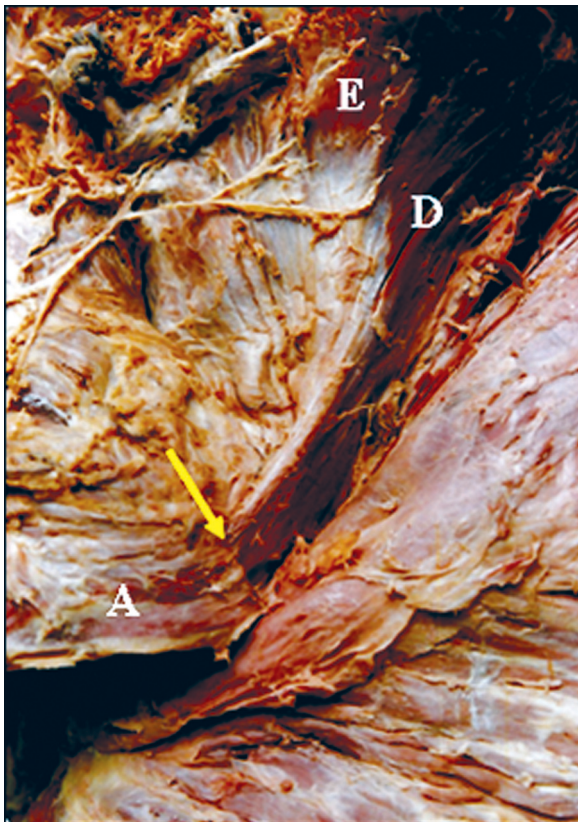


Figure 5. A photograph showing the two parts of the gluteus minimus: anterior part (D) and posterior part (E). Notice that the anterior part has vertically arranged fibres which blend with those of the anterior part of the gluteus medius (A), sharing a common insertion (arrow).

toe-off. The anterior part showed maximum activity during the stance and single support phase. These results confirmed the segmental and phasic function of the gluteus medius.

According to the results of the present study, it is believed that the primary function of the posterior parts of the gluteus medius and minimus, being parallel to the neck of the femur, would be stabilization of the femoral head in the acetabulum during the different stages of the gait cycle (Fig. 4). Similarly, Mairead et al. [16] mentioned that the insertion and orientation of gluteus medius support its primary role as a hip stabilizer, rotator, and abductor. The gluteus medius tendon has two distinct insertion sites on the greater trochanter: the lateral facet and the superoposterior facet [17].

The direction of the fibres of the anterior and middle parts of the gluteus medius and the anterior part of the gluteus minimus suggests that they have vertical pull and initiate abduction, which is then completed by the tensor fasciae latae.

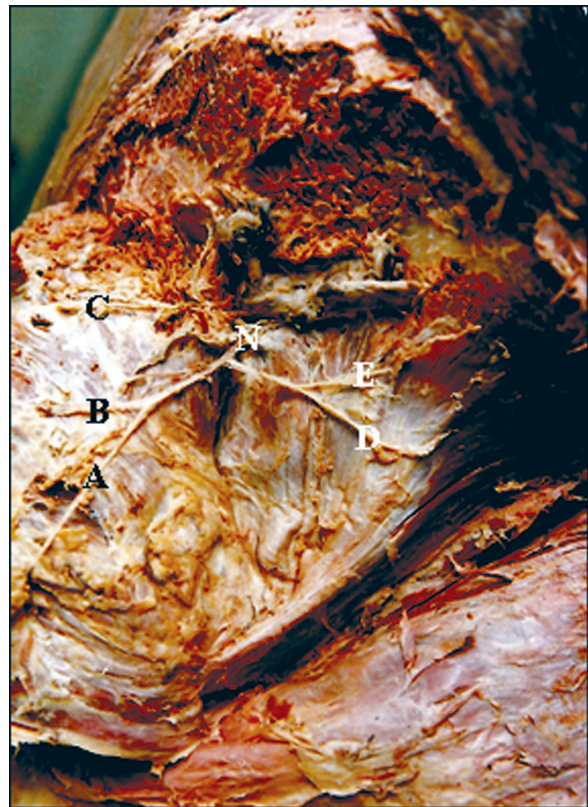


Figure 6. A photograph showing the inferior division of the superior gluteal nerve (N). Notice that it gives three branches for the three parts of the gluteus medius (A–C) and two branches for the gluteus minimus (D, E).



Figure 7. A photograph showing the three branches (A–C) of the inferior division of the superior gluteal nerve for the three parts of the gluteus medius through their deep aspects. Notice that the branch to the posterior part (C) arises in the greater sciatic foramen.

Soderberg and Dostal [10] demonstrated that the increase in the activity of the anterior parts of the gluteus medius from the mid-stance, which is coincident with the initiation of pelvic rotation, suggested that it is the primary pelvic rotator.

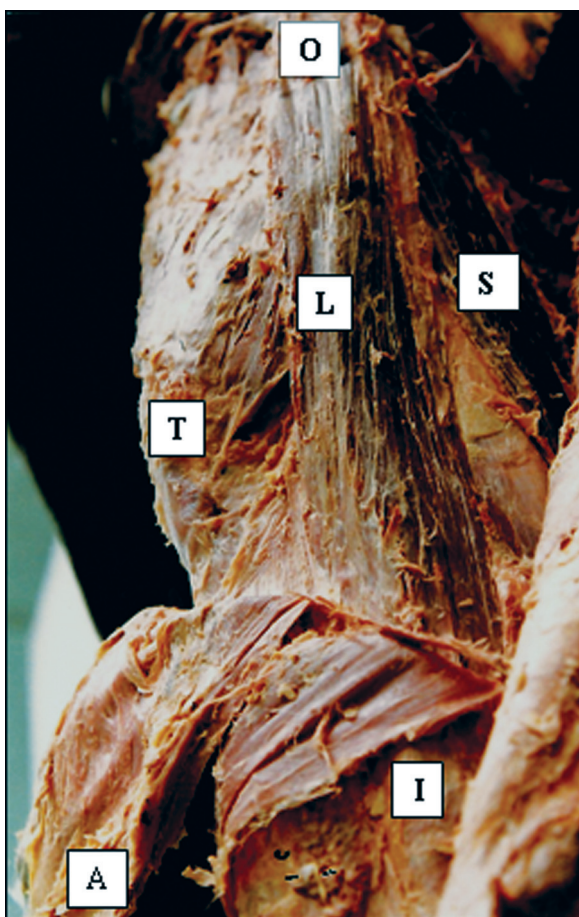

Figure 8. A photograph of the tensor fasciae latae muscle (L) showing its attachment to the outer lip of the iliac crest (O). Notice that it is attached to the iliotibial tract (I) below and in front of the greater trochanter (T). Part of the sartorius muscle (S) can be seen.

Kaplan [18] and Markhede and Steves [19], on a mechanical basis, considered the tensor fasciae latae muscle as the major muscle that counter-balances the force of the body weight during the stance phase of the gait cycle

Evans [7] stated, “the iliotibial tract helps the gluteal abductors to prevent the Trendelenburg gait”. He quoted a case of release of the iliotibial tract, to treat trochanteric bursitis, which resulted in a positive Trendelenburg gait and sign.

He added that the results obtained with the long-tried Ober test for an abduction contracture of the fasciae latae are additional proof that the major hip abductor is the tensor fasciae latae.

By resolving the line of action of the tensor fasciae latae muscle, in the present work, it was found to be parallel and anterior to the mechanical axis of the femur that extends from the centre of the head of the femur to the midpoint of a line connecting the femoral epicondyles (Fig. 9). This arrangement

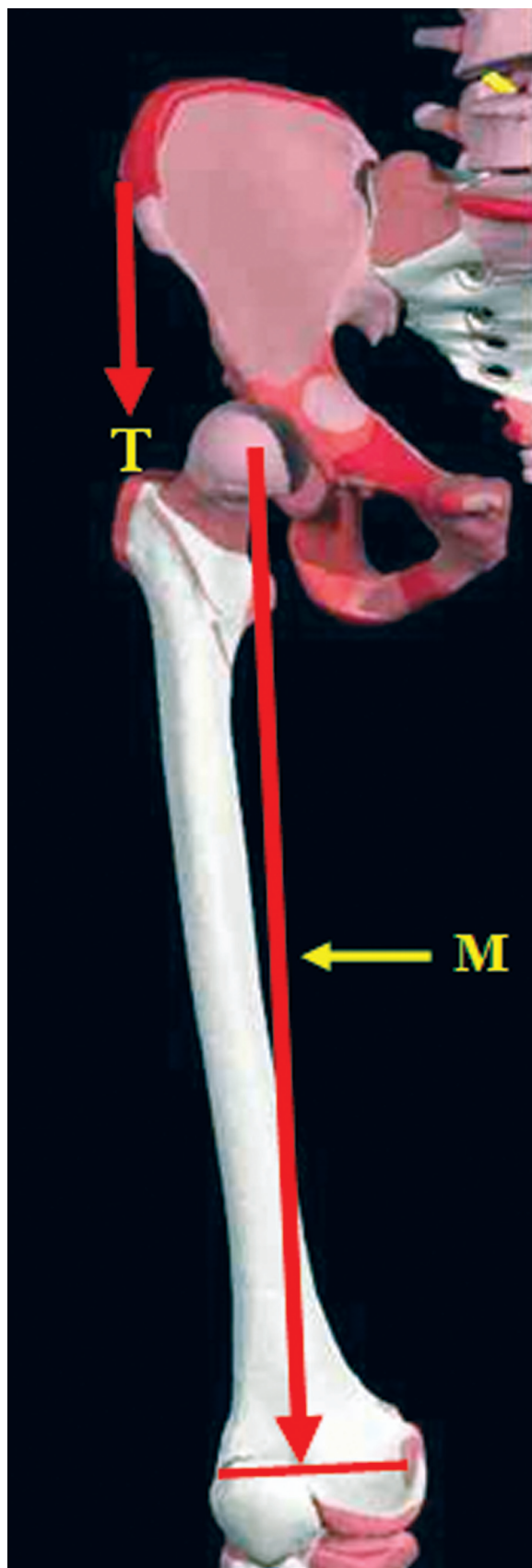


Figure 9. An anterior projection of the line of action of the tensor fasciae latae muscle (T). Notice that it is parallel to the mechanical axis of the femur (M).

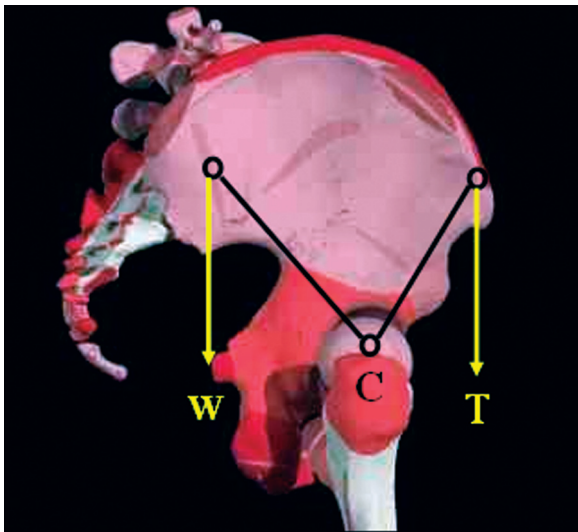


Figure 10. A lateral projection of the line of action of the tensor fasciae latae muscle (T). Notice that it counterbalances the line of force of body weight (W) at the centre of rotation of the hip (C).

would help the muscle to fix the hip and femur together during the stance phase.

In addition, the line of pull of the muscle, being anterior to the hip joint, would counteract the body weight during the standing position (Fig. 10).

The action of the tensor fasciae latae muscle might explain the positive Trendelenburg test after the release of the iliotibial tract. Knowledge of the direction of the fibres of the gluteus medius and minimus muscles as well as tensor fasciae latae muscle is essential in total hip replacement. Inappropriate hip reconstruction might lead to Coxa valga, as in individuals suffering from paralysis of hip abductors or from congenital dislocation of the hip [8].

CONCLUSIONS

The gluteus medius is divided into three different parts and the gluteus minimus is divided into two separate parts. Each part of these two muscles has its separate branch from the superior gluteal nerve. The fibres of the posterior part of the gluteus medius, being parallel to the neck of the femur, are supposed to stabilize the hip joint.

The line of action of the tensor fasciae latae muscle is parallel to both the line of the body weight and the axis of the femur, and is believed to stabilize the body weight and the hip joint.

REFERENCES

1. Crowninshield RD, Johnston RC, Andrews JG, Brand RA (1978) A biomechanical investigation of the human hip. *J Biomech*, 11: 75–85.
2. Borja F, Latta LL, Stinchfield FE, Oberon L (1985) Abductor muscle performance in total hip arthroplasty with and without trochanteric osteotomy. *Clin Orthop Relat Res*, 197: 181–190.
3. Chaganti, RK, Kelman, A, Lui L, Yao L (2008) Change in serum measurements of cartilage oligomeric matrix protein and association with the development and worsening of radiographic hip osteoarthritis. *Osteoarthritis Cartilage*, 16: 566–575.
4. Clark JM, Haynor DR (1987) Anatomy of the abductor muscles of the hip as studied by computed tomography. *J Bone Joint Surg Am*, 69: 1021–1031.
5. Dostal WF, Andrews JG (1981) A three-dimensional biomechanical model of the hip musculature. *J Biomech*, 14: 803–812.
6. Dostal WF, Soderberg GL, Andrews JG (1986) Actions of hip muscles. *Phys Ther*, 66: 351–361.
7. Evans P (1979) The postural function of the iliotibial tract. *Ann R Coll Surg Engl*, 61: 271–279.
8. Inman VT (1947) Functional aspects of the abductor muscles of hip. *J Bone Joint Surg*, 29: 607–619.
9. Jensen RH, Davy DT (1975) An investigation of muscle line of action about the hip: a centroid line approach vs. the straight line approach. *J Biomech*, 8: 103–110.
10. Soderberg GL, Dostal WF (1987) Electromyographic study of the three parts of the gluteus medius muscle during functional activities. *Phys Ther*, 8: 691–696.
11. Lyons K, Perry J, Barnes L, Antonelli D (1983) Timing and relative intensity of hip extensor and abductor muscle action during level and stair ambulation. *Phys Ther*, 63: 1597–1605.
12. Wilson GL, Capen EK, Stubbs NB (1976) A fine wire Electromyographic investigation of the gluteus minimus and gluteus medius muscles. *Resear*, 7: 824–828.
13. Moore KL, Dalley AF (2006) Clinically oriented anatomy. 5th Ed. Lippincott Williams & Wilkins, Philadelphia, Baltimore, New York, London, Buenos Aires, Hong Kong, Sydney, Tokyo, pp. 609–612.
14. Snell RS (1993) Clinical anatomy. 7th Ed. Lippincott & Wilkins, Philadelphia, Baltimore, New York, London, Buenos Aires, Hong Kong, Sydney, Tokyo, p. 609.
15. Standring S, Ellias H, Healy JC, Johnson D, Williams A (2005) Gray's anatomy. 39th Ed. Elsevier Churchill Livingstone, Edinburgh, London, New York, Oxford, Philadelphia, St. Louis, Sydney, Toronto, pp. 1449–1450.
16. Mairead C, Kieran OS, Stephen E (2006) Anatomy and dimensions of the gluteus medius tendon insertion. *Physical Therapy Sport*, 7: 176–178.
17. William JR, Michael JG, Joseph UB, Sreevathsa B, Dean GL, Bryan TK (2008) Anatomy and dimensions of the gluteus medius tendon insertion. *Arthroscopy. J Arthroscopic Related Surg*, 24: 130–136.
18. Kaplan E (1958) The iliotibial tract. *J Bone Joint Surg*, 40A: 817–832.
19. Markhede G, Steves B (1981) Function after removal of various hip and thigh muscles for extirpation of tumors. *Acta Orthopædica Scandinavia*, 52: 373–395.