

Excavated type of rhomboid fossa of the clavicle: a radiological study

G. Paraskevas^{1, 2}, K. Natsis², S. Spanidou², A. Tzaveas¹, P. Kitsoulis², A. Raikos², B. Papaziogas², N. Anastasopoulos

¹Department of Orthopaedics, Hospital "Panagia", Thessaloniki, Greece

²Department of Anatomy, Medical Faculty of Aristotle University of Thessaloniki, Greece

[Received 25 May 2009; Accepted 17 July 2009]

The excavated type of rhomboid fossa of the clavicle is a relatively neglected anatomical structure that can potentially cause diagnostic problems. Its unilateral occurrence may be confused by the physician as avascular necrosis, osteomyelitis, or even a tumour. We studied 80 routine chest radiographs and identified the clavicles with excavated type of rhomboid fossa. The sex, sidedness, and handedness were recorded. An excavated type of rhomboid fossa was present in 43 clavicles (26.88%), appearing more frequently in males than in females. In addition, the incidence of the excavated type of rhomboid fossa was greater on the right side than on the left. That type of fossa was also present more frequently on the right side in right-handed specimens and on the left side in left-handed specimens. The high incidence of the excavated type of rhomboid fossa on the dominant hand supports the mechanical theory of fossa formation. Radiologists and physicians should be aware of this fossa, as it may resemble a pathological condition. (Folia Morphol 2009; 68, 3: 163–166)

Key words: clavicle, rhomboid fossa, excavated type

INTRODUCTION

The area of the inferior surface of the sternal end of the clavicle, in which the powerful costoclavicular or rhomboid ligament is attached, is termed as "impression for costoclavicular ligament" [16]. The relative term provided by the first edition of *Nomina Anatomica*, known as *Basle Nomina Anatomica*, was "tuberositas costalis" [3]. As already established in official anatomical literature, confusion exists regarding the terminology of this anatomical structure. Many authors who have studied this clavicular area refer to this structure using the term "rhomboid fossa", a term derived from the rhomboid ligament attached to it [6, 7, 15].

Although modern anatomy textbooks describe the costoclavicular area as a roughened oval impression [8, 9], classical anatomists, such as Williams et

al. [18] refer to it as a smooth raised eminence. It is obvious that the official anatomical term of *Nomina Anatomica*, as well as the clinical anatomical term "rhomboid fossa", does not fully describe the morphology of the costoclavicular area of the inferior surface of the sternal end of the clavicle.

In some cases of plain chest radiographs, and particularly in cases of the unilateral presence of rhomboid fossa, the latter is seen as a concave osteolytic defect that could be mistaken as evidence of infection, necrosis, or even a neoplasm [1, 11, 13]. In an attempt to resolve the topic, we scrambled patients of known sex and handedness in order to record the incidence of the excavated type of rhomboid fossa of clavicle by sex and side, as well as the side incidence in accordance to handedness.

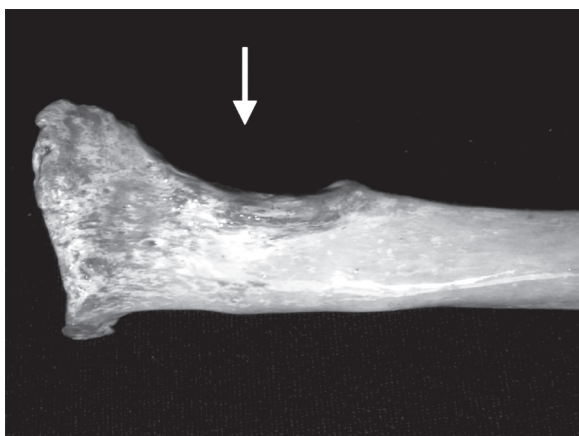

Figure 1. Excavated type of rhomboid fossa (arrow) of the inferior surface of the sternal end of the clavicle, as seen in a macerated bone.

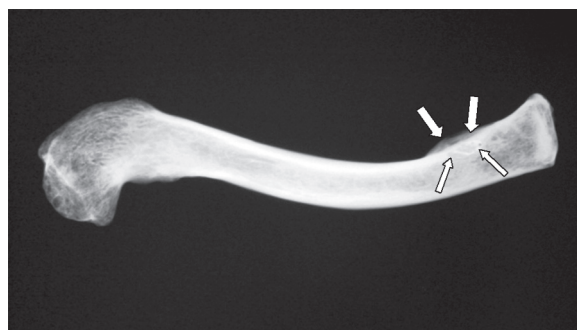


Figure 2. Specimen radiograph. An ovoid area of lucency (arrow) is seen. This area corresponds to the described excavated type of rhomboid fossa.

MATERIAL AND METHODS

Our material consisted of routine roentgenograms of the chest obtained from 80 patients of Caucasian race derived from the Orthopaedic Department of "Panagia" Hospital, Thessaloniki, Greece. We examined the inferior surface of the sternal end of the clavicle on each side in patients of known sex and handedness, in order to record the so-called excavated type of rhomboid fossa of the clavicle (Fig. 1). We recorded the presence of the excavated type of rhomboid fossa, regardless of its depth and length, as an excavation seen at the inferior surface of the sternal end of the clavicle, using two independent investigators to rule out the possibility of error in determining the exact morphology of the excavation. On plain radiographs, these excavations seem like ovoid or circular concave defects characterized by radiolucency. In addition, the magnitudes of sex, handedness, and side differences were estimated by applying a simple χ^2 test. The level of statistical significance was set at $p < 0.05$.

RESULTS

A total of 43 clavicles with a circular or ovoid osteolytic defect or irregularity were found (Fig. 2). The incidence of the excavated type of rhomboid fossa with regard to the total number of the clavicles (160) was 28.88%, while the incidence for the flat-type and tuberosity type was 58.12% and 15%, respectively. The bilateral occurrence of the excavated type of rhomboid fossa with respect to the total number of paired clavicles was found to be 7.5% and 3.75% in males and females, respectively. Concerning the unilateral cases of excavated type of rhomboid fossa,

Table 1. Incidence of rhomboid fossa. The number and the percentages correspond to the total number of paired clavicles

	Males* (%)	Females* (%)
Bilateral fossa	6 (7.5)	3 (3.75)
Unilateral fossa		
Right**	11 (13.75)	6 (7.5)
Left**	5 (6.25)	3 (3.75)
Absence of fossa bilaterally	20 (25)	26 (32.5)
Total	42	38

* $p < 0.005$ (males versus females); ** $p < 0.005$ (right versus left)

we recorded an incidence of 20% and 11.25% in males and females, respectively. The sexual difference in both cases of bilateral and unilateral excavated type of rhomboid fossa was significant ($p < 0.005$) with dominance of that type of fossa in males.

Furthermore, it has been shown that the incidence of excavated type of rhomboid fossa was greater on the right than on the left side in both male and female specimens ($p < 0.005$) (Table 1). In Table 2 it is obvious that the excavated type of rhomboid fossa are more frequently found on the right side in right-handed specimens and on the left side in left-handed specimens ($p < 0.005$).

DISCUSSION

The costoclavicular ligament that is attached to the rhomboid fossa of the clavicle was described very early on as consisting of only one plane of fibres [5], while the first official statement of the bilaminar nature of the ligament was by Poirier [12], who mentioned that the anterior and posterior

Table 2. Distribution of right and left unilateral rhomboid fossae with respect to handedness. The percentages estimated with respect to the total number of right or left unilateral fossae to each gender

	Right-handed (%)	Left-handed (%)	Level of significance (p)
Males			
Right	10 (90.91)	1 (9.09)	< 0.05*
Left	1 (20)	4 (80)	< 0.05**
Females			
Right	5 (83.33)	1 (16.67)	< 0.05*
Left	1 (33.33)	2 (66.67)	< 0.05**

*p (right-handed versus left-handed); **p (left-handed versus right-handed)

fibre layers inclined upwards and outwards. The costoclavicular ligament exists only in apes and humans and limits horizontal and vertical clavicle movements [17].

There are fatigue reports in relation to the exact nature of the costoclavicular area of the clavicle. A long time ago, Poirier [12] mentioned that this area most commonly has the form of a rough oval eminence, although sometimes it has the form of an oval fossette, and is sometimes poorly marked. Parsons [10] observed the presence of the excavated type of rhomboid fossa in only 10% in a sample of 183 adult English clavicles, and Cave [4] found the costoclavicular area of the clavicle to be depressed in 29.1%, elevated in 11.1%, and flat in 60.78% in a sample of 153 adult macerated clavicles. In our radiological study, we found the existence of a markedly deep impression at the costoclavicular area location in 26.88% of clavicles. Furthermore, flat type and tuberosity-type costoclavicular-areas were found in 58.12% and 15%, respectively. In contrast, Srivastava et al. [15] found the rhomboid fossa to be present in 95.7% of instances, Longia et al. [7] in 90%, and Jit et al. [6], in a greater and better-classified sample, found the incidence to be approximately 70%. All the above-mentioned frequencies with the relative high incidences of the fossa concern exclusively Indian populations. Moreover, these authors included all three types of fossae: elevated, flat, and deep excavated, under the term "rhomboid fossa".

Ajello [2] in 7000 "photofluorograms" found the incidence of excavated-type rhomboid fossa to be only 0.129%. Shauffer et al. [14] in 10 000 "photofluorograms" detected significant excavated-type rhomboid fossa in 0.2% of cases bilaterally and 0.3% (right) and 0.09% (left) unilaterally. The previously-mentioned authors reported a greater incidence of

excavated type of rhomboid fossa in males than in females. In addition, they found that these fossa occur more frequently on the right than on the left side. The low incidence of these fossa seen in roentgenograms compared to that seen in dried bones is due to the fact that the position of the clavicles in chest radiographs is extremely variable, a fact that could prevent fossa appearance in radiographs. So, the identification of excavated type of rhomboid fossa becomes quite difficult. For that reason, we used two independent investigators for the detection of even a slightly excavated type of rhomboid fossa. This presumably explains the relatively high incidence of excavated type of fossa noticed in our study. Furthermore, our findings strongly support Ajello [2] and Shauffer et al. [14] regarding the greater incidence of fossa in males than in females, and on the right than on the left side.

Our new significant provided data is that the excavated type of fossa were present more frequently on the right side in right-handed specimens and on the left side in left-handed specimens. This is partially supported by the observation of Jit et al. [6] that the rhomboid fossa develops only when a child starts moving the upper limbs freely at the age of about 4 to 5 years. However, Jit et al. [6] could not establish the fact that the excavated type of fossa exists more frequently in males than in females and, in particular, could not correlate the presence of these fossae with the handedness. According to our knowledge, no such information is provided in the relative literature. That data empowers the mechanical theory of fossa formation due to applied pressure by the costoclavicular ligament. Obviously, further investigation is needed in order to answer the query regarding fossa structure and the reason that an elevation is not formed.

The high incidence of the excavated type of rhomboid fossa on the dominant hand supports the mechanical theory of fossa formation. The unilateral location of an excavated type of rhomboid fossa may cause problems to physicians as well as to radiologists, since such an ovoid osteolytic defect may accidentally be seen as osteomyelitis, necrosis, or a tumour. The presence of an ovoid or circular osteolytic defect with smooth margins at the inferior surface of the sternal end of the clavicle, as well as the absence of clinical signs from the relative clavicular site, could bring to the physician's mind a possible diagnosis of an excavated type of rhomboid fossa.

REFERENCES

1. Agarwal GR, Khatri OP (1974) Deep clavicular rhomboid fossa. *Indian J Radiol*, 28: 193–194.
2. Ajello A (1957) L' incisura rhomboidea della clavicola. *Ann Med. Nav Trop*, 62: 458–460.
3. Basle Nomina Anatomica (1895) *Die Anatomische Nomenklatur*. Verlag von Veit, Leipzig.
4. Cave AJE (1961) The nature and morphology of the costoclavicular ligament. *J Anat*, 95: 170–179.
5. Gray H (1858) *Anatomy, descriptive and surgical*. Parker, London.
6. Jit I, Kaur H (1986) Rhomboid fossa in the clavicles of North Indians. *Am J Phys Anthropol*, 70: 97–103.
7. Longia GS, Agarwal AK, Thomas RJ, Jain PN, Saxena SK (1982) Metrical study of rhomboid fossa of clavicle. *Anthropol Anz*, 40: 111–115.
8. McMinn R (1990) *Last's anatomy, regional and applied*. 8th Ed. Churchill Livingstone, Edinburgh.
9. Moore K, Dalley A (1999) *Clinically oriented anatomy*. 4th Ed. Lippincott, Williams and Wilkins, Philadelphia.
10. Parsons FG (1916) On the proportions and characteristics of the modern English clavicle. *J Anat*, 51: 71–93.
11. Perry RE, Lipscaub PR, Anzel SH (1959) Pathologic fracture of the clavicle after biopsy of the rhomboid depression. *Proc Mayo Clin*, 34: 563–564.
12. Poirier P (1890) La clavicule et ses articulations. *J Anat Paris*, 26: 81–103.
13. Rogers LF (1992) *Radiology of skeletal trauma*. Churchill Livingstone, New York.
14. Shauffer IA, Collings WV (1966) The deep clavicular rhomboid fossa. *J Am Med Assoc*, 195: 158–159.
15. Srivastava U, Bahl I, Kaul M, Garg G, Barry K (1977) Rhomboid fossa: an anatomical study. *Indian J Radiol*, 31: 209–210.
16. *Terminologica (Nomina) Anatomica* (1998) *International anatomical terminology*. 7th Ed. Theme, Stuttgart.
17. Voisin JL (2006) Clavicle, a neglected bone: morphology and relation to arm movements and shoulder architecture in primates. *Anat Rec*, 288A: 9440953.
18. Williams PL, Warwick R (1980) *Gray's anatomy*. 36th Ed. Churchill Livingstone, Edinburgh.