

Myocardial bridging and coronary artery anomalies detected by ECG-gated 64-row multidetector computed tomography angiography in symptomatic patients

R. Javadrashid¹, M.K. Tarzamni¹, N. Aslanabadi², M. Ghaffari², A. Salehi¹, K. Sorteji¹

¹Department of Radiology, Tabriz University of Medical Sciences, Tabriz, Iran

²Department of Cardiology, Tabriz University of Medical Sciences, Tabriz, Iran

[Received 20 May 2009; Accepted 2 August 2009]

Advances in 64-row multidetector computed tomography have provided non-invasive imaging of coronary arteries. The aim of this study was to evaluate the prevalence of coronary artery anomalies in Iranian symptomatic patients and to determine the presence of anomalies resulting in myocardial ischaemia without atherosclerotic plaque.

This study was carried out in Tabriz University of medical sciences on 534 patients with suggestive symptoms for coronary artery diseases. Original slices were reconstructed from data achieved by using a ECG-gated multidetector computed tomography scanner, and reconstructed 3-dimensional images of the heart were reviewed. Congenital angiography was performed in 36.3% of patients. The prevalence of myocardial bridging in symptomatic patients was 6.0% by multidetector computed tomography while conventional angiography could detect 20% of them. The most prevalent site was the middle portion of the left anterior descending artery. Anomalous origin or course of coronary arteries and AV fistula was detected by multidetector computed tomography coronary angiography in 2.6% of cases while conventional angiography could detect 44.4% of these anomalies. The prevalence of atherosclerotic plaques in patients with myocardial bridging was 53.1%. In 46.9% of these patients, myocardial bridging was held responsible for signs and symptoms of myocardial ischaemia as no atherosclerotic plaque was evident. This rate was 64.3% in symptomatic patients with other anomalies in origin or course of coronary arteries. This study gives the prevalence of coronary artery anomalies and myocardial bridging in the Iranian population. The results suggest multidetector computed tomography coronary angiography as the preferred utility for diagnosing such anomalies. (Folia Morphol 2009; 68, 4: 201–206)

Key words: coronary artery anomaly, myocardial bridging, multidetector computed tomography angiography, epidemiology

INTRODUCTION

Coronary artery anomalies (CAAs) are a group of congenital disorders interfering with coronary artery function, which are associated with myocardial ischaemia. Coronary arteries of anomalous origination from the opposite sinus form a subgroup of CAAs with the highest probability of developing a myocardial ischaemia and sudden death in young individuals [7].

Myocardial bridging (MB) is a segment of a major epicardial coronary artery encased by the myocardium, in which the systolic compression and delayed diastolic relaxation can cause ischaemia. Diagnosing the existence of MB and CAAs is important especially in young patients with cardiac chest pain or arrhythmia, in the absence of any risks for atherosclerosis [1, 2, 5, 8, 10, 11].

The assessment of coronary arteries is possible using several techniques including conventional angiography, intravascular sonography and intracoronary Doppler sonography, echocardiography, magnetic resonance imaging, electron beam tomography, and multidetector computed tomography (MDCT) coronary angiography. MDCT angiography, as a fast and noninvasive method, has multiplanar reconstruction imaging capabilities and, with a higher accuracy and reliability and ongoing development in recent times, has become the first choice imaging modality for the evaluation of coronary arteries [2, 6, 8, 10, 14].

The foremost aim of this study was to evaluate the prevalence of MB and other CAAs in symptomatic patients examined with both 64-row MDCT coronary angiography and conventional angiography, and then to determine the presence of CAAs or MB resulting in myocardial ischaemia in the absence of coronary atherosclerotic plaque. To the best of our knowledge, this is the first report regarding the Iranian population.

MATERIAL AND METHODS

This study was carried out in the MDCT Angiography Centre of Tabriz Medical University located in Imam Khomeini Hospital. It included 534 patients who had atypical chest pain or suggestive symptoms for coronary artery disease. Most of the patients had one or more risk factors for coronary artery disease, such as family history, smoking, hypertension, diabetes mellitus, or hyperlipidaemia.

All MDCT evaluations were preceded by a consultation with our cardiology colleagues. Patients with sinus rhythm and heart rate ≥ 70 beats/min

received one dose of atenolol (25–50 mg/oral) to decrease the heart rate 1 hour before, and nitroglycerin (5 mg/sublingual) 1 minute before, the scan to dilate the coronary arteries.

In one breath-hold during the inspiration, scanning was performed along with injection of a non-ionic contrast agent (Ultravist, concentration: 300 mg/mL, flow rate: 5 mL/s, total volume 80 mL) followed by a saline bolus (40–70 mL at 4–6 mL/s) through a 20 or 22 G intravenous catheter in the patient's arm. Each scan lasted for 16–24 s. Radiation dose was 100–140 mAs for patients weighing > 55 kg and 100–120 kV for patients weighing ≥ 45 kg.

The MDCT examinations were performed in our institution using a multidetector scanner (Somatom Sensation 64; Siemens medical solutions, Forchheim, Germany). Original 0.6 mm axial slices were reconstructed from data recorded by an ECG-gated MDCT scanner in 2-dimensional sagittal, coronal, and oblique planes using MIP, MRP, and CPR techniques. Furthermore, volume-rendering by VRT, inspace, and vessel view was performed. Source image data sets were loaded to reconstruct axial scans, double oblique, curved multiplanar reformat, and 3-dimensional volume-rendered (3D VR) images on an on-line workstation (Wizard, Siemens medical solutions, Erlangen, Germany). The reconstructed 3-dimensional images of the heart were then reviewed for each patient.

From the total of 534 patients, 194 underwent conventional coronary angiography as well. An atypical chest-pain syndrome was the most common reason.

Computed tomography coronary angiographic images were evaluated by two radiologists who were blinded to the clinical data, and conventional coronary angiograms were reviewed by a radiologist and a cardiologist, independently. MB was distinguished by milking effect and step-down-step-up phenomenon on MDCT images while systolic compression in the tunnelled artery was its marker during the angiography.

The number, length, and course of bridged coronary segments and evidence of simultaneous plaques proximal and within the intramuscular segment were evaluated.

RESULTS

The age of the study population ranged from 14 to 84 years (mean age \pm SD): 55.4 ± 11.6 years. From a total of 534 patients, 64.4% were male (mean age \pm SD): 55 ± 11.9 , and 35.6% were female (mean age \pm SD): 55.7 ± 11.4 .

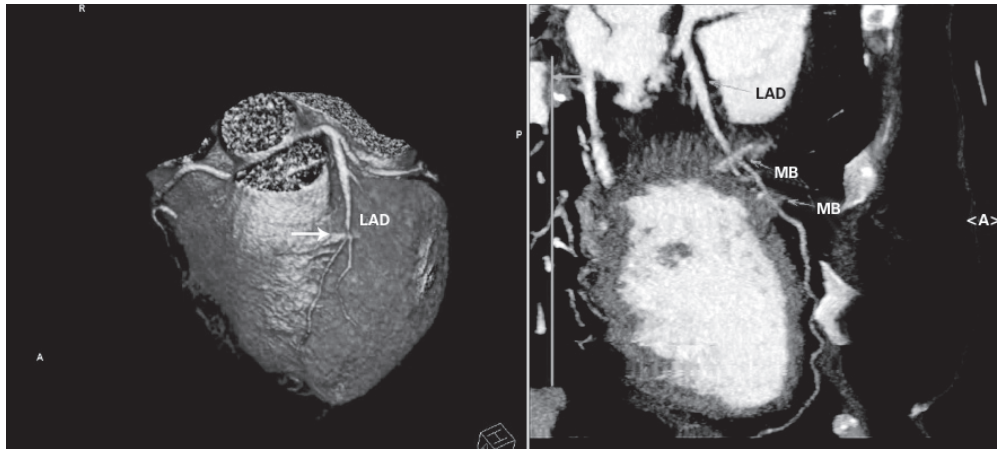


Figure 1. Curved maximum intensity and volume-rendered images show muscle bridge of left anterior descending (LAD) artery; MB — myocardial bridging.

Table 1. Location of myocardial bridging in the study population detected by multidetector computed tomography coronary angiography.

		Total	Male	Female
Left anterior descending	Proximal third	1 (0.2%)	1	0
	Middle third	22 (4.1%)	13	9
	Distal third	6 (1.1%)	3	3
Accessory or secondary branches		3 (0.6%)	0	3
Total		32 (6.0%)	17	15

MDCT coronary angiography revealed 32 patients (6.0%) to have MB (Fig. 1). This included 17 males (mean age \pm SD): 57.5 ± 9.6 , and 15 (2.8%) females (mean age \pm SD): 52.3 ± 11.2 . The difference between the two genders was not significant. The locations of MBs are described in Table 1.

Conventional coronary angiography could detect only four cases of MB (out of 194 patients), which were all identified by MDCT coronary angiography as well. Thus, conventional angiography could detect only 20% of myocardial bridges which were diagnosed by MDCT. All four cases were located at the middle portion of the left anterior descending (LAD) artery, and one was associated with anomalous origination of the left circumflex (LCx) artery from the right coronary cusp.

Anomalous origin or course of coronary arteries and atrio-ventricular (AV) fistula was detected by MDCT coronary angiography in 14 patients (2.6%), including 10 (1.8%) males (mean ages \pm SD): 49.2 ± 17.2 years and 4 (0.7%) females (mean age \pm SD): 46.5 ± 7.1 years. Nine of these patients were among the group of patients undergoing conventional an-

giography, and it could detect CAA in four patients giving a prevalence rate of 2.1%. Accordingly, conventional angiography could detect 44.4% of CAAs. Table 2 describes anomalous origin or course of coronary arteries. One of the patients with an AV fistula had a ramous branch arising from the distal part of the left main artery with two branches (anterior and posterior), both had long segment of myocardial bridging and crossed coronary vein in their path.

The prevalence of atherosclerotic plaques in patients with MB was 53.1% while 15 patients with MB (46.9%) experienced signs, symptoms, and ECG patterns of ischaemic heart disease while no atherosclerotic plaques were evident. This included 4 males (mean ages \pm SD): 46.3 ± 2.4 years and 11 females (mean age \pm SD): 53.1 ± 9.4 years. MDCT coronary angiography missed one, detecting the plaque in one patient.

Atherosclerotic plaques were obvious in 35.7% of patients with other CAAs. Therefore, CAAs were held responsible for symptoms in 9 (64.3%) symptomatic patients with no atherosclerotic plaques, including 6 males (mean ages \pm SD): 39.2 ± 14.6

Table 2. Description of coronary artery anomalies detected by multidetector computed tomography coronary angiography detected in 14 symptomatic patients (more than one anomaly was reported in some patients)

	Male (%)	Female (%)	Total (%)
LCx originateing from right sinus of Valsalva (Fig. 2)	2 (0.4)	1 (0.2)	3 (0.6)
LAD and LCx with two separate origins from aorta	1 (0.2)*	–	1 (0.2)
LAD originating from LCC	1 (0.2)	–	1 (0.2)
LAD originating from right coronary sinus	2 (0.4)	1 (0.2)	3 (0.6)
LM originating from right coronary sinus (Fig. 3)	2 (0.4)	1 (0.2)*	3 (0.6)
RCA originating from left coronary cusp (Fig. 4)	2 (0.4)	–	2 (0.4)
Atrioventricular fistula	–	2 (0.4)*	2 (0.4)

LAD — left anterior descending artery; LCx — left circumflex artery; LCC — left coronary cusp; LM — left main artery; RCA — right coronary artery; *undetactable by conventional angiography

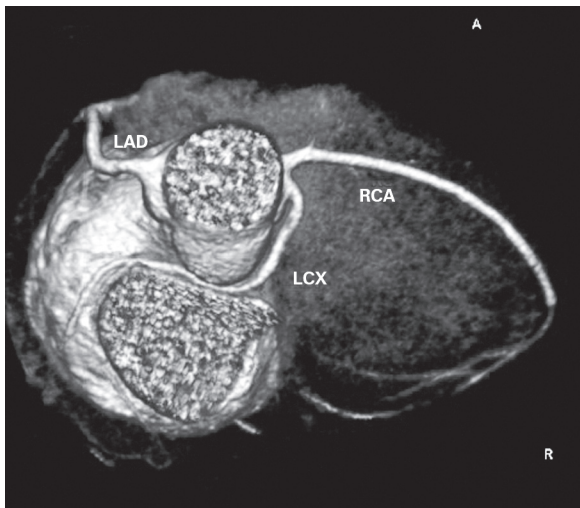

Figure 2. Volume-rendered image shows abnormal origin of left circumflex (LCx) artery from right coronary cusp; LAD — left anterior descending; RCA — right coronary artery.

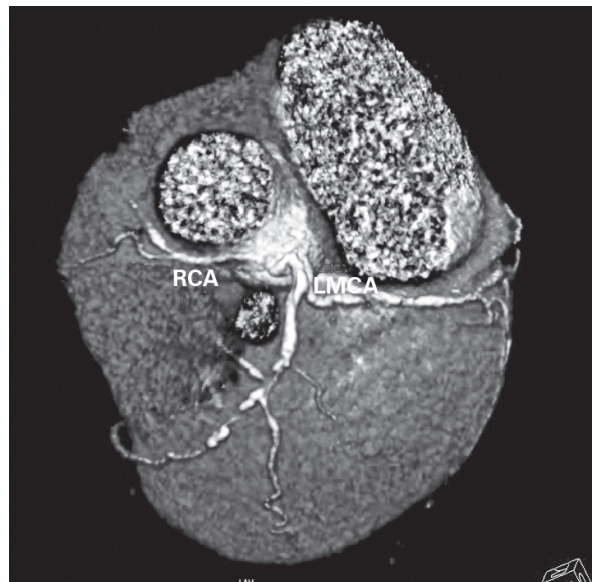


Figure 4. Volume-rendered image shows abnormal origin of right coronary artery (RCA) from left coronary cusp; LMCA — left main coronary artery

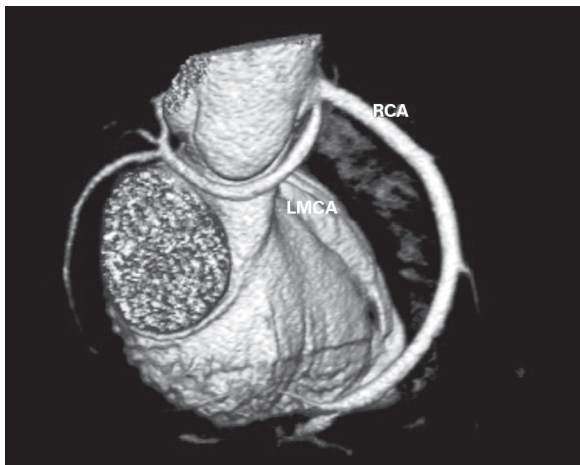


Figure 3. Volume-rendered image shows abnormal origin of left main coronary artery (LMCA) from right coronary cusp; RCA — right coronary artery.

years and 3 females (mean ages \pm SD): 44.7 ± 7.5 years. Conventional and MDCT angiography were compatible in all of the patients with CAA regarding detection of these plaques. The difference between the mean age of symptomatic patients with or without sclerotic plaques did not reach the level of significance.

DISCUSSION

This study evaluated symptomatic patients with suspected coronary artery diseases and reported a prevalence rate of 6.0% for myocardial bridging and 2.6% for other CAAs, with the advantage of using ECG-gated 64-row MDCT angiography. A fur-

ther finding was a considerable number of symptomatic patients with CAAs without atherosclerotic plaques.

In the presence of myocardial bridging, ischaemia may occur with each systole and diastole and is associated with angina, arrhythmia, depressed left ventricular function, myocardial stunning, early death after cardiac transplantation, and sudden death [8]. Myocardial bridging is usually labelled as a congenital anomaly [2], but its prevalence of approximately 1% [3] in the general population and 5% [12] in symptomatic patients (and 6% in the current study) suggests that it is a probable normal variant and only severe types may be counted as pathological anomalies [3, 8]. The rate is even higher in patients with hypertrophic cardiomyopathy and is reported to be as high as 30% [2, 8]. Studies on human cadavers report the rate to be more than 40% and to be located mostly above the anterior interventricular branch of the left coronary artery [4, 13]. There is no similar report from our population, but such studies confirm the high prevalence of MB and the value of diagnosing it in symptomatic patients, as will be discussed subsequently.

The variety in location, depth, and length of myocardial bridging interferes with its diagnosis by angiography in addition to its administrator dependent nature. Concurrent atherosclerotic changes, which are seen mostly in the proximal segment, can interfere with diagnosis of myocardial bridging [2, 8]. Thus, conventional coronary angiography may only reveal the deep type of bridges and sufficiently compressed coronary artery segments [2, 10]. On the other hand, conventional angiography has the advantage of balloon angioplasty or a stent placement.

The current study utilized an improved MDCT scanner generation, 64-row computed tomography angiography, which is reported as an alternative fast, noninvasive diagnostic technique with multiplanar reconstruction imaging capabilities. Myocardial bridges were mostly seen on the LAD middle segment, which is compatible with reports from other populations [2, 8, 9]. MDCT allowed the assessment of the coronary artery lumen, coronary stenosis, and simultaneous atherosclerotic plaques. Consequently, the absence of atherosclerotic plaques was noticed in 46% of symptomatic patients with MB, and 64% of patients with CAAs. Typical or atypical chest discomfort in a patient at low risk for coronary atherosclerosis should raise concerns in the physician regarding possible coronary anomaly, especially taking into account its high prevalence.

CAAs are reported to occur in 0.3–1.2% of the general population [6]. Congenital abnormalities associated with myocardial ischaemia include coronary artery fistula, the LAD originating from the pulmonary artery, anomalous origin of the LAD (from the right coronary artery or the right coronary sinus), and anomalous origin of the right coronary artery (from the LAD or the left coronary sinus). The latter anomaly (which was observed in 0.4% of our study sample) is very rare and is of clinical importance because myocardial infarction or sudden death can occur in up to 30% of patients [6, 7]. The most potent CAA for sudden death in young individuals seems to be the anomalous origination of a coronary artery from the opposite sinus, especially the left coronary artery [1, 2, 5, 8]. The observed prevalence rate of this anomaly was similar to other studies [8].

Conventional angiography can detect the path of anomalous coronary arteries, but sometimes it is difficult to perform or interpret, while computed tomography accurately depicts the origin and proximal course [14]. In the current study, 3D VR and multiplanar reconstruction abilities of MDCT prepared high quality data and evaluation of anomalous coronary origin, course, and dependent territory in comparison to conventional angiography: accurate, easy, and non-invasive. The lower estimated rates of CAAs and myocardial bridging on conventional angiography in this study might be related, in part, to the fact that only the deep types of bridges may be apparent on angiography.

CONCLUSIONS

In conclusion, we reported the prevalence of myocardial bridging and CAAs in Iranian symptomatic patients for the first time. The gender distribution of MB in our population is compatible with other reports [4]. A notable proportion of our studied patients with MB (15/32) and CAAs (9/14) had signs and symptoms of ischaemic heart disease without evidence for coronary atherosclerotic changes; therefore, MB must be considered in patients at low risk for coronary atherosclerosis who experience chest discomfort and myocardial ischaemia.

One of the most important steps in the management of patients at risk of sudden cardiac death is detecting structural anatomic cardiac abnormalities [1]. The current study also demonstrated that MDCT as a fast and noninvasive tool for diagnosing coronary MB and CAAs can achieve more accurate data with 3D VR and multiplanar reconstruction abilities.

REFERENCES

1. Albert CM, Mittleman MA, Chae CU, Lee IM, Hennekens CH, Manson JE (2000) Triggering of sudden death from cardiac causes by vigorous exertion. *N Engl J Med*, 343: 1355–1361.
2. Alegria JR, Herrmann J, Holmes DR, Lerman Jr A, Rihal CS (2005) Myocardial bridging. *Eur Heart J*, 26: 1159–1168.
3. Angelini P (2007) Coronary artery anomalies: an entity in search of an identity. *Circulation*, 115: 1296–1305.
4. Ballesteros LE, Ramirez LM (2008) Morphological expression of the left coronary artery: a direct anatomical study. *Folia Morphol*, 2008; 67: 135–142.
5. Bayram E, Kocatürk H, Kantarc M, Fil F, Cengizolak M (2008) Anomalous origin of the right coronary artery arising from the left anterior descending artery in a case with single coronary artery anomaly: multi-detector computer tomography imaging. *Anadolu Kardiyol Derg*, 8: 381–392.
6. Dirksen MS, Bax JJ, Blom NA, Schalij MJ, Jukema WJ, Vliegen HW (2002) Detection of malignant right coronary artery anomaly by multi-slice CT coronary angiography. *Eur Radiol*, 12: 177–180.
7. Engel HJ, Torres C, Page HL (1975) Major variations in anatomical origin of the coronary arteries: angiographic observations in 4250 patients without associated congenital heart disease. *Catheter Cardiovasc Diagn*, 1: 157–169.
8. Hazirolan T, Canyigit M, Karcaaltincaba M, Dagoglu MG, Akata D, Aytemir K, Besim A (2007) Myocardial Bridging on MDCT. *AJR*, 2007; 188: 1074–1080.
9. Ishikawa Y, Akasaka Y, Ito K, Akishima Y, Kimura M, Kiguchi H, Fujimoto A, Ishii T (2006) Significance of anatomical properties of myocardial bridge on atherosclerosis evolution in the left anterior descending coronary artery. *Atherosclerosis*, 186: 380–389.
10. Kantarci M, Duran C, Durur I, Alper F, Onbas O, Gulbaran M, Okur A (2006) Detection of myocardial bridging with ECG-gated MDCT and multiplanar reconstruction. *AJR*, 186: S391–S394.
11. Kawawa Y, Ishikawa Y, Gomi T, Nagamoto M, Terada H, Ishii T, Kohda E (2007) Detection of myocardial bridge and evaluation of its anatomical properties by coronary multi slice spiral computed tomography. *Eur J Radiol*, 61: 130–138.
12. Ko SM, Choi JS, Nam CW, Hur SH (2008) Incidence and clinical significance of myocardial bridging with ECG-gated 16-row MDCT coronary angiography. *Int J Cardiovasc Imag*, 24: 445–452.
13. Kosiński A, Grzybiak M (2001) Myocardial bridges in the human heart: morphological aspects. *Folia Morphol*, 2001; 60: 65–68.
14. Krishnamoorthy A, Venkatesh G, Vijayakumar M, Preeetham K, Ramanathan M. (2008) Diagnosis of anomalous origin of left coronary artery from pulmonary artery in an adult by 64-slice CT angiography. *Indian Heart J*, 60: 366–367.