

# Superficial temporal artery among Kenyans: pattern of branching and its relation to pericranial structures

P. Mwachaka, S. Sinkeet, J. Ogeng'o

Department of Human Anatomy, University of Nairobi, Kenya

[Received 11 September 2009; Accepted 6 November 2009]

*The superficial temporal artery, one of the terminal branches of the external carotid artery, is used for temporoparietal, parieto-occipital flaps and forehead flaps in reconstructive surgery. The topographic anatomy of this artery exhibits ethnic variations. Therefore, this study aimed to determine the branching pattern of the superficial temporal artery and its relation to specified landmarks in the pericranial region among Kenyans. Sixty superficial temporal arteries from thirty adult cadavers (18 male, 12 female), obtained from the Department of Human Anatomy, were examined during dissection. The number of branches and pattern of branching of the superficial temporal artery was recorded. Specific measurements were taken from the branching point to the lateral canthus, tragus, and midpoint of the arch of the zygoma. Classical bifurcation into a parietal and a frontal branch was seen in 16 (53.3%) cases. Double frontal and double parietal branches were reported in 26.7% and 13.3% of cases, respectively. Only two cases had a trifurcation. The point of origin of the branches in most cases (80%) was above the arch of the zygoma. The mean distance to the midpoint of the arch of the zygoma was  $50.8 \pm 20.9$  mm, to the lateral canthus  $58.6 \pm 24.3$  mm, and to the tragus  $44.1 \pm 18.5$  mm. The branching pattern among Kenyans, therefore, differs from the classical descriptions. A good understanding of the forehead vascularity aids in the design of flaps and minimizes postoperative complications. (Folia Morphol 2010; 69, 1: 51–53)*

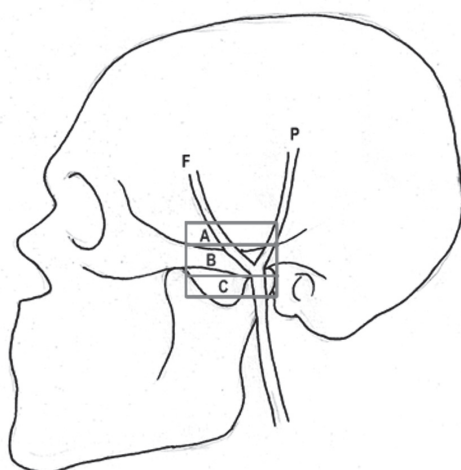
**Key words: superficial temporal artery, Kenyans, reconstructive surgery**

## INTRODUCTION

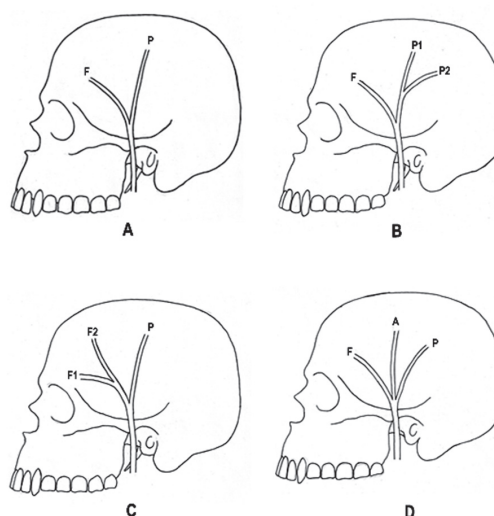
The superficial temporal artery (STA) is one of the terminal branches of the external carotid artery. It begins in the parotid gland behind the mandible and crosses the posterior root of the zygomatic process of the temporal bone [1, 4, 8, 12]. The STA supplies the face and scalp together with some branches of the external carotid artery, usually dividing into an anterior frontal and a posterior parietal branch [5, 11, 14]. Variations include: double parietal

branches, double frontal branches, absence of frontal branch, and absence of parietal branch [10]. The point of origin of the STA branches in relation to the zygomatic arch has also been shown to vary [1, 4, 7, 9].

In reconstructive surgery, three flaps are usually prepared from the STA and its branches i.e. temporoparietal, parieto-occipital, and forehead flaps. These flaps are used for the treatment of baldness and for the recovery of defects of the face and scalp



**Figure 1.** Point of origin of the terminal branches of the superficial temporal artery in relation to the zygomatic arch, above the arch (A), at the arch (B), and below the arch (C); P — parietal branch; F — frontal branch of the superficial temporal artery.



**Figure 2.** Observed branching patterns of the superficial temporal artery; **A.** Classical bifurcation into a parietal (P) and a frontal branch (F); **B.** Double parietal branches (P1 and P2); **C.** Double frontal branches (F1 and F2); **D.** Trifurcation; A — accessory branch.

[3, 6, 9, 15]. In addition, the distance between the STA and tragus is important for designing the preauricular flaps [10]. The STA or its branches are also used as an interposed artery graft for extracranial to intracranial vascular anastomoses [2, 13].

Knowledge of the variations in the course of the STA and its branches is valuable for the evaluation and treatment of certain aesthetic problems, especially those of flap surgery on the lateral forehead region [3, 6, 9, 15]. Previous studies have demonstrated ethnic variations in the branching pattern of the STA as well as its relation to pericranial structures [4, 8]. This study, therefore, aimed at determining the branching pattern of STA and its relation to the tragus, lateral canthus, and zygomatic arch among Kenyans.

### MATERIAL AND METHODS

Thirty formalin-fixed adult cadavers (18 male, 12 female) were examined during routine dissection at the Department of Human Anatomy, University of Nairobi. Soft tissues were removed to expose the STA, which was then traced in reference to the surrounding landmarks, including the tragus, zygomatic arch, and lateral canthus. The branching pattern of the STA was examined and documented. The point of origin of the terminal branches of the STA in relation to the zygomatic arch was noted as being above, at, or below the arch (Fig. 1). When above or below the arch, a ruler was used to measure its distance to the midpoint of the zygomatic arch. Distances from the point of termination of STA to the

tragus and the lateral canthus were also taken. The collected data was analysed using the Statistical Package for Social Sciences 13.0 (Chicago, Illinois).

## RESULTS

### Patterns of branching

Four branching patterns of the superficial temporal artery were observed (Fig. 2). Classical bifurcation into a parietal and a frontal branch was seen in 16 (53.3%) cases. Double frontal and double parietal branches were reported in 8 (26.7%) and 4 (13.3%) cases, respectively. Only two cases had a trifurcation. Gender and side differences were not statistically significant ( $p > 0.05$ ).

### Relation to zygomatic arch, lateral canthus, and tragus

In 24 (80%) out of 30 specimens, the point of origin of the terminal branches of the STA was  $50.8 \pm 20.9$  mm above the zygomatic arch, over the arch in 4 (13.3%) cases, and  $5.0 \pm 0.2$  mm below the arch in 2 (6.7%) cases. Other measurements taken from this point — to the lateral canthus and to the tragus — were  $58.6 \pm 24.3$  mm and  $44.1 \pm 18.5$  mm, respectively. There were no significant differences between these measurements on the right and left sides in any subject ( $p > 0.05$ ).

## DISCUSSION

Repairing defects of the face requires the most suitable tissue. The scalp is the most popular site

**Table 1.** Point of origin of the terminal branches of the superficial temporal artery in relation to the zygomatic arch in different studies; 1 — above the arch; 2 — over the arch; 3 — below the arch

	1 (%)	2 (%)	3 (%)
Stock et al. [14]	60	32	8
Sahinoglu et al. [12]	61	14	7
Czerwinski [5]	62.5	26	11.5
Pinar and Govsa [10]	74.07	22.22	–
Abul-Hassan et al. [1]	80	–	–
Magden and Arman [7]	80	10	8
Chen et al. [4]	86.5	3.8	9.6
Marano et al. [8]	88	4	4
Current study	80	13.3	6.7

for harvesting flaps because it is suitable and near the face [1, 3, 10]. These flaps are based on the blood supply by the STA [15]. It is therefore important to be familiar with the variations in the branching pattern of the STA and its relation to pericranial structures for a suitable flap harvest and better surgical outcome.

The variations in the branching of the STA seen in the present study have also been reported by other workers. Marano et al. [8] reported classical bifurcation into a frontal and a parietal branch in 78% of cases. In the same study, double frontal and parietal branches were observed in 13% and 4% of specimens, respectively. Other variations reported in literature but not seen in our study include double parietal branches [10] and the absence of either a frontal or parietal branch [15, 18].

In various studies (Table 1) the bifurcation point of the STA observed above the zygomatic arch ranged between 60% and 88% of cases [1, 4, 7, 9], directly over the arch between 3.8% and 26%, and below the arch between 7% and 11.5% [4, 5, 7, 12, 14]. In the present study, we reported a bifurcation above the zygomatic arch in 80% of cases, over the arch in 13.3% of cases, and below the arch in 6.7% of cases. The observed inter-study variations have been attributed to ethnological differences [4, 10].

The successful usage of the forehead and parieto-occipital flap depends on whether the pedicles of the parietal and frontal branches contained [4, 10]. However, care should be taken to avoid injuring these vessels during the flap harvest [4]. In this study we found that the terminal branches of the STA usu-

ally arise  $50.8 \pm 20.9$  mm above the midpoint of the zygomatic arch,  $58.6 \pm 24.3$  mm behind the lateral canthus, and  $44.1 \pm 18.5$  mm anterior to the tragus. Bearing these measurements in mind may optimize the size of the flap to be harvested and at the same time minimize injury to the STA or its terminal branches.

## CONCLUSIONS

The branching pattern of the STA among Kenyans differs from the classical descriptions, and the artery can be located using reliable landmarks. Lateral forehead operations may lacerate the STA and/or its branches, leading to haemorrhage and a poor flap. A good understanding of the forehead vascularity thus aids in the design of the flaps and minimizes postoperative complications.

## REFERENCES

1. Abul-Hassan HS, Ascher GD, Acland RD (1986) Surgical anatomy and blood supply of the fascial layers of the temporal region. *Plast Reconstr Surg*, 77: 7–28.
2. Buyukmumcu M, Guney O, Ustun ME, Uysal, II, Seker M (2004) Proximal superficial temporal artery to proximal middle cerebral artery bypass using a radial artery graft: an anatomic approach. *Neurosurg Rev*, 27: 185–188.
3. Chang KP, Lai CS, Tsai CC, Lin TM, Lin SD (2003) Total upper lip reconstruction with a free temporal scalp flap: long-term follow-up. *Head Neck*, 25: 602–605.
4. Chen TH, Chen CH, Shyu JF, Wu CW, Lui WY, Liu JC (1999) Distribution of the superficial temporal artery in the Chinese adults. *Plast Reconstr Surg*, 104: 1276–1279.
5. Czerwinski F (1992) Variability in the course of the superficial temporal artery in man. *Folia Morphol*, 51: 49–54.
6. Har-Shai Y, Fukuta K, Collares MV (1992). The vascular anatomy of the galeal flap in the interparietal and midline regions. *Plast Reconstr Surg*, 89: 64–69.
7. Magden O, Arman C (1995) Arteria temporalis superficialis'in anatomik varyasyonları. *Dokuz Eylul Universitesi Tip Fakultesi Dergisi*, 95: 15.
8. Marano SR, Fischer DW, Gaines C, Sonntag VK (1985) Anatomical study of the superficial temporal artery. *Neurosurg*, 16: 786–789.
9. Nakajima H, Imanishi N, Minabe T (1995) The arterial anatomy of the temporal region and the vascular basis of various temporal flaps. *Br J Plast Surg*, 48: 439–450.
10. Pinar AY, Govsa F (2006) Anatomy of the superficial temporal artery and its branches: its importance for surgery. *Surg Radiol Anat*, 28: 248–253.
11. Ricbourg B, Mitz V, Lassau JP (1975) Artere temporalis superficialis. *Ann Chir Plast*, 2: 197–213.
12. Sahinoglu K, Koldas T, Gorgun B, Arý Z, Usta A (1994) Arteria temporalis superficialis ve arteria temporalis media anatomisi. *Istanbul Tip Fakultesi Dergisi*, 57: 40–42.
13. Sakai S, Soeda S, Ishii Y (1990) Avulsion of the scalp: which one is the best artery for anastomosis? *Ann Plast Surg*, 24: 350–353.
14. Stock AL, Collins HP, Davidson TM (1980) Anatomy of the superficial temporal artery. *Head Neck Surg*, 2: 466–469.
15. Ter Konda RP, Sykes JM (1997) Concepts in scalp and forehead reconstruction. *Conc Consider Head Neck Reconstr*, 30: 519–539.