

Geometry of the articular facets of the lateral atlanto-axial joints in the case of occipitalization

A.M. Ryniewicz^{1, 2}, J. Skrzat³, A. Ryniewicz⁴, W. Ryniewicz¹, J. Walocha³

¹Department of Prosthodontic Dentistry, Jagiellonian University, Collegium Medicum, Krakow, Poland

²Faculty of Mechanical Engineering and Robotics, University of Science and Technology, Krakow, Poland

³Department of Anatomy, Jagiellonian University, Collegium Medicum, Krakow, Poland

⁴Laboratory of Coordination Metrology, Cracow University of Technology, Krakow, Poland

[Received 6 May 2010; Accepted 15 June 2010]

This study investigates if atlanto-occipital fusion affects the size and geometrical configuration of the articular facets of the atlanto-axial joint. Morphometric analysis was performed on the male adult skull, the occipital bone of which is assimilated with the first cervical vertebrae (the atlas). The perimeter, Feret's diameter, surface area, and circularity of the inferior articular facets were measured. However, we did not observe significant bilateral differences in size of the inferior articular facets of the assimilated atlas compared to normal first cervical vertebrae. Geometrical conformation of the articular facets of the atlas and axis was assessed using a coordinate measuring machine (PMM – 12106, Leitz). The results obtained from this machine indicated that the inferior articular facets of the assimilated atlas presented asymmetrical orientation compared to the normal anatomy of the atlas. Hence, in the case of occipitalization, the gap between the articulating facets of the atlas and the axis was measured to be greater than in the normal atlanto-axial joint. Computer assisted tomography was applied to visualise the anatomical relationship between the inferior articular facets of the assimilated atlas and the corresponding facets located on the axis. In this case, radiographic examination revealed that the bilaterally articulating facets (inferior and superior) showed disproportion in their adjustment within the lateral atlanto-axial joints. Thus, we concluded that the fusion of the atlas with the occipital bone altered the geometry of the inferior articular facets of the atlas and influenced the orientation of the superior articular facets of the axis. (Folia Morphol 2010; 69, 3: 147–153)

Key words: occipitalization, atlas, cervical vertebrae, craniovertebral joint

INTRODUCTION

The craniovertebral joints are shaped to give a wide range of movement to the head and to transmit the weight of the head to the rest of the vertebral column. The movements include: flexion, extension, bilateral

bending and rotation, distraction, and axial loading. However, the proper biomechanics of these joints may be disrupted by a pathological ossification that can develop between the occipital condyles and the superior articular facets of the atlas. This anomaly is termed

Address for correspondence: Dr hab. n. biol. J. Skrzat, Department of Anatomy, Collegium Medicum, Jagiellonian University, Kopernika 12, 31–034 Kraków, Poland, tel. +48 12 422 95 11, e-mail: jskrzat@poczta.onet.pl

occipitalization of the atlas (or atlanto-occipital assimilation) and shows firm fusion between parts of the atlas and the basicranium [9, 11, 14]. In the human population, the frequency of occipitalization is rather low and can vary from 0.1% to 0.8% [2, 4].

The occipito-atlanto-axial complex is one of the most intricate articulations in the human skeleton. This joint allows bending (flexion and extension) of the head while the atlanto-axial joint permits the rotation of the atlas upon the axis. The entire occipito-atlanto-axial complex also facilitates lateral bending of the head, which predominantly occurs in the cervical portion of the vertebral column. The flexion that occurs in the atlanto-occipital joint has a range of 10° while the atlanto-axial joint flexion has a range of 5°. In turn, extension that occurs in the atlanto-occipital joint has a range of 25°, while being only 10° in the atlanto-axial joint. Rotation takes place at the atlanto-axial joint (45°), and the rest of the rotating capability is provided by cervical vertebrae three to seven in diminishing amounts. Thus the range of rotation is 90° from neutral position to either side [7, 12, 13].

With occipitalization of the atlas, movement between the occiput and the atlas is abolished. During maximum flexion, maximal stress is placed on the occipito-odontoid ligaments. Any attempts at lateral flexion or rotation exert abnormal stress on the occipito-odontoid ligaments with over-stretching. This may lead to hypermobility of the atlas on the axis with the possibility of atlanto-axial subluxation, which may be found later in life with this type of anomaly or hypomobility of the atlanto-occipital joint.

The aim of this study was to investigate if atlanto-occipital fusion affects the size and geometrical configuration of the articular facets of the atlanto-axial joint and disturbs the biomechanical condition of the atlanto-axial joint.

MATERIAL AND METHODS

A skeleton of an adult male, the skull of which demonstrated remarkable occipitalization, was found during an archaeological exploration in Cracow (Poland). The skull, with fused first cervical vertebra (the atlas) and second articulating cervical vertebra (the axis), was subjected to morphometric analysis (Figs. 1, 2). A further 15 normal isolated atlases were used as reference specimens. Both the skull and vertebrae were well preserved and did not show any traits of deformation. The atlases with normal anatomy belonged to the osteological collection housed in the Department of Anatomy of the Collegium Medicum of the Jagiellonian University.

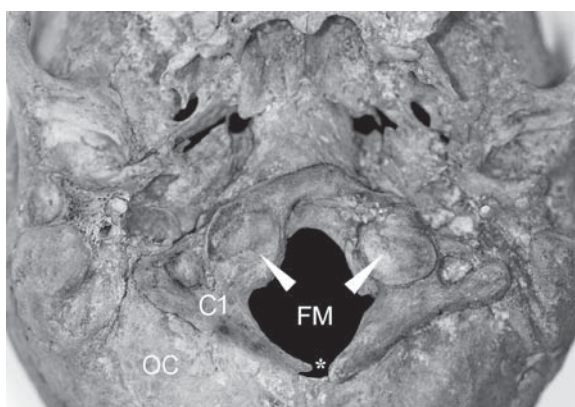


Figure 1. Inferior view of the skull with the assimilated atlas (C1) and the occipital bone (OC). The arrows indicate the inferior articular facets of the atlas. Note the lack of fusion of the posterior arch (indicated by asterisk); FM — foramen magnum.

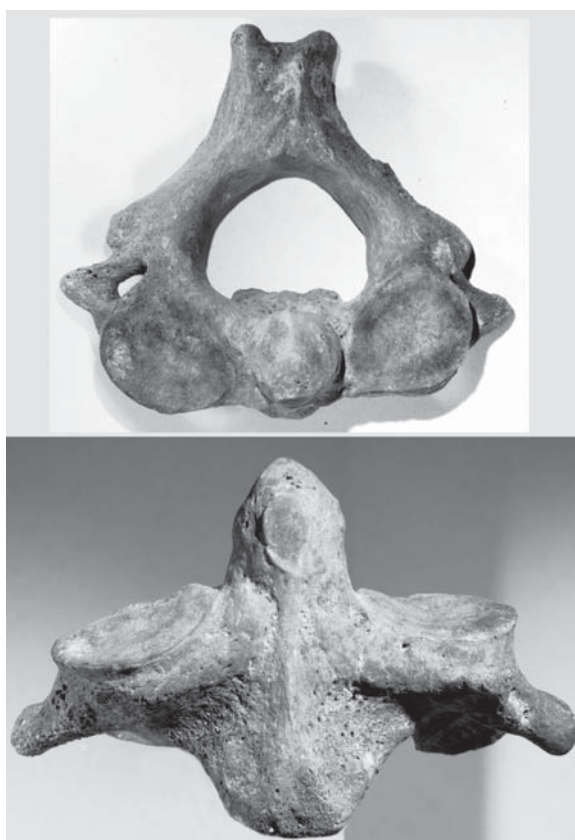

Figure 2. Superior and anterior view of the axis articulating with the fused atlas to the cranial base.

The sex and age of the skull was assessed based on craniofacial morphology. Visible muscular attachments, outstanding osseous crests, prominent superciliary ridges, a strongly developed glabella region, big mastoid processes, and a well-developed external occipital protuberance indicated a male character of the skull.

The sutures of the vault (coronal, sagittal, lambdoid) were in the large part not closed exocranially but entirely fused endocranially, except for the lambdoid suture. Thus, the condition of the suture closure corresponded to an age of about 40 years.

Quantitative analyses were performed to compare the anatomy of the inferior articular facets of the atlas in the case of occipitalization to the inferior articular facets of the normal atlases. Thus, the size and shape of the inferior articular facets were characterised by the perimeter, Feret's diameter, surface area, and circularity. Feret's diameter (maximum caliper) is the longest distance between any two points along the selection boundary. The circularity of the inferior articular facet was calculated using the formula:

$$C = 4\pi \left(\frac{A}{P^2} \right)$$

where: C — circularity, A — area, P — perimeter.

A circularity value of 1.0 indicates a perfect circle. As the value approaches 0.0, it indicates an increasingly elongated polygon. All measurements were performed on digital images using ImageJ software (<http://rsb.info.nih.gov/ij>).

In the case of atlas assimilation, we examined the anatomy of the lateral atlanto-axial articular facets because the second cervical vertebrae (axis) was preserved. The specimens were subjected to computer assisted tomography to analyse the orientation of the articulating facets. Hence, the 3D reconstruction of the atlanto-axial joint in the case of occipitalization was performed to visualise the spatial relationship between the inferior and superior articulating facets of the atlas and axis. Geometrical conformation of the articular facets of these vertebrae was assessed using a coordinate measuring machine (PMM – 12106, Leitz) equip-ped with a scanning probe for measuring geometrical characteristics of the articular facets in all directions. The specimens were placed in a stable holder which enabled measurements of the articular facet textures in the same fixed condition (Fig. 3).

The values of deviations in measurement points were visualised in graphs. In other words, they show local fluctuations of the articular facet shape presented as negative or positive deviations from mean flatness (reference plane). Orientation of mean flatness was estimated by the method of least squares. Negative values represent the position of the real articulating facet below mean flatness whereas positive values indicate an increase above mean flatness.




Figure 3. The coordinate measurement machine used for mapping surface geometry of the articular facets of the vertebrae. Close-up view of the probe in contact with the inferior articular facet of the atlas (top left corner image).

Bilateral measurements of the inferior articular facets of the normal atlases were presented as box-whisker plots using Statistica 7.1 software [10]. Additionally, corresponding measurements of the assimilated atlas were marked along the box-whisker plot, which denoted reference values showing normal variation.

RESULTS

In the case of the atlas assimilation, we did not find any significant bilateral differences in the size of the inferior articular facet (Table 1). The values of surface area, perimeter, Feret's diameter, and circularity of the left and right inferior articular facets of the assimilated atlas were within the normal range of variation estimated for 15 isolated atlases (Fig. 4).

Computer assisted tomography examination of the atlanto-axial joint in the case of occipitalization revealed that the bilateral articulating facets (inferior and superior) showed asymmetry in their slope. The right inferior articular facet was more oblique than the left one. The right superior articulating facet of the axis sloped laterally and anteriorly, whereas the left one was more horizontally orientated. In normal anatomical conditions, there were no disproportions in the declination of the right and left articular facets both of the atlas and the axis. Both articular facets were inclined laterally (Figs. 5–7).

The results obtained from the coordinate measurement machine indicated that the right and left

Table 1. Bilateral measurements of the inferior articular facets (IAF) of the assimilated atlas versus parameters of normal atlases. Measurements in millimetres, standard deviation in parentheses

| Parameter | Normal atlas | | Parameter | Assimilated atlas | |
|-----------------------|--------------|-------------|---------------|-------------------|-----------|
| | IAF left | IAF right | | IAF left | IAF right |
| Min-max surface area | 145.4–210.0 | 144.4–196.4 | Surface area | 171.3 | 192.4 |
| Min-max perimeter | 46.0–55.3 | 47.5–53.9 | Perimeter | 50.4 | 54.9 |
| Min-max circularity | 0.82–0.86 | 0.80–0.88 | Circularity | 0.85 | 0.80 |
| Min-max Feret's diam. | 15.1–19.6 | 15.2–18.5 | Feret's diam. | 17.5 | 19.5 |

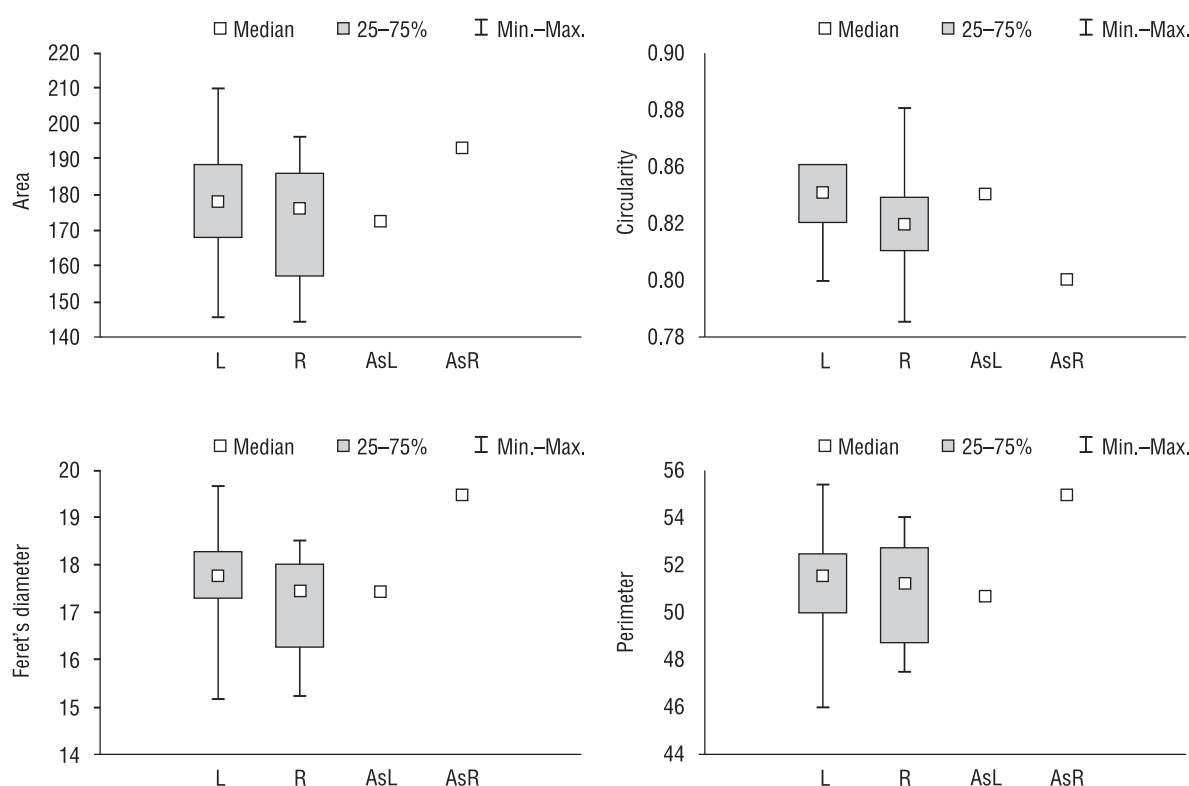


Figure 4. Box-whisker plot of the parameters characterizing inferior articular facets of the normal atlases *versus* the values of the parameter for the assimilated atlas marked as a point; L — left, R — right, AsL — left, in the case of assimilation, AsR — right, in the case of assimilation.

inferior facets of the assimilated atlas had cylindrical depressions which stretched along the longest axis of the ellipse demarcating the shape of each articular facet. The edges of the facets were declined. The maximum depression was estimated as -0.547 mm for the right articular facet and -0.491 mm for the left articular facet. The corresponding superior articular facets of the axis revealed spherical depressions; the depth was estimated at -0.732 mm on the right side and -0.575 mm on the left side (Figs. 8, 9).

Normally, the inferior articular facets of the atlas are circular in form, flattened or slightly convex, and

directed downward and medialward, articulating with the axis. Maximum depression of the right articular facet was -0.431 mm, and -0.631 mm for the left side (Figs. 10, 11).

The superior articular facet of the normal atlanto-axial joint of the axis showed cylindrical convexity, particularly in the middle part, whereas the edges of these facets declined inferiorly. On the right articular facet, maximum convexity was measured as 0.771 mm, and 0.870 mm for the left articular facet of the axis.

Analyses of geometrical conformation of the mutually articulating facets of the atlas and the axis

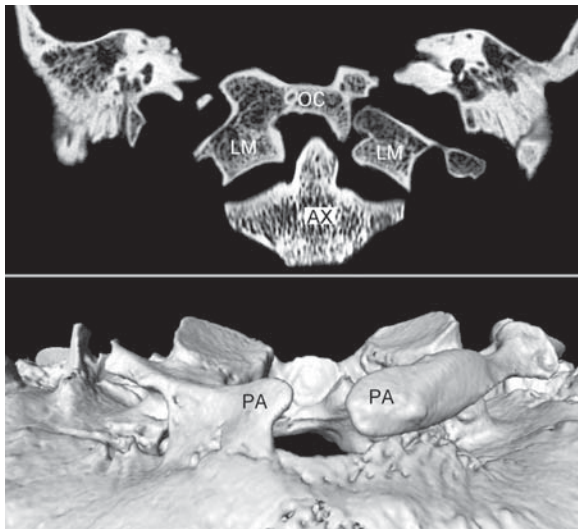


Figure 5. Computed tomography scan of the occipito-atlanto-axial complex in the case of occipitalization, and the 3D reconstruction of the atlas fusion with the cranial base; OC — occipital bone, LM — lateral mass, AX — axis, PA — unfused posterior arch.

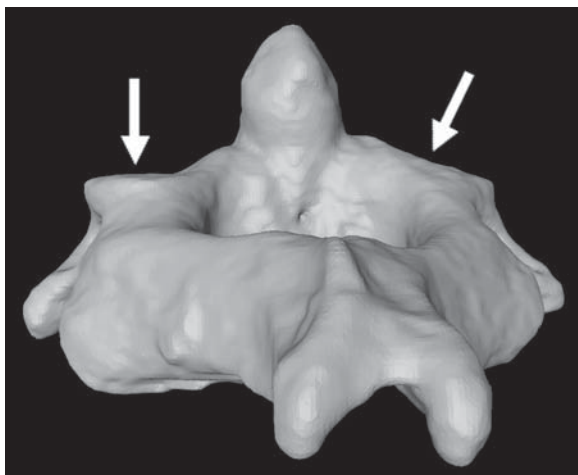


Figure 6. 3D reconstruction of the axis of the skull with assimilated atlas to the cranial base. Note, significant differences in configuration of the left and right superior articular facets (indicated by the arrows).

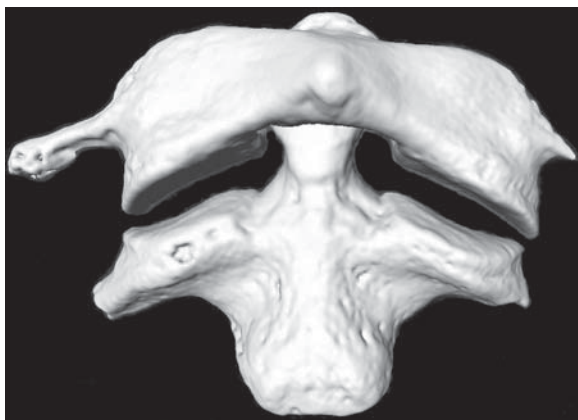


Figure 7. 3D reconstruction of the normal atlanto-axial joint.

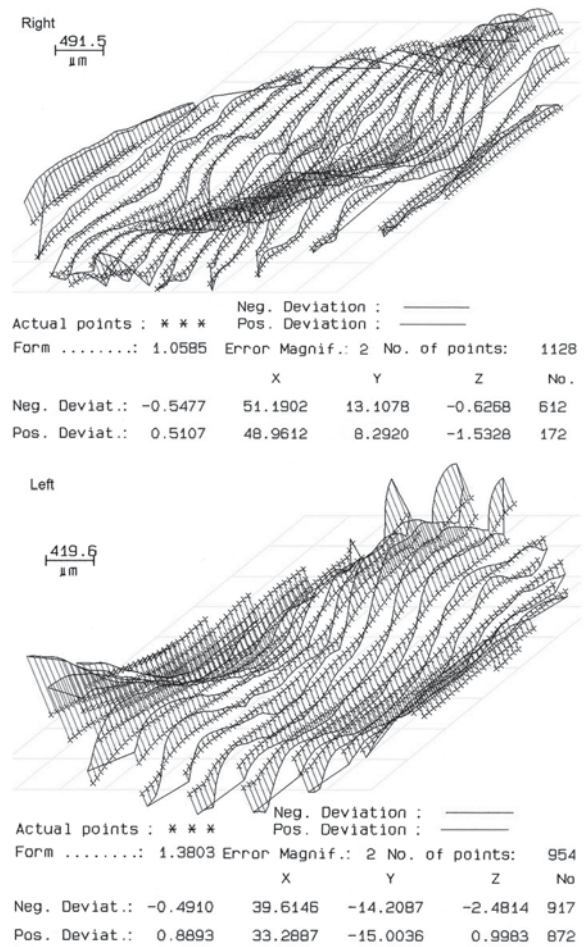


Figure 8. Geometrical mapping of the right and left inferior articular facets of the assimilated atlas.

showed that in the case of occipitalization the distance between them was greater (1.07 and 1.28 mm) than in a normal atlanto-axial joint (0.24 and 0.34 mm). This geometrical property is expressed by the maximum deviations from mean flatness of the lateral articulating facets of the atlas and the axis (Table 2).

DISCUSSION

The occipito-cervical junction, which comprises the occiput, atlas, and axis, represents a unique and complex interface between the cranium and the cervical spine. More than 50% of the rotation and flexion–extension of the head and neck occurs in this region [1]. Atypical ossification within the articular complex between the skull and the vertebral column markedly reduces or even abolishes movements in this region [5, 6].

A congenital fusion of the atlas to the base of the occiput (occipitalization) can cause headache, neck pain, and other neurological disorders [2, 9, 14]. How-




Figure 9. Geometrical mapping of the right and left superior articular facets of the axis articulating with the assimilated atlas.




Figure 10. Geometrical mapping of the right and left superior articular facets of the normal axis.

ever, occipitalization does not always cause clinical symptoms, and this defect can be accidentally discovered during CT examination due to a head injury.

The results of our study showed that fusion between the occipital condyles and the superior articular facets of the atlas does not significantly affect the size of the surface area of the inferior articular facets of the atlas. According to Cattrysse et al. [3], the mean surface area of the left inferior facet of the atlas totals $213.0 \pm 33.8 \text{ mm}^2$ while the mean surface area of the right inferior facet of the atlas totals $210.5 \pm 37.0 \text{ mm}^2$. These values correspond with our findings referring both to the normal cases and the assimilated atlas. Similar observations were also found for other selected parameters of the articular facets. In the case of occipitalization, estimated values of the perimeter, Feret's diameter, and circularity of the inferior articular facets do not differ from measurements performed on normal vertebrae.

However, the results obtained from the coordinate measuring machine, supported by CT analysis, allowed us to speculate that fusion between the superior articular facets and occipital condyles altered the geometry of the superior articular facets of the axis. The typical configuration of the articular facets of the atlanto-axial joint provides bioelastic and hydrodynamic lubrication of the joint, similar to other joints [8]. In occipitalization, remodelling of the atlas and the orientation of the superior articular facets of the axis may alter the movement of the head. Fusion of the atlas with the occipital bone influences the pattern of force distribution exerted by the head on the vertebral column. In this case, the forces are transferred directly via the lateral masses of the atlas to the superior facets of the axis. This is reflected in the arrangement and distribution of the bony trabecula within the vertebrae. The functional adapta-




Figure 11. Geometrical mapping of the right and left inferior articular facets of the normal atlas.

tion of the first and second cervical vertebrae induced changes in the lateral articular facet inclination and alters the geometrical shape of these facets. Hence, the abolishment of movement between the occipital bone and the atlas in the case of occipitalization probably influenced the thickness and density of the bone lying underneath the articular cartilage, and the lack of synovial articulation between the occipital bone and the atlas could not efficiently absorb the energy generated by the head

Table 2. Comparison of the fitting between the lateral articulating facets of the atlas and axis (measurements in millimetres)

| | Articular facets | |
|---|------------------|-------|
| | Left | Right |
| Normal atlanto-axial joint | 0.24 | 0.34 |
| Atlanto-axial joint in occipitalization | 1.07 | 1.28 |

movement. The potential weight of the head is directly transmitted to the atlanto-axial joint and is not suppressed by the cartilage which normally exists within the atlanto-occipital joint. In consequence, abnormal articulation between the skull and the vertebral column caused by the occipitalization could generate excessive movement of the atlanto-axial joint and increase the stress placed on ligaments, inducing subluxation or dislocation of the entire occipito-atlantal complex.

ACKNOWLEDGMENTS

The research has been supported by the State Committee for Scientific Research within the framework of grant No. 4083/B/T02/2008/34.

REFERENCES

- Adams LP, Tregidga A, Driver-Jowitt JP, Selby P, Wynchank S (1994) Analysis of motion of the head. *Spine*, 19: 266–271.
- AL-Motabagani MA, Surendra M (2006) Total occipitalization of the atlas. *Anat Sci Int*, 81: 173–180.
- Cattrysse E, Provyn S, Gagey O, Kool P, Clarys JP, Van Roy P (2008) In vitro three dimensional morphometry of the lateral atlantoaxial articular surfaces. *Spine*, 33: 1503–1508.
- Lang J (1995) Skull base and related structures. *Atlas of clinical anatomy*. Shattauer, Stuttgart, New York.
- Nayak S, Vollala VR, Raghunathan D (2005) Total fusion of atlas with occipital bone: a case report. *Neuroanatomy*, 4: 39–40.
- Ranade AV, Rai R, Prabhu LV, Kumaran M, Pai MM (2007) Atlas assimilation: a case report. *Neuroanatomy*, 6: 32–33.
- Roche CJ, King SJ, Dangerfield PH, Carty HM (2002) The atlanto-axial joint: physiological range of rotation on MRI and CT. *Clin Radiol*, 57: 103–108.
- Ryniewicz AM (2002) The analysis of lubrication mechanism of a human hip joint. Post-doctoral thesis. Academy of Mining and Metallurgy. Cracow, Poland.
- Sonnesen L, Pedersen CE, Kjaer I (2007) Cervical column morphology related to head posture, cranial base angle, and condylar malformation. *Eur J Orthod*, 29: 398–403.
- StatSoft, Inc. 2005 STATISTICA (data analysis software system), version 7.1. www.statsoft.com.
- Wendy RK (1994) Craniovertebral junction: normal anatomy, craniometry, and congenital anomalies. *RadioGraphics*, 14: 255–277.
- White AA, Panjabi MM (1990) *Clinical biomechanics of the spine*. 2nd Ed. J.B. Lippincott Company, Philadelphia.
- Worth D (1970) Movements of the cervical spine. *Austr J Physiother*, 16: 84–85.
- Wysocki J, Bubrowski M, Szymański I (2003) Developmental abnormalities of the craniovertebral region and their significance for hearing and balance disorders. *Otolaryngologia*, 2: 65–71.