

# A case of occipitalization in the human skull

J. Skrzat, I. Mróz, J.K. Jaworek, J. Walocha

Department of Anatomy, Collegium Medicum, Jagiellonian University, Kraków, Poland

[Received 15 April 2010; Accepted 28 May 2010]

*Occipitalization of the atlas is an osseous anomaly of the craniovertebral junction. The aim of this paper is to present an anatomical variant of the fused atlas with the occipital bone and discuss similar cases described in literature. The skull of an adult male analysed in this study belonged to the cranial collection of the Department of Anatomy of the Jagiellonian University, Medical Collage. A tight bony fusion between the anterior arch of the atlas, the left portion of the posterior arch, the lateral masses of the atlas, and the occipital bone was observed. Hence, the left and right superior articular facets of the atlas were fused with the corresponding occipital condyles. The anteroposterior dimension of both inferior articular facets was the same (20 mm), while the transverse diameter of the right one was considerably smaller (12 mm). The transverse diameter of the left inferior articular facets was 17 mm. The right and the left transverse process of the atlas were normally developed, each of them contained transverse foramen, and they were not fused with the occipital bone. The circumference of the foramen magnum was minimally diminished by the osseous structures of the atlas fused to the occipital bone. The sagittal and transverse diameters of the foramen magnum (38 mm × 34 mm) were within the normal range of variation. However, the asymmetrical anatomy of the inferior articular facets of the atlas give rise to speculation that movement in the atlantoaxial joint was disturbed by assimilation with the occipital bone. (Folia Morphol 2010; 69, 3: 134–137)*

**Key words: occipitalization, assimilation of the atlas, atlantooccipital fusion**

## INTRODUCTION

Occipitalization of the atlas (atlantooccipital fusion) is the congenital osseous anomaly found in the craniovertebral junction. This condition is caused by assimilation of the first cervical vertebra (the atlas) to the basicranium [5, 8]. The atlas is normally formed by three primary ossification centres: one for each neural arch and one for the body. Failure of segmentation of the basal occipital sclerotome and first spinal sclerotome lead to osseous fusion between the atlas and the occipital bone [4, 7, 11].

Occipitalization of the atlas may be associated with developmental anomalies of the first and se-

cond branchial arch. This anomaly is accompanied by: maldevelopment of the occipital bone, reduced length of the clivus, non-formation or inadequate formation of the occipitoaxial joint, dislocation of atlanto-axial joints, and platybasia [2, 4, 14]. Usually, the clinical symptoms associated with occipitalization of the atlas can be: abnormally short neck, restricted neck movements, abnormal head posture, headache, neck pain, pain in the limbs, elevation of the scapula, weakness, numbness, dysphagia, dysarthria, or torticollis [5, 7, 10, 12]. Fusion between the atlas and the occipital bone may cause neurological disorders (e.g. Arnold-Chiari syndrome) be-

cause of the proximity to the spinomedullary region [1]. Occipitalization may also result in vertebral artery compression or even its total occlusion in the bony canal, leading to dizziness, seizures, mental deterioration, and syncope [8, 14].

The aim of this paper is to present a rare anatomical variant of fused first cervical vertebra with the occipital bone and discuss similar cases described in literature.

## MATERIAL AND METHODS

The skull, the first cervical vertebra of which is fused with the occipital bone, belonged to the cranial collection of the Department of Anatomy of the Collegium Medicum of the Jagiellonian University. It was well preserved and did not show any traits of craniofacial deformation. Hence, all the bones of the viscerocranium and neurocranium were well developed and did not show any deformities.

Sex and age of the skull were assessed by craniofacial morphology. The cranial bones possessed clearly visible muscular attachments and outstanding osseous crests. These anatomical features were in harmony with prominent superciliary ridges, a strongly developed glabella region, remarkable temporal lines, large mastoid processes, and a well-developed external occipital protuberance. All these traits expressed the evidently male character of the skull. The sutures of the vault (coronal, sagittal, lambdoid) are mostly not closed exocranially but entirely fused endocranially, except the lambdoid suture. Thus, the condition of the suture closure corresponded to about 40–50 years of age.

The sagittal and transverse dimensions of the right and left inferior articular facet of the atlas, and the foramen magnum were measured using digital sliding calipers.

## RESULTS

Visual inspection of the basicranium revealed an obvious anomaly within the region of the foramen magnum, which appeared as the fusion of the first cervical vertebra (the atlas) with the occipital bone (Fig. 1). Abnormal ossification took place between the anterior arch (particularly the left portion), the body of the occipital bone, and both lateral masses with the occipital condyles, and the left portion of the posterior arch with the occipital squama, along the edge of the foramen magnum (Fig. 2). The posterior arch of the atlas was incomplete in the midline, and its right portion was not united with the occipital bone (Fig. 3). Both the left and right supe-

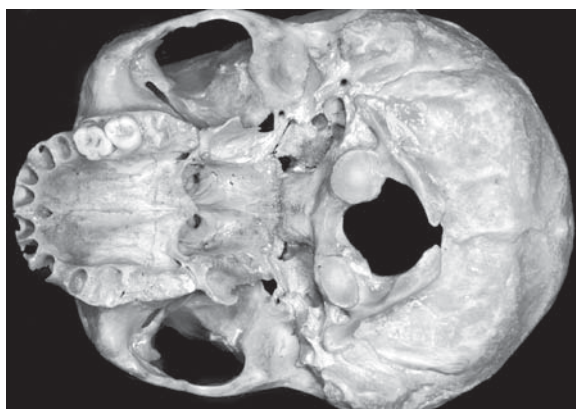

Figure 1. Inferior view of the basicranium with assimilated atlas.

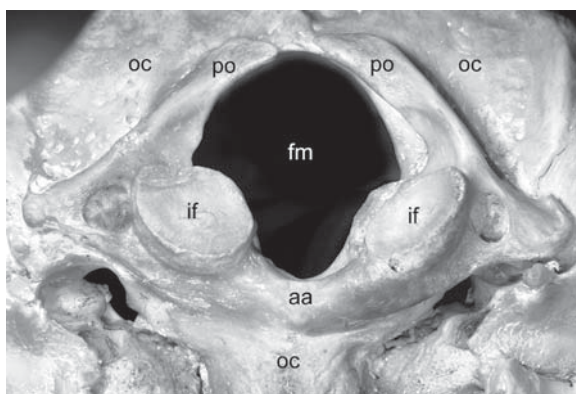


Figure 2. Close-up image of the atlas assimilation; fm — foramen magnum; oc — occipital bone; if — inferior articular facet of the atlas; aa — anterior arch of the atlas; po — posterior arch of the atlas.

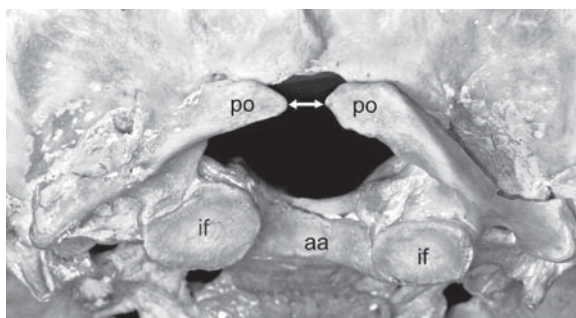


Figure 3. Postero-inferior aspect of the basicranium; visible incomplete posterior arch of the atlas (marked by arrow); if — inferior articular facet of the atlas; aa — anterior arch of the atlas; po — posterior arch of the atlas.

rior articular facets of the atlas were fused with the corresponding occipital condyles. The inferior articular facets of the atlas were asymmetrical. The right articular facet was elliptical in shape while the left

was oval. The anteroposterior dimension of both inferior articular facets was the same (20 mm), while the transverse diameter of the right one was considerably smaller (12 mm). The transverse diameter of the left inferior articular facets was 17 mm.

The right and the left transverse process of the atlas were normally developed, each of them containing the transverse foramen, and they were not fused with the occipital bone.

The anterior aspect of the foramen magnum was minimally diminished by the left lateral mass of the atlas and the left portion of the anterior arch. However, the sagittal and transverse diameters of the foramen magnum (38 mm × 34 mm) were within the normal range of variation. The standard dimensions for the foramen magnum vary between 28–38 mm for the sagittal diameter and 25–40 mm for the transverse diameter [6].

## DISCUSSION

There are numerous anatomical variants and abnormalities in the region of the atlanto-occipital junction, although the occipitalization appears to be the most common, occurring in 0.1–0.8% of cases [6]. According to Al-Motabagani and Surendra [1], this anomaly exists in one per 109 human adult skulls of Asian origin. Assimilation of the atlas to the occipital bone can be complete or partial [3, 8, 10, 12]. According to Wysocki et al. [14], this connection is usually partial and concerns only the anterior arch of the atlas and the anterior edge of the foramen magnum, and according to Nayak et al. [7], it concerns the lateral masses of the atlas, which are fused with the condyles of the occipital bone.

Jayanthi et al. [5] described two skulls with occipitalization of the atlas. In the first case there was complete fusion of only one of the transverse processes with the occipital bone, and the anterior arch of the atlas was fused incompletely. In the second case the anterior arch of the atlas was fused with the occipital bone. This skull also showed fusion of only one of the transverse processes of the atlas to the occipital bone, and partial fusion with the occipital bone.

Ranade et al. [8] examined 98 Indian human skulls of both sexes for occipitalization of the atlas. Only two skulls showed various degrees of assimilation of the atlas. The first skull showed complete fusion of the anterior arch of the atlas with the occipital bone on the left side and incomplete fusion on the right side. The posterior arch was incompletely developed. The left transverse process of the atlas

was fused with a spine-like process of the occipital bone to form a foramen. On the right side the spine-like process showed an incomplete fusion with the transverse process of the atlas. The posterior arch on the right side was not fused with the occipital bone, whereas on the left side it was probably broken. In the second skull the anterior and posterior arches were completely fused with the occipital bone. The transverse processes of the atlas were bilaterally fused with the occipital bone. The left inferior articular process was larger than the right one. Hence, the size of the foramen magnum was reduced.

Nayak et al. [7] described a skull in which the lateral masses of the atlas were fused completely with the occipital condyles, and the anterior arch was fused with the basilar part of the occipital bone. The hypoglossal canals were absent. A foramen between the anterior arch of the atlas and the basilar part of the occipital bone was observed. The posterior arch was fused with the squama of the occipital bone. There were some perforations between the posterior arch of the atlas and the occipital bone. The gap for the vertebral artery passage to the cranial cavity was very small.

In turn, Gholve et al. [3] examined 24 boys and 6 girls with occipitalization (mean age: 6.5 years). A fused anterior arch of the atlas was present in six cases; fused lateral masses in five cases; a fused posterior arch in four cases; and a combination of these in fifteen patients.

The morphological appearance of the occipitalization of the investigated skull is similar to the case described by Ranade et al. [8]. In both cases the transverse processes of the atlas were not fused with the occipital bone, and the lateral masses of the atlas were fused with the occipital condyles. Nayak et al. [7] also described a similar condition.

The atlanto-occipital fusion may reduce the lumen of the foramen magnum and lead to neurological complications due to compression of the spinal cord [5, 7]. Tun et al. [10] presented a case in which computed tomography images revealed not only a fusion between the posterior arch of the atlas and the occipital bone, but also hypertrophy of the occipital condyles and a reduction of the transverse diameters of the foramen magnum.

In our case, the anterior margin of the foramen magnum was partially overlapped by the inferior articular facet of the fused atlas. The margin of the foramen magnum was also covered by the posterior arch. Additionally, the circumference of the foramen magnum was diminished by the lateral masses

of the atlas (which were bilaterally fused with the occipital bone), by the anterior arch of the atlas (particularly the left portion), and by the posterior arch of the atlas (particularly the left portion, which was fused with the occipital squama along the edge of the foramen magnum). Nevertheless, the sagittal and transverse diameters remained within the normal range of variation; therefore, we presume that clinical symptoms associated with the spinal cord compression were absent in our case. The sagittal diameter of the foramen magnum in our case was 38 mm and the transverse diameter was 34 mm. The standard diameters for foramen magnum range between 28–38 mm for the sagittal diameter and between 25–40 mm for the transverse diameter [6].

The inferior articular facets of the atlas were asymmetrical in the studied case. Unfortunately, the axis was not preserved, so we were not able to assess if these two vertebrae articulated properly. If the inferior articular facet of the atlas is asymmetrical, atlantoaxial dislocation may occur [13]. In 60% of cases of atlas assimilation, atlantoaxial dislocation is present [14]. We cannot exclude the case that atlantoaxial dislocation was present in our case. Nevertheless, without the presence of an axis and the ligaments strengthening the atlantoaxial joint we could not investigate the biomechanical aspects of the craniovertebral junction.

Normal atlantooccipital joints permit nodding of the head, with a little lateral bending and rotation. If these articulations are not morphologically correct (as in the case of assimilation of the atlas) then the movements are handicapped, and their range is considerably restricted. Asymmetrical atlantoaxial joint geometry might cause asymmetrical joint dynamics [14]. We suspect that movement in the atlantoaxial joint was changed in the studied case. It is possible that torticollis with inclination of the head to one side and rotation to the contralateral side occurred. An abnormal biomechanical condition caused by a solid junction between occipital bone and the atlas could also lead to gradual loosening of the atlantoaxial joint with progressive atlantoaxial subluxation. According to Wortzman and Dewar [13], the facet joint spaces on either side may appear asymmetrical in the case of atlantoaxial subluxation. The most striking clinical symptom of atlantoaxial subluxation is torticollis with inclination of the head to one side, rotation to the contralateral side, and slight flexion [9, 12].

## CONCLUSIONS

Assimilation of the atlas may cause both orthopaedic problems and occasionally induce neurological effects. This happens particularly when the lumen of the foramen magnum is constricted by the abnormally ossified parts of the atlas. Therefore, improved knowledge on the fusion of the atlas with the occipital bone is important for medical practice.

## REFERENCES

1. AL-Motabagani MA, Surendra M (2006) Total occipitalization of the atlas. *Anatom Scien Inter*, 81: 173–180.
2. Chamberlain WE (1939) Basilar impression (platybasia). *Yale J Biol Med*, 11: 487–496.
3. Gholve PA, Hosalkar HS, Ricchetti ET, Pollock AN, Dormans JP, Drummond DS (2007) Occipitalization of the atlas in children. Morphologic classification, associations and clinical relevance. *J Bone Joint Surg Am*, 89: 571–578.
4. Goel A, Sharma P, Dange N, Kulkarni AG (2005) Techniques in the treatment of craniovertebral instability. *Neurol India*, 53: 525–533.
5. Jayanthi V, Kulkarni R, Kulkarni RN (2003) Atlanto-occipital fusion — report of two cases. *J Anat Soc India*, 52: 71–73.
6. Lang J (1995) Skull base and related structures. *Atlas of clinical anatomy*. Shattauer, Stuttgart, New York.
7. Nayak S, Vollala VR, Raghunathan D (2005) Total fusion of atlas with occipital bone: a case report. *Neuroanatomy*, 4: 39–40.
8. Ranade AV, Rai R, Prabhu LV, Kumaran M, Pai MM (2007) Atlas assimilation: a case report. *Neuroanatomy*, 6: 32–33.
9. Schwarz N (1998) The fate of missed atlanto-axial rotator subluxation in children. *Arch Orthop Trauma Surg*, 117: 288–289.
10. Tun K, Okutan O, Kaptanoglu E, Gok B, Solaroglu I, Beskonakli E (2004) Inverted hypertrophy of occipital condyles associated with atlantooccipital fusion and basilar invagination: a case report. *Neuroanatomy*, 3: 43–45.
11. Uğar DA, Semb G (2001) The prevalence of anomalies of the upper cervical vertebrae in subjects with cleft lip, cleft palate, or both. *Cleft Palate Craniofac J*, 38: 498–503.
12. Wendy RK (1994) Craniovertebral junction: normal anatomy, craniometry, and congenital anomalies. *RadioGraphics*, 14: 255–277.
13. Wortzman G, Dewar FP (1968) Rotary fixation of the atlantoaxial joint: rotational atlantoaxial subluxation. *Radiology*, 90: 479–702.
14. Wysocki J, Bubrowski M, Szymański I (2003) Developmental abnormalities of the craniovertebral region and their significance for hearing and balance disorders. *Otolaryngologia*, 2: 65–71.