

An anatomical study in a Chinese population of the position of the rib head for placing anterior vertebral body screws

X.H. Li^{1, 2}, D.C. Xu¹, Z.J. Li², X. Wang²

¹Section of Clinical Anatomy, Department of Anatomy, Southern Medical University, Guangdong Province, P.R. China

²Department of Anatomy, Inner Mongolia Medical College, Mongolia, P.R. China

[Received 25 August 2010; Accepted 26 September 2010]

The instrumentation of anterior vertebral body screws has become an important approach for the treatment of unstable fractures or curvature of the spine, but little attention has been paid to the starting point of placing the screws and the variability of the rib head position. We analysed the variability of rib head position in a Chinese population in terms of the spinal canal and vertebral body using computed tomography (CT). Images from transverse CT scans of the T4–T12 vertebral bodies of 30 normal individuals were 3-D reconstructed and analysed for measurement of parameters which included: 1) distance between the left (or right) anterior border of the rib head and the posterior (or anterior) margin of the vertebral body [L(R)ARHP(A)VB]; 2) left (or right) transverse dimension [L(R)TD]; 3) left (or right) posterior (or anterior) safe angle [L(R)P(A)SA]; and 4) distance between the inferior border of the left (or right) rib head and the superior (or inferior) end-plate in the sagittal plane [L(R)RHS(I)EP]. The ARHPVB, PSA, and IRHIEP gradually decrease, but ARHAVB, TD, ASA, and IRHSEP gradually increase, from T4 to T12, indicating that the position of the rib head changes from a more anterior position to a more posterior position and from a more superior position to a more inferior position, as the number of the vertebra increases. Our study has provided a comprehensive reference guide for accurate and safe instrumentation of vertebral body screws in treating related spine diseases. (Folia Morphol 2010; 69, 4: 232–240)

Key words: anterior thoracic instrumentation, rib head, vertebral body, screw position, vertebral anatomy

INTRODUCTION

Anterior single rod instrumentation has been broadly used for the treatment of unstable fractures of the spinal column and idiopathic scoliosis, and it has a better effect of relieving compression of the spinal cord and spinal nerves, correcting hypokyphosis and preventing vertebral body fusion than the traditional posterior instrumentation for fixation [2–4, 7, 14]. However, some authors think that an-

terior screw placement is more technically demanding and more risky [1, 5]. Due to the increasing use of this technique, there have been multiple reports about injuries of the thoracic aorta or nerves by the screw tip or guidewire, and loss of stability of the fixed segment of the spine caused by loosening or pullout of the screw in anterior open thoracic or thoracoscopic surgery [6, 12]. Some authors think that the ideal position to place the vertebral body screw is

at the centre of the lateral part of the vertebral body near the superior and inferior endplates, keeping equal distance to either the anterior or posterior margin of the vertebral body [7, 8, 15]. Recently, it has been broadly proposed that the thoracic anterior vertebral body screw should be placed anterior to the rib head, which keeps the screw away from the spinal cord and has a better clamping force [10, 12]. Anatomical study of the position of the rib head is obviously of particular importance for safe and accurate anterior instrumentation. Some anatomical landmarks of the rib head have been identified as critical reference points for accurate placement of the screw, but most of the data so far are from western populations.

In this study, we performed 3-D reconstruction and anatomical analysis of the computed tomography scan images from normal individuals in a Chinese population for identification of parameters that define the position of the rib head, aiming to provide a comprehensive reference guide for accurate and safe instrumentation of vertebral body screws for the treatment of spinal diseases, and fill the blank in this field in eastern populations.

MATERIAL AND METHODS

Patient population

Forty-two patients who visited the outpatient or emergency department of our hospital with a chief complaint of non-spinal disease were subjected to postero-anterior and lateral chest X-ray radiography to exclude scoliosis deformity or other abnormalities of the spine, and all radiographs were double-blindly assessed by three experienced doctors to avoid bias. Twelve patients were excluded from the study because of the following spinal abnormalities identified by radiography: spondyloarthropathies, isthmic spondylolysis, idiopathic scoliosis [11, 12], compression fracture, Scheuermann's kyphosis [11], and missing vertebrae. The other 30 patients with a normal spine from T1 to L1, 14 (47%) males and 16 (53%) females aged 16–68 years with an average age of 32.3 years, were included in this study, and further subjected to thoracic CT scan. Ethical approval for this study was obtained from the Human Research Ethics Committee, and informed consent was obtained from the patients involved in the study.

Methods

The CT scan of the thoracic spine was conducted using a GE HiSpeed NX/I (General Electric Company, USA) scanner with a slice thickness of 1.5 mm.

Images were uploaded to Centricity DICOM Viewer 2.1 (General Electric Company, USA). All transverse images were acquired from planes parallel to the superior endplate of each individual vertebra by carefully adjusting the inclination of the vertebrae. The serial image data in Dicom format were imported to a computer system, and measurement of the position of the rib head was then performed by using Mimics (Materialise's Interactive Medical Image Control System) (Version 11.02, System ID: A13B0916F3XC, Materialise, Leuven). Twenty-eight or 30 slices of CT scan were obtained from the transverse plane for each vertebra, and the images showing the rib head were used for the measurement. All images were analysed separately by two doctors, and the rib head position was assessed by using angular and linear measurement mode in Mimics. The mean of the measurements by the two doctors was taken.

Measurement of transverse images

The following parameters were analysed from the transverse slices of the vertebral bodies from the 4th thoracic (T4) level to the 12th thoracic (T12) level:

- the distances between the left or right anterior border of the rib head and the posterior margin of the vertebral body [(L/R)ARHPVB] (Fig. 1);
- the distances between the left or right anterior border of the rib head and the anterior margin of the vertebral body [(L/R)ARHAVB] (Fig. 1);
- the transverse dimension (TD), which was measured from the left or right anterior border of the rib head to the lateral cortex of the vertebral body [(L/R)TD] (Fig. 1).

At T11 and T12, "P₂" was defined as the most anterior aspect of the spinal canal. "Line 1" was drawn through the point "P₂" across the vertebral body on the coronal plane, and its length from the end of the lateral cortex on one side to the end of the lateral cortex on the other side was measured, which was designated as the transverse dimension of T11 or T12 (Fig. 2); (left/right) posterior safe angle [(L/R)PSA] (Fig. 3); "O" was the most anterior aspect of the rib head. "Line 1" was drawn through the most anterior aspect of the rib heads, parallel to the coronal plane. "P" was the most anterolateral aspect (concave side) of the spinal canal. "Line 3" was drawn through "P" perpendicular to "Line 1". "A" was the most anterior aspect of the vertebrae body on "Line 3". (L/R) PSA is the angle between line "PO" and "Line 1", indicating the posterior safe angle for screw insertion; (left or right) anterior safe angle

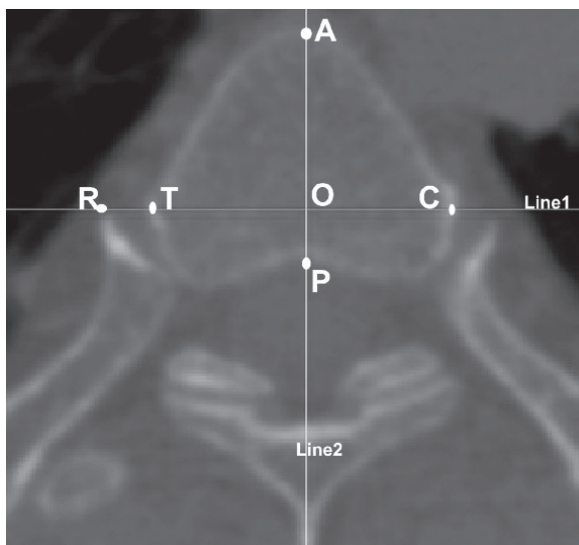


Figure 1. The distance between the anterior border of the rib head and the posterior margin of the vertebral body (ARHPVB), the distance between the anterior border of the rib head ("R") and the anterior margin of the vertebral body (ARHAVB), and transverse dimension (TD) (transverse CT): "Line 1" connects the most anterior aspect of the rib heads; "Line 2" is the line through the mid-sagittal plane of the vertebral body; "O" is the intersection between "Line 1" and "Line 2"; "A" is the point at which line two intersects on the anterior margin of the vertebral body; "P" is the point that line two intersects the posterior margin of the vertebral body; "OA" is the ARHAVB; "OP" is ARHPVB; and "TC" is TD.

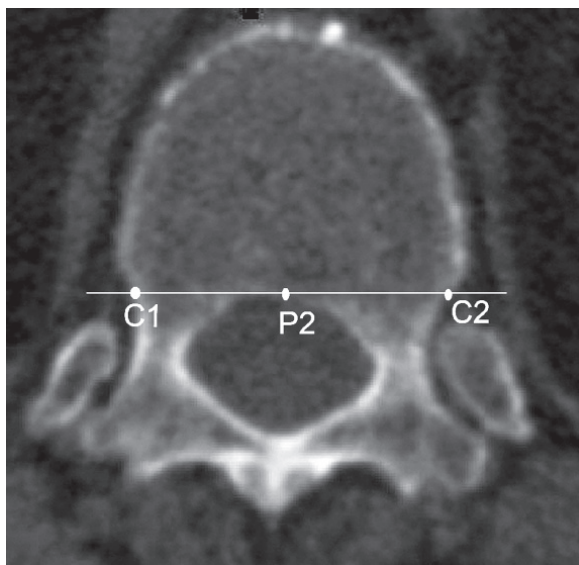


Figure 2. The transverse dimension (TD) at T11 and T12 (transverse CT): "P2" is the posterior margin of the vertebral body; "C1C2" is TD at T11 and T12.

[(L/R)ASA] (Fig. 3): the angle between "Line AO" and "Line 1" is designated as the anterior safe angle, which indicates the anterior safe angle for screw insertion.

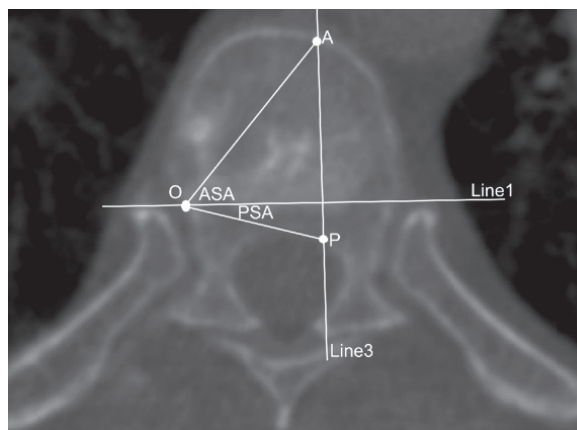


Figure 3. The posterior safe angle (PSA) and anterior safe angle (ASA) (transverse CT). "P" is the most antero-lateral aspect (concave side) of the spinal canal. "Line 3" is a line through P, perpendicular to "Line 1" and tangential to the lateral margin of the concave spinal canal. The PSA is the angle subtended by "Line 1" and a line drawn from the convex rib head ("O") to "P". "A" is the point that "Line 3" intersects the anterior margin of the vertebral body. ASA is the angle subtended by Line 1 and a line drawn from the convex rib head to "A".

3-D rendering and measuring

Segmentation of transverse images. The CT images were first segmented using segmentation tools, such as threshold, region growing, boolean operation, and edit mask, to extract different tissues. The thoracic vertebrae and the rib head of interest were isolated by setting appropriate grey level thresholds to obtain the bone rim. Because some other structures, such as the sternum, had a density similar to that of the thoracic vertebrae, further mask editing was necessary to remove these structures.

3-D rendering. Once the T4–T12 vertebra and the rib head profiles were obtained, a surface rendering technique was used to reconstruct 3-D images, which were then analysed for the following parameters:

- the distance between the most inferior aspect of (left or right) the rib head and the superior endplates in the sagittal plane [(L/R)RHSEP] (Fig. 4);
- the distance between the most inferior aspect of (left or right) the rib head and the inferior endplates in the sagittal plane [(L/R)RHIEP] (Fig. 4).

Data and statistical analysis

All measurements and statistical analyses were performed using the Statistical Package for Social Sciences (SPSS, Chicago, IL, Version 13.0). All the data were presented as mean ± SD, and two-side difference analyses were performed using the paired two-tailed Student's *t* test. Probability valu-

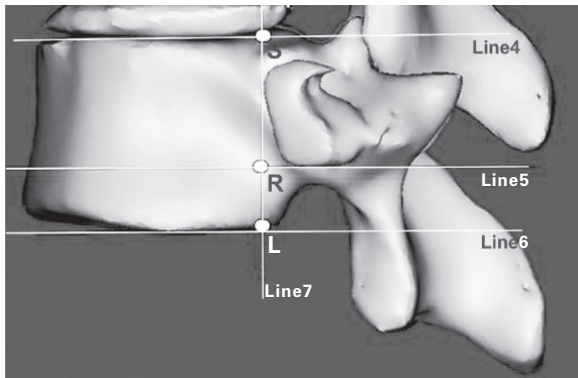


Figure 4. The distance between the most inferior border of the rib head and the inferior-end-plate in the sagittal plane (IRHIEP) and the distance between the most inferior border of the left rib head and the superior end-plate in the sagittal plane (IRHSEP). "Line 4" is a line parallel to the superior end-plate, "Line 5" is drawn through the most inferior aspect of the rib head, parallel to "Line 4". "Line 6" is a line parallel to the inferior end-plate. "Line 7" is drawn through the most anterior aspect of the rib head, perpendicular to "Line 5". "S" is the point at which "Line 4" intersects "Line 7". "R" is the point at which "Line 5" intersects "Line 7". "L" is the point at which "Line 6" intersects "Line 7"; "RS" is "IRHSEP"; "RL" is "IRHIEP".

es of less than 0.05 were considered to be statistically significant.

RESULTS

Images of the thoracic vertebrae and the rib head from a total of 30 subjects were used for analysis. The trends of their numerical values are presented in Tables 1–7.

2-D measurements

The (L/R)ARHPVB (Table 1) showed a gradual decrease from the T4 level towards the T12 level. The values of T11 and T12 were negative. The smallest (L/R)ARHPVB value was at the T12 level (left: -3.31 mm; right: -4.04 mm) and the largest was at the T4 level (left: 5.98 mm; right: 5.43 mm). The measurements of ARHPVB also showed a statistically significant difference between the left and right sides at all levels ($p < 0.05$), except T4 and T6 ($p > 0.05$).

A gradual increase in (L/R)ARHAVB was found from T4 to T12 (Table 2), indicating that the rib head tended to become more posteriorly located with the increase of the number of the vertebrae. The smallest (L/R)ARHAVB value was at T4 (left: 16.08 mm; right: 16.91 mm) and the largest was at the T12 level (left: 28.90 mm; right: 29.51 mm). The measurements of ARHAVB showed a significant statistical difference between the left and right sides from T5 to T9 ($p < 0.05$), but no difference for the rest of the vertebrae ($p > 0.05$).

The TD (Table 3) showed a gradual increase from T4 to the T12. The smallest TD was at the T4 level (left: 24.88 mm; right: 23.43 mm) and the largest was at the T12 level (left: 38.70 mm; right: 39.03 mm). The measurements showed no significant difference between the left and right sides ($p > 0.05$), except for T8 ($p < 0.05$).

The posterior safe angle (PSA) was gradually decreased from T4 to T12. The smallest PSA was at the T12 level (left: -8.70°; right: -9.57°) and the largest

Table 1. The distance between the left (right) anterior border of the rib head and the posterior margin of the vertebral body, (L/R)ARHPVB (mm, n = 30)

Vertebrae	LARHPVB		RARHPVB		P
	Average	SD	Average	SD	
T ₄	5.98	1.68	5.43	1.75	0.903*
T ₅	5.89	1.36	5.09	1.67	0.012
T ₆	4.68	1.15	4.46	1.56	0.252*
T ₇	3.88	1.36	3.35	1.43	0.010
T ₈	2.70	0.83	1.88	1.27	0.001
T ₉	2.03	1.38	1.42	1.48	0.008
T ₁₀	1.66	1.64	1.06	1.57	0.001
T ₁₁	-0.61	1.95	-1.22	1.66	0.007
T ₁₂	-3.31	2.38	-4.04	2.80	0.013

*There is no significant difference between LARHPVB and RARHPVB.

Table 2. The distance between the left (right) anterior border of the rib head and the anterior margin of the vertebral body, (L/R)ARHAVB (mm, n = 30)

Vertebrae	LARHAVB		RARHAVB		P
	Average	SD	Average	SD	
T ₄	16.08	2.53	16.91	2.49	0.060
T ₅	17.69	2.42	18.81	2.67	0.015*
T ₆	19.43	2.08	20.28	2.21	0.000*
T ₇	22.41	2.17	23.04	2.43	0.027*
T ₈	23.94	2.17	24.63	2.58	0.008*
T ₉	25.65	2.48	26.26	2.37	0.018*
T ₁₀	27.67	3.53	27.67	2.73	0.987
T ₁₁	28.08	2.47	28.62	2.47	0.119
T ₁₂	28.90	2.57	29.51	2.31	0.057

*There is a significant difference between LARHAVB and RARHAVB.

Table 3. Left (right) transverse dimension, (L/R)TD (mm, n = 30)

Vertebrae	LTD		RTD		P
	Average	SD	Average	SD	
T ₄	24.88	2.64	23.43	2.67	0.231
T ₅	26.35	2.67	27.15	2.54	0.246
T ₆	28.18	2.54	28.32	2.50	0.723
T ₇	29.90	2.39	29.76	2.34	0.778
T ₈	31.72	2.57	30.67	2.91	0.002*
T ₉	32.10	3.06	32.51	3.10	0.503
T ₁₀	34.37	2.27	34.82	3.07	0.358
T ₁₁	36.71	2.30	37.59	3.24	0.059
T ₁₂	38.70	3.16	39.03	3.63	0.604

*There is a significant difference between LTD and RTD.

Table 4. Left (right) posterior safe angle, (L/R)PSA (n = 30)

Vertebrae	LPSA		RPSA		P
	Average	SD	Average	SD	
T ₄	22.06	5.74	20.42	4.04	0.192
T ₅	21.45	6.18	18.71	4.78	0.022*
T ₆	15.64	4.65	14.85	5.14	0.364
T ₇	14.52	3.98	10.91	3.50	0.000*
T ₈	10.50	3.73	8.49	2.87	0.016*
T ₉	7.78	3.52	6.69	3.52	0.134
T ₁₀	5.24	5.06	3.90	3.74	0.160
T ₁₁	-0.94	5.96	-2.14	5.40	0.256
T ₁₂	-8.70	4.15	-9.57	4.21	0.410

*There is a significant difference between LPSA and RPSA.

Table 5. Left (right) anterior safe angle, (L/R)ASA ($^{\circ}$, n = 30)

Vertebrae	LASA		RASA		P
	Average	SD	Average	SD	
T ₄	44.01	5.15	44.04	6.24	0.975
T ₅	47.35	5.52	47.64	5.55	0.645
T ₆	48.00	6.13	50.60	6.24	0.037*
T ₇	52.88	4.89	52.04	4.97	0.373
T ₈	55.73	2.87	53.29	2.84	0.000*
T ₉	55.78	3.78	53.52	3.22	0.003*
T ₁₀	55.06	4.06	53.19	4.26	0.009*
T ₁₁	53.83	4.99	52.31	4.48	0.020*
T ₁₂	48.18	8.45	44.73	9.23	0.020*

*There is a significant difference between LASA and RASA.

Table 6. The distance between the most inferior border of the left (right) rib head and the superior end-plate in the sagittal plane, I(L/R)RHSEP (mm, n = 30)

Vertebrae	ILRHSEP		IRRHSEP		P
	Average	SD	Average	SD	
T ₄	5.65	1.36	5.76	1.73	0.682
T ₅	6.26	1.45	6.05	1.51	0.314
T ₆	6.65	1.03	6.94	1.22	0.194
T ₇	7.36	1.04	7.09	1.19	0.269
T ₈	8.15	1.02	7.94	1.34	0.310
T ₉	9.15	1.13	8.77	1.46	0.066
T ₁₀	10.41	2.02	10.50	2.05	0.661
T ₁₁	12.06	2.07	11.77	2.12	0.259
T ₁₂	14.36	2.15	14.06	1.68	0.310

Table 7. The distance between the most inferior border of the left (right) rib head and the inferior end-plate in the sagittal plane, I(L/R)RHIEP (mm, n = 30)

Vertebrae	ILRHIEP		IRRHIEP		P
	Average	SD	Average	SD	
T ₄	12.33	2.14	11.52	2.19	0.053
T ₅	11.78	1.09	11.76	1.28	0.934
T ₆	11.69	1.30	11.87	1.26	0.383
T ₇	10.83	1.39	11.95	1.26	0.000*
T ₈	11.75	1.18	12.07	1.16	0.136
T ₉	11.59	1.24	12.22	1.34	0.022*
T ₁₀	10.22	2.76	10.74	1.87	0.189
T ₁₁	9.98	2.45	10.22	2.58	0.231
T ₁₂	10.83	2.80	10.90	2.89	0.619

*There was a significant difference between ILRHIEP and IRRHIEP.

was at the T4 level (left: 22.06°; right: 20.42°). The measurements showed no significant difference between the left and right sides ($p > 0.05$), except for T5, T7, and T8 ($p < 0.05$) (Table 4).

The anterior safe angle (ASA) was gradually increased from T4 to T8, stayed about the same from T8 to T10, but was decreased from T11 to T12. The smallest ASA was at the T4 level (left: 44.01°; right: 44.04°) and the largest at the T9 level (left: 55.78°; right: 53.52°). The measurements showed no significant difference between the left and right sides ($p > 0.05$), except for T4, T5, and T7 ($p < 0.05$) (Table 5).

3-D measurements

A gradual increase was found in the I(L/R)RHSEP from T4 to T12. The smallest I(L/R)RHSEP value was at the T4 level (left: 5.65 mm; right: 5.76 mm) and the largest was at the T12 level (left: 14.36 mm; right: 14.06 mm). The measurements showed no significant difference between the left and right sides ($p > 0.05$) (Table 6).

The I(L/R)RHIEP seemed to have a gradual decrease from T4 to T12, but it stayed about the same from T5 to T12 (Table 7). The smallest I(L/R)RHIEP was at the T11 level (left: 9.98 mm; right: 10.22 mm) and the largest was at the T4 level (left: 12.33 mm; right: 11.52 mm). The measurements showed no significant difference between the left and right sides ($p > 0.05$), except for T7 and T9 ($p < 0.05$).

DISCUSSION

Anterior stabilisation of thoracic vertebrae after trauma or neoplasm-related instability is an important component in surgical management. Anterior spinal instrumentation reduces fracture dislocation and helps to maintain stability and alignment of the thoracic vertebrae, thereby facilitating neurological recovery. It can also prevent late neurological sequelae and disabling mechanical pain due to post traumatic kyphosis. Compared with the posterior approach, the anterior approach has been reported to be superior for decompression when the spinal cord is compressed by fractured bone fragment or tumour. It has also been reported to have a better correction of spinal deformities with less fused segments in both idiopathic and neuromuscular deformities [16]. During surgical stabilisation and instrumentation it is critical to avoid injury of neural structures. An accurate and safe pathway of the anterior vertebrae body is important and requires precision and accuracy. Understanding of the precise anatomy of the vertebrae and neural structures

is fundamentally important for accurate and safe access from the anterior vertebra body.

The ideal starting point for screw insertion has previously been considered to be just anterior to the head of the rib at each level [9]. However, the position of the rib head is varied in the thoracic spine, so the actual starting position of the screw insertion should be dependent on the level of the thoracic vertebrae in which the screws are placed. Zhang et al. [15] found that there was a decline in (L/R)ARHPVB from T3 to T12 in a porcine model, and they also analysed the position of the rib head relative to the spinal canal and vertebral body in normal individuals and patients with right thoracic adolescent idiopathic scoliosis in a western population using magnetic resonance imaging (MRI) [9]. They indicated that the screws in the cephalad thoracic spine were mostly placed anteriorly, while the screws in the caudal thoracic spine were more commonly placed posteriorly. There have been almost no reports about precise, quantitative measurements to assess the position of the rib head, especially in the Chinese population.

This study has demonstrated that the position of the rib head changes from a more anterior position in the cephalad thoracic spine to a more posterior position in the caudal thoracic spine in a Chinese population, based on measurement of the (L/R)ARHPVB. The average value of (L/R)ARHPVB on the left side at T4 was 5.98 mm, and that on the right was 5.43 mm. The average value of (L/R)ARHPVB on the left side at T12 was -0.31 mm, and that on the right side was -4.04 mm. The average value of (L/R)ARHAVB on the left side at T4 was 16.08 mm, and that on the right side was 16.91 mm. The average value of (L/R)ARHAVB on the left side at T12 was 28.90 mm, and that on the right side was 29.51 mm, which is similar to that in the western population reported by Zhang and Sucato [16]. We have further found that the anterior aspect of rib head at T11 and T12 is posterior to the posterior border of the vertebral body (the values of (L/R)ARHPVB were all negative).

We are the first to point out how the screws should be positioned in different segments of the T4–T12 thoracic spine (either anterior or posterior to the anterior rib head). The screw sizes of the standard stainless steel Moss-Miami (DePuy Spine, Inc., Raynham, MA) for anterior instrumentation were 5, 6, and 7 mm in diameter [13]. Taking the 6 mm diameter screw as an example, the screws should be placed posterior to the anterior rib head in the T4–T7 segment if the anterior aspect of rib head is used as the starting point for screw insertion. The screw starting point at T4 on the left side was located 2.98 mm

posterior to the anterior rib head, and that on the right side was 2.43 mm. The screw starting point at T7 on the left side was 0.88 mm, and that on the right side was 0.35 mm. However, the screws should be placed anterior to the anterior rib head in the T8–T12 segment. The screw starting point at T8 on the left side was located 0.30 mm anterior to the anterior rib head, and that on the right side was 1.12 mm. The screw starting point at T12 on the left side was 6.31 mm, and that on the right side was 7.04 mm. A comparison of ARHPVB and ARHAVB between the left and right sides revealed a difference in those parameters at most T4–T12 levels, which should be taken into consideration in designing the surgery. However, further study with a larger sample size is needed to more comprehensively address this question.

The TD is a crucial parameter for selecting an appropriate screw size. Inappropriate size or length of the screw may cause potential injury to the spinal cord and even the aorta. In our study, we found that the TD gradually increases from T4 towards T12, which is consistent with previous studies [16]. This study has revealed no difference between the left and right sides in TD, except for T8. Surgeons could select the screw size for both sides based on the TD.

As well as the correct starting point, accurate angulation of the screw into the vertebral body is also a very important parameter for screw insertion, in order to achieve effective fixation and to reduce the risks of screw pullout, vertebral fracture, and spinal cord and aorta injuries. This study has demonstrated that the posterior safe insertion angle is the largest at T4 and it decreases gradually from T4 (22.06° on the left and 20.42° on the right) to T12 (−8.70° on the left and −9.57° on the right). This observation is consistent with previous studies [15]. The trend of PSA revealed in this study is similar to that from a previous study, but the values of PSA by CT in our study are slightly smaller than those by MRI in that study [16]. The ASA has been shown in our study to be larger in the T7–T11 segment than that of other segments of the T4–T12 levels, which is different from the findings of Zhang and Sucato, who reported that the ASA of the most cephalad thoracic vertebrae (T4, T5, and T6 in normal individuals, and T4 and T5 in patients with scoliosis) are significantly smaller than those of all other thoracic vertebrae [16]. Some researchers have suggested that this difference may be due to the different methods used for the measurement [5], but we think that this may be related to genetic endowment and environmental fac-

tors. Thorough anatomical studies are needed to further clarify this disparity. We have reconstructed 3-D images from the 2-D images of T4–T12 and measured the linear dimensions of I(L/R)RHSEP and I(R/L)RHIEP. The I(L/R)RHSEP showed a gradual increase from T4 level to T12 level, while I(L/R)RHIEP had no such tendency. The variable range of I(L/R)RHIEP was small (9.98–12.33 mm). There was no difference between the left and right sides in both IRHSEP and IRHIEP across T4–T12 levels, except for T7 and T9 in IRHIEP.

We analysed in this study the anatomical parameters of the T4–T12 thoracic vertebrae in a Chinese population that are critical in determining the position and direction of screw instrumentation in the thoracic spine, which can greatly improve the accuracy of the surgery, increase the stability of the spine, and reduce the risk of injury to the surrounding tissues.

REFERENCES

1. Assaker R, Reyns N, Pertruzon B, Lejeune PJ (2001) Image-guided endoscopic spine surgery: part II: clinical applications. *Spine*, 26: 1711–1718.
2. Basobas L, Mardjetko S, Hammerberg K, Lubicky J (2003) Selective anterior fusion and instrumentation for the treatment of neuromuscular scoliosis. *Spine*, 28: S245–S248.
3. Betz RR, Harms J, Clements DH, Lenke LG, Lowe TG, Shufflebarger HL, Jeszenszky D, Beele B (1999) Comparison of anterior and posterior instrumentation for correction of adolescent thoracic idiopathic scoliosis. *Spine*, 24: 225–239.
4. Betz RR, Shufflebarger H (2001) Anterior versus posterior instrumentation for the correction thoracic idiopathic scoliosis. *Spine*, 26: 1095–1100.
5. Kamimura M, Kinoshita T, Itoh H, Yuzawa Y, Takahashi J, Hirabayashi H, Nakamura I (2002) Preoperative CT examination for accurate and safe anterior spinal instrumentation surgery with endoscopic approach. *J Spinal Disorders Techniques* 15: 47–51.
6. Lenke LG (2003) Anterior endoscopic discectomy and fusion for adolescent idiopathic scoliosis. *Spine*, 28: S36–S43.
7. Lowe TG, Alongi PR, Smith DAB, O'Brien MF, Mitchell SL, Pinteric RJ (2003) Anterior single rod instrumentation for thoracolumbar adolescent idiopathic scoliosis with and without the use of structural interbody support. *Spine*, 28: 2232–2241.
8. Lowe T, O'Brien M, Smith DM, Fitzgerald D, Vraney R, Eule J, Alongi P (2002) Central and Juxta-Endplate vertebral body screw placement: a biomechanical analysis in a human cadaveric model. *Spine*, 27: 369–373.
9. Mohamad F, Oka R, Mahar A, Wedemeyer M, Newton P (2006) Biomechanical comparison of the screw-bone interface: optimization of 1 and 2 screw constructs by varying screw diameter. *Spine*, 31: E535–E539.

10. Parent S, Labelle H, Skalli W, Latimer B, de Guise J (2002) Morphometric analysis of anatomic scoliotic specimens. *Spine*, 27: 2305–2311.
11. Scoles PV, Latimer BM, Digiovanni BF, Vargo E, Bauza S, Jellema LM (1991) Vertebral alterations in Scheuermann's kyphosis. *Spine*, 16: 509–515.
12. Sucato DJ (2003) Thoracoscopic anterior instrumentation and fusion for idiopathic scoliosis. *J Am Acad Orthop Surg*, 11: 221–227.
13. Sucato DJ, Kassab F, Dempsey M (2004) Analysis of screw placement relative to the aorta and spinal canal following anterior instrumentation for thoracic idiopathic scoliosis. *Spine*, 29: 554–559.
14. Sweet FA, Lenke LG, Bridwell KH, Blanke KM (1999) Maintaining lumbar lordosis with anterior single solid-rod instrumentation in thoracolumbar and lumbar adolescent idiopathic scoliosis. *Spine*, 24: 1655–1662.
15. Zhang H, Sucato DJ, Welch RD (2004) Anterior vertebral body screw position placed thoracoscopically a function of anatomy and surgeon experience in a porcine model. *Spine*, 29: 815–822.
16. Zhang H, Sucato DJ (2006) Regional differences in anatomical landmarks for placing anterior instrumentation of the thoracic spine in both normal patients and patients with adolescent idiopathic scoliosis. *Spine*, 31: 183–189.