

Estimation of nasal cavity and conchae volumes by stereological method

M. Emirzeoglu¹, B. Sahin¹, M. Celebi², A. Uzun¹, S. Bilgic¹, H.O. Tontus³

¹Anatomy Department, Medical Faculty, Ondokuz Mayıs University, Samsun, Turkey

²ENT Department, Mehmet Aydin Research Hospital, Samsun, Turkey

³Medical Education Department, Medical Faculty, Ondokuz Mayıs University, Samsun, Turkey

[Received 16 February 2012; Accepted 23 February 2012]

Background: Studies evaluating the mean volumes of nasal cavity and concha are very rare. Since there is little data on the mentioned topic, we aimed to carry out the presented study to obtain a volumetric index showing the relation between the nasal cavity and concha.

Material and methods: The volumes of the nasal cavity and concha were measured in 30 males and 30 females (18–40 years old) on computed tomography images using stereological methods.

Results: The mean volumes of nasal cavity, concha nasalis media, and concha nasalis inferior were $5.95 \pm 0.10 \text{ cm}^3$, $0.56 \pm 0.22 \text{ cm}^3$, and $1.45 \pm 0.68 \text{ cm}^3$; $7.01 \pm 0.18 \text{ cm}^3$, $0.67 \pm 0.31 \text{ cm}^3$ and $1.59 \pm 0.98 \text{ cm}^3$ in females and males, respectively. There were statistically significant differences in the volume of the nasal cavity and concha nasalis media ($p < 0.05$) between males and females, except for concha nasalis inferior ($p > 0.05$).

Conclusions: Our results could provide volumetric indexes for the nasal cavity and concha, which could help the physician to manage surgical procedures related to the nasal cavity and concha. (Folia Morphol 2012; 71, 2: 105–108)

Key words: stereology, nasal cavity, volume

INTRODUCTION

Nasal cavity is the first part of the respiratory tract. It not only moisturises, cleans and adjusts the temperature of the air inhaled, but it also serves the smell function. Thanks to these features, it helps us to adjust ourselves to the environment. The dynamic execution of these functions by the nasal cavity depends heavily on the structure of the conchae adherent to the exterior wall of the cavity. Conchae have a dynamic structure. This enables them to adjust the flow rate and volume of the air inhaled. Conchae increase the surface area that the air comes into contact with to achieve this function. The middle and inferior nasal conchae are important points in the exterior nasal wall. The

former forms the medial wall of the ethmoid chambers. This area is of crucial importance for endoscopic sinus surgery. Clinicians have encountered numerous variations of the medial concha. However, previous studies conducted on medial conchae focused on size and structure [9].

Nasal obstruction is known to be a common complaint of people with a long history, and studies have been conducted to determine an ideal treatment. Potential complications of the treatment techniques applied are still on the agenda [12].

Hypertrophy of inferior nasal concha is one of the causes of nasal air passage obstruction. The most common causes for hypertrophy include long-term septal deviation and allergy and nasal

Address for correspondence: Prof. M. Emirzeoglu, Anatomy Department, Medical Faculty, Ondokuz Mayıs University, Samsun, Ondokuz Mayıs Uni. TIP FAK, Atakum, 55000 Samsun, Turkey, e-mail: memirze@omu.edu.tr

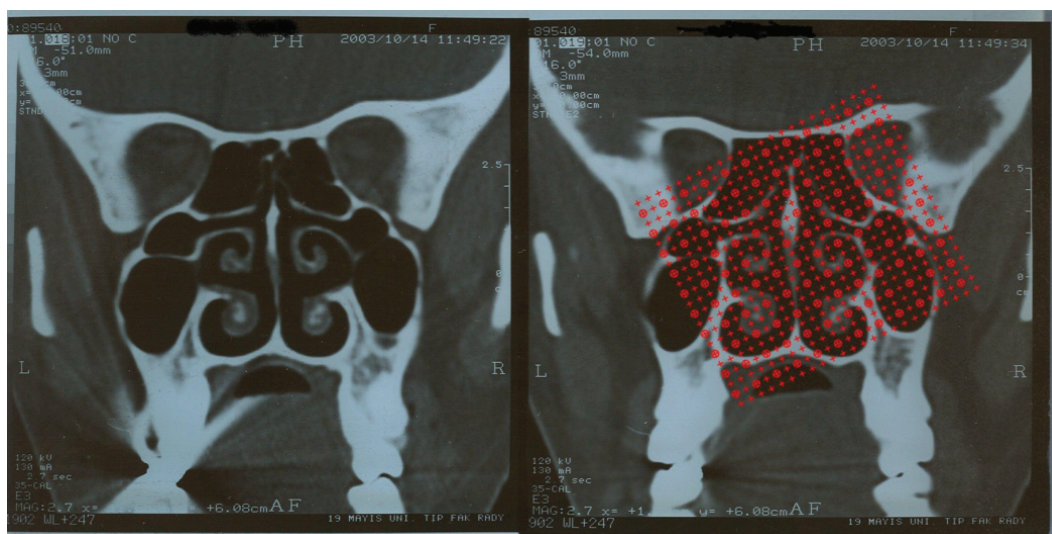


Figure 1. Magnetic resonance image of the nasal cavity and the conchae shaded with point grid.

mucosal diseases such as vasomotor rhinitis [5]. Age-related changes of nasal cavity structure should be determined before planning medical or surgical treatment modalities. These changes probably lead medical professionals to choose different options when managing their patients' symptoms or diseases [6]. Although many researchers have studied the anatomy of the lateral nasal wall "to resolve the problem of patients with nasal air passage obstruction", we could not find any study specifically addressing the volume of the nasal cavity, middle nasal concha, and inferior nasal concha [7, 8, 13, 14].

The volumes of the mentioned structures can be calculated with cross sectional tomography images by using the stereological method (SM). There is no published study about calculating the volumes of the nasal cavity and conchae using computed tomography (CT) images and SM. In this study, we aimed to calculate the nasal cavity and conchae volumes using CT images and SM.

MATERIAL AND METHODS

This study was conducted on the CT images of 60 volunteers (30 male, 30 female). CT images of nasal cavities and conchae were obtained by coronal cross sections. From vestibulum nasi to choanae, CT images with 3-mm cross section thickness were used to collect the volunteers' image data. The images were printed onto X-ray films, which were placed onto a negatoscope. Point counting grids ($d = 0.25/$

$/1.25$ and $d = 0.3/1.5$ cm) of $1/4$ proportion were randomly allocated onto CT image printouts in order to calculate the nasal cavity and conchae volumes. Firstly, the point counting grid was randomly located onto sections. Then we counted how many points were found within the region of interest, and we kept a record of how many points hit each section. Finally, the results are used to compute the volumes. All the intersections of the nasal cavity, including the spots in circles found on the point counting grid, and the conchae were counted. Afterwards, we counted the intersections between the spots, whether in circles or not, and the conchae (Fig. 1). The number of the spots counted was put in the following formula to calculate the volume of the nasal cavity and those of the conchae.

$$V = t \times [((SU) \times d) / SL]^2 \times \Sigma P$$

In this formula, (t) stands for the mean cross sectional thickness, (SU) the length represented by the scale showing image magnification, (d) the distance between two spots on the point counting grid, (SL) the length of the scale on the image measured either by a ruler or a calliper, and (ΣP) the total number of spots of the structure in question on cross sectional surface area.

Superior nasal concha volume estimation is excluded from this study because it is not possible to distinguish it on the cross sectional images. The volumes of the nasal cavity and inferior and middle nasal conchae were calculated for the right and left parts separately. Microsoft Excel[®] was used for the calculations. The number of spots and related data were entered and volumes were automatically calculated.

Table 1. Mean nasal cavity and conchae volumes in males and females

	Min–Max	Mean \pm SD
Nasal cavity in females	4.13–8.10	5.95 \pm 0.10
Middle nasal concha in females	0.25–1.03	0.56 \pm 0.02
Inferior nasal concha in females	0.41–2.94	1.45 \pm 0.07
Nasal cavity in males	4.10–12.71	7.61 \pm 0.18
Middle nasal concha in males	0.22–1.29	0.67 \pm 0.03
Inferior nasal concha in males	0.59–3.94	1.59 \pm 0.09

RESULTS

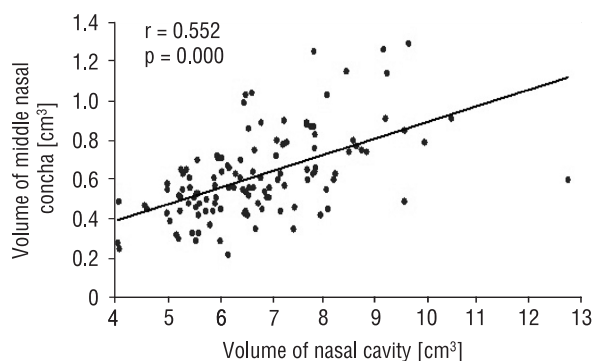
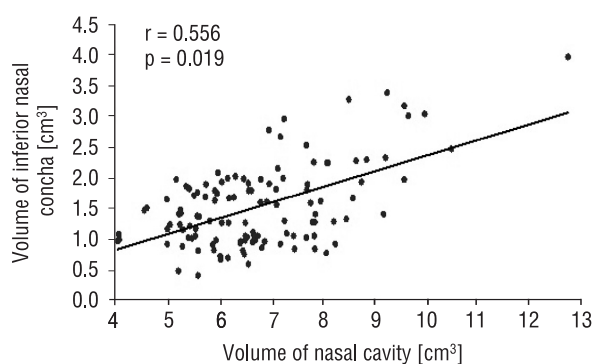
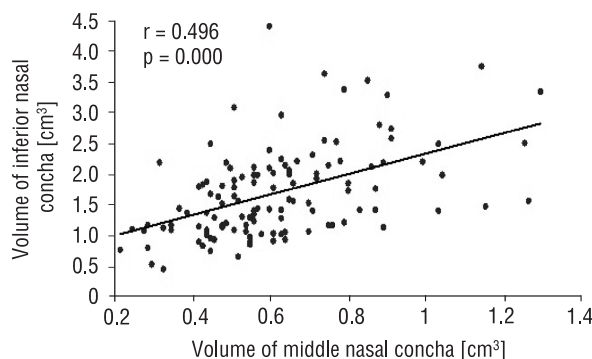
Table 1 represents the mean volumes of the nasal cavity and the conchae in male and female volunteers. The nasal cavities of the males were larger than those of the females ($p < 0.001$). The volume of the middle nasal concha was also larger in males compared with females ($p < 0.01$). On the other hand, there was no significant difference between the male and the female inferior nasal concha volumes ($p > 0.05$). Also, there was no significant difference between the two genders with regard to right and left nasal cavity and the conchae volumes ($p > 0.05$).

The correlation values of the nasal cavity and the conchae are given in Figures 2–4. These values indicate high correlation values between the nasal cavity and the conchae and the conchae themselves.

DISCUSSION

Nasal cavity is the entrance point of the respiratory system and olfactory tracts. Many clinicians have been interested in this region's anatomical structure, structural changes, mucosal diseases, and other pathological and physiological changes because of the great importance in regard of upper and lower respiratory diseases.

One of the main causes of chronic nasal obstruction is turbinate (conchae) hypertrophy. The aim of medical and surgical treatments of turbinate hypertrophy is to decrease the volume of the conchae. Medical professionals have applied several techniques in order to eliminate the nasal obstruction. The ideal technique is to achieve volumetric reductions of the conchae volumes without interrupting the normal function [2]. In many studies

**Figure 2.** The relationship between the volume of the nasal cavity and that of the middle nasal concha.**Figure 3.** The relationship between the volume of the nasal cavity and that of the inferior nasal concha.**Figure 4.** The volume of the middle nasal concha and inferior nasal concha.

researchers have indicated that hypertrophy of inferior conchae is the cause of the nasal obstruction in 20% of cases [1].

Many studies have been conducted on the structure, function, and volume of the nasal cavity [5]. One of the methods recently used in calculating the volume of the nasal cavity is acoustic rhinometry. Although acoustic rhinometry is reported to be an

effective method for predicting the volume of the nasal cavity, it is insufficient for estimating the volume of the posterior part of the nasal cavity [4, 10].

The Cavalieri method is the one of the modern stereological methods enabling secure and effective evaluation of the organs and the volumes of the structures. In this method, the two-dimensional images acquired with CT and/or magnetic resonance are used for three-dimensional volume calculation. The volume calculation can be made with the software of the CT (or magnetic resonance) device that is used to acquire the image. However, in the Cavalieri method, point grid scales are used to calculate the volumes in routine image series. Point grid scales can also be helpful for on-screen studies. This method is an important tool for prospective and retrospective studies [3, 11].

In this study, we calculated the volumes of the nasal cavities and each of the conchae with both the CT technique and the Cavalieri method. According to the data obtained, there was no significant difference in size between the right and left parts of the nasal cavity and the conchae. As expected, the nasal cavity was larger in men than women. Conversely, there was no significant difference between the volumes of the middle nasal concha, which had not been expected.

This study revealed that the volumes of the nasal cavity and the conchae can be calculated on routine coronal CT images without any additional costs. The volume of the studied structure can be calculated in minutes with point grid scales placed on the printed images. Moreover, we believe that the data obtained in this study can help clinicians in the evaluation and planning of treatment of pathological cases.

REFERENCES

1. Cavaliere M, Mottola G, Lemma M (2005) Comparison of the effectiveness and safety of radiofrequency turbinoplasty and traditional surgical technique in treatment of inferior turbinate hypertrophy. *Otolaryngol Head Neck Surg*, 133: 972–978.
2. Cavaliere M, Mottola G, Lemma M (2007) Monopolar and bipolar radiofrequency thermal ablation of inferior turbinates: 20-month follow-up. *Otolaryngol Head Neck Surg*, 137: 256–263.
3. Emirzeoglu M, Sahin B, Selcuk MB, Kaplan S (2005) The effects of section thickness on the estimation of live volume by the Cavalieri principle using computed tomography images. *Eur J Radiol*, 56: 391–397.
4. Kalmovich LM, Elad D, Zaretsky U, Adunsky A, Chetrit A, Sadetzki S, Segal S, Wolf M (2005) Endonasal geometry changes in elderly people: acoustic rhinometry measurements. *J Gerontol*, 60A: 396–398.
5. Kasev KL, Nelson BP, Robert WR, Robert JT, Christian G (1998) Radiofrequency volumetric tissue reduction for treatment of turbinate hypertrophy: a pilot study. *Otolaryngol Head Neck Surg*, 119: 569–573.
6. Kawarai Y, Fukushima K, Ogawa T, Nishizaki K, Gündüz M, Fujimoto M, Masuda Y (1999) Volume quantification of healthy paranasal cavity by three-dimensional CT imaging. *Acta Otolaryngol Suppl*, 540: 45–49.
7. Kim HU, Kim SS, Kang SS, Chung IH, Lee JG, Yoon JH (2001a) Surgical anatomy of the natural ostium of the sphenoid sinus. *Laryngoscope*, 111: 1599–1602.
8. Kim KS, Kim SS, Kang SS, Chung IH, Lee JG, Yoon JH (2001b) Surgical anatomy of the nasofrontal duct: anatomical and computed tomographic analysis. *Laryngoscope*, 111: 603–608.
9. Lee HY, Kim Ch-H, Kim JY, Kim JK, Song MH, Yang H, Kim KS, Chung IH, Lee JG, Yoon JH (2005) Surgical anatomy of the middle turbinate. *Clin Anat*, 196: 493–496.
10. Mayhew TM, O'Flynn P (1993) Validation of acoustic rhinometry by using the Cavalieri principle to estimate nasal cavity volume in cadavers. *Clin Otolaryngol*, 18: 220–225.
11. Sahin B, Emirzeoglu M, Uzun A, Incesu L, Bek Y, Bilgic S, Kaplan S (2003) Unbiased estimation of the liver volume by the Cavalieri principle using magnetic resonance images. *Eur J Radiol*, 47: 165–171.
12. Sapci T, Sahin B, Karavus A, Akbulut UG (2003) Comparison of the effects of radiofrequency tissue ablation, CO₂ laser ablation and partial turbinectomy applications on nasal mucociliary functions. *Laryngoscope*, 113: 514–519.
13. Sato TJ, Murakami G, Tsubota H, Isobe M, Akita K, Kataura A (2000) Morphometric study of the medial aspect of the human maxillary sinus with special reference to the nasal fontanelle. *Auris Nasus Larynx*, 27: 121–130.
14. Yoon JH, Kim KS, Jung DH, Kim SS, Koh KS, Oh CS, Kim HJ, Lee JG, Chung IH (2000) Fontanelle and uncinat process in the lateral wall of the human nasal cavity. *Laryngoscope*, 110: 281–285.