

# Possible usefulness of echocardiographic Z-scores in autopsy routine of the foetal great vessels

A. Grzyb, J. Skrzypecki, A. Koleśnik, C.S. Niszczota

Department of Descriptive and Clinical Anatomy, Centre of Biostructure Research,  
Medical University of Warsaw, Warsaw, Poland

[Received 7 February 2012; Accepted 29 February 2012]

**Background:** Abnormal diameters of foetal vessels are common findings in congenital heart defects. However, it is difficult for pathologist to assess whether the diameters of the vessels are normal or not and to compare with echocardiographic data. The Z-score is a dimensionless quantity representing the distance between the raw score and population mean in standard deviation units. Using Z-score, we can compare single cases to average standards in the population.

**Aim:** To compare diameters of great arteries measured in specimens fixed in 10% formalin solution to normal values obtained on echocardiography using Z-scores.

**Material and methods:** The study was performed on 43 formalin-fixed normal foetal hearts aged from 19 to 40 weeks of gestation. Each specimen was dissected and the following diameters were measured: aortic valve (AoV), ascending aorta (AAo), descending aorta (DAo), aortic isthmus (Aol), ductus arteriosus (DA), pulmonary trunk valve (PV), and pulmonary arteries (RPA and LPA). Z-score parameters were calculated for all structures using the Foetal Echo Z-score Calculator.

**Results:** Z-score values of all measured foetuses were mostly found to fit within the echocardiographic norms, although the most reliable results were obtained for foetuses aged 23 weeks. This group was represented by the highest number of specimens. The minimal and maximal Z-score values were, respectively: AoV –3.45, 1.4; AAo –4.24, –0.11; DAo –2.12, 1.29; PV –3.21, 0.69; RPA –3.4, 0.84; LPA –2.25, 0.31; Aol –1.97, 0.96; DA –3.56, –1.52.

**Conclusions:** The diameters of great arteries measured on autopsy are comparable to the results obtained from echocardiographic measurement. Z-score values for foetal echocardiography can be applied to post-mortem examination. (Folia Morphol 2012; 71, 2: 86–92)

**Key words:** cardiac morphology, foetal anatomy, foetal echocardiography, perinatal autopsy

## INTRODUCTION

Post-mortem examination of the foetal heart is a procedure of a great importance in confirmation of prenatal echocardiographic findings. Due to difficulties with visualisation of the great arteries on

ultrasound, alterations to their morphology are often misdiagnosed in medical centres of prenatal care [31]. Nowadays we can observe development of screening techniques and an increasing number of clinicians performing prenatal diagnostic proce-

dures. In situations when the foetus dies, the findings should be confirmed by autopsy. This is essential not only for educational but also for clinical reasons [21].

All congenital heart diseases can be described by the pathologist using sequential segmental analysis, as described by Anderson et al. [1]. There are many defects where we can observe abnormal diameters of the great vessels, but in borderline cases it is difficult to recognize them by sight alone [5, 18]. Hypoplastic left heart syndrome, coarctation of the aorta, interrupted aortic arch, aortic valve stenosis, and atresia of the pulmonary trunk are easy to diagnose because of other features, for instance ventricular size, morphology, and associated malformations.

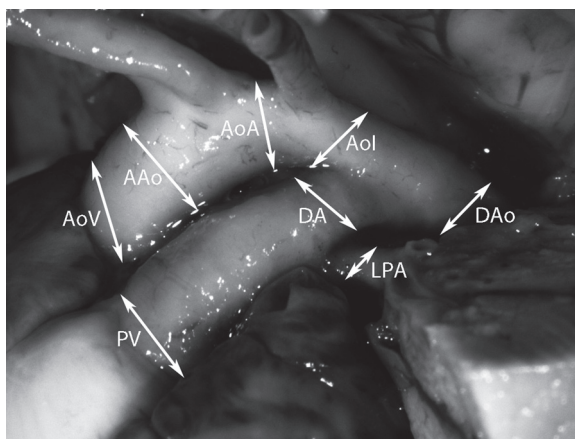
Most ultrasound findings are described using the Z-score value — a statistical parameter expressing the distance between the raw score and the mean in the population [22, 27]. It has been widely applied currently in prenatal and postnatal echocardiography. So far there has been a shortage of data considering foetal autopsy employment. Lack of standardised Z-score for post-mortem examination hinders accurate assessment and impedes information flow between various research centres and between echocardiographers and pathologists.

Percentiles tables are commonly used by clinicians in the evaluation of the normal development of foetuses or children in clinics [33]. Unfortunately they are generally standardised only to gestational age; therefore, cardiac structures cannot be always assessed in foetuses that are too small or too large for their gestational age. Research shows that simple mathematical transformation allows normalisation of Z-score values for cardiac structures to dimensions commonly obtained on echocardiography, e.g. femoral length [18, 27].

The aim of this study was to examine whether there is a significant correlation between measurements of the great vessels performed on echocardiography and post-mortem examination. Potential convergence of this data might allow wider application of Z-Score values established for echocardiographers.

## MATERIAL AND METHODS

The study was based on 43 specimens aged from the 19<sup>th</sup> to the 40<sup>th</sup> week of gestation, fixed in 10% formalin solution. They were derived from the collection of the Department of Descriptive and Clinical Anatomy Centre of Biostructure Research of the Medical University of Warsaw. They were obtained



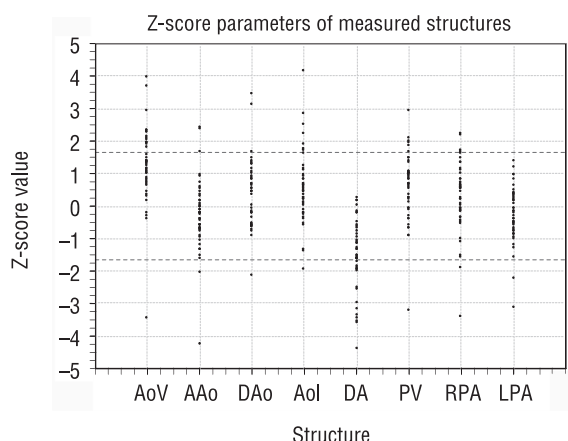
**Figure 1.** The location of measurements performed in the study; AoV — aortic valve; AAo — ascending aorta; AoA — aortic arch; AoI — aortic isthmus; DA — ductus arteriosus; DAo — descending aorta; LPA — left pulmonary arteries; PV — pulmonary trunk valve.

after spontaneous abortion (42 foetuses) or death caused by intrauterine infection (one foetus). No cardiac abnormalities were found on autopsy or in echo. All of them were dissected using microsurgical instruments under stereoscopic microscope SMZ 1500 microscope, and the following dimensions were measured: aortic valve (AoV), ascending aorta (AAo), aortic arch (AoA), aortic isthmus (AoI), ductus arteriosus (DA), pulmonary valve (PV), and right and left pulmonary arteries (RPA and LPA) (Fig. 1). Callipers were used to obtain particular values, and therefore only the external diameter was of interest. Measurements were performed twice and mean diameter was calculated as a final result.

Z-scores were calculated using the Foetal Echo Z-Score Calculator. The database of this calculator is based on population of normal foetal hearts measured by echocardiography. We strived to assess if diameters acquired in post-mortem examination of normal foetal heart, when input to the Echo Z-Score Calculator, would appear to fit within the range of normal values.

## RESULTS

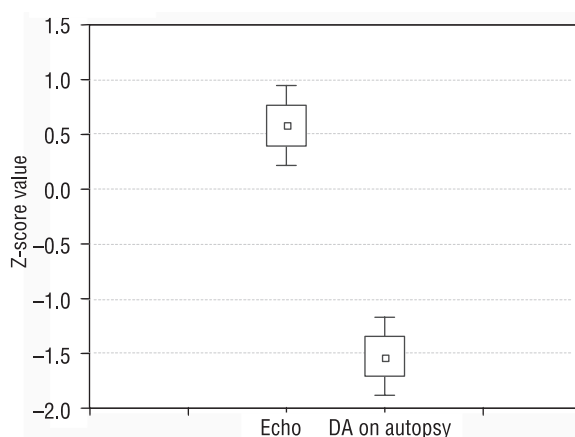
Z-score values of all measured structures except the DA are mostly found within the confidence interval (CI) of  $0.9 \pm 1.645$  (Fig. 2, Table 1). A statistically significant difference ( $p < 0.05$ ) is observed in case of the DA, where calculated Z-scores are remarkably lower (Fig. 3). In this case, the mean Z-score value is comparable to the echocardiographic normal lower limit, and the maximum measured diameter is close to the mean normal value. From the fact that the rest



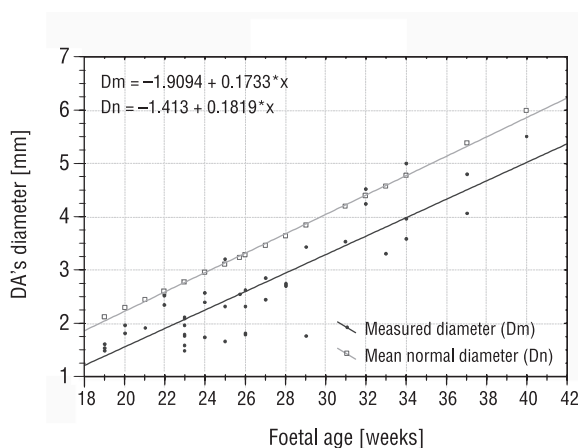
**Figure 2.** Plot showing the distribution of Z-score values of measured structures for all age groups. The horizontal lines represent the confidence interval (CI) of  $0.9 \pm 1.645$  for normal echocardiographic measurement. Remarkably low values are observed for the ductus arteriosus, contrary to other structures, the Z-scores of which mostly fall within the CI; AoV — aortic valve; AAo — ascending aorta; DAo — descending aorta; Aol — aortic isthmus; DA — ductus arteriosus; PV — pulmonary trunk valve; RPA — right pulmonary artery; LPA — left pulmonary artery.

of measured structures, including the Aol, do not show such a tendency, disproportional shrinkage of the DA during the process of specimen fixation in 10% formalin solution can be implied.

As measurements of the DA made on fixed specimens are not reliable, they should be converted using an appropriate mathematical formula. In order to develop it, we plotted mean normal (Dn) and measured (Dm) values of the DA diameter [mm] against foetal age [weeks] and calculated regression equations for both groups (Fig. 4). Subsequently, by combining them, an equation enabling correction of the measured diameters was constructed.



**Figure 3.** Statistically significant difference in ductus arteriosus (DA) diameter measurement.



**Figure 4.** Measured ductus arteriosus (DA) diameters compared to normal values in all age groups. Echocardiographic norms cannot be used directly for the assessment of measurement data collected on post-mortem examination. Raw scores should be corrected using the appropriate mathematical formula. From the analysis of regression equations presented above, an exemplary equation can be developed:  $Dc = 1.0496 * Dm + 0.5911$ , where Dc is the corrected value of the DA diameter.

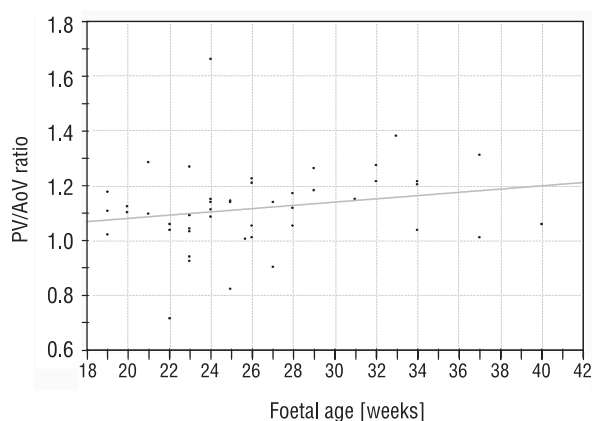
**Table 1.** Extreme and mean values and standard deviation of Z-scores of measured structures for all age groups. Uneven distribution and lowered values observed in the case of the ductus arteriosus

Structure	Measured Z-scores			
	Minimum	Maximum	Mean	Standard deviation
Aortic valve	-3.45	3.96	1.23	1.17
Ascending aorta	-4.24	2.40	-0.33	1.12
Descending aorta	-2.12	3.47	0.34	1.07
Aortic isthmus	-1.97	4.18	0.56	1.13
Ductus arteriosus	-4.41	0.27	-1.53	1.11
Pulmonary trunk valve	-3.21	2.95	0.55	1.07
Right pulmonary arteries	-3.40	2.23	0.26	1.07
Left pulmonary arteries	-3.13	1.39	-0.30	0.88

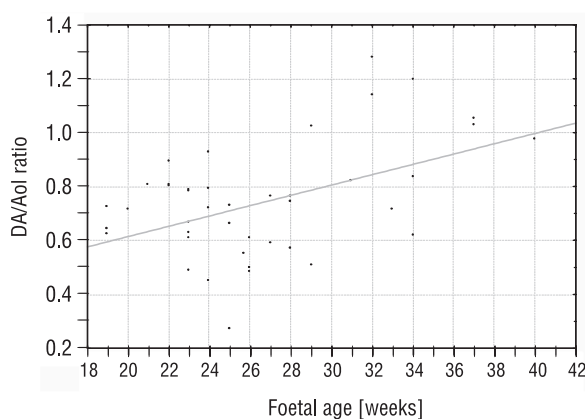
It is:  $D_c = 1.0496 \cdot D_m + 0.5911$ , where  $D_c$  is the corrected value of the DA diameter, which can be compared to echocardiographic norms. However, the number of specimens in the study group imposes certain restrictions over the applicability of the equation. It should not be used when the difference between  $D_m$  and  $D_n$  for the same age is less than 10%. Further studies are needed to make the formula more accurate, especially to determine its dependence on foetal age.

Another method enabling comparison of the measured DA diameter to echocardiographic norms could be by calculating a "shrinkage factor" (SF) defined as the mean [mean normal diameter/measured diameter] ratio. For the data analysed here  $SF = 1.34$ . Therefore,  $D_c$  can be calculated from the formula:  $D_c = SF \cdot D_m = 1.34 \cdot D_m$ . This method, albeit easier, has the same disadvantages as the former one and its precision is even lower.

The results show several correlations between measured structures. There was a linear increase in the diameters of these vessels within the developmental period studied. At the level of arterial valves, the pulmonary trunk diameter was greater than the aortic diameter in all but five cases (42/47). The average PV/AoV ratio value was  $1.12 \pm 0.15$  and the extreme values were 0.71 and 1.66. It showed a slight tendency to increase with age (Fig. 5). The diameter of the RPA was larger than the diameter of the left one in 43/45 specimens with an average RPA/LPA ratio of  $1.23 \pm 0.2$ . The maximum value was 1.78 and the minimum was 0.91; there was no tendency observed. The diameter of the aorta changed over its run, with the aortic isthmus as the narrowest segment (Table 2). The diameter of the Aol was greater than that of the DA in all foetuses aged less than 29 weeks and in only 6/12 foetuses aged from 29 weeks to term (Fig. 6).



**Figure 5.** Pulmonary trunk valve (PV)/aortic valve (AoV) ratio and its changes during pregnancy. The value of the ratio was below 1 only in five cases. A slight tendency to increase with gestational age was observed; however, there is no direct correlation ( $r = 0.2$ ).



**Figure 6.** Ductus arteriosus (DA)/aortic isthmus (Aol) ratio and its changes during pregnancy. In all foetuses below 29 weeks of gestation the mentioned ratio was below 1. After that time, it was greater in half of the cases. Nonetheless, the ratio does not correlate well with gestational age ( $r = 0.47$ ).

**Table 2.** Changes of the aortic diameter over its run. The widest part is at the level of the aortic valve, and then it narrows gradually, with the narrowest segment in the aortic isthmus

	AAo/AoV	Aol/AoV	DAo/AoV
Mean	0.93	0.75	0.87
Standard deviation	0.09	0.10	0.12
Maximum	1.18	0.95	1.15
Minimum	0.72	0.55	0.64

AAo — ascending aorta; AoV — aortic valve; Aol — aortic isthmus; DAo — descending aorta

## DISCUSSION

The use of Z-scores instead of percentiles is currently well established in both foetal and postnatal cardiology [14, 17–19, 22, 23, 27]. By allowing exact, quantitative assessment of obtained data, it constitutes a powerful tool in diagnosis and management of multiple defects of the heart and great vessels. However, to date this system has been developed sufficiently only for the echocardiography. On foetal post-mortem examination of the great arteries there are no such standards available. Therefore, it is very difficult for both pathologists and cardiologists to assess whether the vessel diameters measured on autopsy are normal or not.

Using already available echocardiographic standards for foetal post-mortem study of the great arteries would be very useful; however, they should not be applied recklessly. There are significant differences in examination protocols of such techniques, which can lead to unacceptable mistakes. Firstly, in our study we used standard autopsy technique, measuring the external diameter of vessels. Measurement of the internal diameter, the way it is done on echo, would be discrepant with the routine and bring in additional confusion. Secondly, post-mortem studies are usually performed on specimens fixed in formalin solution, which causes shrinkage of tissues depending on their hydration and content of elastic elements [2, 15].

Our study showed that, despite the mentioned differences, echocardiographic Z-scores can be mostly applied to post-mortem examination. Excluding the diameter of the vessel lumen itself, two variables have an impact on the absolute measured value: the thickness of the vessel wall and its shrinkage ratio in formalin solution. Their influences are contradictory and, apparently, cancel each other to a high degree.

The different shrinkage ratio of the DA compared to other structures may be due to the specific ultrastructure of this vessel and its different response to the process of fixation in formalin. The DA is a muscular artery connecting the pulmonary trunk and the aortic arch, distally to the origin of the left subclavian artery. Its media is abundant in well-differentiated smooth muscle cells (oriented circumferentially) and relatively deficient in elastic elements. The intima forms characteristic cushions composed of proliferating endothelial cells, migrating smooth muscle cells from the media and subendothelial oedema [4, 28, 29]. During pregnancy DA plays the role

of right to left shunt, enabling blood to omit a high-resistance pulmonary vascular bed. It closes after birth together with the foramen ovale, thus separating pulmonary and systemic circulations.

Ductal constriction and functional closure usually occurs by the first 48 hours of postnatal life and is a result of the interaction of several mechanisms [10]. Immediately after birth, the DA is exposed to an increased arterial oxygen tension of about 40–60 mm Hg, compared to 18–28 mm Hg in utero [13]. This leads to constriction of the vessel wall, probably mediated by cytoplasmic calcium release and secretion of endothelin-1 [7, 20]. Moreover, DA produces several vasodilating substances, among which prostaglandin E<sub>2</sub> (PGE<sub>2</sub>) seems to be the most important [7, 20]. Most of the circulating PGE<sub>2</sub> is of placental origin. The main place of its inactivation is the pulmonary vascular bed, constricted during pregnancy. Removal of the placental source, increased metabolism in newly inflated lungs, and decreased number of PGE<sub>2</sub> receptors in the ductal wall causes its constriction in full-term newborns [6, 32].

The sensitivity of the DA to prostaglandins has an important clinical application. In ductal-dependent congenital heart diseases, including e.g. pulmonary atresia/stenosis, tricuspid atresia/stenosis, transposition of the great arteries, coarctation of the aorta, hypoplastic left heart syndrome, critical aortic stenosis, and interrupted aortic arch, it is essential to maintain ductal blood flow after birth, until the improvement of the newborn's condition and adequate surgical intervention. This is usually done by administration of prostaglandin E<sub>1</sub> in form of the preparation named Alprostadil in doses of 0.01–0.1 µg/kg per minute [8, 11].

A structure that is both anatomically and functionally connected with the DA is the AoI, the segment of the aorta located between the left subclavian artery and the DA. It is the most common site for pathological narrowing of the aorta, referred to as coarctation. The reason for this condition is now thought to be the presence of ductal tissue in the wall of the AoI, where it forms a narrow ridge, easily recognisable in histological preparations [12]. In our study, which included only anatomically normal hearts and vessels, the shrinkage ratio of the AoI was not proportional to that of the DA in any case. Therefore, we infer that there was no migration of ductal tissue into the AoI walls within the material studied.

Correlations between the measured structures observed in our study are consistent with the litera-

ture. The growth of vessels with advancing foetal age showed a linear tendency [16, 30, 34]. The diameter of the pulmonary trunk was greater than that of the aorta at the level of the arterial valves in most cases [16, 30, 34]. Similarly, the RPA diameter was greater than LPA diameter [3, 9]. The narrowest segment of the aorta was always the Aol; however, its diameter was still larger than the DA diameter in all foetuses below 29 weeks of gestation. After that age, the DA was greater than the Aol in half of the cases. According to Ursell et al. [34] and Rudolph et al. [24–26], the explanation for such a situation may be as follows. The relative narrowing of the Aol compared to AAO and DAo may result from reduced blood flow through this segment (“flow dependence rule”). Indeed, it is located between the cephalic branches of the aortic arch and the outlet of the DA and carries less blood than adjacent parts. During the last trimester of pregnancy, blood flow to the brain and other parts of the body increases dramatically, which requires growth of the AAO and DA, which outstrips that of the Aol. As a result, the narrowing is accentuated and the DA/Aol diameter ratio may invert.

## CONCLUSIONS

Whereas echocardiographic standards for foetal great vessel measurement are already available and widely used, there is still a paucity of analogous data concerning post-mortem examinations. In this study we tried to determine the applicability of echocardiographic norms in autopsy routines and proved them useful in most of cases. The use of the Z-score method additionally enables more precise quantification of obtained data, when compared to percentiles. However, further studies involving greater numbers of specimens are needed to fully confirm the observed correlation.

## REFERENCES

- Anderson RH, Becker AE, Freedom RM, Macartney FJ, Quero-Jimenez M, Shinebourne EA, Wilkinson JL, Tynan M (1984) Sequential segmental analysis of congenital heart disease. *Pediatr Cardiol*, 5: 281–287.
- Angelini A, Allan LD, Anderson RH, Crawford DC, Chita SK, Ho SY (1998) Measurements of the dimensions of the aortic and pulmonary pathways in the human fetus: a correlative echocardiographic and morphometric study. *Br Heart J*, 60: 221–226.
- Castillo EH, Arteaga-Martinez M, Garcia-Pelaez I, Villasis-Keever MA, Aguirre OM, Moran V, Vizcaino AA (2005) Morphometric study of the human fetal heart. I. Arterial segment. *Clin Anat*, 18: 260–268.
- Chiruvolu A, Jaleel MA (2009) Pathophysiology of patent ductus arteriosus in premature neonates. *Early Hum Dev*, 85: 143–146.
- Christian J, Kellenberger CJ (2010) Aortic arch malformations. *Pediatr Radiol*, 40: 876–884.
- Clyman RI, Brett C, Mauray F (1980) Circulating prostaglandin E2 concentrations and incidence of patent ductus arteriosus in preterm infants with respiratory distress syndrome. *Pediatrics*, 66: 725–729.
- Coceani F, Kelsey L, Seidlitz E (1992) Evidence for an effector role of endothelin in closure of the ductus arteriosus at birth. *Can J Physiol Pharmacol*, 70: 1061–1064.
- Coceani F, Olley PM (1973) The response of the ductus arteriosus to prostaglandins. *Can J Physiol Pharmacol*, 51: 220–225.
- Comstock CH, Riggs T, Lee W, Kirk J (1991) Pulmonary-to-aorta diameter ratio in the normal and abnormal fetal heart. *Am J Obstet Gynecol*, 165: 1038–1044.
- Drayton MR, Skidmore R (1987) Ductus arteriosus blood flow during first 48 hours of life. *Arch Dis Child*, 62: 1030–1034.
- Elliott RB, Starling MB, Neutze JM (1975) Medical manipulation of the ductus arteriosus. *Lancet*, 1: 140–143.
- Elzenga NJ, Gittenberger-de Groot AC (1983) Localised coarctation of the aorta. An age dependent spectrum. *Br Heart J*, 49: 317–323.
- Heymann MA, Rudolph AM (1975) Control of the ductus arteriosus. *Physiol Rev*, 55: 62–78.
- Hornberger LK, Weintraub RG, Pesonen E, Murillo-Olivas A, Simpson IA, Sahn C, Hagen-Ansert S, Sahn DJ (1992) Echocardiographic study of the morphology and growth of the aortic arch in the human fetus observations related to the prenatal diagnosis of coarctation. *Circulation*, 86: 741–747.
- Hornblad PY, Larsson KS (1967) Studies on closure of the ductus arteriosus. *Cardiologia*, 51: 231–41.
- Hyett J, Moscoso G, Nicolaidis K (1995) Morphometric analysis of the great vessels in early fetal life. *Hum Reprod*, 10: 3045–3048.
- Karamlou T, Bernasconi A, Jaeggi E, Alhabshan F, Williams WG, Van Arsdell GS, Coles JG, Caldarone CA (2009) Factors associated with arch reintervention and growth of the aortic arch after coarctation repair in neonates weighing less than 2.5 kg. *J Thorac Cardiovasc Surg*, 137: 1163–1167.
- Lee W, Riggs T, Amula V, Tsimis M, Cutler N, Bronsteen R, Comstock CH (2010) Fetal echocardiography: z-score reference ranges for a large patient population. *Ultrasound Obstet Gynecol*, 35: 28–34.
- Manlhiot C, Millar K, Golding F, McCrindle BW (2010) Improved classification of coronary artery abnormalities based only on coronary artery z-scores after Kawasaki disease. *Pediatr Cardiol*, 31: 242–249.
- Nakanishi T, Gu H, Hagiwara N, Momma K (1993) Mechanisms of oxygen-induced contraction of ductus arteriosus isolated from the fetal rabbit. *Circ Res*, 72: 1218–1228.

21. Onanong N, Boonchai U (2008) Population-related differences in fetal aortic arch dimensions. *Int J Gynecol Obstet*, 102: 72–73.
22. Pasquini L, Mellander M, Seale A, Matsui H, Roughton M, Ho SY, Gardiner HM (2007) Z-scores of the fetal aortic isthmus and duct: an aid to assessing arch hypoplasia. *Ultrasound Obstet Gynecol*, 29: 628–633.
23. Pettersen MD, Wei D, Skeens ME, Humes RA (2008) Regression equations for calculation of z-scores of cardiac structures in a large cohort of healthy infants, children, and adolescents: an echocardiographic study. *J Am Soc Echocardiogr*, 21: 922–934.
24. Rudolph AM ed. (1974) Aortic coarctation and narrowing. In: *Congenital diseases of the heart*. Year Book Medical Publishers, Inc., Chicago, pp. 330–346.
25. Rudolph AM ed. (1974) The fetal circulation. In: *Congenital diseases of the heart*. Year Book Medical Publishers, Inc., Chicago, pp. 2–9.
26. Rudolph AM, Heymann MA, Spitznas U (1972) Hemodynamic considerations in the development of narrowing of the aorta. *Am J Cardiol*, 30: 514–525.
27. Schneider C, McCrindle BW, Carvalho JS, Hornberger LK, McCarthy KP, Daubeney PEF (2005) Development of Z-scores for fetal cardiac dimensions from echocardiography. *Ultrasound Obstet Gynecol*, 26: 599–605.
28. Silver MM, Freedom RM, Silver MD, Olley PM (1981) The morphology of the human newborn ductus arteriosus: a reappraisal of its structure and closure with special reference to prostaglandin E1 therapy. *Hum Pathol*, 12: 1123–1136.
29. Slomp J, Gittenberger-de Groot AC, Glukhova MA, Munsterem JC, Kockx MM, Schwartz SM, Koteliansky VE (1997) Differentiation, dedifferentiation and apoptosis of smooth muscle cells during the development of the human ductus arteriosus. *Arterioscler Thromb Vasc Biol*, 17: 1003–1009.
30. Szpinda M, Brazisa P, Elminowska-Wenda G, Wiśniewski M (2006) Morphometric study of the aortic and great pulmonary arterial pathways in human fetuses. *Ann Anat*, 188: 25–31.
31. Tennstedt C, Hufnagl P, Körner H, Vogel M, Dietel M, Chaoui R (2001) Fetal Autopsy: the most important contribution of pathology in a center for perinatal medicine. *Fetal Diagn Ther*, 16: 384–393.
32. Thorburn GD (1992) The placenta, PGE2 and parturition. In: Sakamoto S ed. *Advances in perinatal medicine*. Elsevier, Amsterdam, pp. 63–73.
33. Ursell PC, Byrne JM, Fears TR (1991) Growth of the great vessels in the normal human fetus and in the fetus with cardiac defects. *Circulation*, 84: 2028–2033.
34. Ursell PC, Byrne JM, Fears TR, Strobino BA, Gersony WM (1991) Growth of the great vessels in the normal human fetus and in the fetus with cardiac defects. *Circulation*, 84: 2028–2033.