

Anatomy and clinical significance of sacral variations: a systematic review

E. Nastoulis¹, M.-V. Karakasi², P. Pavlidis², V. Thomaidis¹, A. Fiska¹

¹Department of Anatomy, School of Medicine, Democritus University of Thrace, Alexandroupolis, Greece

²Laboratory of Forensic Sciences, School of Medicine, Democritus University of Thrace, Alexandroupolis, Greece

[Received: 11 February 2019; Accepted: 15 March 2019]

The sacrum is a large trilateral bone located at the base of the vertebral column serving to transfer the body weight from the trunk to the pelvis and lower extremities. Over the years, an abundance of sacral anatomical divergences has been reported, including numerical and/or morphological variations of sacral entities. The majority of these anatomical alternations has been incidentally identified during radiological investigations, surgical procedures or discovered in anatomical, anthropological and forensic research studies. Throughout international literature, however, there is a scarcity of an integrative recording of all known anatomical variations of the sacrum in a single study. This constitutes the objective of the present paper: to provide an exhaustive systematic review of the relevant literature, as well as to thoroughly describe all the recognised deviations of the sacrum structure, while highlighting the aspects of their clinical significance. (Folia Morphol 2019; 78, 4: 651–667)

Key words: sacral variations, sacrum, anatomical variations, sacral hiatus variations, sacral foramina pairs

INTRODUCTION

The sacrum regarded as the keystone of the human body, is important because it forms a link between the spine and the iliac bones and has a vital role to play in hip stability. It is also called the “holy bone,” a translation from the Greek “hieron ostoun” (ιερόν οστόν). The term “hieron” was first recorded in the book “On the Articulations” of the Hippocratic Collection (ca 400–250 BC), in order to describe the sacral bone [42]. There are several explanations of the appellation “sacred” or “holy”, including the suggestion that it was used in ancient rituals, as it was believed to be necessary for resurrection (religious belief borrowed from the ancient Egyptians). Furthermore, on the grounds that “hieron” also means “temple” in ancient Greek, it has been proposed that perhaps the sacrum was believed to be the sanctuary of the genitalia [112].

Regarding sacral variations, Galen of Pergamon (129–217 BC) in his work “On the use of the parts” (De usu partium) described the anatomy of human sacrum and suggested that it comprises of four bones [34]. On the other hand, Andreas Vesalius illustrated a six-piece sacrum [121]. Leonardo da Vinci (1452–1519) was the first to correctly describe the sacrum as being composed of five vertebrae [36]. Bardeen (1904–1905) on the other hand was the first to describe the development and numerical variations of the embryonic sacrum [9, 10].

In time, numerous anatomical divergences of the sacrum have been documented. The detailed knowledge of anatomical variations is very important for medical education because they could change symptoms and physical examination and could cause changing operation techniques during surgeries. Clinical awareness of known and newly discovered an-

Address for correspondence: E. Nastoulis, MD, forensic pathologist, doctoral student, School of Medicine, Democritus University of Thrace, Dragana, 68100, Alexandroupolis, Evros Prefecture, Greece, tel: +30 6972524316, fax: +30 25513 53824, e-mail: nastevang@yahoo.gr

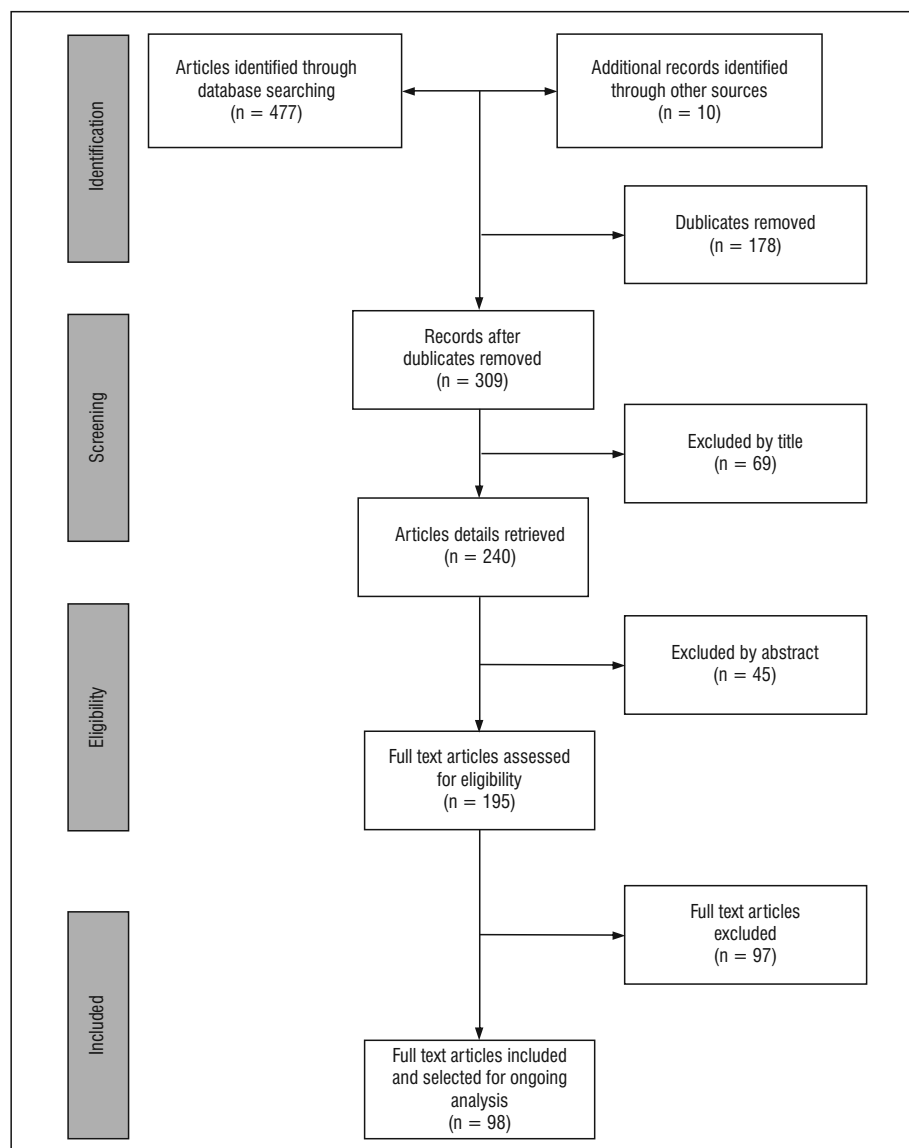


Figure 1. Flow diagram for the search and selection process developed using PRISMA guidelines.

atomical variations which can be achieved through a frequent review of the literature is the key to a successful outcome in the clinical setting. The present study aims to investigate all reported sacral variations, as well as their integrative classifications, taking into account any possible clinical significance.

METHODOLOGY

Search strategy

An exhaustive systematic review was carried out on the anatomical and clinical significance of sacral variations. Our systematic review was developed according to the Preferred Reporting Items for Sys-

tematic reviews and Meta-Analysis (PRISMA) guidelines [63]. Electronic databases searched included PubMed, Google search, Google Scholar, Heal Link, EMBASE, Scopus and Cochrane Library up to September 2018. The search terms were: "sacral variations," "sacrum," "variations," "sacrum anatomy," "sacral hiatus variations," "sacral canal variations," "sacrum congenital anomalies," and "sacral foramina pairs." Papers containing original data were selected and secondary references retrieved from bibliographies. A flow diagram for the search and selection process developed using PRISMA guidelines is presented in the Figure 1.

Ethical issues

This review is part of a doctoral dissertation and has been approved by the Research and Ethics Committee of Democritus University of Thrace, Faculty of Medicine (serial number: 480δτ-10/10/2014). There is no funding agency for this study. Only previously published data included in this systematic review.

Eligible criteria (inclusion-exclusion)

The search was largely based on anatomical studies but important and selected imaging studies were also consulted. Due to the long history of anatomical studies regarding sacral variations, we didn't set date limit. The search was mainly restricted to English language but significant foreign language papers were included. Studies with unclear anatomical descriptions and incomplete or missing results were excluded.

Study selection

The titles and abstracts identified through the search strategy described above reviewed independently by two authors. A third reviewer resolved any discrepancies between the two reviewers. Two additional reviewers completed the same process for full texts, with a third reviewer who resolved discrepancies.

Data extraction

Data extracted included: author name, publication year, number of total sample, ethnicity/race of sample, gender, type of study (anatomical/radiological), percentage (%) of sacral variation type. Data extraction was made by one reviewer and repeated by a second reviewer to check and verify the findings and accuracy of the results. Any disagreements in data extraction were resolved through discussion between the reviewers so there was 100% agreement. All data were extracted into an electronic data base and created nine tables with results (Tables 1–9).

RESULTS

More than 60-year-old anatomical research studies on adult sacral variations exist in the international literature. During the last decade, an increased interest in the research of sacral divergences has been noted, due to their clinical significance in caudal epidural anaesthesia and surgical procedures in the sacral area. In the present paper, anatomical variations of the sacrum have been classified in three main

categories: 1 — numerical variations, 2 — morphological variations, and 3 — rare (unclassified) variations.

Numerical variations

Most anatomical variations in the lumbosacral area are associated with differences in the sacral vertebrae or sacral foramina pairs number, caused either by the fusion of the fifth lumbar or the first coccygeal vertebra with the sacrum or by the dissociation of the first sacral vertebra from it.

Variations in the number of sacral vertebrae — lumbosacral transitional vertebrae

Lumbosacral transitional vertebrae (LSTV) are hereditary disorders of the lumbosacral region which involve either the transition of the first sacral vertebra to a lumbar arrangement (lumbarisation of S1) or the assimilation of the fifth lumbar vertebra to the sacrum (sacralisation of L5) [43]. When the L5 vertebra is completely fused to the sacrum, the lumbar spine is consisted of four vertebrae and six vertebrae constitute the sacrum, while when S1 is completely separated from the sacrum, the lumbar spine is consisted of six lumbar vertebrae (four sacral vertebrae exist). Several intermediate variations are also reported. In 1917, Bertolotti [14] was the first to describe the morphological characteristics of the LSTV and was the first to relate LSTV to low back pain (Bertolotti syndrome). The distinction, between ossification defect and developmental defect is challenging, as both result in the same anatomical formation of LSTV. The inter-population prevalence of LSTV throughout international literature ranges from 4% to over 35% [17, 31, 43]. In a meta-analysis of 22 studies from 1986 to 2007, the mean prevalence of LSTV was approximately 12.3%. Regarding the categorisation of LSTV into lumbarisation and sacralisation, a mean prevalence of 5.5% and 7.5% was respectively noted [17]. Sacralisation is considered a more frequent anatomical deviance compared to lumbarisation. The wide range observed in LSTV prevalence, except from the different genetic factors of the investigated population's samples may also be explained by the different imaging techniques and the different classification systems. Several attempts of classifying LSTV are present in the literature [11, 18, 97].

Variations in the number of sacral foramina pairs

The normal sacrum has four pairs of anterior (pelvic) and posterior (dorsal) sacral foramina, which

Table 1. Research studies on the prevalence of numerical variations of sacral foramina pairs

Author	Total sample of dry adult sacra	Ethnicity/race	5 pairs of sacral foramina	3 pairs of sacral foramina
Kubavat (2012) [54]	189	India (Western Region)		3 (1.58%)
Nagar (2012) [75]	302	India	51 (16.9%)	
Khana (2013) [51]	80	India	6 (7.5%)	4 (5%)
Deepa (2014) [24]	117	India (South Region)		2 (1.7%)
Goswami (2014) [38]	80	India (North Region)	2 (2.5%)	2 (2.5%)
Singh (2014) [105]	66	India	11 (16.6%)	
Kumar (2015) [56]	50	India (South Region)	1 (2%)	1 (2%)
Kumar (2015) [57]	82	India	3 (3.65%)	2 (2.43%)
Shingh (2015) [104]	30	India		2 (6.7%)
Laishram (2016) [59]	155	India	31.61%	1.93%

communicate with the sacral canal and are run through by the respective sacral nerves (S1–S4) [21].

The anatomical variants of lumbar or coccygeal sacralisation result into five pairs of sacral foramina. The reported prevalence varies from 2% to 16.9% (Table 1). Regarding coccygeal vertebrae sacralisation, there is a lack of available data within relevant literature. According to Singh, the fifth sacral foramina pair, formed due to coccygeal sacralisation, is run through by a fifth pair of sacral and coccygeal nerves. Furthermore, Singh [105] classified sacra with five pairs of foramina into five categories.

On the other hand, the occurrence of three sacral foramina pairs develops due to failure of fusion of the first sacral vertebra (lumbarisation). The estimated prevalence ranges from 1.58% to 6.7% (Table 1, Fig. 2).

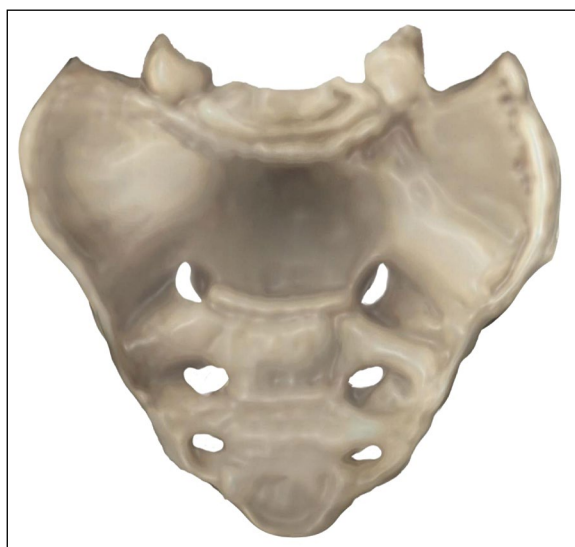Finally, in literature have been described rare cases of sacrum with six foramina pairs which formed by the simultaneous fusion of fifth lumbar with the first sacral vertebra at the cranial end and the first coccygeal vertebra with the apex of sacrum at the caudal end [108].

Morphological variations

Numerous sacral developmental malformations and morphological divergences exist, varying from slight deviations in the sacral hiatus to sacral (caudal) agenesis.

Sacral defects

Minor scale sacral impairment is a common finding and thus is often overlooked. In a report examining the radiographs of 100 patients with urinary

**Figure 2.** Numerical variations in sacral foramina pairs: three pairs of sacral foramina.

incontinence, 43 individuals had various minor sacral deformities [35].

According to Stanley et al. [110], the evidence of Lendon (1968) [62], supports the contention, that in practice the sacral defects fall into three definite patterns:

- Group I — Absent Vertebra (Sacral Agenesis);
- Group II — Hemivertebra (Dysgenesis — hemisacrum). Sometimes this sacral impairment is associated with butterfly vertebrae in the thoracolumbar spine;
- Group III — Deficiencies of the neural arch (Dysraphic — sacral spina bifida with meningocele or myelomeningocele).

Table 2. Research studies on the incidence of sacral spina bifida occulta

Author	Sample-Method	Percentage	Most common level
Lawrence (1977) [61]	1389 pelvic X-rays	4%	S1-S2
Fidas (1987) [32]	2707 urinary X-rays	22%	L5-S2
Schweitzer (1993) [98]	108 abdominal X-rays	17%	L5-S2
Avrahami (1994) [7]	1200 X-rays, CT scans	17%	S1
Wu (2009) [123]	203 dry sacra visual inspection	28.1%	S1-S2
Ali (2014) [5]	200 dry sacra	34.5%	S1-S2

CT — computed tomography

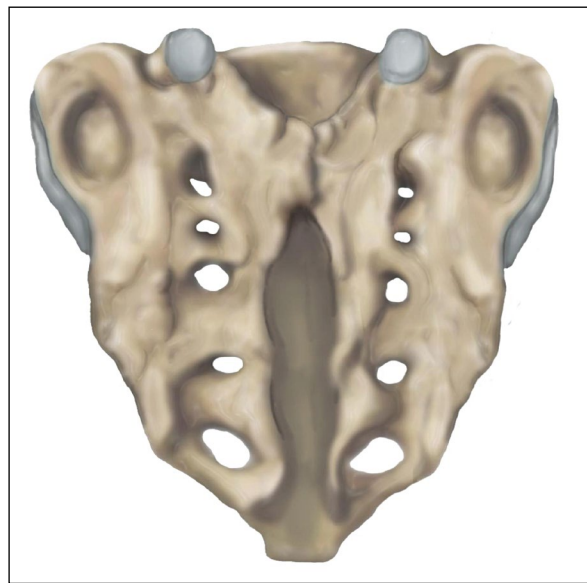
Sacral agenesis. Sacral agenesis is a severe form of abnormal development of sacrum. As a clinical expression of the caudal regression syndrome (CRS), it is a rare disorder with an incidence ranging from approximately 0.01 to 0.05 per 1000 live births [73]. Its occurrence, however, escalates twofold to threefold among mothers suffering from diabetes mellitus [110]. In 1961, Bernard Duhamel [27] first coined the term “caudal regression syndrome” in order to describe a congenital disorder presenting with anomalies of the rectum, urinary bladder, genital system, lumbosacral spine and lower extremities. Several attempts of classifying the CRS are present in the literature, based on the degree of sacral agenesis [39, 81, 92].

Sacral spina bifida. Spina bifida is a developmental defect resulting from the inadequate closure of the neural tube during the early embryonic period [73].

Sacral spina bifida (SSB) may be divided in two types: *Sacral spina bifida cystica* — in this category, the meninges and/or the spinal cord contents project through the abnormal opening in the skin covering sacral region (myelomeningocele) and *Sacral spina bifida occulta* (SSBO) — in this category, the meninges and/or neural tissue remain “hidden” underneath the intact skin (Fig. 3) [96].

Sacral meningoceles represent approximately 20% of total SSB incidence. Furthermore, the anterior sacral meningocele was reported to relate with the Currarino Syndrome or Triad that involves: sacral bone defect, presacral mass, and anorectal malformations [23]. Additionally, “scimitar sacrum,” a smooth curved unilateral sacral deformity that simulates the shape of Arabic sabre on plain X-ray, is considered to be pathognomonic of anterior sacral meningocele [4].

Wu et al. [123] and Singh et al. [106] classified SSBO according to the degree of the sacral canal closure impairment.

**Figure 3.** Sacral spina bifida occulta, second degree.

Research papers concerned with the prevalence of sacral spina bifida occulta are summarised in Table 2.

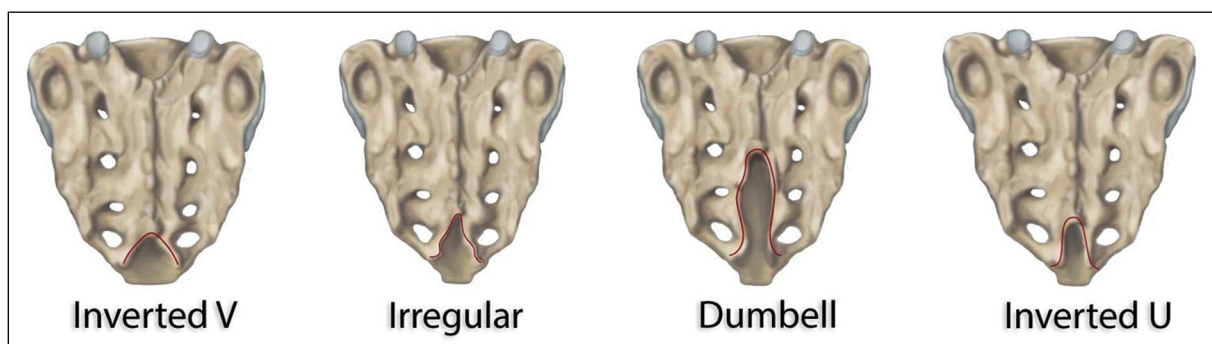
Variations in the morphology of sacral hiatus

The sacral hiatus is created by the failure of fusion of the fifth and occasionally the fourth sacral vertebra laminae. The sacral hiatus apex may vary in shape, from an inverted U or V, to irregular or dumbbell shapes. Table 3 presents a comparison of the formations of the sacral hiatus between different reports.

Most research studies have been conducted on samples of dry adult sacra originating from India. Nagar’s work examined the largest research sample ($n = 270$). It is noteworthy that the most frequent shape of the sacral hiatus apex among Nigerians, Kenyans and Egyptians is an inverted V, while among Indians inverted U is the most common shape (Fig. 4).

Table 3. Pivotal table and comparative presentation among different research studies concerning the shapes of the sacral hiatus.

Author	N (dry adult sacra)	Ethnicity/ Race	Inverted "U"	Inverted "V"	Irregular	Dumbbell	Bifid
Kumar (1992) [58]		India	46.53%	29.7%			
Nagar (2004) [75]	270	India	73 (27%)	112 (41.5%)	38 (14.1%)	36 (13.3%)	4 (1.5%)
Patel (2011) [83]	150	India	74 (49.3%)	30 (20%)		6 (4%)	
Njihia (2011) [78]	88	Kenya	(16.7%)	(32.1%)	(19%)	(31%)	
Seema (2013) [99]	149	India	64 (42.95 %)	41 (27.51%)	24 (16.10%)	20 (13.41%)	
Suwanlikhid (2013) [113]	253	Thailand	128 (54.47%)	46 (19.57%)	26 (11.06%)	5 (2.13%)	9 (3.83%)
Shewale (2013) [102]	204	India	83 (40.69%)	66 (32.35%)	19 (9.31%)	12 (5.89%)	2 (0.98%)
Phalgunan (2013) [85]	30	India	10 (35%)	10 (35%)	8 (28%)		
Bhattacharya (2013) [15]	100	India	65 (65%)	23 (23%)	12 (12%)		
Nasr (2014) [77]	150	Egypt	47 (31.33%)	58 (38.66%)	23 (15.33%)	18 (12%)	4 (2.66%)
Mayuri (2014) [69]	118	India	50 (42.37%)	32 (27.11%)	19 (16.1%)	15 (12.71%)	2 (1.69%)
Rajeev (2014) [90]	254	India	107 (42.12 %)	90 (35.43%)	33 (12.99%)	10 (4.00%)	14 (5.51%)
Osunwoke (2014) [80]	54	Nigeria	13 (24.1%)	18 (33.1%)	7 (13%)	5 (9.3%)	3 (5.6%)
Kamal (2014) [45]	172	Bangladesh	65 (38.00%)	60 (35.10%)	26 (15.20%)	9 (5.30%)	1 (0.60%)
Nadeem (2014) [74]	100	Caucasians leaving in Germany	56 (56%)	14 (14%)	16 (16%)	10 (10%)	2 (2%)
Malarvani (2015) [68]	100	Nepal	35 (35%)	32 (32%)	14 (14%)	3 (3%)	2 (2%)
Vasuki (2016) [120]	75	India	27 (36%)	15 (20%)	15 (33%)	16 (23%)	3 (3%)
Laishram (2016) [59]	155	India	(39.35%)	(16.77%)	(24.51%)	(7.091%)	
Bagheri (2017) [8]	87	Turkey	29 (33.3%)	17 (19.45%)	17 (19.45%)	6 (6.9%)	3 (3.45%)

**Figure 4.** Morphological divergence of the sacral hiatus.

The localisation of the sacral hiatus apex varies between S2 and S5 levels, ranging from 39% to 72%. Most frequent locus is at the S4 level (Table 4).

The localisation of the sacral hiatus base extends from the S4 level to the coccyx with a range from 54% to 91% and most frequent locus at S5 (Table 5).

Complete absence of the sacral hiatus may be induced either by bony overgrowth or complete fusion

of the laminae of the fourth and fifth sacral vertebrae (Fig. 5). Sacral hiatus absence is clinically significant, as it is one of the anatomical reasons for caudal epidural anaesthesia failure. Absence of sacral hiatus appeared in 4% of a Japanese population sample and in 6.25% of a Turkish sample group [100, 101]. In addition, absence of sacral hiatus was noted in 1.96% and 0.7% of Indian population groups, in two different studies [75, 102].

Table 4. Pivotal table and comparative presentation among different research studies concerning the anatomical localisation of the apex in relation to the level of sacral vertebrae

Author	N (dry adult sacra)	Ethnicity/Race	S2	S3	S4	S5
Nagar (2004) [75]	270	India	9 (3.4%)	98 (37.3%)	147 (55.9%)	9 (3.4%)
Patel (2011) [83]	150	India	1 (0.66%)	40 (26.6%)	89 (53.3%)	19 (12.67%)
Seema (2013) [99]	149	India	6 (4.02%)	53 (35.57%)	84 (56.36%)	6 (4.02 %)
Suwanlikhid (2013) [113]	253	Thailand	3 (1.18%)	41 (16.2%)	148 (58.4%)	38 (15.01%)
Shewale (2013) [102]	204	India	8 (4%)	30 (15%)	133 (66%)	29 (14.5%)
Phalgunan V (2013) [85]	30	India	2 (7.1%)	13 (46%)	13 (46%)	
Bhattacharya (2013) [15]	100	India		5 (5%)	72 (72%)	23 (23%)
Nasr (2014) [77]	150	Egypt	2 (1.33%)	22 (14.66%)	81 (54.00%)	41 (27.33%)
Mayuri (2014) [69]	118	India	5 (4.23%)	42 (35.39%)	67 (56.77%)	4 (3.38%)
Rajeev (2014) [90]	254	India	14 (5.60%)	45 (17.71%)	153 (60.23%)	42 (16.53%)
Osunwoke (2014) [80]	54	Nigeria	3 (5.6%)	11 (20.4%)	36 (66.6%)	4 (7.4%)
Kamal (2014) [45]	172	Bangladesh	8 (4.70%)	52 (30.40%)	103 (60.20%)	8 (4.70%)
Nadeem (2014) [74]	100	Caucasians leaving in Germany	2 (2%)	62 (62%)	34 (34%)	2 (2%)
Malarvani (2015) [68]	100	Nepal	3 (3%)	42 (42%)	39 (39%)	13 (13%)
Vasuki (2016) [120]	75	India	2 (3%)	32 (43%)	36 (48%)	4 (5%)
Bagheri (2017) [8]	87	Turkey	1 (1.15%)	9 (10.34%)	61 (71.11%)	10 (11.49%)

Table 5. Pivotal table and comparative presentation among different research studies concerning the anatomical localisation of the sacral base in relation to the level of sacral vertebrae

Author	N (dry adult sacra)	Ethnicity/race	S4	S5	Coccyx
Nagar (2004) [75]	270	India	29 (11.1%)	191 (72.6%)	43 (16.3%)
Patel (2011) [83]	150	India	16 (10.67%)	119 (79.33%)	
Seema (2013) [99]	159	India	20 (13.42%)	105 (70.46%)	24 (16.10%)
Suwanlikhid (2013) [113]	253	Thailand	19 (7.50%)	180 (71.14%)	22 (8.69%)
Shewale (2013) [102]	204	India	4 (2%)	164 (82%)	32 (16%)
Nasr (2014) [77]	150	Egypt	18 (12%)	105 (70%)	27 (18%)
Rajeev (2014) [90]	254	India	11 (4.33%)	191 (75.19%)	54 (21.25%)
Osunwoke (2014) [80]	54	Nigeria	6 (11.1%)	32 (59.3%)	16 (29.6%)
Kamal (2014) [45]	172	Bangladesh	1 (0.60%)	156 (91.20%)	14 (8.20%)
Nadeem (2014) [74]	100	Caucasians leaving in Germany	62 (62%)	24 (24%)	14 (14%)
Malarvani (2015) [68]	100	Nepal	31 (31%)	54 (54%)	1 (1%)
Vasuki (2016) [120]	75	India	12 (16%)	48 (64%)	15 (20%)
Bagheri (2017) [8]	87	Turkey	2 (2.3%)	72 (82.76%)	7 (8.05%)

Interestingly, the mean length of the sacral hiatus (from the apex to the midpoint of base) among Indian population studies, ranged from 11 to 20 mm, in a Turkish population study from 31 to 40 mm and in a Nigerian population study from 21 to 30 mm (Table 6) [80, 101].

Variations have also been reported in the anteroposterior diameter of the sacral canal at the level of apex, with the mean range between 4 and 6 mm (Table 7).

Variations in the morphology of the sacral canal — complete dorsal wall agenesis of sacral canal

The shape of the sacral canal is triangular to oval in sagittal view. It extends from the level of the upper border of S1 to the sacral hiatus, posterior to the sacral vertebrae bodies. The sacral canal encloses the cauda equina, including the filum terminale and the spinal meninges. The dura and arachnoid mater

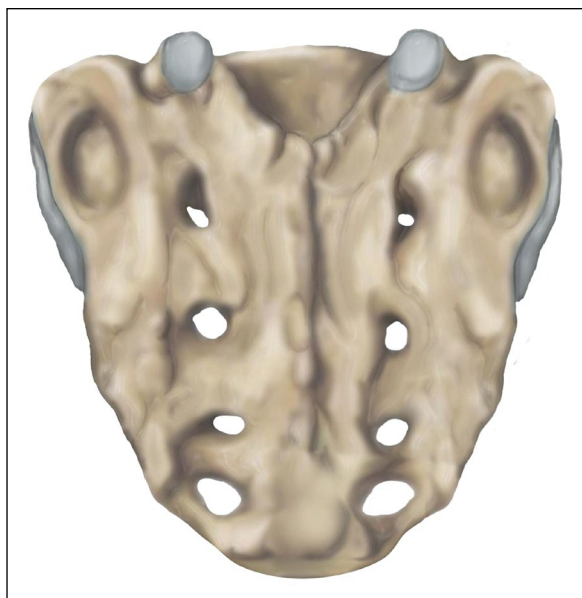


Figure 5. Absence of sacral hiatus.

terminate at the level of S2; this level also varies between the lower border of the S1 foramen among adults and S3 among children. At this end point they fuse into one layer, while the pia mater progresses to the coccyx as filum terminale. Numerous divergences occur in the dorsal wall of the sacral canal, including its complete agenesis. 263 dry adult sacra of Indian individuals were examined by Nagar [75], among which the complete agenesis of the dorsal wall of the sacral canal was detected in 4 (1.5%) cases. Previous research studies had reported complete dorsal wall agenesis in 1.18% of an American population sample, while similar results were reached (1.49%) among Indian women [58, 118]. The prevalence rates of dorsal wall agenesis range from 1.18% to 7.1% (Table 8).

In regard to incidence comparison between genders, the occurrence of the complete agenesis of the dorsal wall is more frequent among males [3].

Few studies have investigated the volume variations of the sacral canal. An early anatomical study, which was conducted by Lanier and Trotter [60], suggested that the volume of sacral canal in a European population using rising of fluid in the vertebral column was slightly more than 30 mL (range from 12 to 65 mL). In a recent study, the mean recorded volume of the sacral canal in an Indian population sample was 38.26 mL (range from 23.67 to 62.78 mL) [6].

Table 6. Pivotal table and comparative presentation of different research studies regarding the length of sacral hiatus from the apex to the midpoint of base

Length [mm]	Author											
	Nagar (2004) [75]	Senoglou (2005) [101]	Shewale (2013) [102]	Seema (2013) [99]	Phalgunan (2013) [85]	Suwalnikhid (2013) [113]	Mayuri (2014) [69]	Nasr (2014) [77]	Rajeev (2014) [90]	Osunwoke (2014) [80]	Parashuram (2015) [82]	Vasuki (2016) [120]
	n	%	n	%	n	%	n	%	n	%	n	%
0–10	27	10.3	11	5.5	11.4	25	10.6	13	11.0	12	8	36.6
11–20	92	35	80	40	34.8	134	57.0	41	34.7	55	23	11.9
21–30	81	30.8	74	37	29.5	60	25.5	35	29.6	45	89	45.9
31–40	45	17.1	21	10.5	16.7	10	4.2	20	16.9	25	67	34.5
41–50	13	4.9	10	05	4.6	5	2.1	5	4.2	7	12	6.2
> 51	05	1.9	04	02	2.6	1	0.4	4	3.3	2	2	1.0
										3.7	1	0.5
											1	1

Table 7. Pivotal table and comparative presentation of different studies regarding the anteroposterior diameter of the sacral canal

Diameter [mm]	Author																	
	Nagar (2004) [75]		Seema (2013) [99]		Shewale (2013) [102]		Phalgunan (2013) [85]		Nasr (2014) [77]		Rajeev (2014) [90]		Mayuri (2014) [69]		Parashuram (2015) [82]		Vasuki (2016) [120]	
	n	%	n	%	n	%	n	%	n	%	n	%	n	%	n	%	n	%
0–3	4	15.6	8	5.36	15	7.50			28	18.66	27	10.62	6	5.08	58	29.9	35	47
4–6	169	64.2	107	71.81	152	76	16	57	91	60.66	201	79.13	84	71.18	132	68.1	31	42
7–8	52	19.8	33	22.14	32	16	11	39	31	20.66	25	9.84	26	22.03	4	2.1	7	9
> 9	1	0.4	1	0.67	1	0.5	1	3.5	0	0.0	01	0.40	2	1.69	0	0.0	1	1

Table 8. Research studies examining the incidence of complete dorsal wall agenesis (CDWA) of the sacral canal in different population groups

Author	N*	Ethnicity/ /race	CDWA
Nagar (2004) [75]	263	India	4 (1.5%)
Senoglou (2005) [101]	96	Turkey	2 (2.08%)
Patel (2011) [83]	150	India	4 (2%)
Seema (2013) [99]	159	India	5 (3.14%)
Suwvanlikhid (2013) [113]	235	Thailand	1 (0.43%)
Phalgunan (2013) [85]	30	India	2 (7.1%)
Shewale (2013) [102]	204	India	2 (0.98%)
Nasr (2014) [77]	150	Egypt	4 (2.66%)
Osunwoke (2014) [80]	54	Nigeria	4 (1.5%)
Nagendrappa (2014) [76]	100	India	3 (3%)
Shinde (2014) [103]	100	India	2 (2%)
Malarvani (2015) [68]	100	Nepal	3 (3%)
Akhtar (2015) [3]	116	India	3 (2.58%)

*Dry adult sacra

Variations in the morphology of sacral cornua (horns)

These remnants of the inferior articular processes, progressing bilaterally downwards on both sides of the sacral hiatus, are the most commonly-used palpable bony landmarks for the sacral hiatus identification during caudal epidural block (CEB). Sacral cornua morphological divergences range from well-defined projections to flattened patterns and their morphological variability greatly affects locating the sacral hiatus.

In a sample of dry adult sacra, the occurrence of bilaterally prominent sacral cornua was 55.6% and of bilaterally flattened cornua 21.5% [2]. These findings were in contrast with a previous report that detected 21% bilaterally prominent sacral cornua in isolated

dry sacra and bilaterally flattened sacral cornua in more than 50% [100]. The authors suggested that sacral cornua are inadequate as a bony landmark and thus cannot be utilised in CEB in 21.5–50% of the population. Furthermore, in a research study of 300 multidetector computed tomography (MDCT) images, bilateral plane cornua were found in 3%, unilateral plane cornua in 5%, bilateral short cornua in 7%, and unilateral short cornua in 15.3% [52]. In addition, sacral cornua were examined through three-dimensional computed tomography (3D CT) images in children and they were bilaterally absent in 3.5% and unilaterally absent in 4.2% [53].

Variations in the morphology of the first sacral (S1) vertebra

Anatomical findings associated with the morphometry and anatomical divergences of the first sacral vertebra (S1) are seldom encountered throughout international literature, despite their clinical importance. Sex-dependent differences have been noted in the male and female first sacral vertebra. It is considered that the corpus of primary sacral segment of first sacral vertebra of females is relatively smaller and lateral section (costal parts and wings) is relatively larger [93]. A magnetic resonance imaging (MRI) study of 61 patients revealed that coronal plane dimensions in 9 (14.8%) patients were disproportionately smaller compared to transverse plane dimensions, with a varying size of S1 and S2 body, a fact that makes an effective surgical procedure difficult [48]. Reviewing 1200 X-rays and CT scans of Israeli people sacra concluded that 17% of them presented spina bifida occulta (SBO) at the first sacral vertebra [7]. Furthermore, rare anatomical variations of the first sacral vertebra have been described throughout international literature and they are reported in the next section.

Accessory auricular surface

The presence of supernumerary — accessory sacroiliac joints (ASIJ) or accessory auricular surfaces (AAS), with varying locations, is documented in several reports and classified into two types by Hadley: a) the “superficial” ASIJ localised between the posterior superior iliac spine and the lateral sacral crest, opposite to the second sacral foramen, and b) the “deep” ASIJ situated between the large roughened tuberosity of the ileum and the lateral crest of sacrum opposite the first posterior sacral foramen [40]. In 7 out of 9 skeletons of Americans with ASIJ, the articular facets were localised in the area of the lateral sacral tuberosity at the level of the second sacral foramen and on the medial surface of the posterosuperior iliac spine. The joint was unilateral in 5 and bilateral in 3 cases [30]. In a research study examining a Turkish sample group, ASIJ was located between the iliac and the sacral articular surfaces at the posterior portion of sacroiliac joint, ranging from the level of the first to the second sacral foramen. ASIJ was detected unilaterally in 11.5% and bilaterally in 6.0% of the cases [25]. In another study, Wu et al. [123] observed more AAS locations in Chinese population, in posteriorsuperior crest or apex of AS and in posteroinferior part of AS. The prevalence of AAS varies in different population groups from 3.6% to over 40% (Table 9).

Variations in sacral curvature and inclination

Sacral curvature is represented by the angle between the first and last sacral vertebrae. It is a primary curvature that develops during the foetal period and differentiates between genders [87]. Male sacral curvature is more evenly distributed over the whole length of the bone and is generally greater compared to females [95]. Several reports agree that the curvature index is greater in males as compared to females (Curvature Index = mid-ventral straight length \times 100 / mid-ventral curved length) [55].

Variations in sacral curvature are frequently observed ranging from sacrum planum (flattened) to sacrum arcuatum (markedly curved). The location of maximum sacral curvature is at S3 level in 64.7% of cases [22]. Furthermore, after the age of 60, sacral curvature may become more evident [86].

Sacral skewness

During their research in Chinese population, Wu et al. [123] coined a new sacral variable under the

Table 9. Research studies examining the incidence of accessory auricular surface (AAS) in different population groups

Author	N*	Method	AAS
Trotter (1940) [117]	953	Dry adult skeletons	40%
Solonen (1957) [109]	30	Dry adult skeletons	8%
Ehara (1988) [30]	100	CT	13%
	56	Dry adult skeletons	16%
Valojerdy (1990) [119]	153	Dry adult skeletons	16%
Prassopoulos (1999) [88]	534	CT	19.1%
Demir (2007) [25]	400	CT	17.5%
Fortin (2009) [33]	559	Post-arthrography CT	3.6%
Wu (2009) [123]	203	Dry adult sacra	12.3%

*Total sample number; CT — computed tomography

term of “sacral skewness.” According to the authors, sacral skewness is defined as a developmental asymmetry of the sacrum in which the middle sagittal line of the pelvic face skews rightward or leftward. They examined a sample group of 208 Chinese adult dry sacra, among which sacral skewness was detected in 48 subjects (23.6% incidence) [123]. Most of the sacral skewness turned right, while the direction of sacral skewness turned to the smaller side. However, no other anatomical research studies on sacral skewness are available, and thus, the causal factors and clinical significance of this anatomical divergence is still to be explored (Fig. 6).

Multiple variations

In their study, Wu et al. [123] detected multiple sacral variations in 42 (20.7%) subjects. It was the first study to systematically investigate the occurrence of more than one morphological divergence in the same sacrum and identified nine combinations of multiple variations:

- a) AAS in combination with lumbar sacralisation (LS);
- b) AAS in combination with sacral spina bifida occulta (SSBO);
- c) AAS plus sacral skewness;
- d) S1 lumbarisation in combination with sacral SBO;
- e) S1 lumbarisation in combination with sacral skewness;
- f) LS plus SSBO;
- g) LS plus sacral skewness;
- h) SSBO in combination with sacral skewness;
- i) AAS plus LS plus sacral skewness.

Research findings of the study indicated that lumbar sacralisation combined with sacral skewness

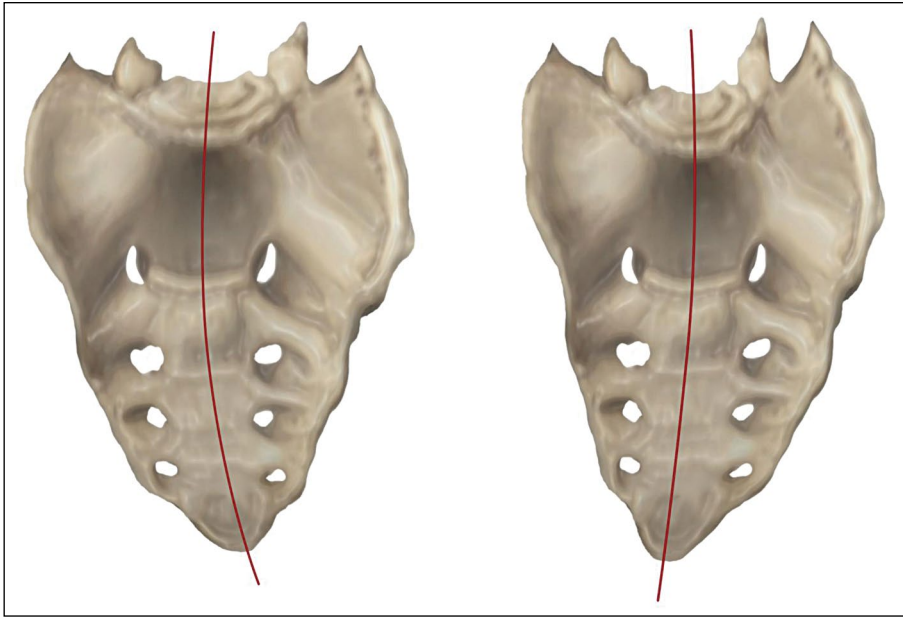


Figure 6. Sacral skewness, left and right.

were the most frequently occurring combination of sacral variations. It is also noteworthy that three types of multiple variations, (a), (c), and (e), were detected only in male dry sacra. Furthermore, no combination of more than three variations was recorded.

In a recent study examining 300 dry sacra a five-group classification and coding system was presented, based on the common variations observed in the context of the number of sacral segments, the position of the auricular surfaces and the type of neural arch components [37, 67].

Rare variations of the sacrum

Sacral rib

Supernumerary ribs may occur at any level of the spine, but are most commonly observed in the cervical and lumbar areas, while they are extremely rare in the sacral area (sacral ribs) [28]. According to the available data, only 9 cases of sacral rib have been reported. Sacral rib is a congenital deformity that is composed of an osseous configuration arising in soft tissue around the sacrum [91]. The flawed fusion of the primordial rib with the vertebral centres of the sacrum is the cause of the sacral-rib formation. It is usually asymptomatic and is often detected incidentally on radiographs. Two thirds of reported cases involve females. Sacral rib may be a factor of complications during delivery [72].

Butterfly S1 vertebra

Butterfly vertebra or sagittal cleft vertebra is a rare congenital abnormality, which is characterised by flawed convergence of the chondrification centres of the vertebral body during embryogenesis [49]. Very few cases of butterfly vertebra have been reported throughout international literature and only two cases refer to sacral vertebrae alone; Boulet et al. [16] were the first to report a novel case of S1 sagittal cleft vertebra occurring with space narrowing at L5-S1 level, while Kapetanakis et al. [47] described a case of S1 butterfly vertebra with dorsal projection of the hemivertebrae within the sacral canal, causing stenosis of the left lateral recess and compression of left S1 nerve root.

Foramen Rajani

Rajani Singh and her students detected an oval foramen on the posterior surface of the left sacral ala, which communicated with the first sacral foramina and sacral canal. It was also possible that various structures (such as the common iliac artery or vein, lumbosacral trunk and sympathetic chain) could run through this foramen [107].

Rare bony development on the S1

Chauhan and Kalra [19] reported an unprecedented case of unusual osseous growth on the ventral aspect of a male sacrum. The bony development of

approximately 5 × 4 cm mainly arose from the left half of S1 body. The most probable cause of this rare developmental abnormality was assumed to be the overgrowth of the ventral ossification centre. Symptomatology from the gastrointestinal and genitourinary system is likely to result from such a large osseous deformity on the ventral aspect of the sacrum due to rectum and sympathetic chain compression, leading to constipation, as well as bladder and bowel dysfunction [19].

DISCUSSION

Clinical significance of sacral variability

The detailed knowledge of sacral anatomical divergences and morphometric data is of paramount significance for various medical specialists (orthopaedic surgeons, neurosurgeons, neurologists, urologists, anaesthesiologists, obstetricians, radiologists, forensic doctors and all surgical specialties operating in close proximity to the vertebral column).

Clinical significance in orthopaedic surgery — radiology

Almost a century ago, Bertolotti first suggested a correlation between lumbosacral transitional vertebrae (LSTV) and low back pain (LBP). Since then, similar studies were conducted, indicating that LSTV increase the probability of LBP, while others suggested that there is not greater frequency compared with the general population. In a systematic review of 22 observational studies, a positive association was found between LBP and LSTV in four studies, while no association was indicated in five studies. LSTV patients often present various secondary pathological conditions of the spine due to the mechanical alterations of the area, such as spinal canal or foraminal stenosis, intervertebral disc herniation and facet joint degeneration and arthrosis [17]. In a single study, Taskaynatan et al. [116] reported that 4.3% of patients with LBP were diagnosed with SSBO, with co-occurrence of LSTV and SSBO in 2 patients.

Moreover, it is suggested that coccygeal sacralisation may result in coccydynia [105]. In the first systematic study of the sacrococcygeal cornual region anatomy, Woon et al. [122] recorded unilateral or bilateral cornual fusion in 20–45% of adults. They observed that among subjects with unfused cornua, the gap was bridged by an intercornual ligament, which is innervated, and thus, it may pose a possible source of coccygeal pain, as well. The knowledge of anatomical

divergences and mechanical changes of lumbosacral area certainly assists a deeper understanding of the findings in patients with LBP or coccydynia.

As previously mentioned, the anatomical variations of the sacrum, although infrequently described, present significant clinical liaison with various surgical specialties operating in the sacral area. S1 transpedicular screw fixation and iliosacral screw fixation are frequently performed for the treatment of numerous medical conditions, involving lumbar burst fractures, lumbar scoliosis, spondylolisthesis and metastatic, infectious or traumatic diseases affecting the sacrum [26, 70, 124]. Pedicle screw fixation of the first sacral vertebra remains a challenging procedure due to uniqueness and variability of the S1 anatomy. Injuries to the pedicle cortex, nerve root, facet joint and adjacent vital structures may be caused by a misplaced or misdirected pedicle screw [12, 29, 79, 124, 125]. Numerous sacral deformities with elevation of the upper sacral segments have been reported to have caused problems to S1-screw insertions (up to 33%) [41, 70].

In regard to iliosacral screw fixation, which is a procedure for the stabilisation of pelvic fractures, various complications have been reported, despite the existence of many radiographic-guidance techniques. Sacral variations, especially in the iliosacral area, demand thorough anatomic knowledge and pose great difficulties in the accurate placement of the screws, even under radiographic control. Even if the screw placement is guided by fluoroscopy, CT or computer-navigated techniques, disadvantages arise in each radiographic technique [70, 71, 126]. In a recent study, Khan et al. [50] suggested that percutaneous iliosacral screw fixation for pelvic ring injuries with the use of intraoperative CT scanners such as the O-arm surgical imaging system has been associated with decreased procedure time and improved accuracy of iliosacral screw placement, compared with the use of fluoroscopic guidance. Especially, in cases with difficult anatomy, 3D imaging and navigation minimizes the risk of screw malposition [50].

Complications from incorrect iliosacral screw fixation can occasionally have serious consequences, including neurological deficits, implant failure and the need for a second surgery [41, 94]. Among 104 CT scans of injured pelvises, sacral deformities were detected in 41%, and presented an increased risk of cortical perforation during the iliosacral screw fixation procedure at the occurrence of upper sacral segment dysplasia [44].

It should be mentioned that radiologists and surgeons use different methods for lumbar vertebrae measurements; radiologists commonly count downwards from the last rib, while surgeons count upwards from the sacrum. Both labelling methods of lumbar vertebrae are correct, but confusion can be caused in cases of LSTV.

Clinical significance in anaesthesiology

Determining the exact morphology and variations of sacrum with the use of radiographic methods is important to avoid complications in epidural or spinal anaesthesia at a wrongly assumed level [17]. Caudal epidural anaesthesia or block (CEB) is commonly used for pain relief during the first and second stages of labour and is advantageous compared to general anaesthesia as the anaesthetic drugs do not affect the infant. Among adult patients, CEB is also chiefly administered to control chronic pain, while in children CEB is the most widely practiced regional anaesthesia technique due to its suitability for intraoperative and postoperative analgesia. One of the most important key factors for the successful management of CEB is the correct identification of the sacral hiatus as the insertion of the needle into the sacral canal should penetrate the sacral hiatus after puncturing the sacrococcygeal ligament. Anatomical variations of the sacrum are a serious impediment to caudal epidural space identification, even for experienced clinicians. Therefore, thorough knowledge of the sacral-hiatus anatomy plays a pivotal role in avoiding unintended subdural, subarachnoid and intravenous drug injection and dural injury [2].

As already mentioned, the most important osseous landmarks for CEB are sacral hiatus and sacral cornua, which may not only vary in shape and size, but may also be hard to palpate, particularly in obese patients. Therefore, anaesthesiologists make use of other prominent anatomical landmarks in order to perform CEB, such as (a) the triangular area formed between the posterior superior iliac spines (superolateral sacral crests) and the apex of sacral hiatus as well as (b) the triangular area formed between the posterior superior iliac spines and sacral apex, which are generally considered as equilateral. These triangles, however, should not be deemed equilateral *ipso facto*. Their dimensions differentiate with the occurrence of variations in the posterior surface of the sacrum, resulting in confusion about the reference points of anaesthesia. Specifically, these triangles

were reported to be equilateral (a) between the superolateral sacral crests and the apex of sacral hiatus at a rate ranging from 14.2% to 29% according to the studies of Phalgunan and Baskaran [85] and Patil et al. [84], respectively, and (b) between the posterior superior iliac spines and apex of sacrum in 51% of the cases [2].

International bibliographical references report occurrence of incorrect needle insertion in up to 36% of cases, even among experts, leading to intra-osseous drug aspiration and toxicity [89]. In order to reduce the risk of dural puncture and other severe complications, the knowledge of the anatomical distance between the sacral hiatus and dural sac is of great significance in CEB. The needle should be promoted less than 5 mm ahead after permeating the sacrococcygeal membrane, while it is safer to be inserted through the base which is more distant from S2. According to Aggarwal et al. [2], the minimum distance from S2 to the apex of sacral hiatus is estimated to be 7.25 mm. Furthermore, the optimal needle-length has to be carefully selected, as a long needle increases the risk of dural puncture.

Another clinically important dimension is the antero-posterior diameter of sacral canal at the apex of sacral hiatus, as it should fit the needle. The diameter of the sacral canal is less than 2 mm in 1% of sacral bones, thus inhibiting the use of 22 G needles [100]. In addition, the available caudal epidural space volume must be estimated preoperatively, so that high block complications are avoided [6]. Ultrasound is a safe, non-invasive and simple method of examination of the exact sacral anatomy, identification of sacral variations and accurate estimation of the volume of epidural space [1]. The use of ultrasonography for the navigation of needle placement into the caudal epidural space increases success rates by 100% [20].

When CEB is contraindicated, the trans-sacral epidural block is used as an alternative method of anaesthesia in the sacral area for surgical procedures in the rectal, anal and urethral regions or for cancer pain relief in these regions [84]. This procedure is performed through the dorsal sacral foramina, the numerical or morphological variations of which may be a causative factor for complications or failure.

Clinical significance in obstetrics

The potential effects of anatomical variations in female sacrum on labour have scarcely been reported. Regarding obstetrics, the diameters of the pelvic

outlet, pelvic inlet, and midpelvis are assessed so that it is determined whether sufficient capacity exists for vaginal delivery [13]. Pelvimetry (measurement of these diameters) can be conducted with the use of CT (which is the most accurate method), radiography, or pelvic (clinical) examination [13]. The measurement of the distance between the sacral promontory and the inner pubic arch of the pubic symphysis is important for the estimation of the obstetrical conjugate, which should be at least 11 cm. Obstetricians may use the method of palpation, of the sacral promontory, which also means that the accuracy of the obstetrical-conjugate measurement can be influenced by morphological variations of the sacrum, and especially of LSTV variations.

In a recent study Mahato [66] suggested that structural alterations identified in female LSTV sacrum may change dorsal pelvic dimensions and the availability of dorsal pelvic space, potentially altering the biomechanics of normal labour.

Moreover, the backward movement of coccyx during the second stage of labour increases the antero-posterior diameter of the pelvic outlet and assists the progress of delivery. In cases of coccygeal-vertebra sacralisation, however, the coccyx becomes fixed leading to prolonged second stage of labour and perineal tears [105, 114].

Variations in sacral curvature and inclination have an impact on the relationship of the lower sacrum and sacrococcygeal platform to the ischial spines, thus altering the shape of the pelvic outlet. Steer [111] in 1975 attempted to depict the effects of lower sacral variations on the pelvic outlet in the treatment of pelvic arrest by using several case studies. Cephalopelvic disproportion of a narrow pelvis (dystocia) can be diagnosed, in which delivery by caesarean section is indicated [64].

Clinical significance in forensic sciences

Regarding forensics, anatomical variations and congenital sacrum abnormalities used for human identification purposes have rarely been published. Forensic experts encounter sacral variations occasionally during the examination of skeletal remains. Hospital records can be retrieved and matched with the condition observed variation during the forensic examination, facilitating the identification of the deceased. Kanchan et al. [46] reported a case in which the discovery of a LSTV during medicolegal exam-

ination of skeletal remains facilitated the forensic identification of the deceased.

Tanaka et al. [115] described another case in which human remains were detected in a house where an old man had lived alone. An examination of the skeleton disclosed an extra lumbar vertebra and sacralisation of the sixth lumbar vertebra (type IIB) as distinguishing features. However, in that case the relevant medical records were not found (maybe because the LSTV was asymptomatic), and the identification process was conducted through DNA examination. Subsequently, the comparison of ante-mortem and postmortem medical data on sacral variations can be a significant tool to forensic experts [115].

Finally, for stature estimation in forensic cases with sacralisation of lumbar vertebra, the height of the actual S1 segments should be included in the calculation or the height of the extra vertebra added to the stature estimate [65].

CONCLUSIONS

The sacrum presents with an abundance of anatomical divergences involving numerical variations of the sacral vertebrae, diversities in sacral morphology, as well as other atypical alterations. Throughout international literature, there is a lack of an integrative recording of the known anatomical variations of the sacrum in a single study. Clinical awareness of known and newly discovered anatomical variations is the key to successful result in the clinical setting.

The present paper is a systematic review of the relevant and most current literature as well as the first known attempt of systematic recording and indexing of all known variants of the sacrum. The main anatomical variations of the sacrum found in the bibliographic survey are the LSTV and variations in the morphology of sacral hiatus. However, in depth knowledge of sacral variations is vital to avoid complications in surgery, anaesthetics and obstetrics as well as in forensic identification procedures.

Acknowledgements

The authors gratefully acknowledge for his expert assistance Dr. Mazinis Emmanouil in the preparation of figures throughout the completion of the study.

This review is part of a doctoral dissertation and has been approved by the Research and Ethics Committee of Democritus University of Thrace — Faculty of Medicine (serial number: 480δτ-10/10/2014).

REFERENCES

- Abukawa Y, Hiroki K, Morioka N, et al. Ultrasound versus anatomical landmarks for caudal epidural anesthesia in pediatric patients. *BMC Anesthesiol.* 2015; 15: 102, doi: [10.1186/s12871-015-0082-0](#), indexed in Pubmed: [26169595](#).
- Aggarwal A, Aggarwal A, Sahni D. Morphometry of sacral hiatus and its clinical relevance in caudal epidural block. *Surg Radiol Anat.* 2009; 31(10): 793–800, doi: [10.1007/s00276-009-0529-4](#), indexed in Pubmed: [19578805](#).
- Akhtar J, Madhukar K, Fatima N, et al. A morphometric study of complete agenesis of dorsal wall in human sacrum. *Indian J Applied Res (IJAR).* 2015; 5(4): 449–451.
- Alappat JP. Scimitar sacrum. *Neurol India.* 2004; 52(2): 288, indexed in Pubmed: [15269512](#).
- Ali S, Azeemi A, Shoukat S. The prevalence of spina bifida occulta in Pakistani population: A study of dry human sacra. *Anaesth, Pain Intensive Care.* 2014; 18(2): 157–161.
- Asghar A, Naaz S. The volume of the caudal space and sacral canal in human sacrum. *J Clin Diagn Res.* 2013; 7(12): 2659–2660, doi: [10.7860/JCDR/2013/6287.3724](#), indexed in Pubmed: [24551603](#).
- Avrahami E, Frishman E, Fridman Z, et al. Spina bifida occulta of S1 is not an innocent finding. *Spine.* 1994; 19(1): 12–15, doi: [10.1097/00007632-199401000-00003](#), indexed in Pubmed: [8153797](#).
- Bagheri H, Govsa F. Anatomy of the sacral hiatus and its clinical relevance in caudal epidural block. *Surg Radiol Anat.* 2017; 39(9): 943–951, doi: [10.1007/s00276-017-1823-1](#), indexed in Pubmed: [28247084](#).
- Bardeen CR. Numerical vertebral variations in the human adult and embryo. *Anat Anz.* 1904; 25: 497–519.
- Bardeen CR. Studies of the development of the human skeleton. A. The development of the lumbar, sacral and coccygeal vertebrae. *Am J Anat.* 1905; 4: 265–302.
- Barnes E. Developmental defects of the axial skeleton in paleopathology. University Press of Colorado 1994.
- Başaloğlu H, Turgut M, Taşer FA, et al. Morphometry of the sacrum for clinical use. *Surg Radiol Anat.* 2005; 27(6): 467–471, doi: [10.1007/s00276-005-0036-1](#), indexed in Pubmed: [16211321](#).
- Beckman C, Ling F. Obstetrics and gynecology. Sixth Ed. ACOG 2010.
- Bertolotti M. Contributo alla conoscenza dei vizi differenziazione regionale del rachid con speciale riguardo all'assimilazione sacrale ed alla v lombare. *La Radiologia Medica.* 1917; 4: 113–144.
- Bhattacharya S, Majumdar S, Chakraborty P, et al. A morphometric study of sacral hiatus for caudal epidural block among the population of West Bengal. *IJBAMR.* 2013; 7(2): 660–667.
- Boulet C, Schiettecatte A, De Mey J, et al. Case report: imaging findings in a. *Acta Neurol Belg.* 2011; 111(4): 344–348, indexed in Pubmed: [22368979](#).
- Bron JL, van Royen BJ, Wuisman PI. The clinical significance of lumbosacral transitional anomalies. *Acta Orthop Belg.* 2007; 73(6): 687–695, indexed in Pubmed: [18260478](#).
- Castellvi AE, Goldstein LA, Chan DP. Lumbosacral transitional vertebrae and their relationship with lumbar extradural defects. *Spine.* 1984; 9(5): 493–495, doi: [10.1097/00007632-198407000-00014](#), indexed in Pubmed: [6495013](#).
- Chauhan P, Kalra S. A rare osseous growth on sacrum. *Int J Anat Var.* 2010; 3: 218–219.
- Chen CPC, Tang SFT, Hsu TC, et al. Ultrasound guidance in caudal epidural needle placement. *Anesthesiology.* 2004; 101(1): 181–184, doi: [10.1097/00005542-200407000-00028](#), indexed in Pubmed: [15220789](#).
- Cheng JS, Song JK. Anatomy of the sacrum. *Neurosurg Focus.* 2003; 15(2): E3, indexed in Pubmed: [15350034](#).
- Crighton IM, Barry BP, Hobbs GJ. A study of the anatomy of the caudal space using magnetic resonance imaging. *Br J Anaesth.* 1997; 78(4): 391–395, doi: [10.1093/bja/78.4.391](#), indexed in Pubmed: [9135359](#).
- Currarino G, Coln D, Votteler T. Triad of anorectal, sacral, and presacral anomalies. *AJR Am J Roentgenol.* 1981; 137(2): 395–398, doi: [10.2214/ajr.137.2.395](#), indexed in Pubmed: [6789651](#).
- Deepa TK, John M. A study of lumbarisation of first sacral vertebra among the South Indians. *Int J Med Res Health Sci.* 2014; 3(1): 1–4, doi: [10.5958/j.2319-5886.3.1.001](#).
- Demir M, Mavi A, Gümüşburun E, et al. Anatomical variations with joint space measurements on CT. *Kobe J Med Sci.* 2007; 53(5): 209–217, indexed in Pubmed: [18204297](#).
- Diel J, Ortiz O, Losada RA, et al. The sacrum: pathologic spectrum, multimodality imaging, and subspecialty approach. *Radiographics.* 2001; 21(1): 83–104, doi: [10.1148/radiographics.21.1.g01ja0883](#), indexed in Pubmed: [11158646](#).
- Duhamel B. From the mermaid to anal imperforation: the syndrome of caudal regression. *Arch Dis Child.* 1961; 36(186): 152–155, doi: [10.1136/adc.36.186.152](#), indexed in Pubmed: [21032381](#).
- Dunaway CL, Williams JP, Brogdon BG. Case report 222. Sacral and coccygeal supernumerary ribs (pelvic ribs). *Skeletal Radiol.* 1983; 9(3): 212–214, indexed in Pubmed: [6844944](#).
- Ebraheim NA, Xu R, Biyani A, et al. Morphologic considerations of the first sacral pedicle for iliosacral screw placement. *Spine.* 1997; 22(8): 841–846, doi: [10.1097/00007632-199704150-00002](#), indexed in Pubmed: [9127914](#).
- Ehara S, el-Khoury GY, Bergman RA. The accessory sacroiliac joint: a common anatomic variant. *Am J Roentgenol.* 1988; 150(4): 857–859, doi: [10.2214/ajr.150.4.857](#), indexed in Pubmed: [3258099](#).
- Erken E, Ozer HTE, Gulek B, et al. The association between cervical rib and sacralization. *Spine.* 2002; 27(15): 1659–1664, doi: [10.1097/00007632-20020810-00013](#), indexed in Pubmed: [12163729](#).
- Fidas A, MacDonald HL, Elton RA, et al. Prevalence and patterns of spina bifida occulta in 2707 normal adults. *Clin Radiol.* 1987; 38(5): 537–542, doi: [10.1016/s0009-9260\(87\)80150-2](#), indexed in Pubmed: [3311565](#).
- Fortin JD, Ballard KE. The frequency of accessory sacroiliac joints. *Clin Anat.* 2009; 22(8): 876–877, doi: [10.1002/ca.20772](#), indexed in Pubmed: [19173249](#).
- Galen. De usu partium, ed. G. Helmreich, Galeni de usu partium libri xvii. Leipzig: Teubner, 1:1907; 2:1909 (repr. Amsterdam: Hakkert, 1968), (Cod: 202,076: Med.).
- Galloway NT, Tainsh J. Minor defects of the sacrum and neurogenic bladder dysfunction. *Br J Urol.* 1985; 57(2): 154–155, doi: [10.1111/j.1464-410x.1985.tb06410.x](#), indexed in Pubmed: [3986449](#).
- Gansemann Y, Broos P. Leonardo da Vinci and Andreas Vesalius; the shoulder girdle and the spine, a comparison. *Acta Chir Belg.* 2008; 108(4): 477–483, indexed in Pubmed: [18807610](#).
- García-Coronado JM, Espinosa-Urbe AG, Vélchez-Cavazos F, et al. Comments on: Implications of structural variations in the human sacrum: why is an anatomical classification crucial? *Surg Radiol Anat.* 2017; 39(2): 233, doi: [10.1007/s00276-016-1724-8](#), indexed in Pubmed: [27431439](#).
- Goswami P, Yadav Y, Chakradhar V. Sacral Foramina: Anatomical variations and clinical relevance in North Indians. *Eur J Acad Essays (EJAE).* 2014; 1(4): 29–33.
- Guille JT, Benevides R, DeAlba CC, et al. Lumbosacral agenesis: a new classification correlating spinal deformity and ambulatory potential. *J Bone Joint Surg Am.* 2002; 84(1): 32–38, doi: [10.2106/00004623-200201000-00006](#), indexed in Pubmed: [11792777](#).

40. Hadley LA. Accessory sacroiliac articulations with arthritic changes. *Radiology*. 1950; 55(3): 403–409, doi: [10.1148/55.3.403](#), indexed in Pubmed: [14781347](#).
41. Hasenboehler EA, Stahel PF, Williams A, et al. Prevalence of sacral dysmorphism in a prospective trauma population: Implications for a. *Patient Saf Surg*. 2011; 5(1): 8, doi: [10.1186/1754-9493-5-8](#), indexed in Pubmed: [21569232](#).
42. Hippocrate. *Des Articulations*, ed. É. Littré, Oeuvres complètes d'Hippocrate, vol. 4. Baillière, Paris 1844.
43. Hsieh CY, Vanderford JD, Moreau SR, et al. Lumbosacral transitional segments: classification, prevalence, and effect on disk height. *J Manipulative Physiol Ther*. 2000; 23(7): 483–489, doi: [10.1067/mmt.2000.108817](#), indexed in Pubmed: [11004653](#).
44. Kaiser SP, Gardner MJ, Liu J, et al. Anatomic determinants of sacral dysmorphism and implications for safe iliosacral screw placement. *J Bone Joint Surg Am*. 2014; 96(14): e120, doi: [10.2106/JBJS.M.00895](#), indexed in Pubmed: [25031382](#).
45. Kamal A, Ara S, Ashrafuzzaman Md, et al. Morphometry of sacral hiatus and its clinical relevance in caudal epidural block. *J Dhaka Med Coll*. 2015; 23(1): 31–36, doi: [10.3329/jdmc.v23i1.22690](#).
46. Kanchan T, Shetty M, Nagesh KR, et al. Lumbosacral transitional vertebra: clinical and forensic implications. *Singapore Med J*. 2009; 50(2): e85–e87, indexed in Pubmed: [19296021](#).
47. Kapetanakis S, Giannopoulou E, Nastoulis E, et al. Butterfly vertebra. A case report and a short review of the literature. *Folia Morphol*. 2016; 75(1): 117–121, doi: [10.5603/FM.a2015.0066](#), indexed in Pubmed: [26365862](#).
48. Karachalios T, Zibis AH, Zintzaras E, et al. An anatomical update on the morphologic variations of S1 and S2. *Orthopedics*. 2010; 33(10): 733, doi: [10.3928/01477447-20100826-12](#), indexed in Pubmed: [20954663](#).
49. Katsuura Y, Kim HJo. Butterfly vertebrae: a systematic review of the literature and analysis. *Global Spine J*. 2019; 9(6): 666–679, doi: [10.1177/2192568218801016](#), indexed in Pubmed: [31448202](#).
50. Khan JM, Lara DL, Marquez-Lara A, et al. Intraoperative CT and surgical navigation for iliosacral screws: technique for patients with sacral dysmorphism. *J Orthop Trauma*. 2018; 32 Suppl 1: S24–S25, doi: [10.1097/BOT.0000000000001213](#), indexed in Pubmed: [29985900](#).
51. Khanna J, Chauhan R. Anatomical variations and clinical relevance of dorsal sacral foramina in North Indians. *Int J Res Med Sci*. 2013; 1(3): 263–266, doi: [10.5455/2320-6012.ijrms20130820](#).
52. Kilicaslan A, Keskin F, Babaoglu O, et al. Morphometric analysis of the sacral canal and hiatus using multidetector computed tomography for interventional procedures. *Turk Neurosurg*. 2015; 25(4): 566–573, doi: [10.5137/1019-5149.JTN.10942-14.0](#), indexed in Pubmed: [26242333](#).
53. Kim DW, Lee SJ, Choi EJ, et al. Morphologic diversities of sacral canal in children; three-dimensional computed tomographic study. *Korean J Pain*. 2014; 27(3): 253–259, doi: [10.3344/kjp.2014.27.3.253](#), indexed in Pubmed: [25031811](#).
54. Kubavat D, Nagar S, Lakhani C, et al. A study of sacrum with three pairs of sacral foramina in western India. *IJMSH*. 2012; 1(2): 127–132, doi: [10.5455/ijmsph.2012.127-131](#).
55. Kumar A, Vishwakarma N. An anthropometric analysis of dry human sacrum: Gender Discrimination. *IJSR*. 2015; 4(4): 1306–1310.
56. Kumar P, Lokanadham S, Kothandaraman U. A study of anterior sacral foramina and their variations in South Indian population. *Sch J App Med Sci*. 2015; 3(3): 1196–1198.
57. Kumar KP, Dhoot M, Thaduri N, et al. A study of sacrum with five pairs of sacral foramina in Bhopal population. *IJPBBA*. 2015; 4(5).
58. Kumar V, Pandey SN, Bajpai RN, et al. Morphometrical study of sacral hiatus. *J Anat Soc India*. 1992; 41(1): 7–13.
59. Laishram D, Ghosh A, Shastri D. A study on the variations of sacrum and its clinical significance. *IOSR- JDMS*. 2016; 15(6): 8–14.
60. Lanier PF, Trotter M. The volume of the sacral canal. *Am J Phys Anthropol*. 1946; 4(2): 227–234, indexed in Pubmed: [20990836](#).
61. Lawrence JS. *Rheumatism in Populations*. William Heinemann Medical Books, London 1977.
62. Lendon RG. Studies on the embryogenesis of spina bifida in the rat. *Dev Med Child Neurol*. 1968; Suppl(16): 54–61, doi: [10.1111/j.1469-8749.1968.tb04847.x](#), indexed in Pubmed: [4896359](#).
63. Liberati A, Altman DG, Tetzlaff J, et al. The PRISMA statement for reporting systematic reviews and meta-analyses of studies that evaluate healthcare interventions: explanation and elaboration. *BMJ*. 2009; 339: b2700, doi: [10.1136/bmj.b2700](#), indexed in Pubmed: [19622552](#).
64. Lierse W. *Applied Anatomy of the Pelvis*. Springer-Verlag Berlin Heidelberg 1984.
65. Lundy JK. Sacralization of a sixth lumbar vertebra and its effect upon the estimation of living stature. *J Forensic Sci*. 1988; 33(4): 1045–1049, indexed in Pubmed: [3171499](#).
66. Mahato NK. Transitional female sacrum: dimensions, alterations in dorsal pelvic structure, and potential obstetric implications. *Oman Med J*. 2018; 33(1): 22–28, doi: [10.5001/omj.2018.05](#), indexed in Pubmed: [29467995](#).
67. Mahato NK. Implications of structural variations in the human sacrum: why is an anatomical classification crucial? *Surg Radiol Anat*. 2016; 38(8): 947–954, doi: [10.1007/s00276-016-1667-0](#), indexed in Pubmed: [27014779](#).
68. Malavani T, Ganesh E, Nirmala P, et al. Study of sacral hiatus in dry human sacra in Nepal. *Int J Anat Res*. 2015; 3(1): 848–855, doi: [10.16965/ijar.2014.527](#).
69. Mayuri J, Vijay G, Vasudha N, et al. Anatomical Study Of Sacral Hiatus In Dry Isolated Sacra. *J Res Med Den Sci*. 2014; 2(2): 43–46, doi: [10.5455/jrmds.20142210](#).
70. Mendel T, Noser H, Kuervers J, et al. The influence of sacral morphology on the existence of secure S1 and S2 transverse bone corridors for iliosacral screw fixation. *Injury*. 2013; 44(12): 1773–1779, doi: [10.1016/j.injury.2013.08.006](#), indexed in Pubmed: [24004615](#).
71. Miller AN, Routt ML. Variations in sacral morphology and implications for iliosacral screw fixation. *J Am Acad Orthop Surg*. 2012; 20(1): 8–16, doi: [10.5435/JAAOS-20-01-008](#), indexed in Pubmed: [22207514](#).
72. Miyakoshi N, Kobayashi A, Hongo M, et al. Sacral rib: an uncommon congenital anomaly. *Spine J*. 2015; 15(6): e35–e38, doi: [10.1016/j.spinee.2013.08.055](#), indexed in Pubmed: [24268667](#).
73. Moore KL, Persaud T. *The developing human, clinically oriented embryology*. 7th edn. WB Saunders Co., Philadelphia, PA 2003.
74. Nadeem G. Importance of knowing the level of sacral hiatus for caudal epidural anesthesia. *J Morphol Sci*. 2014; 31(1): 9–13, doi: [10.4322/jms.a0053913](#).
75. Nagar SK. A study of sacral hiatus in dry human sacra. *J Anat Soc India*. 2004; 53(2): 18–21.
76. Nagendrappa R, Jayanthi KS. Study of dorsal wall of sacrum. *Int J Res Med Sci*. 2014; 2(4): 1325–1328, doi: [10.5455/2320-6012.ijrms20141115](#).
77. Nasr A, Ali Y, ElSawy N. The sacral hiatus: an anatomic study on both cadaveric and dry bones. *Trans Clin Biol*. 2014; 2(1): 4, doi: [10.14259/tcb.v2i1.124](#).
78. Njihia BN, Awori KO, Gikenye G. Morphology of the Sacral Hiatus in an African Population – Implications for Caudal Epidural Injections. *Ann African Surg*. 2011; 7(1), doi: [10.4314/aas.v7i1.67024](#).
79. Okutan O, Kaptanoglu E, Solaroglu I, et al. Pedicle morphology of the first sacral vertebra. *Neuroanatomy*. 2003; 2: 16–19.
80. Osunwoke EA, Oladipo GS, Alison TA, et al. A study of sacral hiatus in dry human sacra in Southern Nigeria. *J Biol Agriculture Healthcare* (JBAH). 2014; 4(5): 43–48.
81. Pang D. Sacral agenesis and caudal spinal cord malformations. *Neurosurgery*. 1993; 32(5): 755–78; discussion 778,

- doi: [10.1227/00006123-199305000-00009](https://doi.org/10.1227/00006123-199305000-00009), indexed in Pubmed: [8492851](https://pubmed.ncbi.nlm.nih.gov/8492851/).
82. Parashuram R. Morphometrical study of sacral hiatus in dry human sacra. *Int J Res Med Sci*. 2015; 1726–1733, doi: [10.18203/2320-6012.ijrms20150260](https://doi.org/10.18203/2320-6012.ijrms20150260).
 83. Patel ZK, Thummar B, Rathod SP, et al. Multi-centric morphometric study of dry human sacrum of Indian population in Gujarat region. *NJIRM*. 2011; 2: 31–35.
 84. Patil DS, Jadav HR, Chauhan KB, et al. Anatomical study of the sacrum for transsacral block of sacral nerves. *Nat J Med Res*. 2012; 2(4): 501–503.
 85. Phalgunan V, Baskaran S. Morphometric analysis of sacral hiatus and its clinical significance. *Health Agenda*. 2013; 1: 10–15.
 86. Plockochi JH. Morphometric age-related change in the adult human sacrum. Thesis. Wichita State Univ, Wichita KS 1999.
 87. Plochoki JH. Sexual dimorphism of anterior sacral curvature. *J Forensic Sci*. 2011; 56(1): 161–164, doi: [10.1111/j.1556-4029.2010.01455.x](https://doi.org/10.1111/j.1556-4029.2010.01455.x), indexed in Pubmed: [20487142](https://pubmed.ncbi.nlm.nih.gov/20487142/).
 88. Prassopoulos PK, Fafila CP, Voloudaki AE, et al. Sacroiliac joints: anatomical variants on CT. *J Comput Assist Tomogr*. 1999; 23(2): 323–327, doi: [10.1097/00004728-199903000-00029](https://doi.org/10.1097/00004728-199903000-00029), indexed in Pubmed: [10096348](https://pubmed.ncbi.nlm.nih.gov/10096348/).
 89. Price CM, Rogers PD, Prosser AS, et al. Comparison of the caudal and lumbar approaches to the epidural space. *Ann Rheum Dis*. 2000; 59(11): 879–882, doi: [10.1136/ard.59.11.879](https://doi.org/10.1136/ard.59.11.879), indexed in Pubmed: [11053065](https://pubmed.ncbi.nlm.nih.gov/11053065/).
 90. Rajeev R, Surekha D, Medha A, et al. Variations in anatomical features of the sacral hiatus in Indian dry sacra. *Int J Med Res Health Sci*. 2014; 3(3): 634–638.
 91. Rashid M, Khalid M, Malik N. Sacral rib: a rare congenital anomaly. *Acta Orthop Belg*. 2008; 74(3): 429–432, indexed in Pubmed: [18686476](https://pubmed.ncbi.nlm.nih.gov/18686476/).
 92. Renshaw TS. Sacral agenesis. *J Bone Joint Surg Am*. 1978; 60(3): 373–383, indexed in Pubmed: [649642](https://pubmed.ncbi.nlm.nih.gov/649642/).
 93. Romanes GJ. *unningsham's Textbook of Anatomy*, Twelfth Ed. Oxford University Press 1981: 98–102.
 94. Routt ML, Simonian PT, Mills WJ. Iliosacral screw fixation: early complications of the percutaneous technique. *J Orthop Trauma*. 1997; 11(8): 584–589, indexed in Pubmed: [9415865](https://pubmed.ncbi.nlm.nih.gov/9415865/).
 95. Sachdeva K, Singla R, Kalsey G, et al. Role of sacrum in sexual dimorphism: a morphometric study. *J Indian Acad Forensic Med*. 2011; 33(3).
 96. Sadler TW. *Langman's medical embryology*. 11th ed. Lippincott Williams and Wilkins, Philadelphia 2009: 302–303.
 97. Schmorl G, Junghanns H. *The human spine in health and disease* (2nd American Edition). Edited and translated by Besemann EF. Grune & Stratton, New York 1971.
 98. Schweitzer ME, Balsam D, Weiss R. Spina bifida occulta. Incidence in parents of offspring with spina bifida cystica. *Spine*. 1993; 18(6): 785–786, indexed in Pubmed: [8516715](https://pubmed.ncbi.nlm.nih.gov/8516715/).
 99. Seema S, Singh M, Mahajan A. An anatomical study of variations of sacral hiatus in sacra of north indian origin and its clinical significance. *Int J Morphol*. 2013; 31(1): 110–114, doi: [10.4067/s0717-95022013000100017](https://doi.org/10.4067/s0717-95022013000100017).
 100. Sekiguchi M, Yabuki S, Satoh K, et al. An anatomic study of the sacral hiatus: a basis for successful caudal epidural block. *Clin J Pain*. 2004; 20(1): 51–54, indexed in Pubmed: [14668657](https://pubmed.ncbi.nlm.nih.gov/14668657/).
 101. Senoglu N, Senoglu M, Oksuz H, et al. Landmarks of the sacral hiatus for caudal epidural block: an anatomical study. *Br J Anaesth*. 2005; 95(5): 692–695, doi: [10.1093/bja/aei236](https://doi.org/10.1093/bja/aei236), indexed in Pubmed: [16155035](https://pubmed.ncbi.nlm.nih.gov/16155035/).
 102. Shewale S, Laeeque M, Kulkarni P, et al. Morphological and Morphometrical study of sacral hiatus. *IJRTSAT*. 2013; 6(1): 48–52.
 103. Shinde V, Bhusharaddi P. A study of variations of sacral hiatus of dry human sacra in north interior Karnataka region. *Nat J Clin Anat (NJCA)*. 2014; 3(4): 215–219.
 104. Shingh DI, Ajita R, Singh N. Variation in the number of sacral pieces. *IOSR- JDMS*. 2015; 14(12): 106–108.
 105. Singh R. Classification and analysis of fifth pair of sacral foramina in indian dry sacra. *Int J Morphol*. 2014; 32(1): 125–130, doi: [10.4067/s0717-95022014000100021](https://doi.org/10.4067/s0717-95022014000100021).
 106. Singh R. Classification, causes and clinical implications of sacral spina bifida occulta in Indians. *Basic Sci Med*. 2013; 2(1): 14–20.
 107. Singh R. A new foramen on posterior aspect of ala of first sacra vertebra. *IJAV*. 2012; 5: 29–31.
 108. Singh R. Sacrum with five pairs of sacral foramina. *IJAV*. 2011; 4: 139–140.
 109. Solonen KA. The sacroiliac joint in the light of anatomical, roentgenological and clinical studies. *Acta Orthop Scand Suppl*. 1957; 27: 1–127, indexed in Pubmed: [13478452](https://pubmed.ncbi.nlm.nih.gov/13478452/).
 110. Stanley JK, Owen R, Koff S. Congenital sacral anomalies. *J Bone Joint Surg Br*. 1979; 61-B(4): 401–409, indexed in Pubmed: [500747](https://pubmed.ncbi.nlm.nih.gov/500747/).
 111. Steer CM. *Moloy's Evaluation of the Pelvis in Obstetrics*. Plenum Publishing Corporation 1975: 77–94.
 112. Sugar O. How the sacrum got its name. *JAMA*. 1985; 257(15): 2061–2063, indexed in Pubmed: [3550163](https://pubmed.ncbi.nlm.nih.gov/3550163/).
 113. Suwanlikhid N, Lakchayapakorn K, Mahakkanukrauh P. The position and size of sacral size of sacral hiatus in Thai dry human sacra. *Thammasat Med J*. 2013; 13(3): 313–319.
 114. Tague RG. Fusion of coccyx to sacrum in humans: prevalence, correlates, and effect on pelvic size, with obstetrical and evolutionary implications. *Am J Phys Anthropol*. 2011; 145(3): 426–437, doi: [10.1002/ajpa.21518](https://doi.org/10.1002/ajpa.21518), indexed in Pubmed: [21541925](https://pubmed.ncbi.nlm.nih.gov/21541925/).
 115. Tanaka N, Kinoshita H, Jamal M, et al. A forensic case of sacralization of the sixth lumbar vertebra in skeletal remains. *Bangladesh J Med Sci*. 2013; 12(2): 224–226, doi: [10.3329/bjms.v12i2.14977](https://doi.org/10.3329/bjms.v12i2.14977).
 116. Taskaynatan MA, Izci Y, Ozgul A, et al. Clinical significance of congenital lumbosacral malformations in young male population with prolonged low back pain. *Spine*. 2005; 30(8): E210–E213, doi: [10.1097/01.brs.0000158950.84470.2a](https://doi.org/10.1097/01.brs.0000158950.84470.2a), indexed in Pubmed: [15834319](https://pubmed.ncbi.nlm.nih.gov/15834319/).
 117. Trotter M. A common anatomical variation in the sacroiliac region. *J Bone Joint Surg*. 1940; 22: 293–299.
 118. Trotter M, Letterman GS. Variations of the female sacrum; their significance in continuous caudal analgesia. *Surg Gynaecol Obstet*. 1944; 78(4): 419–424.
 119. Valoerdy MR, Hogg DA. Anatomical note: The occurrence of accessory sacroiliac joints in man. *Clin Anat*. 1990; 3(4): 257–260, doi: [10.1002/ca.980030403](https://doi.org/10.1002/ca.980030403).
 120. Vasuki D, Nirmaladevi D, Hebzbah M, et al. Morphology of sacrum and its variations. *IOSR-JDMS*. 2016; 15(08): 129–142, doi: [10.9790/0853-150802129142](https://doi.org/10.9790/0853-150802129142).
 121. Vesalius A. *De humani corporis fabrica libri septem*. Oporinus, Basel 1543.
 122. Woon JTK, Stringer MD. The anatomy of the sacrococcygeal cornual region and its clinical relevance. *Anat Sci Int*. 2014; 89(4): 207–214, doi: [10.1007/s12565-013-0222-x](https://doi.org/10.1007/s12565-013-0222-x), indexed in Pubmed: [24343170](https://pubmed.ncbi.nlm.nih.gov/24343170/).
 123. Wu LP, Li YK, Li YM, et al. Variable morphology of the sacrum in a Chinese population. *Clin Anat*. 2009; 22(5): 619–626, doi: [10.1002/ca.20809](https://doi.org/10.1002/ca.20809), indexed in Pubmed: [19484801](https://pubmed.ncbi.nlm.nih.gov/19484801/).
 124. Xu R, Ebraheim NA, Gove NK. Surgical anatomy of the sacrum. *Am J Orthop*. 2008; 37(10): E177–E181, indexed in Pubmed: [19081888](https://pubmed.ncbi.nlm.nih.gov/19081888/).
 125. Xu R, Ebraheim NA, Yeasting RA, et al. Morphometric evaluation of the first sacral vertebra and the projection of its pedicle on the posterior aspect of the sacrum. *Spine*. 1995; 20(8): 936–940, doi: [10.1097/00007632-199504150-00010](https://doi.org/10.1097/00007632-199504150-00010), indexed in Pubmed: [7644959](https://pubmed.ncbi.nlm.nih.gov/7644959/).
 126. Zwingmann J, Konrad G, Mehlhorn AT, et al. Percutaneous iliosacral screw insertion: malpositioning and revision rate of screws with regards to application technique (navigated vs. Conventional). *J Trauma*. 2010; 69(6): 1501–1506, doi: [10.1097/TA.0b013e3181d862db](https://doi.org/10.1097/TA.0b013e3181d862db), indexed in Pubmed: [20526214](https://pubmed.ncbi.nlm.nih.gov/20526214/).