

Endodontium — together or separately?

A. Kleinert¹, L. Kleinert¹, M. Ozimirska², R. Chałas³

¹Private Dental Practice, Jestetten, Germany

²Private Dental Practice, Warsaw, Poland

³Chair and Department of Conservative Dentistry with Endodontics, Medical University of Lublin, Poland

[Received: 8 December 2017; Accepted: 2 January 2018]

Endodontium, otherwise referred to as pulp-dentin complex or endodont. This term includes two tooth tissues: dentin and pulp, which constitute a structural and functional unity. These tissues have a huge, inseparable influence on each other — the pulp (inter alia) nourishes the dentine, while the dentin forms a protective barrier for the pulp. They develop from the papillary tissue (Latin: papilladentis) from mesenchymal tissue. Nevertheless, in clinical practice this structural-functional complex is often treated as two separate tissues, and not as a whole. Adequate knowledge of the structure, function and protective mechanisms of the endodontium produces successful results in the treatment. The appropriate choice and application of the therapeutic methods and materials to the dentin secures vitality of both tissues of this complex. (Folia Morphol 2018; 77, 3: 409–415)

Key words: dentin, pulp, endodontium, dentin-pulp complex, types of dentin, endodontium functions, pulp capping materials

DENTIN

Structure and morphology

Dentin (Latin: *dentinium*) constitutes the largest mass in tooth both in the crown and root of the tooth. In the crown part it is covered by enamel, while in the root part by the root cement. In the permanent teeth it is of a yellowish colour and a bluish-white in primary teeth. It is harder than the dense bone — its hardness corresponds to 4–5 degrees in a ten-degree Mohs scale. At the same time dentin has the elasticity which increases the mechanical resistance of the teeth to injuries. In chemical terms, dentin is composed of: inorganic material — 70%, organic material — 18% and water — 12% [9].

Organic compounds

The dentin organic compounds are 90% collagen fibres type I, called Ebner fibres. The remaining 10% are mainly, a phosphoprotein, and a small amount of glycoproteins and proteoglycans, and enzymatic proteins of hydrolase type.

The Ebner fibres are cemented with a calcified ground substance, are in collagen fibre bundles approximately 4 μm thick, almost parallel to the surface of the tooth, and perpendicular to the dentinal tubules. On the dentin surface the bundles cross with each other at an acute angle. Near the tooth chamber the angle is close to the right angle. At the dentinal tubules, collagen fibres are archwise arranged, forming a collagen-free strip.

The main dentine-specific non-collagen proteins are phosphoproteins: phosphite (DPP, dentin phosphoprotein) and dentin sialoprotein (DSP). They are formed by enzymatic cleavage of the precursor protein of the dentin sialophosphoprotein (DSPP).

Phosphites play a major role in initiating and controlling dentin mineralisation — the shape and size of the hydroxyapatite crystal depend on them. These proteins have a specific affinity for calcium ions and combine with chemical bonds with collagen. Deficiency or lack of phosphite causes a dentinogenesis imperfecta.

Dentin sialoproteins are needed in the processes of formation of dentin and control mineralisation process [3, 9].

Inorganic compounds

The inorganic part of dentin is composed primarily of calcium phosphate (95%) in the form of dihydroxyapatite crystals, with a small amount of carbonate and trace amounts of Mg^{2+} , K^+ , Na^+ , Fe^{2+} , Cl^- [3]. Dihydroxyapatite crystals are deposited during the dentin calcification in the form of calcospherites — spherical bodies that are connected to one another [9]. In the place where calcospheritic structures have not fully merged, there are areas of non-mineralised organic substance called interglobular dentin. Calcification/mineralisation of dentine is a rhythmic and layered process. Rhythmic process of dentin growth and calcium salts depositing in it is observed in the form of incremental lines of von Ebner. Sometimes the incremental lines are very broad and they are referred to as the Owen contour lines, the interglobular dentin is arranged according to their arrangement. In the milk teeth there is a neonatal line that separates the dentin layer produced in the foetal life from the dentine produced after birth and is the result of mineralization disorders during this period [3].

Ground substance

In ground substance of dentin there are proteins found in bone and cartilage tissue (osteopontin, osteonectin, osteocalcin), bone morphogenetic proteins (BMP), as well as peptide growth and differentiation factors — fibroblast growth factor (FGF), transforming growth factor (TGF), insulin-like growth factors (IGF) [1].

Types of dentin (Fig. 1)

Mantle dentin — is the first layer of dentin formed during odontogenesis. It is located at the dentin-enamel junction — constituting the outermost part of the dentin [6].

Primary dentin

During the development of the tooth or in the process of odontogenesis, primary dentin is formed. It is formed by odontoblasts until complete formation of the tooth root. It has a typical tubular structure with odontoblast processes inside the tubules. This is a physiological dentin [6].

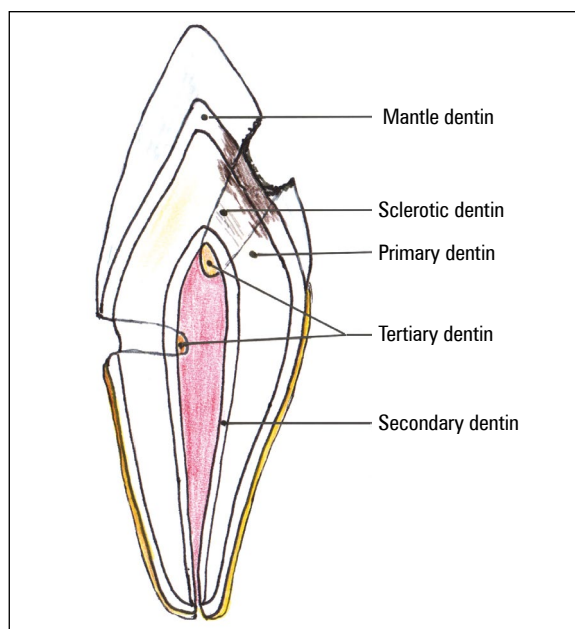


Figure 1. Section of human teeth. Types of dentin.

Predentin

It is the layer of dentin closest to the pulp above the odontoblast layer — it is the innermost layer. It is a thin layer of freshly made, yet not mineralised dentin, consisting of a basic ground substance and collagen fibres. It is deposited throughout the tooth's life until the pulp is vital [6, 9].

Secondary physiological dentin (secondary dentin)

After root formation is completed and tooth is erupted, the pulp continues to deposit dentin. Under the influence of physiological processes, mainly related to chewing, secondary dentin develops. As a result of its deposition in the pulp periphery, the tooth chamber lumen and the tubules lumen gradually decrease. The dentin has less regular structure and is more mineralised. Clinically, the colour is from honey to dark brown [6, 9].

Secondary pathological dentin (tertiary dentin)

Tertiary dentin is produced in response to external irritants — pathology (caries, abrasion, attrition, erosion, managing and filling of cavities). When there is stimulus, the tertiary dentin is created as soon as the enamel-dentin border is affected. It has an irregular structure. The degree of irregularities depends on the dynamics of the pathological process (in acute processes it is more irregular than in chronic processes),

and on the severity of pathological irritants. The dentin resulting from the pathological irritants, formed by the primary odontoblasts, is called reactionary dentin. If odontoblasts are destroyed by a pathological process, they release into the intercellular space biologically active substances that are strongly stimulating mesenchymal cells and possibly fibroblasts. This results in the transformation of these cells into odontoblast-like cells capable of producing dentin. The dentin that was formed in this way is a reparative dentin. It is formed by the odontoblast-like cells under external stimulation (most often pulp capping materials). If damage to the pulp was severe, and it was exposed to direct pathological factors — the dentin must first be formed by fibroblasts and it has a non-tubular structure, forming so called dentin bridge [6, 9, 17].

Dentin tubules

Dentin tubules are characteristic structures in the dentine structure (Fig. 2). Microscopic tubules extend to the dentin-enamel junction, while within the root they rarely reach the dentin-cementum junction. They are perpendicular to the tooth surface. Within the crown, these tubules follow an S-shaped path, and in the root they run parallel to each other, slightly wavy. The diameter of the tubules is 3–5 μm , but in the outermost parts is about 1 μm . Dentin tubules have many branches by which they can connect. A few of the dentinal tubules enter between the enamel prisms at various depths creating the so-called enamel cobs. In the dentinal tubules there are odontoblastic dentin processes termed Tomes fibres, the non-myelinated nerve fibres, and tissue fluids filling the space. Odontoblasts processes have a lot of lateral branches passing into tubular side branches. In the cytoplasm of Tomes fibres there are microtubules, microfilaments, mitochondria and matrix vesicles.

Peritubular dentin forms the wall of each dentinal tubule. The main mass of the dentin between the tubules is the intertubular dentin (Fig. 3). Peritubular dentin is more mineralised and has fewer collagen fibres than intertubular dentin, and also has a slightly different composition of matrix and smaller hydroxyapatite crystals. As a result of greater mineralisation, peritubular dentin is more likely to be damaged during the early phase of caries, and toxic substances can easier penetrate directly into the pulp. The walls of the tubules near the odontoblasts are lined with a thin layer of non-mineralised substance called the Neumann lining. The formation

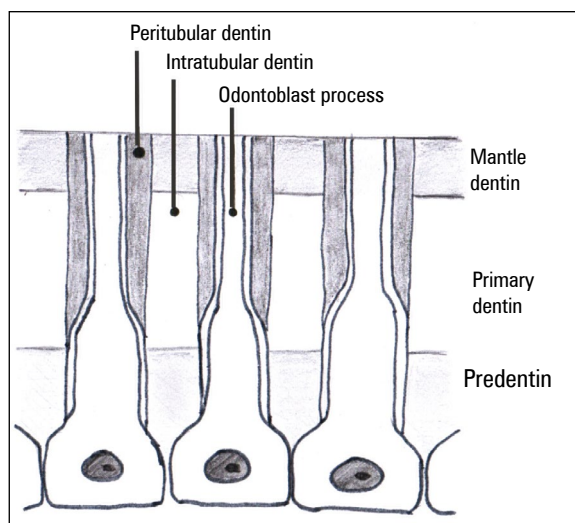


Figure 2. Dentin tubules and odontoblasts.

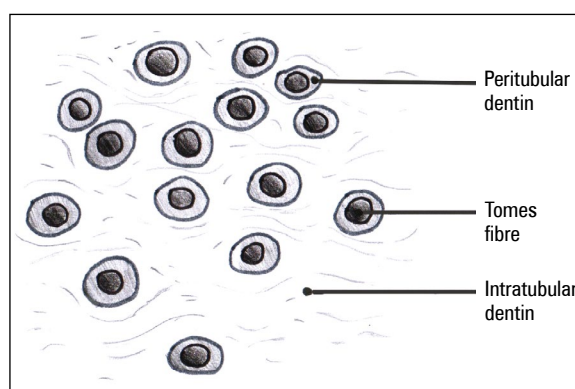


Figure 3. Peritubular und intratubular dentin.

of a peritubular dentin is a continuous process that can be accelerated by external stimuli. Then, so-called sclerotic dentin is formed in the primary dentin. The stimuli cause progressive obliteration of the tubule and even its complete closure [9]. The odontoblast cytoplasmic processes withdraw to the pulp or degenerate leading to calcification. As a result of these processes, a layer of dead tubules filled with gases, fluid or cell debris is formed creating death tracts. Its presence facilitates the penetration of bacteria into the dentin after enamel destruction [9].

Types of dentinal tubules

The vast majority of dentinal tubules are tubules of classical structure, but there are also tubules of different structure. These include bifurcate, clavate,

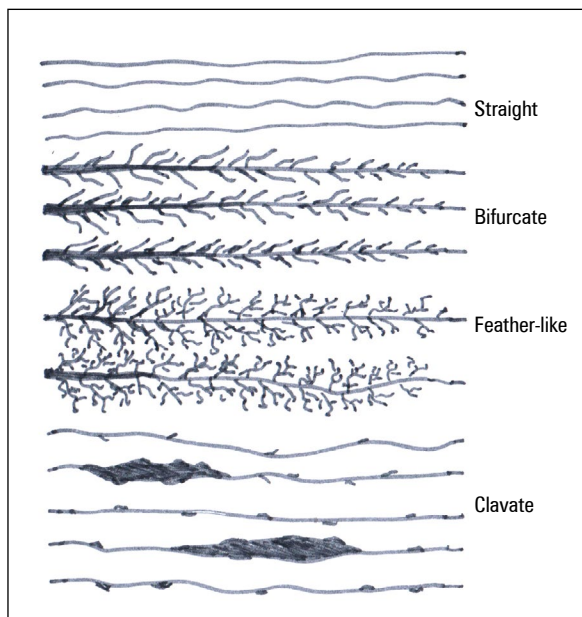


Figure 4. Types of dental tubules.

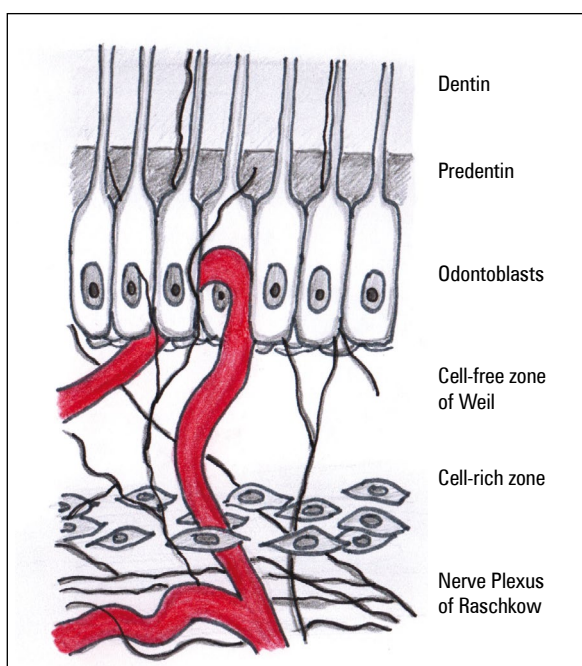


Figure 5. Pulpal dentin junction.

feather-like and giant tubules (Fig. 4). Straight tubules form bundles near the tooth chamber, disappear in the outer dentin. These bundles are separated by spaces to form niches and fissures within the calcified dentin ground substance. In these niches or slits there are bifurcate tubules. They are numerous, thick and have twisted branches. These tubules rarely reach the

dentin-enamel junction, usually ending in half or 1/3 of the outer dentin. They are most often found in root dentin. A variation of bifurcate tubules are feather-like tubules of more delicate structure. These tubules are less frequent and not only in niches, but also between classical dentin tubules. They are characterised by a large number of lateral branches. The rarest among dentinal tubules are clavate tubules. They are characterised by considerable thickness and unevenness of the surface. They have lateral, short branches, connecting and merging together, this way making the tubule thicker. These clavate extensions of the tubules are only at a distance from the tooth chamber. There are also sometimes giant tubules, which are considered to be places where odontoblasts are trapped. They are found in root dentin and vary in size and shape [6, 9].

Dentin innervation

Dentin as compared to enamel is an innervated tissue sensitive to various stimuli. Non-myelinated nerve fibres extend into dentin from the subodontoblastic neural plexus. They initially form delicate plexuses between the odontoblasts and near the predentin. Then they proceed to the predentin and dentinal tubules, where they run along the Tomes fibres. These fibres do not reach the surface of the dentin, but to the depth of 0.5–0.7 mm, and the odontoblast processes are the supporting elements [6, 9].

PULP

Structure and morphology

Pulp (Latin: *Pulpa dentis*) is a tissue filling the tooth (chamber, canals) (Fig. 5). Histologically, it resembles the gelatine-like matured connective tissue, containing a large number of ground substance, rich in proteoglycans, a network of loosely arranged collagen fibres, and numerous stellate cells. On the peripheral strip of the pulp there are thick silver-absorbent fibres called Korff spiral fibres.

Within the pulp, three zones can be distinguished: the odontoblastic zone, a cell-free zone of Weil beneath the odontoblasts, and the core pulp or cell-rich zone [6].

Odontoblasts

These cells are located most peripherally in the pulp, arranged in a palisade. In the coronal part they form 2–3 rows of cylindrical cells. Within the root pulp, there is one row of cubic or flat cells. Odontoblast

has three types of processes: dentinal, pulpal and lateral. The dentinal process is long and penetrates into the dentinal cavity to form a Tomes fibre. The pulpal process is shorter and passes through the basal zone of Weil into the pulp. Odontoblasts also have short lateral processes that are connected with other lateral processes of adjacent odontoblasts.

Odontoblasts are involved in the formation of the dentin ground substance and its mineralisation. The pre-dentin layer is deposited in the apical part between dentin processes and then is mineralised. These cells also produce procollagen, which at the secretory part of cells is released into the matrix of dentin to form collagen fibres. In addition to procollagen, glycoproteins and proteoglycans are also synthesised.

Odontoblasts have the capability to produce dentin throughout their lifespan. As a result of damage, the new odontoblasts can be formed from pulp fibroblasts or differentiated mesenchymal cells to form a so-called pseudodontoblasts [9].

Cell-free zone of Weil

This layer contains pulpal processes of odontoblast, fibroblast processes, Korff spiral fibres, and non-myelinated nerve fibres from the nerve plexus that penetrate into the dentinal tubules. In this layer there is also a subodontoblastic capillary plexus [6, 7].

Core pulp — cell-rich zone

This layer is formed of mesenchymal cells and star-shaped, spheroidal and spindle-shaped fibroblasts. These cells join together to form a network [7]. Both types of cells, under the influence of stimuli (physiological or pathological), can divide and differentiate into fibroblasts or (via the transitional form — pre-odontoblasts) into odontoblasts. In addition, there are infiltrating cells in the pulp involved in immune responses. These include lymphocytes, granulocytes, plasma macrophages, mast cells, and antigen presenting cells. Their number grows in the inflammatory state of the tooth [6, 7].

Nerves and vascularity of the pulp

Innervation

Pulp is nourished by sensory fibres (myelinated) and by vascular fibres (non-myelinated vegetative fibres). Along with blood vessels, nerve fibres (in 2–3 bundles containing several hundred axons) penetrate into the pulp through the apical opening. In the central part of the pulp, the fibres are myelinated and

non-myelinated. They then branch into several smaller bundles. Directly under the odontoblast layer, both types of fibres form subodontoblastic plexus (nerve plexus of Raschkow).

Sensory nerves are the receptors that receive different stimuli, transmitting the sensation of pain. Sensory nerves run from the trigeminal ganglion. The sensory fibres penetrate as myelin fibres and then branch off and lose the myelin sheath. From the subodontoblastic plexus, they proceed to the odontoblast layer into very thin non-myelinated fibres and further to the dentinal tubules. Vasomotor fibres are fibres of the sympathetic nervous system and are responsible for vascular circulation, regulating the flow of blood in blood vessels by their narrowing or dilating [6, 7, 9].

Vascularity

Arteries of the pulp are branches of periodontal vessels; they penetrate as small arterioles (3 or more) and branch out within the coronal pulp. These branches are of the capillary type in the number of about 150–180 capillaries. At the base of the odontocytes, they form a network of broad capillaries, often creating loops, that merge into venules. There are two types of capillaries in the pulp. The first one — fenestrated capillaries, the thinnest, having pores in basal membrane of 50 nm in diameter, facilitating the exchange of various substances between blood and the cells. The second type are continuous capillaries that have continuous endothelial lining and are typical capillaries. Both of these types of vessels are linked together, forming a subodontoblastic capillary network. Pulp capillaries change into wide thin-walled venules that extend through the central portion of the pulp. These venules, one or two, taper within the root canal and leave the pulp through the apical opening.

All pulp vessels have very thin walls due to muscularis mucosa reduction. This makes the pulp very sensitive to pressure changes. During rapid flow of blood, vessels surrounded by hard tissue of the tooth cannot increase their volume. Also the blood outflow through the narrow apex is difficult. Long-term elevated vascular pressure, resulting in pulp congestion, can lead to pulp necrotizing changes [9–11].

ENDODONTIUM FUNCTIONS

Nutrition of tooth

Through periodontium and cement, the exchange of tissue fluids is minimal. Vital pulp is the main nutri-

tional path of the tooth. This is done by a very well developed blood vessel system. Subodontoblastic plexus is particularly important in the delivery of nutrients to odontoblasts. Nutrition of dentin is achieved by a network of dentinal tubules, filled with tissue fluids and odontoblast processes. Tomes fibres penetrate the organic dentin and enamel to provide nutrients to the tissue [9].

Dentin formation

During the tooth formation, primary dentin is formed constituting the main bulk of the tooth. Once the development of the tooth is complete, dentin formation continues, but at a slower rate, and such dentin is called a secondary dentin. Under the influence of various pathological irritants (e.g. caries, attrition, abrasion), the pulp deposits the secondary pathological dentin, also called the tertiary dentin [9].

Defensive role

Primary and secondary physiological dentin surrounds the pulp from all sides, protecting it from the external environment. Under the influence of pathological factors, secondary pathological dentin is formed, which has a more irregular structure than physiological dentin. Sclerotic dentin is also a protective reaction to the harmful effect of pathological stimulus and develops in the primary dentin between the carious lesion and the pulp. Pulp and dentin protect themselves against harmful factors by building a new dentin or sealing primary dentin. Another protective reaction is the dentin bridge created by the pulp capping materials at the site of exposure or pulp injury [9].

Sensory function

The tooth pulp through innervation has the ability to record sensation of pain regardless of the type or location of the stimulus. The first path of transmitting physical and chemical stimuli to the pulp is odontoblast fibres in dentinal tubules. The other path is the nerve fibres that surround the odontoblast processes in the dentinal tubules that come from the subodontoblastic plexus [9].

AGE-RELATED CHANGES IN ENDODONTIUM

With age, the tooth tissue degenerates like other tissues in the human body. As a result of deposition of the secondary dentin into the tooth pulp (chamber, canals, lateral and pulp-dentin canals), the lumen is reduced. Obliteration of lateral canals, however, is

preferable for endodontic treatment due to the inability to spread the infection through these gates. Dentinal tubules become obliterated by mineralised tissue, causing even their complete occlusion. As a result of apoptosis, odontoblasts disappear, there is a reduced number of the remaining cells, and the number of fibrous elements increases. Nerve fibres and blood vessels, especially capillaries and precapillaries commonly calcify. All these changes cause weakening of the protective and regenerative properties of endodontium, and consequently, difficulties in endodontic treatment [6, 9, 12].

DENTINE-PULP COMPLEX REACTION TO PULP CAPPING MATERIALS

A specific type of dentin is a repair dentine. It is formed by odontoblast-like cells as a result of external stimulation with preparations having odontotropic effect after the destruction of the odontoblasts. If the pulp damage was severe, dentin is formed by fibroblasts as a dentin bridge of non-tubular structure [7]. Odontotropic preparations used in the daily dental practice as a direct pulp capping include calcium hydroxide and mineral trioxide aggregate (MTA) [9, 11]. Under the odontotropic influence of calcium hydroxide, the pulp under the produced dentin bridge shows no signs of inflammation [1, 3, 10, 17]. According to some authors, calcium hydroxide is not a long-term barrier to bacteria, and after several years, symptoms of infection and necrosis can be observed [16]. A newer formulation used for direct covering of pulp is MTA. It has a tighter adhesion than calcium hydroxide and lower incidence of the symptoms of inflammation, congestion or necrosis of the pulp. Thicker dentin bridge was formed and more often pseudoblastic layers were formed [2]. Most authors show a greater success rate of direct pulp therapy with MTA than $\text{Ca}(\text{OH})_2$. Although MTA has better treatment results, it is not devoid of defects. The application of the preparation is simpler, while the bonding time is 4–6 h and requires two visits. The cost of using this material is also much higher. Biodentine is another formulation used in practice in biological therapy, perforation, or as a substitute for dentin without the need for etching [19]. This preparation, like MTA, is classified as a bioceramic material — silica-calcium cement. It consists of powder and liquid. This powder, as MTA — is calcium oxide in tricalcium and dicalcium silicate, Portland cement and calcium carbonate. The liquid contains calcium chloride, which increases the pH and

shortens the binding to a few minutes and improves the mechanical properties of the formulation. The studies of other authors have shown similar effects of MTA when used to cover pulp directly [13]. In both groups, total dentin bridge formation was observed and no pulp inflammation was present, suggesting Biodentine as an alternative to MTA [4, 5]. Attempts are also made to cover wounded and open pulp with bonding systems [14, 18], glass ionomer cement [8] or enamel matrix proteins [7]. The effects are debatable, because inflammation, including necrosis, and no dentin bridge has been found [12, 15, 16].

CONCLUSIONS

Endodontium is a structural-functional unity, created by the pulp and dentin. It has an indispensable role in the processes occurring in vital tissues of the tooth and in the periapical tissues. This dentin-pulp complex has four functions: nutritive, formative, protective and sensory. As a structural-functional unit it deserves to be treated as a whole. Complete knowledge of its structure, function, and age-related changes gives an image of complexity and shows how important it is in daily practice to treat these two tissues not separately, but as a closely interrelated complex. The use of the pulp capping materials is beneficial for prolonging the life of the tooth, as well as reducing inflammation. Accordingly, the medical procedures should lead to the preservation of protective and repair processes of the tooth.

Acknowledgements

All figures are drawn by Adriana Kleinert.

REFERENCES

- About I, Mitsiadis TA. Molecular aspects of tooth pathogenesis and repair: in vivo and in vitro models. *Adv Dent Res.* 2001; 15: 59–62, doi: [10.1177/08959374010150011501](https://doi.org/10.1177/08959374010150011501), indexed in Pubmed: [12640742](https://pubmed.ncbi.nlm.nih.gov/12640742/).
- Aeinehchi M, Eslami B, Ghanbariha M, et al. Mineral trioxide aggregate (MTA) and calcium hydroxide as pulp-capping agents in human teeth: a preliminary report. *Int Endod J.* 2003; 36(3): 225–231, indexed in Pubmed: [12657149](https://pubmed.ncbi.nlm.nih.gov/12657149/).
- Bjørndal L, Mjör IA. Pulp-dentin biology in restorative dentistry. Part 4: Dental caries--characteristics of lesions and pulpal reactions. *Quintessence Int.* 2001; 32(9): 717–736, indexed in Pubmed: [11695140](https://pubmed.ncbi.nlm.nih.gov/11695140/).
- Chalas R, Mielko E, Zubrzycka-Wrobel J, et al. A chemical activity evaluation of two dental calcium silicate-based materials. *Curr Iss Pharm Med Sci.* 2015; 28(2), doi: [10.1515/cipms-2015-0051](https://doi.org/10.1515/cipms-2015-0051).
- Chafas R, Mielko E, Bachanek T, et al. Assessment of dentin reaction after Biodentine application. *Curr Iss Pharm Med Sci.* 2013; 26(4): 435–439, doi: [10.12923/j.2084-980x/26.4/a.19](https://doi.org/10.12923/j.2084-980x/26.4/a.19).
- Hellwig E, Klimek J, Gattin T. Einführung in die Zahnerhaltung. Deutscher Zahnärzte Verlag Köln. 2009; 8-11: 311–315.
- Kiatwateeratana T, Kintarak S, Piwat S, et al. Partial pulpotomy on caries-free teeth using enamel matrix derivative or calcium hydroxide: a randomized controlled trial. *Int Endod J.* 2009; 42(7): 584–592, doi: [10.1111/j.1365-2591.2009.01552.x](https://doi.org/10.1111/j.1365-2591.2009.01552.x), indexed in Pubmed: [19467054](https://pubmed.ncbi.nlm.nih.gov/19467054/).
- Lan WH, Lan WC, Wang TM, et al. Cytotoxicity of conventional and modified glass ionomer cements. *Oper Dent.* 2003; 28(3): 251–259, indexed in Pubmed: [12760696](https://pubmed.ncbi.nlm.nih.gov/12760696/).
- Lapińska J, Dąbrowska E, Stokowska W. Możliwości naprawy i obronne miazgi w procesie próchnicowym – przegląd piśmiennictwa. *Nowa Stomatol.* 2004; 2: 83–86.
- Magloire H, Romeas A, Melin M, et al. Molecular regulation of odontoblast activity under dentin injury. *Adv Dent Res.* 2001; 15: 46–50, doi: [10.1177/08959374010150011201](https://doi.org/10.1177/08959374010150011201), indexed in Pubmed: [12640739](https://pubmed.ncbi.nlm.nih.gov/12640739/).
- Makowiecki P, Trusewicz M, Tyszler Ł, Buczkowska-Radlińska J. Leczenie biologiczne miazgi zębów stałych. *Rocznik PAM w Szczecinie.* 2014; 60(2): 80–88.
- Mjör IA. Pulp-dentin biology in restorative dentistry. Part 7: The exposed pulp. *Quintessence Int.* 2002; 33(2): 113–135, indexed in Pubmed: [11890026](https://pubmed.ncbi.nlm.nih.gov/11890026/).
- Nowicka A, Lipski M, Parafiniuk M, et al. Response of human dental pulp capped with biodentine and mineral trioxide aggregate. *J Endod.* 2013; 39(6): 743–747, doi: [10.1016/j.joen.2013.01.005](https://doi.org/10.1016/j.joen.2013.01.005), indexed in Pubmed: [23683272](https://pubmed.ncbi.nlm.nih.gov/23683272/).
- Onur MA, Taşman F, Cehreli ZC, et al. Effect of a fifth-generation bonding agent on vascular responses in rats. *J Endod.* 2000; 26(7): 407–409, doi: [10.1097/00004770-200007000-00007](https://doi.org/10.1097/00004770-200007000-00007), indexed in Pubmed: [11199766](https://pubmed.ncbi.nlm.nih.gov/11199766/).
- Postek-Stefańska L, et al. Leki i materiały stosowane do bezpośredniego pokrycia miazgi zębowej - przegląd piśmiennictwa. *Prz Stom Wiekui Rozw.* 2001; 1: 12–16.
- Schuurs AH, Gruythuysen RJ, Wesselink PR. Pulp capping with adhesive resin-based composite vs. calcium hydroxide: a review. *Endod Dent Traumatol.* 2000; 16(6): 240–250, indexed in Pubmed: [11202889](https://pubmed.ncbi.nlm.nih.gov/11202889/).
- Smith AJ, Murray PE, Sloan AJ, et al. Trans-dentinal stimulation of tertiary dentinogenesis. *Adv Dent Res.* 2001; 15: 51–54, doi: [10.1177/08959374010150011301](https://doi.org/10.1177/08959374010150011301), indexed in Pubmed: [12640740](https://pubmed.ncbi.nlm.nih.gov/12640740/).
- Taşman F, Cehreli ZC, Onur MA, et al. Effect of different single-bottle dentin adhesives on vascular responses in rat carotid artery. *Am J Dent.* 2000; 13(6): 337–339, indexed in Pubmed: [11764129](https://pubmed.ncbi.nlm.nih.gov/11764129/).
- Tran XV, Gorin C, Willig C, et al. Effect of a calcium-silicate-based restorative cement on pulp repair. *J Dent Res.* 2012; 91(12): 1166–1171, doi: [10.1177/0022034512460833](https://doi.org/10.1177/0022034512460833), indexed in Pubmed: [22983409](https://pubmed.ncbi.nlm.nih.gov/22983409/).