

A plea for extension of the anatomical nomenclature. Part 1: Nervous system and senses

D. Kachlik^{1, 2}, V. Musil³, V. Baca²

¹Department of Anatomy, Second Faculty of Medicine, Charles University, Prague, Czech Republic

²Department of Health Care Studies, College of Polytechnics Jihlava, Czech Republic

³Centre of Scientific Information, Third Faculty of Medicine, Charles University, Prague, Czech Republic

[Received: 7 June 2016; Accepted: 3 August 2016]

A correct, exact, concise and detailed anatomical nomenclature is a cornerstone of communication not only in anatomy and related subjects but also in other medical branches and in the whole medical education. Terminologia Anatomica fulfils this task but some important structures are still missing there. The authors have collected and present here a list of terms including their definitions or explanations to provoke discussion about possible extension of the Terminologia Anatomica. The first part of this contribution, presented in this article, comprises 113 terms concerning the regulation systems of the human body: endocrine glands, central and peripheral nervous system, and senses. It also contains some corrections of anatomical mistakes, systemic inconsistencies and grammar changes. (Folia Morphol 2017; 76, 2: 168–177)

Key words: anatomy, anatomical terminology, anatomical nomenclature

INTRODUCTION

The anatomical nomenclature already exists for 121 years. The first and huge step was done by the Anatomical Society of German speaking Anatomists (Anatomische Gesellschaft) by creation, codification and publication of the Basiliensia Nomina Anatomica (BNA) in 1895 [28]. After some years of quarrels, the full consensus in the Latin anatomical nomenclature was achieved by issuing the Parisiensia Nomina Anatomica (PNA) in 1955 [28]. It was later revised 5-times and finally replaced by the Terminologia Anatomica (TA) [7]. Nowadays, the terminological organ of the International Federation of Associations of Anatomists (IFAA), termed the Federative International Programme on Anatomical Terminology (FIPAT), has been continuously working on the other morphological nomenclatures since 2009 and prepares a new revised edition of the anatomical nomenclature which should be published in near future. Such tool which is concise and precise, worldwide accepted and acknowledged, clear and simple, is viable for uncon-

fused and understandable communication between medical specialists.

The plea for better, more accurate, more detailed and uniform anatomical nomenclature is a never-ending story. Although anatomy belongs to the oldest scientific medical branches and first terms come from the Egyptian papyri (e.g. Papyrus of Edwin Smith and Papyrus of Ebers from 16th century BC), there still exists some incoherence between the scientific knowledge and its mirror in the anatomical terminology and nomenclature. Terminology is a system of terms used in the specific scientific field, and nomenclature, comprising the terms created within the scope of terminology, is a normalised system (usually processed as a systematised list) of exactly defined terms which are arranged according to certain classification principles. Nomenclature is then approved by an official organ of the specific scientific branch and is usually worldwide accepted and used by the professional community. Some well-known, established and used terms (parts of terminology) have not yet pertained to the nomenclature.

The anatomical nomenclature is a very useful and moreover necessary and inevitable tool for both the pedagogic and scientific life. Naming parts of the human body should be unanimous, unique and common worldwide to avoid confusion, errors, misunderstanding, redundant learning and time loss. That is why, from the first attempt in 1895 (BNA), generations of anatomists spent hours and days to refine it and to create a world consensus. The revision of TA which is now in progress (by FIPAT) will bring for the first time a nomenclature featuring only one term applied to every structure in two languages, Latin and English, completed with other terminological and eponymous synonyms. Several manuscripts drawing attention to the problems of TA have been published [3, 9, 11, 22–25].

The purpose of this article is to suggest incorporation of following terms to the new version of TA but before that to subject them to a wide discussion and criticism of anatomical experts throughout the world who are not directly involved in the revision process but who are interested in reaching the above mentioned common aim. FIPAT expects and welcomes any proposal or commentary on this topic.

The terms have been gathered during the educational and scientific process in which our team was involved in last 15 years. They are either known from recent and old anatomical atlases, detailed textbooks of the certain specific fields or from repetitive scientific researches that is why in most of cases, references are not necessary. Some proposals have already been published by other authors but scattered in the individual articles and it is practical to mention them and to draw attention to them again. After discussion it is useful to consider them and if agreed, introduce them into the new version of TA. Some of the structures lack their precise denomination and that is why new terms are proposed for discussion. In general, the terms comprise systemic, topographic, clinical and variational anatomies.

At first, some anatomical mistakes have to be solved:

- *articulationes costochondrales* are not synovial joints but cartilaginous junctures (synchondroses) between the bony rib and the *cartilago costalis* (except for the ninth and tenth ribs which connection is fibrous) that is why the term should be corrected to ***synchondroses costochondrales***;
- the term *nucleus ventralis posterolateralis* is listed twice in TA, first subordinated to *nuclei ventrobasales* under the identification number A14.1.08.640, and second independently under A14.1.08.656. It seems to be a mistake because only one such structure exists in thalamus.

And several grammar changes have to be discussed, although majority of them has been solved and proposed in our previous articles [13–16].

- The developmental term *ductus thyroglossalis* (A05.1.04.021) should match the other terms concerning the tongue, e.g. *musculus styloglossus*, *nervus hypoglossus*, and the change back to the term from the PNA (1955) — “ductus thyroglossus” would be reasonable and consistent; the correct modern form should be ***ductus thyroglossus*** as already listed in the Terminologia Embryologica (E5.4.2.0.0.1.22) [8].
- “Introitus oesophagei” (mouth of Killian) at the transition between the pharynx and the oesophagus, which is narrowed ventrally by the *cartilago cricoidea*, now termed *constrictio pharyngooesophagealis* (A05.3.01.026), should be slightly changed to ***constrictio pharyngooesophagea*** to be consistent with other structures using the adjective “oesophageus”. Moreover, as a non-preferred synonym, the term *constrictio cricoidea* can be added.
- “Impressio oesophageale” for the oesophageal impression of the liver is a grammatically incorrect term. Firstly, *impressio* is a feminine, secondly “oesophagealis” is inconsistent with other terms using the preferred adjective *oesophageus* [15]. That is why the correct term should be ***impressio oesophagea (hepatis)***.
- There are inconsistencies in using terms “peroneus” and “peronealis”. The former is applied in the chapter ‘General anatomy’ and for “trochlea peronealis”, the latter for muscles and nerves. From the grammatical point of view, the term “peroneus” should be chosen but as proposed in our previous articles, the term ***fibularis*** should be the preferred one for all the structures [13–15].
- Also, there are inconsistencies of the adjective form in terms related to the *musculus sphincter*: majority of them uses the non-concordant adjective such as *musculus sphincter urethrae externus*, *musculus sphincter vesicae*, *musculus sphincter ductus choledochi*, *musculus sphincter ampullae*, *musculus sphincter ani (externus et internus)*, *musculus sphincter pupillae*, but one of them, *musculus sphincter pyloricus*, uses the concordant adjective. It would be reasonable to unify it to the former type (non-concordant adjective), i.e. to use ***musculus sphincter pylori*** which was already part of BNA, lenaensia Nomina Anatomica (INA) and PNA.
- *Nodus lymphoideus/nodus lymphaticus/lymphonodus** are synonyms listed in TA although the

term “lymphoid” means from the linguistic point of view only “similar to lymph” (‘eidōs’ is a Greek term for form) and that is why the term **lymphatic** should be preferred.

- The English synonyms of *pili* — hairs; *capilli* — hairs of head; *pubes* — pubic hairs, according to the grammar, should be stated as singular, i.e. **hair; hair of head; pubic hair**, as they do not represent the exact number of the hair but only its type.

There are also some systemic inconsistencies which should be solved:

- the term *cavitas conchae* has a non-preferred synonym *cavum conchae*. As the only surviving example of “cavum” in TA is the dural duplication *cavum trigeminale* and the others have been replaced with *cavitas*, it should be reasonable to delete the remaining ones as well;
- there is inconsistency in denomination of the sensory ganglion of *nervus vestibularis* (ganglion of Corti): in chapter ‘*Systema nervosum*’ two synonyms are listed – *ganglion cochleare*; *ganglion spirale cochleae* (A14.2.01.134) but in chapter ‘*Organa sensuum*’ only the latter term is used. To be consistent with the name of the other ganglion of the *nervus vestibulocochlearis*, the *ganglion vestibulare*, the only term should be **ganglion cochleare**;
- the term *radiatio optica* is stated under *substantia alba thalami* (item A14.1.08.673) as well as under *capsula interna*. But the latter position comprises two items — once accompanied with a non-preferred synonym *fibrae geniculocalcarinae* (A14.1.09.542) as a part of *pars retrolenticiformis capsulae internae* and then alone, without a synonym (A14.1.09.547) as a part of *pars sublenticiformis capsulae internae*. These discrepancies must be resolved in a clear and clever way;
- the inexact term *prominentia canalis facialis* is derived from the term *canalis nervi facialis* and that is why it should be refined as **prominentia canalis nervi facialis**.

As for the English terminology, there are inconsistencies as well:

- transverse plane is a virtual plane situated strictly horizontal and it corresponds to what is in clinical medicine often termed as the axial plane or cross-section. To avoid any ambiguity or uncertainty, only the term **transverse plane** (and projection) should be preferred. Similarly, frontal plane is a virtual plane situated strictly vertical and parallel with the forehead and it corresponds to what is in clinical medicine often termed as the coronal plane; only the term **frontal plane** should be used;

- denominations of liver segment V, VI and VIII lack the side indication; the anterior medial segment (segment V) should be specified as **right anterior medial segment** and similarly for segment VI and VIII;
- the term round ligament of the liver should be slightly changed to **round ligament of liver** because the definite article is not commonly used in the list of terms in TA;

- there are mistakes in denominations of structures of the tympanic membrane related to the malleus — the incorrect terms “anterior and posterior malleolar folds, malleolar stria and malleolar prominence” should be changed to **anterior and posterior mallear folds, mallear stria and mallear prominence** because the term “malleolar” is related to *malleolus* of the leg and the term “mallear” to the auditory ossicle *malleus*.

Some terms deserve further scientific research as their anatomy is not either well known and understood or precisely and correctly described and presented. This can be shown using the example of an eponymic lymph node.

“Delphian (Delphic) node” is a dubious anatomical term. Clinically it is applied to a pathological enlarged lymph node in front of the lower respiratory tract on the neck. It is described as one or more (1–4) lymph nodes within the fascia in the midline above the *isthmus glandulae thyroideae* (but can encompass any lymph node located ventral to the inferior half of the *cartilago thyroidea*, in front of the *membrana cricothyroidea* or *cartilago cricoidea*), usually closely associated with the *lobus pyramidalis glandulae thyroideae* (if present) and denominated as the “nodus lymphoideus prelaryngeus, precricoideus seu cricothyroideus”. It seems it belongs to the group called *nodi prelaryngei* but a precise terminology should be useful to state the exact location of this/these lymph node(s).

It was hypothesised that metastasis to this lymph node foretells a “terrible” end-result from the cancer that is why its name was inspired by the Oracle of Delphi, the most important religious prophet in ancient Greece. If enlarged, it is indicative of disease of either the thyroid gland or the larynx [12].

The term “innominatus” seems to be a joke in the anatomical terminology and nomenclature. It designates a structure without a proper name but such a structure is already recognised and described and deserves a specific term, based on its morphology and/or localisation and/or function. Here are listed structures which were and/or even still are denominated with this queer term:

- former “tuberculum innominatum”, now proposed as ***tuberculum vastoadductorium*** is a projecting distal end of the *trochanter major femoris*, serving for the origin of the *musculus vastus medialis* and for the insertion of the *musculus gluteus medius* [15];
- “canaliculus innominatus (of Arnold)” is an obsolete term for the *foramen petrosum*;
- “arteria anonyma” is an obsolete term used as the official term until 1935 when it was replaced by the currently valid *truncus brachiocephalicus* (other obsolete synonyms were “truncus anonymus” in Latin and “innominate artery” and “innominate trunk” in English);
- “vena anonyma dextra et sinistra” are obsolete terms used as the official terms until 1935 when they were replaced by the currently valid *vena brachiocephalica dextra et sinistra*;
- “arteria anonyma iliaca” and “vena anonyma iliaca” are obsolete terms used by Jacob Henle for *vasa iliaca communia*;
- “lobulus anonymus” is an obsolete term for the *lobus quadratus hepatis*;
- “os innominatum” is an obsolete term for the *os ilium*;
- *substantia innominata* (of Reichert) is the only currently valid term (A14.1.09.426) of anatomical nomenclature, describing the area of basal forebrain below the *commissura anterior*, deep to the *globus pallidus* and dorsal to the *corpus amygdaloideum*. Based on the above mentioned explanation, it should be revised to e.g. ***substantia basalis (telencephali)*** according to its localisation and contents (*nucleus basalis* of Meynert).

The last and the largest part of the article contains a list of terms classified according to the existing chapters of the TA, related to the individual parts of the human body. It comprises terms concerning the regulation systems of the human body: endocrine glands, central and peripheral nervous system, and senses. To introduce following paragraphs, the **terms in bold Italics** are the new proposed terms to be incorporated into TA, the *terms in Italics* are existing terms of TA, terms in parentheses can be eponyms, former terms (obsolete or non-recommended terms, synonyms or explanations), and terms marked with asterisk have been already mentioned in our previous articles but it is necessary to emphasize them again. Totally 113 terms: 8 in *Glandula endocrinae*, 25 in *Systema nervosum centrale*, 12 in *Systema nervosum periphericum*, 16 in *Oculus et structurae accessoriae*, and 52 in *Auris* are presented here.

GLANDULAE ENDOCRINAE

- ***Capsula fibrosa glandulae thyroideae*** is composed of two layers and encloses a venous plexus between them.
- ***Tuberculum posterius glandulae thyroideae*** (of Zuckerkandl) is a pyramidal extension of the *glandula thyroidea*, located at the most dorsal side of each lobe. It is closely related to the *nervus laryngeus recurrens* and the *arteria thyroidea inferior*.
- ***Crista glandulae suprarenalis*** on the *facies posterior*, separates the *facies posterior* leaning against the diaphragm, and the *facies renalis* adhering to the kidney. The gland itself can be divided into the ***caput, corpus et cauda***; the *cauda* contains no medulla. On the transverse section, for purposes of pathologists, the gland can be divided into the paired lateral ***alae*** and the unpaired middle ***pars centralis***.

SYSTEMA NERVOSUM

Systema nervosum centrale

Although this chapter has been substantially extended in TA, some terms can be also added:

- ***Epiconus medullaris*** (or simply ***epiconus***) is a part of the spinal cord covering three segments (L5, S1, S2) above the *conus medullaris*. Its lesion/compression causes typical neurological symptomatology (epiconus syndrome).
- ***Fissura cerebellomesencephalica*** is located above the *pedunculi cerebellares superiores*, separates the *culmen* and the *alae lobuli centralis* from the brainstem, relates to the superior half of the roof of the fourth ventricle and contains the *arteria superior cerebelli*, *vena precentralis cerebelli* and the *nervus trochlearis*.
- ***Fissura cerebellomedullaris*** separates the *uvula, tonsillae cerebelli* and the *lobuli biventri* from the dorsolateral surface of the *medulla oblongata*, relates to the inferior half of the roof of the fourth ventricle and contains the *arteria inferior posterior cerebelli*, a vein and the *nervus trigeminus, facialis, glossopharyngeus et vagus*.
- ***Fissura cerebellopontina*** separates the cerebellum and the pons with *pedunculi cerebellares inferiores*, relates to the *recessus lateralis ventriculi quarti* and contains the *arteria inferior anterior cerebelli* and a vein.
- ***Tuberculum acusticum*** is a slight pear-shaped prominence of the floor of the *recessus lateralis ventriculi quarti*, corresponding to the underlying *nucleus cochlearis posterior*.

- *Lamina medullaris medialis thalami* is a plate of white matter in the thalamus which bifurcates rostrally and the *nuclei anteriores thalami* are situated between the split parts of the lamina — these extensions can be termed ***crus mediale et crus laterale laminae medullaris medialis thalami***.
 - ***Fissura telodiencephalica*** is a very common synonym for the *fissura transversa cerebri* and should be listed as the second, non-preferred synonym.
 - *Sulcus intraparietalis* has two extensions: ***sulcus parietalis transversus*** (of Brissaud) is a smaller superior vertical branch from the *sulcus intraparietalis*, and ***sulcus intermedius*** (of Jensen) is a larger inferior vertical branch from the *sulcus intraparietalis*, separating the *gyrus supra-marginalis* from the *gyrus angularis* (or it can be a distal and superior vertical branch of the *gyrus temporalis superior*).
 - ***Sulcus diagonalis*** (of Eberstaller) is a variable branch from the *sulcus lateralis cerebri* (of Sylvius), running from front to back, dividing the anterior portion of the *pars opercularis gyri frontalis inferioris* into two triangular portions that are positioned inversely to each other.
 - The superior and inferior surfaces of the *corpus callosum* are large but innominate structures which are well visible using computed tomography or magnetic resonance imaging. The superior surface covered by archicortex (*indusium griseum*) is in close relation to the cortex and its *gyrus cinguli*, and it can be called ***facies corticalis***. The opposite inferior surface, building the roof of the *ventriculus lateralis* and being in smaller extent in close relation to the *septum pellucidum* and *fornix* can be called ***facies profunda***, as proposed by Malobabić and Štimec [21].
 - *Nucleus accumbens* is composed of two functionally and structurally different parts: the central part termed core (***pars nuclearis***) and the medially located part termed shell (***pars tegens***).
 - *Incisura tentorii* is a notch only in a separate specimen of the *dura mater cranialis* but a foramen (“foramen ovale” [of Pacchioni]) in its original location, containing the brainstem and the *nervus oculomotorius*. This anatomical relations should evoke a discussion about possible replacement with the term ***foramen tentorii/tentoriale***.
 - ***Ligamentum petroclinoideum*** is a fold of the *dura mater cranialis* that extends between the *processus clinoideus anterior et posterior* and the *pars petrosa ossis temporalis*, and can be composed of two bands, termed ***ligamentum petroclinoideum anterius et posterius***.
 - “A cauliflower-like tuft of grains” (original description by Bochdalek) is a part of the *plexus choroideus ventriculi quarti* protruding from the *apertura lateralis ventriculi quarti* (foramen of Luschka) into the *cisterna cerebellomedullaris lateralis*. Bochdalek compared it to a round small basket of flowers or a cornucopia (Fig. 1) that is why it is termed flower basket or flower spray in English (‘Blumenkörbchen’ in German; ‘Бохдалека корзиночка’ in Russian; ‘Bochdalkův keříček’ in Czech) but it possesses no Latin term. A proposal to denominate this wonderful structure can be ***fruticulus***, a diminutive from word “frutex”, meaning a bush [2, 6].
 - ***Canalis nervi abducentis*** (of Dorello) is a bow-shaped bony enclosure surrounding the *nervus abducens* and *sinus petrosus inferior* as the two structures merge with the *sinus cavernosus*. It is found at the *apex partis petrosae ossis temporalis*, cranially bounded by the *ligamentum petrosphenoidale* (of Gruber).
 - ***Ligamentum petrosphenoidale*** (of Gruber) is a fibrous band located between the *apex partis petrosae ossis temporalis* and the *processus clinoideus posterior*.
 - *Tractus opticus* is a continuation of the *nervus opticus* fibres beyond the hemidecussation in the *chiasma opticum* and most of its fibres terminate in the *corpus geniculatum laterale* (***radix lateralis; radix metathalamica***); a smaller number of fibres enters the *brachium colliculi superioris* to terminate in the *colliculus superior* and the *area pretektalis* (***radix medialis; radix mesencephalica***); some fibres turn into the hypothalamus to end in the *nucleus supra-chiasmaticus* (***radix hypothalamica***).
 - ***Spatium perivasculare*** (space of Virchow-Robin) is a very narrow space between a larger vessel (artery or vein) and the *pia mater*. The vessel takes the *pia mater* with when entering the mass of the brain. The *pia mater* is reflected from the surface of the brain onto the surface of blood vessels in the subarachnoid space. These perivascular spaces contain interstitial fluid and are a region of leukocyte aggregation.
- Systema nervosum periphericum**
- ***Ramus trapezius nervi accessorii*** is a muscular branch from the eleventh cranial nerve coursing within the lateral cervical region to supply the homonymous muscle.

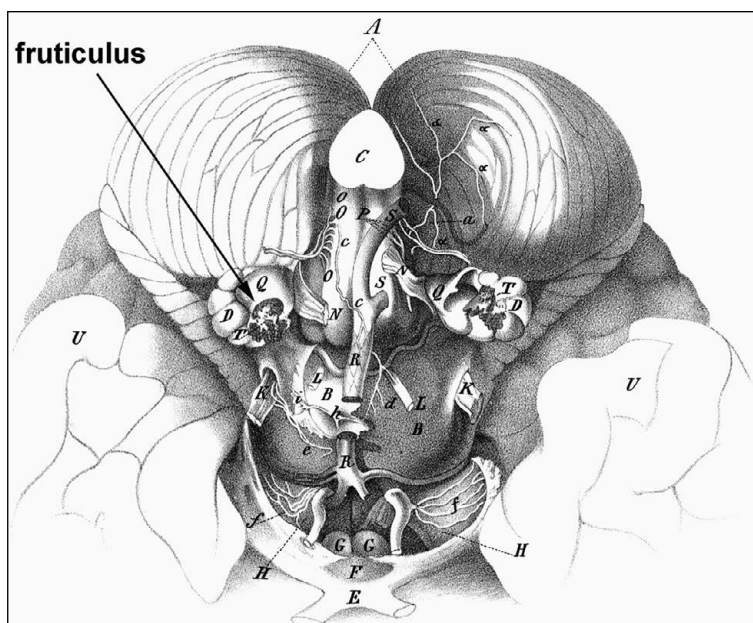


Figure 1. *Fruticulus* or flower basket or cornucopia (of Bochdalek [2])

- The general term for descriptive areas of innervation are used in neurology: **area radicularis sensoria** is the dermatome (area of skin) and the internal organs and muscles area innervated by one *radix posterior nervi spinalis* (somatic and visceral sensory innervation); **area radicularis motoria** is the myotome (several muscles or their parts) innervated by one *radix anterior nervi spinalis* (somatic motor innervation) and **area nervina** is the peripheral nerve field innervated by one peripheral nerve.
- *Ganglion sensorium nervi spinalis* is a general term listed under the *ganglion craniospinale sensorium* but a specific term for the ganglion related to the *radix posterior nervi spinalis* is missing. The general term needs a counterpart, as in case of the cranial nerves, and the simple and already widely used one is **ganglion spinale**.
- **Ansa cervicalis superficialis** is a nerve loop between the *ramus colli nervi facialis* and the *ramus superior nervi transversi colli*, situated between the *platysma* and the *musculus sternocleidomastoideus* in the upper ventrolateral part of the neck. Thus the term **ansa cervical profunda** should replace the until now used *ansa cervicalis* (nerve loop from the *plexus cervicalis* supplying the *musculi infrahyoidei*).
- A short branch emanating from the *ramus anterior nervi thoracici duodecimi* (anterior branch of the spinal nerve TXII) and joining the branch of the *ramus anterior nervi lumbalis primi* (L1) to form

the *nervus iliohypogastricus* can be termed **ramus communicans iliohypogastricus**; similarly, a short branch emanating from the *ramus anterior nervi lumbalis quarti* (LIV) and joining the descending branch of the *ramus anterior nervi lumbalis quinti* (LV) to form the *truncus lumbosacralis* can be termed **ramus communicans lumbosacralis**.

- Sensory innervation of the thigh is mediated by four nerves — two direct branches from plexuses (*nervus cutaneus femoris lateralis* from the *plexus lumbalis*, and *nervus cutaneus femoris posterior* from the *plexus sacralis*) and two indirect branches (*ramus cutaneus rami anterioris nervi obturatorii*, and *rami cutanei anteriores nervi femoralis*). To be consistent, the indirect branches can be termed similarly to the direct ones, i.e. **ramus cutaneus femoris medialis** from the *ramus anterior nervi obturatorii*, and **rami cutanei femoris anteriores** from the *nervus femoralis*.
- **Ansa sacralis** is a nerve cord connecting both *trunci sympathici* with the *ganglion impar* (of Walther).

ORGANA SENSUUM

Oculus et structurae accessoriae

- *Orbiculus ciliaris* is the flatter posterior two thirds of the *corpus ciliare* and is in clinical practice called **pars plana corporis ciliaris** (e.g. *pars plana vitrectomy*); *corona ciliaris* is the folded anterior one third of the *corpus ciliare*, producing the *humor aquosus* and suspending the lens, and is in clinical

- cal practice called *pars plicata corporis ciliaris*. The clinical terms sound more reasonable as they reflex the morphology and should be preferred.
- Expansions of the sheaths of the *musculus rectus medialis et lateralis* of the eyeball that are attached to the bony wall of the orbit (medial to the *os lacrimale*, lateral to the *tuberculum orbitale ossis zygomatici*), serve individually to prevent exaggerated action of the muscle from which they extend, and together they form a supporting hammock-like formation suspending the eyeball in the orbit. The latter is known as *lacertus musculi recti lateralis* (check ligament of lateral rectus muscle), the former can be denominated in a similar way — *lacertus musculi recti medialis* (check ligament of medial rectus muscle).
 - There are two palpebral arterial arcades which are the major source of the blood supply of conjunctiva. *Arcus palpebralis marginalis* is an anastomosis between the *rami palpebrales mediales* and the *rami palpebrales laterales* in both eyelids, located 2 mm from the *margo palpebrae*, in the submuscular plane in front of the *tarsus*. *Arcus palpebralis centralis* is an anastomosis between another branches from the *rami palpebrales mediales* and the *rami palpebrales laterales* in both eyelids, located near the peripheral border of *tarsus*. Both arcades send *rami perforantes* for nutrition of the *tarsus* and the *tunica conjunctiva*.
 - The eyelid features two margins: a visible *margo liber palpebrae* is the free margin heading towards the *rima palpebrarum*; *margo orbitalis palpebrae* is the hidden one fixating the eyelid to the *septum orbitale*, and consequently to the bony wall of the orbit.
 - The upper lid can be divided into two parts: the upper *pars orbitalis*, and the lower *pars tarsalis*, containing the *tarsus superior*.
 - *Sulcus subtarsalis* is a groove in the *facies posterior palpebrae* near the *margo liber palpebrae*, a free margin of the eyelid, and which is also parallel to it. It separates the *pars marginalis tunicae conjunctivae palpebrarum* from the *pars tarsalis tunicae conjunctivae palpebrarum*, and provides potential space for lodging of foreign bodies.
 - *Canaliculus lacrimalis communis* is a short duct (present in 90% of cases) formed by fusion of the *canaliculus lacrimalis superior et inferior*, and empties into the *saccus lacrimalis*.
 - *Saccus lacrimalis* can be divided into two parts: *fundus* projecting above the *ligamentum palpebrale mediale*, and *corpus*, being the larger part below.

Auris

- The auricle features two until now innominate surfaces — *facies lateralis* (comprising the positive and negative spatial structures including *cavitas conchae*, the entrance to the *meatus acusticus externus*), and *facies medialis* (with opposite structures to the former ones). *Crura antihelicis* can be classified as *crus antihelicis superius et inferius* bounding the *fossa triangularis*.
- Between the *eminentia fossae triangularis* and the *eminentia conchae*, there is a shallow groove termed *sulcus transversus antihelicis* which corresponds to the course of the *crus antihelicis inferior*. There is an oblique crest — *ponticulus auriculae* — running across the *eminentia conchae* serving for insertion of the *musculus auricularis posterior*.
- There exist ligaments of the auricle which fix it to the head (*ligamentum auriculae anterius, posterius et superius*), and small proper ligaments between certain structures of the auricle itself: *ligamentum tragohelicinum* extending between the *tragus* and the *spina helix* which contributes to the cartilaginous border of the entrance into the *concha auriculae*; and *ligamentum helicoantihelicinum* extending between the *cauda helix* and the *antihelix* filling the *fissura antitragohelicina*.
- *Porus acusticus externus* is a term designed for two different structures: first it is the bony entrance to the bony *meatus acusticus externus*, termed the external acoustic opening in English, and listed in the chapter 'Ossa' under A02.1.06.054; second it is the cartilaginous entrance (covered with skin) to the *meatus acusticus externus cartilagineus*, termed the external acoustic pore or the external acoustic aperture in English, located in the *cavitas conchae* and partly covered with the *tragus*, listed in the chapter 'Organa sensuum' under A15.3.01.046. These two terms should be distinguished by specifying adjectives: *porus acusticus externus osseus et cartilagineus*, and unified in English as well. In a similar way, the bony and cartilaginous parts (segments) of the *meatus acusticus externus* should be refined as the general term *meatus acusticus externus* featuring *pars ossea et pars cartilaginea meatus acustici externi*, instead of the *meatus acusticus externus cartilagineus* and the nonspecific *meatus acusticus externus*, the latter listed in the chapter 'Ossa' under A02.1.06.055, and in the chapter 'Organa sensuum' under A15.3.01.045.
- There are two physiological narrowings (constrictions) in the *meatus acustici externi*. The lateral

- one is located just internally to the transition between the *pars cartilaginea et ossea*, the medial one is situated in the *pars ossea* approximately 20 mm from the floor of the *concha auriculae*. They can be termed and distinguished as ***isthmus meatus acustici externi medialis et lateralis***.
- *Meatus acusticus externus cartilagineus* is continuous with the *cartilago auriculae* ventrally, where it merges with the *lamina tragi* but discontinuous caudally and dorsally where both cartilages are separated with a deep notch — ***incisura terminalis auris*** — filled with collagenous tissue. Both cartilages are thus connected by a narrow bridge called the isthmus (***isthmus cartilaginis auris***) and that is why the complex of the *cartilago auriculae* and the *cartilago meatus acustici* should be termed ***cartilago auris***.
 - A membrane between *crus anterius et posterius stapedis* is innominate and can be simply termed ***membrana stapedia***; the free space bordered by the *crura stapedis* and the *basis stapedis*, filled with the *membrana stapedia*, should be termed (in a similar way to the *foramen obturatum* located among three bones and closed with a membrane) as ***foramen stapedis***.
 - A fibrous juncture between the *membrana tympani* and the *manubrium mallei* is innominate and can be termed ***syndesmosis tympanomallearis***.
 - A space in the posterior part of the *cavitas tympani* (“retrotympanum”) extends into four recesses bordered by four bony ridges, some of them are officially termed, some still lack their valid terms. The central bony landmark of the *paries mastoideus* is the *eminetia pyramidalis* and small bony ridges are detached in different direction:
 - ***crista chordae tympani*** (chordal ridge) laterally;
 - ***crista infrapyramidalis*** (pyramidal ridge) caudally;
 - ***crista suprapyramidalis*** cranially;
 - *ponticulus* medially.
 These ridges then form four recesses between the *promontorium* and the *sinus tympanicus* (which terminology is ameliorated here):
 - ***sinus tympanicus posterior*** (in TA as “*sinus posterior*”) mediocranially — bordered medially by the ***commissura posterior fenestrae vestibuli***, laterocranially by the *prominentia canalis nervi facialis*, and caudally by the *ponticulus*;
 - ***sinus tympanicus*** (in TA as “*sinus tympani*”) mediocaudally — bordered cranially by the *ponticulus*, caudally by the *subiculum*, laterally by the *crista infrapyramidalis*, and medially by the *promontorium*;
 - ***sinus tympanicus lateralis*** laterocaudally — bordered by three eminencies of the “styloid complex”: *eminetia pyramidalis*, *prominentia styloidea*, and ***eminetia chordae tympani***;
 - ***sinus facialis*** (in TA as “*recessus facialis*”) laterocranially — a triangle bordered cranially by the *fossa incudis* and on sides by the *chorda tympani* and the *nervus facialis*.
 There are three additional structures in this area:
 - an innominate communication beneath the *ponticulus* between the cranial *sinus tympanicus posterior* and the caudal *sinus tympanicus*;
 - ***fossa suprapyramidalis*** (of Sappey) is an air cell of the *sinus facialis* at the laterocaudal part of the sinus, just above the *crista chordae tympani*;
 - ***pseudosubiculum*** is an additional bony ridge caudal to the *subiculum* and separating the *sinus tympanicus* and a depression of the *fenestra cochleae*.
 - *Paries caroticus cavitatis tympani* contains several openings or passages for air, muscle, nerve and vessels. These openings should be termed similarly to other such structures and completed within the subchapter concerning the middle ear and the tympanic cavity:
 - ***ostium tympanicum canalis nervi petrosi minoris*** is located at the transition of the anterior and superior wall of the tympanic cavity, serving for the *nervus petrosus minor* and the *vasa tympanica superiora*;
 - *fissura petrotympanica* (of Glaser) in the lower part of the anterior wall, containing the *vasa tympanica anteriora* and the *ligamentum mallei anterius*;
 - ***canaliculus chordae tympani anterior*** (of Huguier and Civinini) is a short canal in the medial part of the *fissura petrotympanica* transmitting the *chorda tympani*, and ***canaliculus chordae tympani posterior*** is a short canal branching from the *pars mastoidea canalis nervi facialis* and opening on the *paries mastoideus cavitatis tympani* into the tympanic cavity, containing the *chorda tympani* and the *vasa tympanica posteriora*;
 - *canaliculi caroticotympanici* connect the tympanic cavity and the *canalis caroticus*, transmitting the *rami et nervi caroticotympanici*;
 - *canalis musculotubarius*, composed of two parts — the upper *semicanalis muscoli tenso-*

ris tympani and the lower *semicanalis tubae auditivae*.

- **Ponticulus promontorii** is a thin bony bridge from the *eminentia pyramidalis* to the *promontorium*.
- **Angulus sinuduralis** (of Citelli) is formed by dura mater of the *fossa cranii media* and the ventrocranial surface of the *sinus sigmoideus*. The floor of the angle is bound by the *sinus petrosus superior*. In a well pneumatized bone, small air cells occupy the angle.
- **Lamina petrosquamosa** (of Körner; clinically termed Körner's septum) is a bony plate separating the *cellulae squamosae*, and the *cellulae petrosae*, lying deep to the *sutura petrosquamosa*, and stretching from the posterior aspect of the *fossa mandibularis*, extending above the *cavitas tympani*, coursing caudally and passing laterally to the *canalis nervi facialis* towards the apex of the *processus mastoideus*. It serves as an important surgical landmark within the *cellulae mastoideae*.
- **Corpus adiposum tubae auditivae** (of Ostmann) is a triangular fat pad located mediocaudally to the *tuba auditiva*, and laterocranially to the *musculus tensor veli palatini*, and is thought to be important in normal closure of the tube, preventing transmission of nasopharyngeal pressure to the middle ear cavity.
- The mastoid air cell system (*cellulae mastoideae*) is categorised according to various regions of the temporal bone [1]:
 - **cellulae squanomastoideae** include the *antrum mastoideum* and the adjacent air cells: central mastoid tract (**cellulae mastoideae centrales**), and peripheral air cell tract (**cellulae mastoideae periphericae**);
 - **cellulae perilabyrinthicae**, which can be further divided according to their relationship to the *labyrinthus osseus* into **cellulae supralabyrinthicae et infralabyrinthicae**;
 - **cellulae petrosae** located inside the *pars petrosa ossis temporalis*, and their subgroup within the *apex partis petrosae* termed **cellulae petrosae apicales**;
 - **cellulae accessoriae** comprise the air cells inside the *processus zygomaticus ossis temporalis* (**cellulae zygomaticae**), **cellulae occipitales**, **cellulae squamosae et cellulae styloideae**.

DISCUSSION

The problem of a precise, correct and detailed anatomical nomenclature is bothering anatomists from the 19th century. Many steps were achieved

and the process is still continuing. This set of articles should provoke further discussion as we have noticed that many tiny groups of neurons are listed in TA as nuclei and their subnuclei, but many gross anatomical structures are missing there. This discrepancy caused by tremendous research boom in the neuroscience should be balanced by incorporating all structures of the human body, visible by naked eye, and usually already described years ago.

This list of terms brings a proof that an extension of TA is one of the processes which will probably never end but is one of the most important tasks in the terminological work and research. From 1895, the number of terms within the anatomical nomenclature has doubled. Until now the only officially valid language in the anatomical nomenclature has been Latin. Worldwide, it is a gold standard in the description of any morphological structure or unit. But the current language of science is the English. The plan for the next edition of TA is to have both Latin and English terms official, and to have only one preferred term; the other terms shall be listed as mere (non-preferred) synonyms, e.g. *fibularis* (because we use the term *fibula* as well) as the preferred term, and "peroneus" as a mere (non-preferred) synonym (because the term "perone" (*περόνη*) is a Greek word for the calf-bone but it is used as a technical term neither in anatomy nor in clinical practice).

Another aspect concerns the clinical extensions of TA. Until now, only anatomists have been involved in its amelioration, with an exception of the phlebological field. Fortunately, in years 2002 and 2005, two consensus documents extending and revising the venous parts of TA have been approved by IFAA and International Union of Phlebology. They concern the superficial and deep veins of the lower limb [5, 17, 18, 20] and the veins of the pelvis [4, 19]. Although they are quite detailed and involve even the venous perforators, some structures situated mainly within the foot are missing [27]. Such activities of the clinicians and clinical anatomists are cordially welcome and principal for further life and credit of TA.

Some terms, proposed in articles, are open to further discussion, such as *fascia postauricularis* [26], or they lack their Latin counterparts, and have to be completed and ameliorated [10]. The process of nomenclature revision is a never-ending story but it must not cease or stop otherwise the communication would become more difficult, unprecise and misleading in future.

The aims of this series of articles are to evoke a discussion concerning the above listed terms if necessary but mainly to show the way how to ameliorate the

anatomical nomenclature to all the morphologists, physicians, scientists and other people interested in this topic. Detailed, unanimous and precise nomenclature is a necessary tool for librarians and IT specialists dealing with databases and searching tools, for correctors and reviewers, for translators and teachers.

CONCLUSIONS

Terminologia Anatomica is strong in anatomical communication but it should reach such position also among all medical specialists. Opened discussion about its fundamental points, grammatical aspects, contents and clinical extensions is the only way to achieve this goal. Otherwise, TA would slowly sink to the dust of forgotten shelves in our libraries.

Acknowledgements

The authors thank Miroslava Plecítá for help in obtaining the cited articles. The study was supported by the Charles University, Project PRVOUK #33.

REFERENCES

- Allam AF. Pneumatization of the temporal bone. *Ann Otol Rhinol Laryngol.* 1969; 78(1): 49–64, doi: [10.1177/000348946907800105](https://doi.org/10.1177/000348946907800105), indexed in Pubmed: [5763190](https://pubmed.ncbi.nlm.nih.gov/5763190/).
- Bochdalek VA. Anleitung zur praktischen Zergliederung des menschlichen Gehirnes, nebst einer anatomischen Beschreibung desselben; mit besonderer Rücksicht auf das kleine Gehirn. Gottlieb Haase Söhne, Prag 1833.
- Bradford MD, Thorpe D, DeLuna V, et al. Frequency in Usage of Terminologia Anatomica Terms by Clinical Anatomists. *J Biomed Edu.* 2014; 2014: 1–9, doi: [10.1155/2014/950898](https://doi.org/10.1155/2014/950898).
- Caggiati A, Bergan JJ, Gloviczki P, et al. International Interdisciplinary Consensus Committee on Venous Anatomical Terminology. Nomenclature of the veins of the lower limb: extensions, refinements, and clinical application. *J Vasc Surg.* 2005; 41(4): 719–724, doi: [10.1016/j.jvs.2005.01.018](https://doi.org/10.1016/j.jvs.2005.01.018), indexed in Pubmed: [15874941](https://pubmed.ncbi.nlm.nih.gov/15874941/).
- Caggiati A, Bergan J, Gloviczki P, et al. Nomenclature of the veins of the lower limbs: An international interdisciplinary consensus statement. *J Vasc Surg.* 2002; 36(2): 416–422, doi: [10.1067/mva.2002.125847](https://doi.org/10.1067/mva.2002.125847).
- Chváta A, Kachlik D, Vincenc Alexandr Bohdálék (1801–1883): Czech anatomist and neuroscientist of the nineteenth century. *J Hist Neurosci.* 2017; 26(2): 125–139, doi: [10.1080/0964704X.2016.1150671](https://doi.org/10.1080/0964704X.2016.1150671), indexed in Pubmed: [26927541](https://pubmed.ncbi.nlm.nih.gov/26927541/).
- FCAT Terminologia anatomica. Thieme Verlag, Stuttgart 1998.
- FICAT Terminologia Embryologica: International Embryological Terminology. Thieme Verlag, Stuttgart 2013.
- Gobée O, Jansma D, DeRuiter M. AnatomicalTerms.info: Heading for an online solution to the anatomical synonym problem hurdles in data-reuse from the Terminologia Anatomica and the foundational model of anatomy and potentials for future development. *Clin Anat.* 2011; 24(7): 817–830, doi: [10.1002/ca.21185](https://doi.org/10.1002/ca.21185).
- Hennekam RCM, Allanson JE, Biesecker LG, et al. Elements of morphology: standard terminology for the external genitalia. *Am J Med Genet A.* 2013; 161A(6): 1238–1263, doi: [10.1002/ajmg.a.35934](https://doi.org/10.1002/ajmg.a.35934), indexed in Pubmed: [23650202](https://pubmed.ncbi.nlm.nih.gov/23650202/).
- Hirsch BE. Does the Terminologia Anatomica really matter? *Clin Anat.* 2011; 24(4): 503–504, doi: [10.1002/ca.21140](https://doi.org/10.1002/ca.21140), indexed in Pubmed: [21509816](https://pubmed.ncbi.nlm.nih.gov/21509816/).
- Iyer NG, Shaha AR, Ferlito A, et al. Delphian node metastasis in head and neck cancers--oracle or myth? *J Surg Oncol.* 2010; 102(4): 354–358, doi: [10.1002/jso.21640](https://doi.org/10.1002/jso.21640), indexed in Pubmed: [20589710](https://pubmed.ncbi.nlm.nih.gov/20589710/).
- Kachlik D, Baca V, Bozdechova I, et al. Anatomical terminology and nomenclature: past, present and highlights. *Surg Radiol Anat.* 2008; 30(6): 459–466, doi: [10.1007/s00276-008-0357-y](https://doi.org/10.1007/s00276-008-0357-y), indexed in Pubmed: [18488135](https://pubmed.ncbi.nlm.nih.gov/18488135/).
- Kachlik D, Bozdechova I, Cech P, et al. Mistakes in the usage of anatomical terminology in clinical practice. *Biomed Pap.* 2009; 153(2): 157–161, indexed in Pubmed: [19771143](https://pubmed.ncbi.nlm.nih.gov/19771143/).
- Kachlik D, Musil V, Baca V. Terminologia Anatomica after 17 years: inconsistencies, mistakes and new proposals. *Ann Anat.* 2015; 201: 8–16, doi: [10.1016/j.aanat.2015.04.006](https://doi.org/10.1016/j.aanat.2015.04.006), indexed in Pubmed: [26094127](https://pubmed.ncbi.nlm.nih.gov/26094127/).
- Kachlik D, Musil V, Baca V. Contribution to the anatomical nomenclature concerning general anatomy and anatomical variations. *Surg Radiol Anat.* 2016; 38(7): 757–765, doi: [10.1007/s00276-016-1627-8](https://doi.org/10.1007/s00276-016-1627-8), indexed in Pubmed: [26946463](https://pubmed.ncbi.nlm.nih.gov/26946463/).
- Kachlik D, Pechacek V, Baca V, et al. The superficial venous system of the lower extremity: new nomenclature. *Phlebology.* 2010; 25(3): 113–123, doi: [10.1258/phleb.2009.009046](https://doi.org/10.1258/phleb.2009.009046), indexed in Pubmed: [20483860](https://pubmed.ncbi.nlm.nih.gov/20483860/).
- Kachlik D, Pechacek V, Musil V, et al. Information on the changes in the revised anatomical nomenclature of the lower limb veins. *Biomed Pap.* 2010; 154(1): 93–97, indexed in Pubmed: [20445717](https://pubmed.ncbi.nlm.nih.gov/20445717/).
- Kachlik D, Pechacek V, Musil V, et al. The venous system of the pelvis: new nomenclature. *Phlebology.* 2010; 25(4): 162–173, doi: [10.1258/phleb.2010.010006](https://doi.org/10.1258/phleb.2010.010006), indexed in Pubmed: [20656953](https://pubmed.ncbi.nlm.nih.gov/20656953/).
- Kachlik D, Pechacek V, Musil V, et al. The deep venous system of the lower extremity: new nomenclature. *Phlebology.* 2012; 27(2): 48–58, doi: [10.1258/phleb.2011.010081](https://doi.org/10.1258/phleb.2011.010081), indexed in Pubmed: [21821722](https://pubmed.ncbi.nlm.nih.gov/21821722/).
- Malobabić S, Štimec B. A note to corpus callosum's nomenclature. *Fol Anat Jugoslavia.* 1989-1990: 19–20:13–16.
- Manzanares-Céspedes MC. On-line Terminologia Anatomica: a proposal. *Anat Sci Educ.* 2010; 3(3): 154–155, doi: [10.1002/ase.149](https://doi.org/10.1002/ase.149), indexed in Pubmed: [20496437](https://pubmed.ncbi.nlm.nih.gov/20496437/).
- Martin BD, Thorpe D, Barnes R, et al. Frequency in usage of FCAT-approved anatomical terms by North American anatomists. *Anat Sci Educ.* 2009; 2(3): 94–106, doi: [10.1002/ase.83](https://doi.org/10.1002/ase.83), indexed in Pubmed: [19459207](https://pubmed.ncbi.nlm.nih.gov/19459207/).
- Martin BD, Thorpe D, Merenda V, et al. Contrast in usage of FCAT-approved anatomical terminology between members of two anatomy associations in North America. *Anat Sci Educ.* 2010; 3(1): 25–32, doi: [10.1002/ase.114](https://doi.org/10.1002/ase.114), indexed in Pubmed: [19890984](https://pubmed.ncbi.nlm.nih.gov/19890984/).
- Pawlina W, Drake R. Moving forward with Terminologia Anatomica. *Anat Sci Educ.* 2009; 2(3): 93, doi: [10.1002/ase.89](https://doi.org/10.1002/ase.89), indexed in Pubmed: [19496153](https://pubmed.ncbi.nlm.nih.gov/19496153/).
- Shokrollahi K, Taylor JP, Le Roux CM, et al. The postauricular fascia: classification, anatomy, and potential surgical applications. *Ann Plast Surg.* 2014; 73(1): 92–97, doi: [10.1097/SAP.0b013e31826cb2b5](https://doi.org/10.1097/SAP.0b013e31826cb2b5), indexed in Pubmed: [23657044](https://pubmed.ncbi.nlm.nih.gov/23657044/).
- Uhl JF, Gillot C. The plantar venous pump: Anatomy and physiological hypotheses. *Phlebology.* 2019; 17: 151–158.
- Woerdeman MW. *Nomina anatomica parisiensia* (1955) et BNA (1895). Ossthoek, Utrecht 1957.