

# Intestinal malrotations: a review and report of thirty cases

S. Aslanabadi<sup>1, 2</sup>, A. Ghalehgalab-Behbahan<sup>3</sup>, M. Jamshidi<sup>1</sup>, P. Veisi<sup>4</sup>, S. Zarrintan<sup>4, 5</sup>

<sup>1</sup>Division of Paediatric Surgery, Children's Hospital, Tabriz University of Medical Sciences, Tabriz, Iran

<sup>2</sup>Paediatrics Research Team, Tabriz University of Medical Sciences, Tabriz, Iran

<sup>3</sup>Department of Paediatrics, Faculty of Medicine, Tabriz University of Medical Sciences, Tabriz, Iran

<sup>4</sup>Faculty of Medicine, Tabriz University of Medical Sciences, Tabriz, Iran

<sup>5</sup>Student Research Centre, Tabriz University of Medical Sciences, Tabriz, Iran

[Received 2 May 2007; Revised 5 July 2007; Accepted 5 July 2007]

*Intestinal malrotation is a developmental anomaly affecting the position and peritoneal attachments of the small and large bowels during organogenesis in foetal life. It has been defined as absent or incomplete rotation and fixation of the embryonic gut around the superior mesenteric artery. In the present paper, we review the definition, history, embryology/aetiology, epidemiology, symptoms and signs, diagnosis and treatment of intestinal malformations. Moreover, we report the records of 30 cases of malrotation admitted to our department over a period of five years. The final intraoperative diagnosis of the cases presented was 53.3% pure malrotation, 33.3% malrotation with mid-gut volvulus, 6.7% malrotation with duodenal atresia, 3.3% malrotation with Meckel's diverticulum and duodenal atresia, and 3.3% malrotation and biliary atresia. Preoperative imaging studies were performed for 27 cases and surgical management was successfully conducted without any mortality among the cases studied. This article provides an overview of basic and clinical aspects of intestinal malrotation. In addition, the signs and symptoms, imaging findings, and final intraoperative diagnoses presented by the subjects reported on are of potential use and clinical interest.*

**Key words:** malrotation, embryology, intestine, organogenesis

## DEFINITION

Intestinal malrotation is a developmental anomaly affecting the position and peritoneal attachments of the small and large bowels during organogenesis in foetal life. It has been defined as absent or incomplete rotation and fixation of the embryonic gut around the superior mesenteric artery (SMA) [4, 14].

## HISTORY

Malrotation was first noted by Mall in 1898 [1]. There are pre-20<sup>th</sup> century reports of malrotation. In 1923 the first clear clinical correlation with embry-

logical observation was mentioned by Dorr. In 1928 Waugh described two cases of volvulus due to non-rotation. In 1936 William E. Ladd [14] wrote a classic article on the treatment of malrotation, introducing his surgical approach, "Ladd's procedure", which remains the cornerstone of practice today.

## EMBRYOLOGY/AETIOLOGY

Normal gut rotation places the two ends of the intestinal tract, namely the proximal duodenojejunal loop and the distal caecocolic loop, simultaneously in their proper positions [18]. In this process, which

takes place from the 5<sup>th</sup> to the 12<sup>th</sup> gestational weeks, the developing primary mid-gut "herniates" into the base of the umbilical cord, returns and becomes fixed in a reasonably predictable fashion, having undergone as much as 270° counter-clockwise rotation around the axis of the SMA, such that the proximal (prearterial) portion of the loop comes to reside posterior to the SMA. Its more cranial portion takes part in the formation of the proximal duodenum, and the more caudal portion passes posterior to and becomes fixed to the left of the SMA, lying horizontally and forming the third and fourth portions of the duodenum, which are normally attached to the posterior body wall at the ligament of Treitz to the left of the aorta.

The embryonic postarterial segment of the mid-gut gives rise to the terminal ileum, caecum and the segment anterior to the SMA. Thus the caecum is positioned initially to the left, then anterior to and ultimately to the right of the SMA before becoming fixed in its final adult location in the right iliac fossa. Whatever the cause, disruption of this rotating mechanism can result in non-rotation or incomplete rotation at the time of the event. Previous case reports have suggested a strong concordance of intestinal malrotation between identical twins and even between non-twin siblings. Genetic factors may thus play some role in its pathogenesis [1, 3, 8, 16, 18].

### EPIDEMIOLOGY

Intestinal malrotation occurs at a rate of 1 in 500 live births. Male predominance exists in neonatal presentations at a male-to-female ratio of 2:1. Up to 40% of patients with malrotation present within the first week of life, 50% up to one month of age and 75% by the age of one year. The remaining 25% of patients present later, even into adult life. There is no sexual bias among patients older than one year [14].

### SYMPTOMS AND SIGNS

The antenatal diagnosis of malrotation can be suggested by identification of its complications, such as bowel dilatation, ascites or meconium peritonitis. Malrotation can be associated with a narrow mesenteric base, an anatomical arrangement predisposing to potentially fatal mid-gut volvulus and infarction [8], which are the main complications of malrotation. After birth therefore the diagnosis is usually established on the basis of abdominal pain and bilious vomiting secondary to bowel obstruction. Although bilious vomiting is the presenting symptom among almost all patients diagnosed in

the neonatal period, clinical features of older patients (infants or children) include chronic or recurrent colicky abdominal pain, intermittent constipation, solid food intolerance, abdominal distension, recurrent non-bilious vomiting, malabsorption/chronic diarrhoea, failure to thrive [2, 10], common bile duct obstruction, intestinal obstruction, gastrointestinal bleeding, peritonitis and even septic shock.

Malrotation can cause internal herniation, it usually has a chronic picture, while its physical examination findings can be unremarkable, and diagnosis is made by radiological studies and the index of suspicion only. Left mesentericoparietal hernias may cause haematochezia, haemorrhoids and dilated anterior abdominal veins which are related to venous obstruction. If the bowel of the patient is obstructed at the time of presentation, abdominal tenderness and guarding may be present, and a soft globular mass may be palpated at the location of the hernia [14].

Intestinal malrotation in an adult may present by the subsets of acute intestinal ischaemia including mesenteric arterial occlusion, venous thrombosis and non-occlusive mesenteric ischaemia [4, 17].

The attribution of symptoms and signs to malrotation is further confounded by the presence of dysmotility in many of these patients, who will maintain these symptoms and signs despite correction of the malrotation [7].

Malrotation may occur in association with other congenital abnormalities including congenital heart disease, short small bowel, diaphragmatic hernias, biliary or oesophageal atresia, duodenal or jejunal web or atresia, mesenteric cyst, omphalocele, gastroschisis, imperforate anus, persistent cloaca, Hirschsprung's disease, Meckel's diverticulum and trisomy 21/mental retardation [1, 6, 9, 14].

### DIAGNOSIS

Clinical investigation hinges on the upper gastrointestinal contrast study, while some experts also advocate a routine contrast enema to determine the position of the caecum if it is not seen on the follow-through films. The upper gastrointestinal contrast study derives most of its diagnostic information by defining the position of the duodenojejunal (D-J) flexure with respect to the pylorus and vertebral column. Other findings, such as volvulus, duodenal obstruction, paucity of air in the distal small bowel, the position of the caecum on follow-through films and the position of the proximal loops of the jejunum are also useful. Typically, malrotation with

volvulus produces an incomplete obstruction of the descending or distal duodenum with the appearance of extrinsic compression and torsion, variably described as "bird's beak", "corkscrew" or "coiled" in appearance. Malrotation is diagnosed if the D–J flexure is inferior to the pylorus, unless the stomach is grossly distended, in which case the stomach is emptied and the flexure reassessed, or to the right of the left vertebral pedicle [1, 8]. With malrotation, the small bowel typically resides in the right abdomen and the colon and caecum are often on the left. The contrast enema is less reliable in identifying malrotation because the position of the caecum and colon are highly variable and may even be normal. The finding of a high right-sided or left sided caecum is consistent with malrotation.

Other investigations that have been reported to diagnose malrotation or volvulus incidentally include:

- plain abdominal X-ray film. This may show the double bubble sign, the classic finding of duodenal obstruction, if present. However, a patient with mid-gut volvulus may have a normal radiograph [1, 15]. Distended bowel loops and possibly *pneumatosis intestinalis* may be observed if necrotising enterocolitis is present. A left lateral decubitus radiograph can discover free air in the abdomen, if this exists [14];
- ultrasonography. This has been shown to have almost 100% sensitivity in detecting neonatal malrotation, although it depends on the experience of the ultrasonographers. The highest sensitivity is achieved when inversion of the SMA and the superior mesenteric vein (SMV) is shown. Other diagnostic findings are fixed midline bowel loops and duodenal dilation with distal tapering. Volvulus is also highly probable if the SMV is shown to be coiling around the SMA. All features are enhanced if water is instilled first by the nasogastric (NG) tube [14, 19];
- computed tomography (CT) scanning. This is not well developed for diagnosing malrotation and mid-gut volvulus and therefore is not recommended as the principal diagnostic tool [5, 13, 14];
- air enema [12];
- scintigraphy [11].

These modalities are not accepted as being suitable first-line investigations in most instances.

## TREATMENT

The surgical management of malrotation is mainly based on Ladd's procedure. Preoperative preparation for symptomatic patients does not differ from

that for other seriously ill cases that need emergency laparotomy. Management includes intravenous fluid resuscitation, nasogastric decompression, urinary catheter insertion and medical intervention for electrolyte imbalances and respiratory disturbances. Antibiotic coverage is necessary as well.

Prompt exploration is warranted in all symptomatic patients. Supraumbilical transverse incision is preferred in infants and children for generous exposure of the right upper quadrant. After rapid exploration, evisceration of the intestines is essential to assess the anatomical abnormality. Volvulus, if present, is relieved by rotating the intestine in a counter-clockwise direction. A period of intestinal warming is often necessary. If either the scope of the resection is excessive or the viability of the bowel cannot be adequately assessed, the following principles are involved in intestinal salvage: resection of the non-viable bowel, preservation of the marginal tissues to preserve length and possible exteriorisation and re-exploration. In cases of entire mid-gut infarction, closure without resection and terminal care may be the appropriate approach.

The next step is to broaden the base of the mesenteric pedicle by dividing the peritoneal bands that tether the small bowel and colon mesentery. Injury to the vessels and the pancreas must be avoided. Ladd's peritoneal bands must be completely divided to relieve any duodenal obstruction. Appendectomy must be performed because the malpositioned appendix can make future appendicitis a difficult diagnosis later. At the conclusion of the procedure, the intestine is replaced into the abdomen without mesentery torsion and generally with the small intestine on the right and the caecum and colon on the left.

Efforts to secure the mesentery surgically by caecal or duodenal attachment to the posterior abdominal wall have been abandoned for lack of supportive data.

If malrotation is discovered incidentally, either in a clinical/paraclinical work-up for other diseases or during laparotomy for any reason, the common trend will be toward performing Ladd's procedure.

## OUR CASES

We reviewed the records of 30 cases of malrotation who were admitted to the Division of Paediatric Surgery, Tabriz Children's Hospital (affiliated to Tabriz University of Medical Sciences) between the years 2001 and 2006. Their demographic data and presenting signs and symptoms, which were common

**Table 1.** Demographic data and presenting signs and symptoms of our 30 cases of malrotation

Findings		Frequency
Sex	Male	17 (56.7%)
	Female	13 (43.3%)
Age	Neonate	17 (56.7%)
	Infant	7 (23.3%)
	Child (preschool age)	6 (20%)
Spectrum of presenting symptoms	Bilious vomiting	16 (53.3%)
	Non-bilious vomiting	5 (16.7%)
	Abdominal pain	5 (16.7%)
	Faecal vomiting	2 (6.7%)
	Abdominal distension	2 (6.7%)
	Multiple gross anomaly	1 (3.3%)
	Prolonged icterus	1 (3.3%)

findings of partial, complete, or intermittent upper gastrointestinal obstruction are shown in Table 1.

Diagnostic imaging studies were made of 27 cases before surgery, the other 3 cases having been transferred to the operating theatre as emergencies with overt signs of gastrointestinal obstruction. These imaging studies and their results have been described in Table 2. In some case a variety of examinations were carried out.

Figure 1 shows a plain abdominal X-ray film of a malrotation case with gastric distension and distal intestinal air. In addition, a barium enema of one of the presented cases is illustrated in Figure 2.

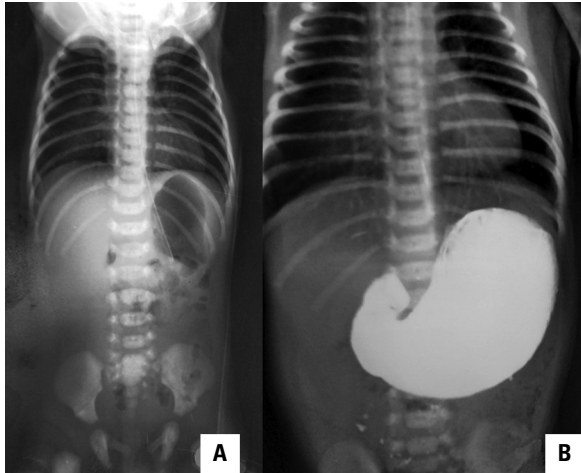
A thorough investigation was also carried out to uncover any associated anomaly in the studied cases of malrotation. This disclosed the following wide spectrum of extraintestinal derangements in 5 out of the 30 patients:

- Case 2: with Down’s syndrome, ambiguous genitalia and congenital heart disease (complete atrioventricular canal);
- Case 11: with congenital heart disease (mitral regurgitation, atrial septal defect and severe pulmonary arterial hypertension);
- Case 13: with congenital heart disease (atrial septal defect and ventricular septal defect);
- Case 18: congenital heart disease (patent ductus arteriosus, atrial septal defect and pulmonary arterial hypertension);
- Case 26: imperforated anus, ectopic kidney and vertebral anomalies.

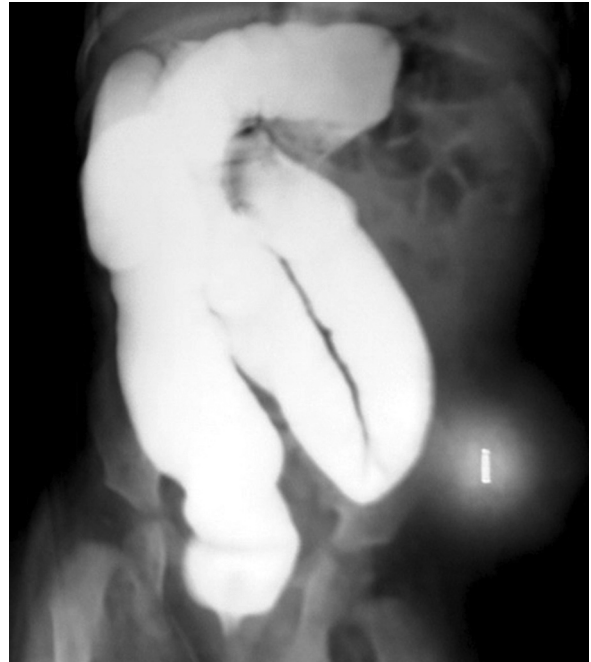Surgical management of all the patients studied was achieved successfully without any mortality. The surgical procedures and intraoperative final diagnoses are summarised in Table 3. Figures 3 and 4 present two intraoperative photographs of the malrotation cases mentioned.

**Table 2.** Imaging studies and their results in 27 cases of malrotation

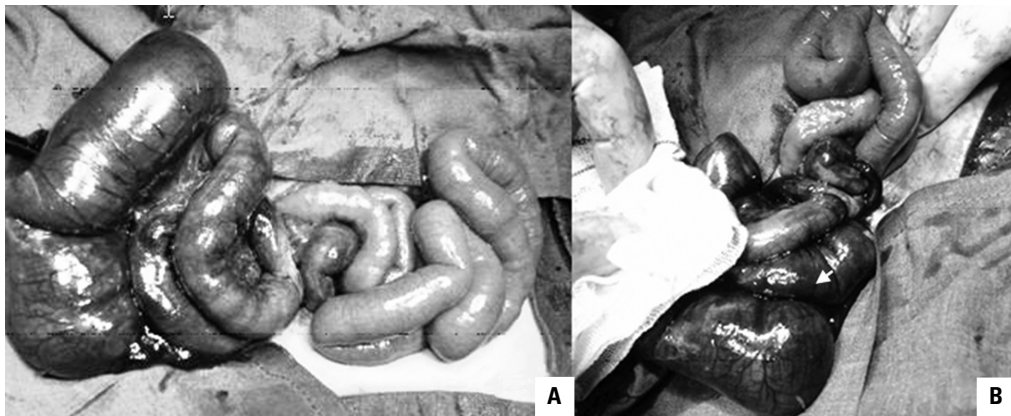
Type of imaging studies	Number of studied cases	Reported findings	Number of cases	
Plain abdominal X-ray films	27	Gastric or duodenal distension	Present	22 (81.5%)
			Absent	5 (18.5%)
		Distal duodenal air	Normal	13 (48.1%)
			Decreased	4 (14.8%)
			Absent	10 (37.0%)
			Reported double bubble sign	4 (14.8%)
Upper gastrointestinal contrast seriography follow-through films	14	Bowel obstruction	Complete	6 (42.9%)
			Partial	4 (28.6%)
			None	4 (28.6%)
		Displacement of bowel or ligamentum Treitz	Present	4 (28.6%)
			Absent	10 (71.4%)
			Cecum malposition	Present
Absent	8 (57.1%)			
Barium enema	8	Caecum malposition	Present	4 (50%)
			Absent	4 (50%)



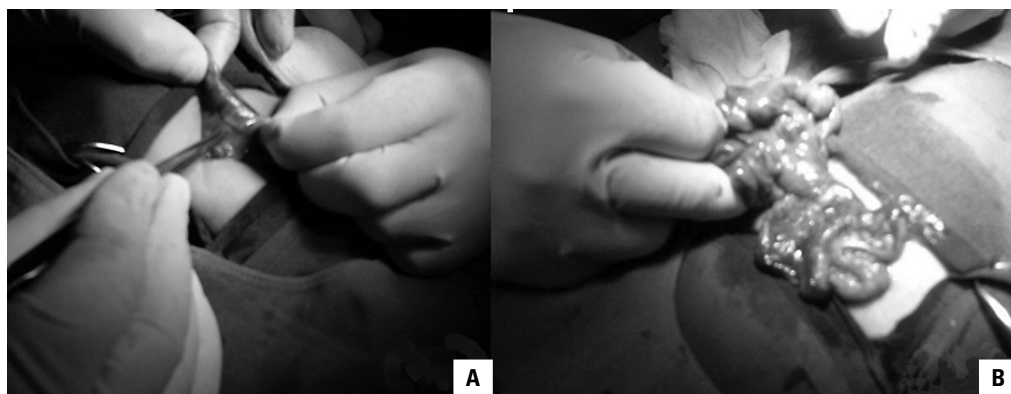
**Figure 1.** A sample plain abdominal X-ray film of a neonate with malrotations showing distension of the stomach together with a small amount of gas in distal parts of the intestine (A). Contrast-enhanced radiograph of the same case reveals the poor passage of the contrast to the intestinal regions distal to D<sub>2</sub> (B).



**Figure 2.** A barium enema of a malrotation case; note that the caecum and appendix are not located normally.



**Figure 3.** Rotation of the main part of the small intestine on its mesentery; this has led to gangrene of a large part of the jejunum and ileum (a); note the gangrene (B).



**Figure 4.** The peritoneal bands, which have a compressive effect on the duodenum, are becoming detached (A); rotation of the small intestine around the SMA axis (mid-gut volvulus) (B); volvulus did not lead to vascular derangements in this case.

**Table 3.** Surgical procedures and final intraoperative diagnoses

Final diagnosis	Number of cases	Surgical procedure	Number of cases
Pure malrotation	16 (53.3%)	Ladd's procedure	13 (43.3%)
		Ladd's procedure without appendectomy	3 (10%)
Malrotation with mid-gut volvulus	10 (33.3%)	Ladd's procedure and derotating volvulus	6 (20%)
		Ladd's procedure, bowel resection (due to bowel gangrene) and derotating volvulus	4 (13.3%)
Malrotation and duodenal atresia	2 (6.7%)	Ladd's procedure and duodenojejunostomy	2 (6.7%)
Malrotation with Meckel's diverticulum and duodenal atresia	1 (3.3%)	Ladd's procedure, diverticulectomy and duodenojejunostomy	1 (3.3%)
Malrotation and biliary atresia	1 (3.3%)		1 (3.3%)

## CONCLUSION

Intestinal malrotation is a common embryological anomaly affecting the position and peritoneal attachments of the small and large bowels during organogenesis in foetal life. During the 20<sup>th</sup> century understanding of the embryology and anatomy of malrotation became more complete, along with changes in the surgical approaches to the problems. We have outlined the symptomatology, diagnosis, and management of intestinal malrotations in this review. In addition, the presenting signs and symptoms, imaging findings and final intraoperative diagnoses of the subjects reported are of potential use and clinical interest for paediatricians, paediatric surgeons, embryologists and anatomists.

## REFERENCES

- Aiken JJ, Oldham KT (2005) Malrotation. In: Ashcraft KW, Holcomb GW, Murphy JP (eds) *Pediatric surgery*. Elsevier Saunders, New York, pp. 435–477.
- Anatol TI (1992) Intestinal malrotation in Trinidad. *J R Coll Surg Edin*, 37: 172–174.
- Beaudoin S, Mathiot-Gavarin A, Gouizi G, Bargy F (2005) Familial malrotation: report of three affected siblings. *Pediatr Surg Int*, 21: 856–857.
- Cassart M, Massez A, Lingier P, Absil AS, Donner C, Avni F (2006) Sonographic prenatal diagnosis of malpositioned stomach as a feature of uncomplicated intestinal malrotation. *Pediatr Radiol*, 36: 358–360.
- Chou CK, Chang JM, Tsai TC, Mak CW, How CC (1995) CT of the duodenojejunal junction. *Abdom Imaging*, 20: 425–430.
- Cieri MV, Arnold GL, Torfs CP (1999) Malrotation in conjunction with esophageal atresia/tracheo-esophageal fistula. *Teratology*, 60: 114–116.
- Devane SP, Coombes R, Smith VV, Bisset WM, and Booth IW, Lake BD, Milla PJ (1992) Persistent gastrointestinal symptoms after correction of malrotation. *Arch Dis Child*, 67: 218–221.
- Dilley AV, Pereira J, Shi ECP, Adams S, Kern IB, Currie B, Henry GM (2000) The radiologist says malrotation: does the surgeon operate? *Pediatr Surg Int*, 16: 45–49.
- Erez I, Reish O, Kovalivker M, Lazar L, Raz A, Katz S (2001) Congenital short-bowel and malrotation: clinical presentation and outcome of six affected offspring in three related families. *Eur J Pediatr Surg*, 11: 331–334.
- Howell CG, Voza F, Shaw S, Robinson M, Srouji MN, Krasna I, Ziegler MM (1982) Malrotation, malnutrition, and ischaemic bowel disease. *J Pediatr Surg*, 17: 469–473.
- Kovanlikaya A, Miller JH, Williams HT (1996) Malrotation discovered during routine radionuclide gastric emptying study. *Pediatr Radiol*, 26: 531–533.
- Lobo E, Daneman A, Fields JM, Keller MS, Alton DJ, Shandling B (1997) The diagnosis of malrotation during air enema procedure. *Pediatr Radiol*, 27: 606–608.
- Matsuki M, Narabayashi I, Inoue Y, Yamasaki K (1997) Two adult cases of primary small bowel volvulus: usefulness of computed tomographic diagnosis. *Radiat Med*, 15: 181–183.
- Parish A, Hatley R, Intestinal Malrotation (2006) In: *Pediatrics: Gastroenterology articles*. E-medicine: <http://www.emedicine.com/ped/GASTROENTEROLOGY.htm>.
- Potts SR, Thomas PS, Garstin WIH, McGoldrick J (1985) The duodenal triangle: a plain film sign of midgut malrotation and volvulus in the neonate. *Clin Radiol*, 36: 47–49.
- Smith VL, Long F, Nwomeh BC (2006) Monozygotic twins with discordant intestinal rotation. *Pediatr Radiol*, 26: 1–3.
- Svab J, Rathous I, Klofanda J, Vyborny J, Kotrlíkova E, Vitkova I, Povysil C (2005) Intestinal ischaemia — consequence of intestinal malrotation. *Rozhl Chir*, 84: 626–630.
- Touloukian RJ, Smith EI (1998) Disorders of rotation and fixation. In: *Pediatric surgery*. St. Louis, Missouri, pp. 1199–1214.
- Weinberger E, Winters WD, Liddell RM, Rosenbaum DM, Krauter D (1992) Sonographic diagnosis of intestinal malrotation in infants: importance of the relative positions of the superior mesenteric vein and artery. *AJR*, 159: 825–828.