

The ansa subclavia: a review of the literature

M. Loukas¹, X.L. Zhan¹, R.S. Tubbs², D. Mirchandani¹, M.M. Shoja³

¹Department of Anatomical Sciences, School of Medicine, St. George's University, Grenada, West Indies

²Section of Pediatric Neurosurgery, Children's Hospital, Birmingham, AL, USA

³Tuberculosis and Lung Disease Research Center, Tabriz University of Medical Sciences, Tabriz, Iran

[Received 2 April 2008, Accepted 17 June 2008]

The ansa subclavia, subclavian loop, Vieussens' ansa or Vieussens' loop is a nerve cord that connects the middle cervical and inferior cervical sympathetic ganglia, forming a loop around the subclavian artery. The structure of the ansa subclavia is evolutionarily conserved from rats, guinea pigs, the porcine species and dogs to humans. A common application in physiological studies is to electrically stimulate the ansa subclavia in animal models as a robust protocol to modulate stimulatory cardiac sympathetic input. Despite a large number of physiological studies utilizing the ansa subclavia, only very brief descriptions have been devoted to it in standard anatomy texts. An extensive search found only one report in the English language literature concerning the anatomy of the ansa subclavia. The aim of this report, therefore, was to provide a comprehensive review of the clinical anatomy of the ansa subclavia and to discuss its potential physiological functions. (Folia Morphol 2008; 67: 166–170)

Key words: ansa subclavia, subclavian loop, Vieussens' ansa, Vieussens' loop

ANATOMY OF THE ANSA SUBCLAVIA

The ansa subclavia was first described in 1864 by Vieussens (cited by Paturet) as a "nerve loop surrounding the subclavian artery, in the prescalene portion, situated outside the beginning of the vertebral artery and inside the start of the thyro-bicervico-scapular trunk and the internal mammary" [16].

Standard anatomy texts describe the ansa subclavia as a nerve cord that forms a loop inferiorly around the subclavian artery and connects the inferior cervical ganglion and middle cervical ganglia [18]. The inferior cervical ganglion (or cervicothoracic/stellate) ganglion is situated between the base of the transverse process of the last cervical vertebra and the neck of the first rib, on the medial side of the vertebral artery. The inferior cervical ganglion is usually in close proximity to the vertebral artery anteriorly, to the costocervical trunk of the subclavian artery inferiorly, and to the inferior thyroid artery

laterally. The middle cervical ganglion is usually found at the level of the sixth vertebral, anterior or just superior to the inferior thyroid artery. Two or more very variable cords originate from the middle cervical ganglion and connect to the middle and inferior ganglia: the posterior usually splits to enclose the vertebral artery; the anterior loops down anterior to and then below the first part of the subclavian artery, medial to the origin of its internal thoracic branch [2].

Paturet, in his monogram published in 1964, mentioned different types of ansa subclavia [16]. He described how "on the left, a single, flattened, ribbon-like loop is observed, placed like a lamella surrounding the artery. From this ansa a flattened filament, variable in length, descends to encircle the outer and anterior sides of the thoracic portion of the subclavian artery to merge with the lower cardiac nerve; this is Guillaume's small spiral band; on

Address for correspondence: Dr. M. Loukas MD, PhD, Ass. Prof., Department of Anatomical Sciences, St. George's University, School of Medicine, Grenada, West Indies, tel: 473 444 4175 x2556, fax: 473 444 2887, e-mail: edsg2000@yahoo.com, mloukas@sgu.edu

the right, it is only in exceptional cases that the ansa is single; it usually consists of two to five flattened, contiguous filaments, placed on the anterior side of the artery, at a width of 5 to 6 mm." However, Paturet's notion that there is only a single cord of the ansa subclavia on the left, whereas there are multiple cords on the right is not substantiated in a subsequent study reported in the literature in English. In 1984 Caliot et al. [2] reported that the ansa subclavia existed in 83% of 60 cadaveric specimens. In 32% (19 out of 60) of specimens a single cord existed; in 28% of specimens a double cord existed and in 13% and 10% of specimens triple and quadruple cords existed respectively. On the left side 57% of the subclavian ansae (17 out of 30) contained more than two nerve cords compared to 47% of the subclavian ansae on the right side (14 out of 30). The right side has more nerve cords in total than the left (54 vs. 47).

In addition to the anatomical heterogeneity of the number of cords in the ansa subclavia, there appears to be variation in the origin and termination of the loops. In 1964 Paturet classified three types of variation according to the origin and termination of the loop:

- a short loop on the nerve funiculus devoid of the middle cervical ganglion;
- a short loop with a middle cervical ganglion situated more or less low down;
- a long loop originating from the superior cervical sympathetic ganglion or from the immediately adjacent sympathetic chain.

This classification of the size of the loop is informative, but is only qualitative in nature, as it lacks any quantification [16].

In summary, the ansa subclavia is present in the majority of dissections (Fig. 1). It can exist as single or multiple cords and the right side has more nerve cords in total than the left. The significance of this difference is unclear. Variations in the origin and termination of the ansa subclavia have rarely been reported. However, a conclusive quantitative study is needed. These issues remain to be critically and systematically evaluated in future investigations.

ANASTOMOSES BETWEEN THE CERVICAL SYMPATHETIC, ANSA SUBCLAVIA AND RECURRENT LARYNGEAL AND VAGUS NERVES

In addition to the ansa subclavia, there are variable branches that originate from either the ansa subclavia or the middle cervical ganglion and form

anastomoses with the recurrent laryngeal nerve or phrenic nerve. Paturet [16] in 1964, offered the classic description of the anastomoses between the cervical sympathetics and the recurrent laryngeal nerve as being both indirect and direct. Direct anastomoses originate from either the middle cervical ganglion or the ansa subclavia and pass beneath the subclavian artery to join the recurrent laryngeal nerve. Caliot et al. [2] reported that sympathetic and recurrent laryngeal nerve anastomoses occurred in 63% of specimens (19 out of a total of 30) on the right side. Of these, the anastomoses were direct and formed an ansa around the subclavian artery in 23% (7 out of 30) of the specimens. More frequently (40%, 12 out of 30), the anastomoses occurred superior to the arch of subclavian artery and in close relationship to the common carotid artery. In 4 of these samples the connection originated from the sympathetic chain, while in the other 8 samples it originated from the inferior cervical ganglion. On the left side the anastomoses occurred in 60% of the specimens (18/30), and none of them formed loops around the subclavian artery because of the separate origins of the common carotid and subclavian arteries. Most of the anastomoses were located superior to the subclavian artery on the left side and originated from the inferior cervical ganglion (57%, 17/30). In 2 out of 30 cases the anastomoses originated from the ansa subclavia and were located inferior to the subclavian artery. In addition, Caliot et al. [2] also presented the finding that there is a low incidence (8%, 5/60) of direct anastomosis between the trunk of the vagus nerve and the ansa subclavia and the cervical sympathetic trunk at the level of the subclavian artery. These connections may be physiologically significant, because similar anastomoses have been reported in other species, including cats and guinea pigs [1, 15].

ANASTOMOSES BETWEEN THE CERVICAL SYMPATHETICS, ANSA SUBCLAVIA AND THE PHRENIC NERVE

The inferior part of the stellate ganglion is in close contact with the cervical pleura and generally connects with the phrenic nerve. Paturet describes this connection as "one constant anastomosis located between the stellate ganglion and Vieussens' subclavia annulus and the phrenic nerve, where it reaches the outer side of the start of the internal thoracic artery; this phrenic-stellate anastomosis, varying in size, often double or triple and sometimes plexiform,

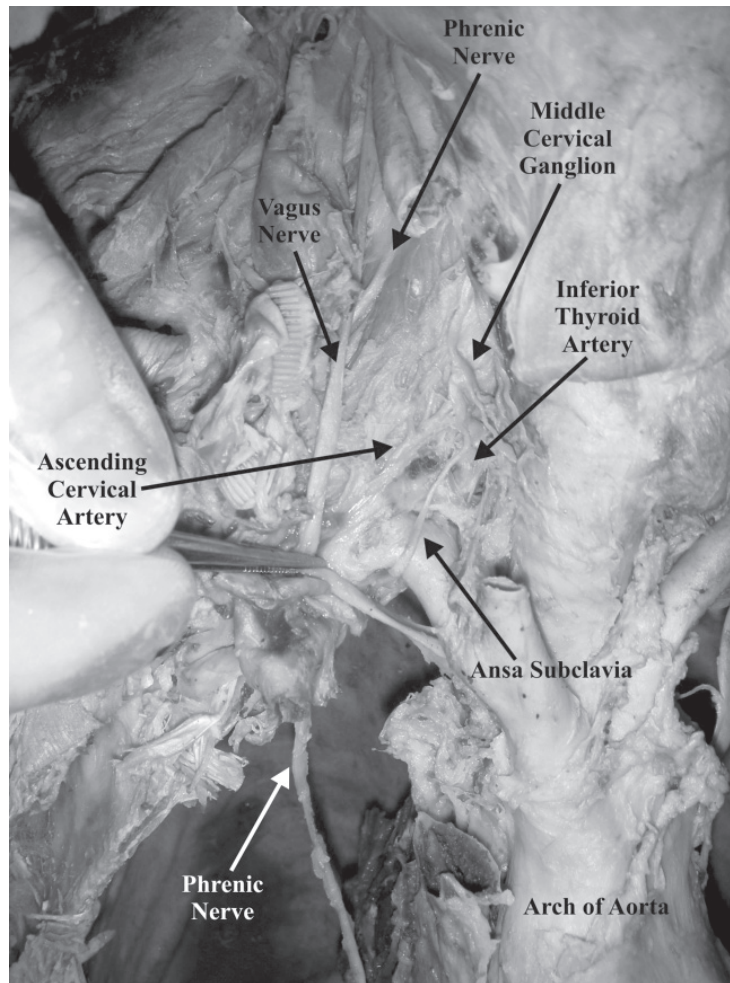


Figure 1. The ansa subclavia is depicted ascending anterior to the subclavian artery to connect to the middle cervical ganglion. Other structures such as the phrenic nerve, vagus nerve, inferior thyroid artery and ascending cervical artery are also depicted for orientation.

is situated between the subclavian artery and the anterior side of the pleural dome" [15]. This classic description of multiple anastomoses between the phrenic nerve and stellate ganglion is contradicted by Caliot's study, published in 1984, in which 47% of specimens displayed the phrenic-stellate anastomosis and the majority of them always had only a single nerve cord [2]. In Caliot's report only 30% (18/60) of connections fit the classic description, in which the anastomosis courses underneath the subclavian artery and forms a loop around it. In the other 28% (17/60) samples it traveled superior to the subclavian artery.

HYPOTHESES REGARDING THE DEVELOPMENT OF THE ANSA SUBCLAVIA

There is virtually no information regarding how the ansa subclavia is formed during embryonic de-

velopment. In 1994 Kanagasuntheram and Dharshini [10] put forward an interesting hypothesis. They suggested that sympathetic ganglia are associated mainly with intersegmental vessels such as the intercostal and lumbar arteries and that the differences seen in the neck region are due to the disappearance of most of the cervical intersegmental arteries and the subsequent modifications that follow during development. This results in the fusion of the upper four cervical ganglia to form the superior cervical sympathetic ganglion in relation to the developing external carotid artery, which seems to provide the necessary inductive stimulus. Furthermore, the anterior-inferior migration of the heart, its corresponding arch arteries and the dorsal aorta bring about the formation of the ansa subclavia around the subclavian artery and the positioning of the stellate ganglion behind the vertebral artery [10]. This hypothesis remains to be tested experimentally.

PHYSIOLOGICAL INVESTIGATIONS AND IMPLICATIONS FOR FUTURE RESEARCH

The physiological functions of the ansa subclavia are derived largely from animal models. Unless specified in the review, data are mostly summarized from studies on experimental animals. The ansa subclavia has been shown to distribute sympathetic fibers to the aortic bodies and to the heart. It maintains or increases chemoreceptor discharge during hypertension elicited by sympathetic activation [15]. Electric stimulation of the ansa subclavia produces an overflow of norepinephrine and cAMP levels into the coronary sinus blood. It activates the chronotropic and inotropic responses of the heart [7, 9, 13, 14, 17]. This property has been extensively used in experimental protocols in which sympathetic stimulation of the heart is desired [6, 8]. Interestingly, different effects on cardiac responses have been reported for the left and right ansa subclavia. For instance, the increase in heart rate was considerably greater during stimulation of the right versus the left ansa subclavia. Conversely, left ansa stimulation had a slightly greater effect on right ventricular contractile force than did right-sided stimulation [14]. Stimulation of the right ansa subclavia also leads to greater inhibition of the vagal effects (parasympathetic activation) on the atrioventricular interval and cardiac cycle length [19]. The authors provided preliminary data that such differential effects may be correlated with the distribution of neuropeptide Y-containing sympathetic fibers at the sinus node that originated in the right-sided ganglia, whereas most of those at the atrioventricular node originated in the left-sided ganglia. The greater number of nerve cords in the right ansa subclavia may partially contribute to the difference in the strength of physiological responses.

There is some evidence that the ansa subclavia functionally modulates the muscles of respiration by controlling the triangularis sterni (transverses thoracis). In dogs expiration is actively facilitated by activation of the triangularis sterni. Contraction of the triangularis sterni in these animals caused a marked caudal displacement of the ribs and a decrease in lung volume. Stimulation of the ansa subclavia in dogs can produce ipsilateral excitation and contralateral inhibition of the left and right triangularis sterni respectively, and such stimulation resulted in a significant decrease in inspiration time [4]. Spontaneous quiet expiration in humans is a passive process. However, the human

triangularis sterni is a primary muscle of expiration during active expiration, and its neural activation is largely coupled with that of the abdominal muscles [5].

The types of axon and the chemical nature of the neurotransmitters carried in the ansa subclavia remain to be determined. Electrical stimulation of the ventral roots while recording evoked potentials from the anterior ansa subclavia and posterior ansa and demonstrated that A-, B-, and C-type fibers exist in the ansa subclavia [12]. On the basis of pharmacological studies, axons with nicotinic receptors have been shown to mediate transmission of action potentials in the ansa subclavia [3]. Since the ansa subclavia carries sympathetic input to the heart, it is reasonable to speculate that neuropeptide Y and norepinephrine are localized in the sympathetic nerve terminals. In addition, GABA has been shown to modulate the outcome of ansa subclavian stimulation in a dosage-dependent manner: facilitation in small doses and depression in large doses [11].

In summary, the ansa subclavia forms the connection between middle cervical and inferior cervical ganglia. Two anastomoses connect the inferior cervical ganglion or ansa subclavia to the recurrent laryngeal or phrenic nerves, respectively. In addition, there is an evolutionarily conserved direct connection between the ansa subclavia and the vagus nerves. Stimulation of the ansa subclavia results in chronotropic and inotropic responses of the heart to increased heart rate, contractility and blood pressure.

Although only a limited set of data are available in the literature, they have nevertheless indicated a great degree of variation in terms of the number of nerves, origins, termination, course and spatial relationship to each other. Thus both the anatomical patterns and the extent of variations in the ansa subclavia and anastomoses between the cervical sympathetic-recurrent laryngeal or between cervical sympathetic-phrenic nerves present an important opportunity for future anatomical investigation. In addition, several important questions remain unanswered. For instance, whether there is any difference in the distribution of the ansa subclavia synaptic terminals on the heart, whether there is a correlation between the distribution and differential effects of stimulating one side rather than the other, what the nature is of the axons contained in the ansa subclavia, how many axons are usually found within the ansa and whether there are pathological processes that involve it. Future

investigations will provide more insight regarding the clinical anatomy and physiological functions of the ansa subclavia.

REFERENCES

1. Baluk P, Gabella G (1989) Innervation of the guinea pig trachea: a quantitative morphological study of intrinsic neurons and extrinsic nerves. *J Comp Neurol*, 285: 117–132.
2. Caliot P, Bousquet V, Cabanie P, Midy D (1984) The nerve loops crossing below the subclavian artery and their anatomical variations. *Anat Clin*, 6: 209–213.
3. Chinn C, Hilton JG (1976) Selective activation of nicotinic and muscarinic transmission in cardiac sympathetic ganglion of the dog. *Eur J Pharmacol*, 40: 77–82.
4. Coon RL, Hopp FA, Zuperku EJ (1995) Reflex effects of stimulation of sympathetic afferents on the triangularis sterni. *Respir Physiol*, 102: 187–194.
5. De Troyer A, Ninane V, Gilmartin JJ, Lemerre C, Estenne M (1987) Triangularis sterni muscle use in supine humans. *J Appl Physiol*, 62: 919–925.
6. Forfar JC, Riemersma RA, Russell DC, Oliver MF (1984) Relationship of neurosympathetic responsiveness to early ventricular arrhythmias in ischaemic myocardium. *Cardiovasc Res*, 18: 427–437.
7. Furnival CM, Linden RJ, Snow HM (1973) Chronotropic and inotropic effects on the dog heart of stimulating the efferent cardiac sympathetic nerves. *J Physiol*, 230: 137–153.
8. Hageman GR, Urthaler F, James TN (1984) Parasympathetic and sympathetic efferent traffic during a cardiogenic hypertensive chemoreflex. *Cardiovasc Res*, 18: 583–590.
9. Harry JD, Knapp MF, Linden RJ (1974) Proceedings: antagonism by ICI 66082 of the effects of electrical stimulation on the right ansa subclavia of the dog. *Br J Pharmacol*, 50: 457P–458P.
10. Kanagasuntheram R, Dharshini P (1994) The cervical sympathetic trunk — a new hypothesis. *Ann Acad Med Singapore*, 23: 923–928.
11. Kimura T, Imamura H, Hashimoto K (1977) Facilitatory and inhibitory effects of gamma-aminobutyric acid on ganglionic transmission in the sympathetic cardiac nerves of the dog. *J Pharmacol Exp Ther*, 202: 397–403.
12. Kostreva DR, Zuperku EJ, Cusick JF, Kampine JP (1977) Ventral root mapping of cardiac nerves in the canine using evoked potentials. *Am J Physiol*, 232: H590–H595.
13. Lavallee M, Laurencin C, de Champlain J, Nadeau RA (1981) Liberation of cyclic AMP and catecholamine from the heart during left stellate stimulation in the anesthetized dog. *Can J Physiol Pharmacol*, 59: 533–540.
14. Levy MN, Blattberg B (1977) Correlation of the mechanical responses of the heart with the norepinephrine overflow during cardiac sympathetic neural stimulation in the dog. *Cardiovasc Res*, 11: 481–488.
15. Mills E (1968) Activity of aortic chemoreceptors during electrical stimulation of the stellate ganglion in the cat. *J Physiol*, 199: 103–114.
16. Paturet (1964) *Traite d'anatomie humaine*. Vol. 1. Masson et Cie edit. Paris.
17. Pindok MT, Sukowski E, Glaviano VV (1981) Cardiac cyclic nucleotides and norepinephrine during neural sympathetic stimulation. *Am J Physiol*, 240: H630–H635.
18. Standring S (2004) *Gray's anatomy: the anatomical basis of clinical practice*. 39th ed. Churchill Livingstone, London, pp. 549, 560.
19. Warner MR, Levy MN (1990) Sinus and atrioventricular nodal distribution of sympathetic fibers that contain neuropeptide Y. *Circ Res*, 67: 713–721.