

Tomasz Grądalski^{1, 2}, Izabela Bętkowska^{2, 3}¹Pain and Palliative Clinic, Chair of Internal Medicine and Gerontology, Jagiellonian University *Collegium Medicum*, Krakow, Poland²St. Lazarus Hospice, Krakow, Poland³Division of Family Medicine, Chair of Internal Medicine and Gerontology, Jagiellonian University *Collegium Medicum*, Krakow, Poland

Effectiveness of octreotide in advanced cancer patients with malignant bowel obstruction and intractable diarrhea

Abstract

Malignant bowel obstruction and intractable diarrhea in advanced cancer are common devastating syndromes. Apart from disease specific, causative treatment in patients with longer prognosis, there is a possibility of conservative, non-operative symptom management in terminal phase. A successful control of intractable vomiting and diarrhea using octreotide in two advanced cancer patients was presented, with guidance through steps of the management. Pathophysiologic vicious circle of the bowel obstruction and diarrhoea was described and the management algorithm was proposed. Due to the gut hyposecreting action, octreotide occurs to be a potent and essential drug in refractory vomiting or diarrhea.

Key words: malignant bowel obstruction, intractable diarrhea, octreotide

Adv. Pall. Med. 2009; 8, 4: 161–164

Introduction

In patients with end-stage disease malignant bowel obstruction (MBO) is a quite common and devastating complication, which worsens the quality of life and markedly shortens prognosis. Its frequency ranges from 5% to 42% in advanced ovarian cancer and from 4% to 24% in advanced colorectal cancer. It may be partial or complete and at single or multiple sites; the small bowel is more commonly involved than the large bowel (61% vs. 33% in over 20% of the patients both are involved). Its pathological mechanisms may be benign (more common in colorectal cancer, less in gynaecological cancers), such as adhesions, post-irradiation bowel

damage, inflammatory bowel disease, hernia or functional obstruction. Malignant causes are: extrinsic, intrinsic or intraluminal gut occlusion and neoplastic or paraneoplastic intestinal motility disorders due to infiltration or neuropathy of mesentery nerves or celiac plexus [1].

Typical clinical symptoms consist of nausea/vomiting and continuous abdominal pain (90% of patients, less severe in large bowel obstruction) which induce colic pain due to gut ineffective motility (approx. 75% of patients). The most pronounced signs are abdominal distension (periodically spontaneously resolving in partial MBO) and high-pitched peristalsis or borborygmi [2]. Possible radiological investigations that may be performed in patients with

Address for correspondence: Tomasz Grądalski
Pain and Palliative Clinic, Chair of Internal Medicine and Gerontology
Jagiellonian University *Collegium Medicum*, Krakow, Poland
e-mail: tomgr@mp.pl



Advances in Palliative Medicine 2009, 8, 161–164

Copyright © 2009 Via Medica, ISSN 1898–3863

symptoms and signs of MBO like plain/contrast radiography or abdominal CT should be considered only in patients who will benefit from surgery (good performance and nutritional status, no previous abdominal surgery or radiotherapy and acute single mechanical obstruction). Surgical treatment — which ought to be considered in every case — due to high risk of mortality (9–40%) and complications (9–90%) is not superior to conservative treatment and may consist of laparotomy resection or gut bypass, endoscopy laser resection and endoscopy stenting. In inoperable, vomiting and resistant to pharmacological therapy patients venting procedures [e.g. percutaneous endoscopically placed gastrostomy (PEG) tube] may be considered. To the vast majority of terminal cancer patients drug therapy is the only possible option. It focuses on relief of nausea, vomiting and pain, sometimes may even temporarily reverse the MBO signs.

Diarrhoea in advanced cancer relates to approx. 10% of patients can be caused by drugs (laxatives, antibiotics, antacids or chemotherapy), radiotherapy, oncological surgery (e.g. restorative proctocolectomy) gastrointestinal tumours, infection, inflammation, malabsorption or incorrect diet. Particularly in older patients “diarrhea” can also be a sign of the overflow fecal incontinence caused by fecal impaction. Apart from disease specific (causal) management, treatment usually includes opioids (morphine or loperamide), pancreatic enzyme replacement or probiotics. In intractable or refractory diarrhoea (ID) gut hypersecretion can play a significant role [3]. This excessive secretion can be caused by the damage to the intestinal mucosa including loss of intestinal epithelium, superficial necrosis, and inflammation of the bowel wall (e.g. due to chemotherapy) the presence of fistulas or neuroendocrine gastrointestinal tumors (carcinoids or endocrine pancreatic tumors) or paraneoplastic stimulation of the gut enzymes [4–6].

The aim of this study is to present two cases of successful management of MBO and ID in terminal cancer patients using somatostatin analogue.

Case 1

A 75 year old man, with three-year history of colon cancer (adenocarcinoma tubulare) was admitted to the hospice. He complained of severe unrestrained vomiting (up to 2 litres a day), weakness, anorexia, abdominal pain and sleep disturbances. Laparotomy revealed relapse of the disease with bowel obstruction (regional 25 cm infiltration of

sigmoid spreading into small intestine and retroperitoneal space). Performed surgical treatment (partial small bowel resection and colostomy) had brought no relief. Afterwards gastro-entero anastomosis also had not alleviated the symptoms. On the contrary his nausea and vomiting had being more and more severe in time. Due to his ileus he became bed bound and depressive and his social contact was scarce. During hospice care he did not respond to more than 7 days trial of dexamethasone (8 mg a day *i.v.*) with metoclopramide. Haloperidol and levomepromazine benefit was of minor importance too, with aggravation of depression and consciousness disturbances. Hyoscine butyrbromide (up to 180 mg a day) was completely inefficient with huge discomfort of dry mouth and mental deterioration. A trial of octreotide was suggested and his vomiting diminished immediately and was controlled on 0,3 mg a day. His sc daily morphine demand decreased from 60 to 30 mg. Attempt of octreotide withdrawal caused symptoms recurrence. He was stable for seven months, walking with assistance, with good appetite, enteral diet and with mood improvement, until peaceful death preceded by slow general deterioration.

Case 2

A 82 year old woman with advanced cervical cancer after palliative colostomy was suffering of a huge diarrhea because of malignant bowel obstruction symptoms. It made administering of her colostomy sacks almost impossible. In subsequence there was a huge skin irritation, pruritus and the risk of electrolytes loss. Odour and shame took effect in avoiding of social contact and exacerbated depression. On admission: bed bound, with extensive scorching and burning red inflammatory skin irritation around the colostomy. She was not hypercalcemic. Her diarrhea was not controlled on high doses of pancreatic enzymes, loperamide, hyoscine butyrbromide and morphine, with additional notable adverse symptoms as dry mouth. Similarly a trial of steroids did not cause improvement. Octreotide at a starting dose of 0.1 mg a day (in divided doses) was administered, and titrated to 0.3 mg a day, with eventual diarrhea assessment. It enabled colostomy sack administration and skin irritations healing. In consequence of this treatment, the patient’s psychological condition and social contacts improved and occupational therapy became possible. A trial of octreotide withdrawal caused diarrhea recurrence. She remained stable for two months and died in comfort.

Pathophysiology of MBO and ID

The most distressing symptoms of MBO are vomiting, colic or continuous pain; in ID: colic pain and devastating frequent bowel movements. The increase of bowel secretion and contraction seems to play the crucial role both in the vicious circle of MBO and ID (Fig. 1).

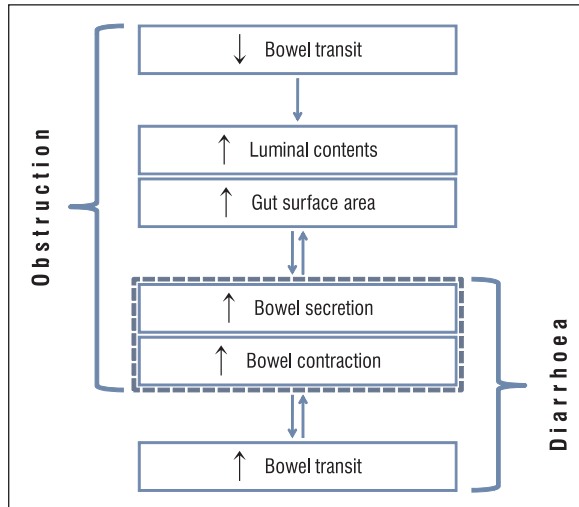


Figure 1. The importance of bowel secretion and contraction in MBO/ID pathomechanisms

MBO drug therapy comprising analgetics, antiemetics, and antisecretory drugs without using a nasogastric tube was first described by Mary Baines et al. in 1985 [7]. The drugs of choice vary to a certain extent between countries and different centers, based on clinical experience, drug availability, cost and fashion. Medication should be tailored to each patient with regard to both the drugs to be administered and the route of administration. In resistant MBO to anticholinergics a trial of octreotide can be a valuable option (Fig. 2).

ID therapy

Diarrhea is a symptom. When possible, the underlying disorder should be treated, but symptomatic treatment is often necessary. Traditional ID symptomatic management has focused on the use of nonspecific therapy such as atropine, loperamide, codeine, and the opium mixture. Alternative nonspecific approaches include anticholinergics, antispasmodics, and adsorbent agents preparations. Opioids exert their antidiarrheal activity on gastrointestinal cells by their agonistic effects on opioid receptors, thus decreasing peristaltic movements and increasing absorption. However, although opioids are currently considered as gold standard for ID in cancer patients, their effectiveness in control-

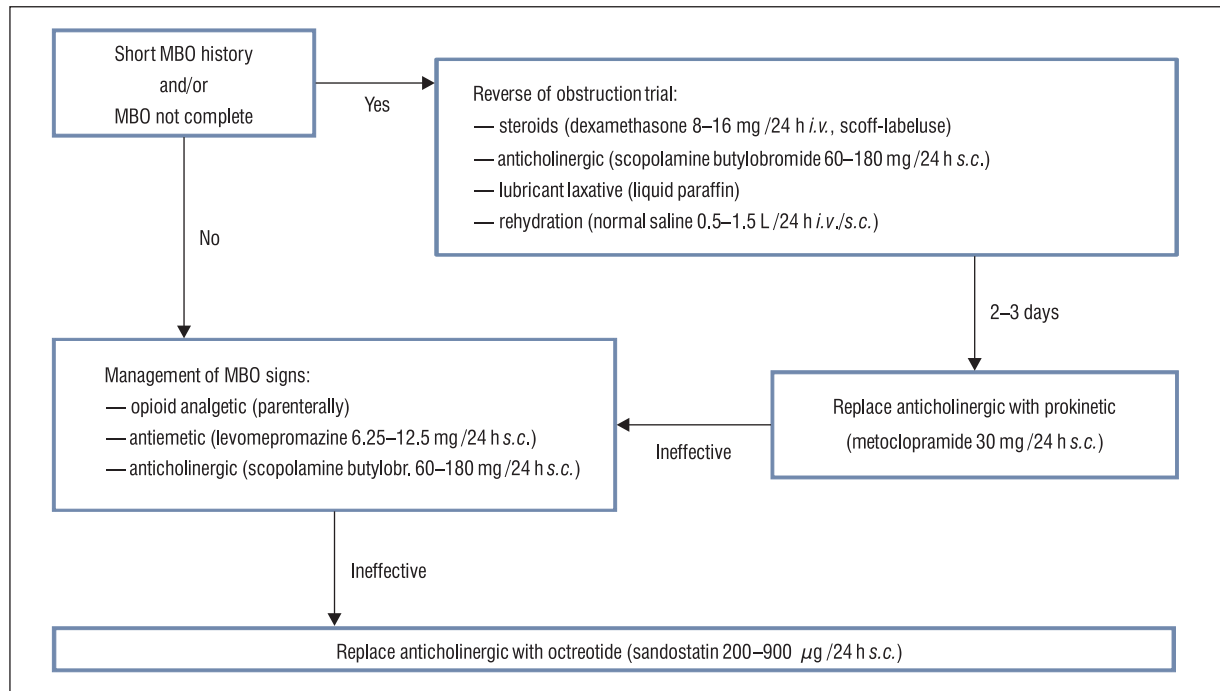


Figure 2. MBO conservative management diagram

ling it can be insufficient. Additionally, chronic or high-dose opioid treatment may cause serious side effects, e.g. loperamide-induced paralytic ileus, which makes close monitoring of patients receiving this antidiarrheal treatment mandatory. The somatostatin can exert its antidiarrheal actions by multiple mechanisms.

Octreotide is a synthetic analogue of somatostatin with a longer duration of action. It inhibits the release of growth hormone, TSH, prolactin and ACTH, the secretion of insulin, glucagon, gastrin and other peptides of the gastro-enteropancreatic system, reducing splanchnic blood flow, portal blood flow, gastro-intestinal motility, gastric, pancreatic and small bowel secretion, and increasing water/electrolyte absorption. In patients with cancer and inoperable bowel obstruction, octreotide rapidly improves symptoms in $\geq 75\%$ of patients. In hormone-secreting tumours, octreotide improves symptoms by inhibiting hormone secretion, e.g.: 5HT in carcinoid (improving flushing and diarrhoea) VIP in VIPomas (improving diarrhoea) glucagon in glucagonomas (improving rash and diarrhoea). In refractory secretory diarrhoea it is known to enhance water and sodium absorption from the small intestine, it inhibits chloride secretion in the colon and prolongs small intestine transit [8]. Octreotide has a direct anticancer effect on solid tumours of the gastro-intestinal tract thus can prolong survival. It is poorly absorbed after oral administration. After subcutaneous injection its duration of action can extend up to 12 hours so it should be given not less frequently than twice a day. The dose should be titrated according to the effect. There are 2-drug compatibility data for octreotide in 0.9% saline with diamorphine, haloperidol, hyoscine butylbromide, midazolam, morphine sulphate and ondansetron. Incompatibility may occur with dexamethasone or levomepromazine [9]. A long-acting formulation (LAR) has been designed to provide long-term controlled release after a singular intramuscular injection. Most side effects encountered with octreotide are either local (pain, redness or swelling) or gastrointestinal (anorexia, nausea, vomiting, abdominal cramp-like pain). Adverse endocrinological ef-

fects are rare. Due to the high acquisition costs (0.1 mg ampoule = approx. 30 PLN comparable with for example hyoscine butylbromide: 20 mg ampoule = approx. 1 PLN), the cost effectiveness of prescribing octreotide must be considered before commencing therapy [5].

In the case 1 of MBO, both surgical and conservative management failed — octreotide due to restoration of the gut passage and symptom withdrawal — gave the patient seven months of fairly normal life. In the case 2, ID resistant to causal treatment, irresponsive to opioid, pancreatic enzyme and probiotic therapy suggested excessive fluid secretion. The enrollment of octreotide gave the patient not only restoration of the normal bowel movement and possibility to skin lesion healing, but also improved her mood and diminished social isolation. Octreotide occurred the valuable option in the management of drug resistant MBO and ID.

References

1. Ripamonti C., Twycross R., Baines M. et al. Clinical-practice recommendations for the management of bowel obstruction in patients with end-stage cancer. *Support Care Cancer* 2001; 9: 223–233.
2. Ripamonti C. Bowel obstruction. In: Bruera E., Higginson I.J., Ripamonti C., von Gunter C. (eds.). *Textbook of Palliative Medicine*. Edward Arnold Publishers Ltd, London 2006: 588–600.
3. Fallon M., O'Neill B. ABC of palliative care: Constipation and diarrhea. *BMJ* 1997; 315: 1293–1296.
4. Topkan E., Karaoglu A. Octreotide in the Management of Chemoradiotherapy-Induced Diarrhea Refractory to Loperamide in Patients with Rectal Carcinoma. *Oncology* 2006; 71: 354–360.
5. Gilbar P.J. The role of octreotide in symptom management in oncology and palliative care. *J. Oncol. Pharm. Practice* 2000; 6: 81–91.
6. Freeman H.J., Berean K.W. Resolution of paraneoplastic Collagenous enterocolitis after resection of colon cancer. *Can. J. Gastroenterol.* 2006; 20: 357–360.
7. Baines M., Olivier D.J., Carter L.R. Medical management of intestinal obstruction in patients with advanced malignant disease: a clinical and pathological study. *Lancet* 1985; 2: 990–993.
8. Farthing MJG The patient with refractory diarrhoea. *Best Practice and Research Clinical Gastroenterology* 2007; 21: 485–501.
9. Available on: <http://www.palliativedrugs.com/octreotide.html> (28.07.09).