

Application of endovenous mechanochemical ablation (MOCA) with Flebogrif™ to treat varicose veins of the lower extremities: a single center experience over 3 months of observation

Tomasz Zubilewicz, Piotr Terlecki, Karol Terlecki, Stanislaw Przywara, Janusz Rybak, Marek Ilzecki

Department of Vascular Surgery and Angiology, Medical University of Lublin, Poland

Abstract

Introduction. Chronic venous insufficiency is one of the most common medical conditions among highly developed societies. The majority of patients (70%) suffer from saphenous veins incompetency. The study presents results of a 3-month follow-up of application of venous mechanochemical ablation system with the Flebogrif™ catheter.

Material and methods. The study was conducted on 200 patients, including 170 women and 30 men treated with ablation with Flebogrif™ to treat varicose veins. All patients were qualified based on the ultrasound in a standing position confirming incompetence of the great saphenous vein or small saphenous vein. The vein was punctured under ultrasound guidance in the distal part of the incompetent segment. The area of vascular access was anesthetized with 0.5 mL of 1% lignocaine. The compression therapy in the form of the first grade medical elastic stocking was used after the surgery.

Results. The initial technical success of the surgery was achieved in all the patients. During the 3-month follow-up, recanalization occurred in 8 cases, in 5 patients great saphenous vein and in 3 small saphenous vein recanalised. Based on the recommendations of the European Consensus Meeting on Foam Sclerotherapy, 7 cases were defined as complete recanalization and 1 as partial. The analysis of numerical data obtained with Venous Clinical Severity Score and Clinics Ethiology Anatomy Pathophysiology Classification showed a statistically significant decrease in the severity of clinical symptoms compared to ones before the surgery and between particular days of the observation during the 3-month follow-up.

Conclusions. The procedure is highly effective reaching 96% at 3 months of follow-up, provides good cosmetic effect and the low rate of complications. Minimal invasiveness of mechanochemical ablation with Flebogrif™ may improve the quality of life during the postoperative period. A long-term observation is recommended to achieve a full-value assessment of this novel method.

Key words: mechanochemical ablation, varicose veins, Flebogrif™

Acta Angiol 2016; 22, 4: 137–142

Introduction

Chronic venous insufficiency is one of the most common medical conditions in the world. The World Health Organization defines varicose veins of the lower

limbs as dilated superficial veins presenting as baggy or cylindrical in shape and possessing damaged valves [1]. In 70% of cases saphenous veins are affected [2]. It is reported that 40–60% of women and 25–30% of men will present symptoms of venous insufficiency during

Address for correspondence: Stanislaw Przywara, Department of Vascular Surgery and Angiology, Medical University of Lublin, Staszica 11, 20–081 Lublin, Poland

life time [3]. The disease can initially be asymptomatic. After this asymptomatic period, varicose veins may result in thrombotic complications and venous ulcers. Traditional methods of surgical treatment of varicose veins are being increasingly replaced by less invasive thermal ablation. The effectiveness of this approach has been confirmed in numerous clinical studies. Recent years have brought new, promising non-thermal ablation techniques to the forefront, including mechanochemical ablation (MOCA). Two-years follow-up of the ClariVein system application proved, that the method was significantly less traumatic compared to thermal methods with its efficacy reaching 96% [3].

This study presents the results of a 3-month follow-up of application of venous mechanochemical ablation system with the Flebogrif™ catheter.

Material and methods

The study was conducted on 200 patients, including 170 women and 30 men diagnosed by means of Doppler ultrasound with great saphenous vein/small saphenous vein insufficiency. All patients qualified for mechanochemical ablation of the saphenous vein using the Flebogrif™ system. The study has been approved by Bioethics Committee of the Medical University of Lublin (0254/226/2015). Patient demographics are presented in Table 1.

Measurement of saphenous vein diameter was performed in a standing position on three levels: 1–2 cm from the saphenofemoral junction, in the mid-thigh, and at the height of the knee fissure. The diameter of the sa-

phenous vein in women in the region of the saphenofemoral junction averaged 8.89 mm (range 4.1–20.4 mm), in the mid-thigh 6.96 mm (3.5–17.1 mm), and at the level of knee fissure 5.88 mm (9.3–11.9 mm). In men, the diameter below saphenofemoral junction averaged 8.82 mm (5–22 mm), in the mid-thigh 7.45 mm (3.8–11.2 mm), and at the level of the knee fissure 6.8 mm (3.2–10.4 mm). The results of measurements of GSV (great saphenous vein) diameter are presented in Table 2.

All procedures were performed in the operating room. Under ultrasound guidance, the site of GSV puncture was evaluated and then chosen, usually below the knee joint and at the site of the lowest reflux level to provide maximum technical success. The puncture was performed using the Seldinger needle provided with the kit, through which the guiding wire was inserted so that its end was located in the region of saphenofemoral junction. Before insertion of the 6F introducer sheath, the skin was locally anesthetized with 1% lignocaine at the puncture site. Table 3 presents the region where the Flebogrif™ catheter was inserted.

Using the guiding wire, the Flebogrif™ system was inserted placing its working part 2 cm below the saphenofemoral junction. The system was freed by sliding the external sheath in relation to the internal mandrill. The five arms of the working part with sharp hooks on the ends were released and directed toward the wall of the vessel and scarification of the vein was performed from the positioning site to the puncture site by withdrawing the system with continuous movement. The speed at which the system was slid amounted to

Table 1. Patients demographics

Sex	Number of patients		Age		Total
Females	170	87	56	18	200
Males	30	75	46	23	

Table 2. The diameter of the punctured vein, numerical distribution depending on the side (right, left), sex, and the rate of punctured GSV/SSV

Diameter of the vein (from-to/average)			Operated limb				Proportion	
Below SFJ	Mid-thigh	Knee level	Females		Males		GSV	SSV
			Right	Left	Right	Left		
4.2–22.1/8.1	3.8–17.1/6.2	3.8–11.9/6.6	68	102	13	17	172 (86%)	28 (14%)

Table 3. The region where Flebogrif™ catheter was inserted

Sex	Puncture site		
	Above the knee	Knee level	Below the knee
Females	37	36	97
Males	7	6	18

5 cm/s and the volume of the injected foam amounted to 1 mL/5 cm of vein. For veins with a diameter of 15 mm 2% polidocanol was used, and for veins of larger diameter 3% polidocanol.

The volume of the sclerosant used for saphenous vein ablation ranged from 3 to 10 mL with an average of 6.5 mL.

After the operation, compression therapy was used with second grade compression stockings (Sigvaris®) for a minimum of 10 days. Enoxaparin was chosen for patients with increased risk of thromboembolism at a dose of 1 × 40 mg s.c. for 10 days. Follow-up visits were scheduled at one, three, six, and 12 months after procedure.

The patients qualified for treatment with MOCA were evaluated using CEAP, VCSS (Clinics Etiology, Anatomy, Pathophysiology Classification and Venous Clinical Severity Score), and the Analog Pain Scale.

Results

Figure 1 presents numerical distribution of patients participating in a follow-up, during which the effectiveness of ablation was evaluated in the form of an index of treated vein occlusion, pain severity estimated with ten-point visual analog scale (VAS), VCSS, and CEAP. Table 4 presents staging of clinical symptoms in evaluated

patients at baseline. Analysis of VAS data demonstrated a significant decrease in pain severity at each follow-up time point compared to the initial pain level (Fig. 2).

Analysis of numerical data obtained via VCSS and CEAP showed a statistically significant decrease in the severity of clinical symptoms compared to baseline levels and at each day of observation during the 3-month follow-up. Due to the non-parametric data distribution, analyses were performed using the Friedman ANOVA and Wilcoxon test. The level of significance was set at $p < 0.05$. Figures 3, 4, and 5 present statistical analysis of the results obtained during the 3-month follow-up period. The effectiveness of MOCA with the Flebogrif™ catheter was estimated based on the ratio of the number of closed veins to the number of recanalization.

During the 3-month follow-up, eight cases of recanalization occurred, 5 concerning the great saphenous vein and 3 concerning the small saphenous vein. Based on the recommendations of the European Consensus Meeting on Foam Sclerotherapy, 7 cases were defined

Table 4. Staging of clinical symptoms in evaluated patients at baseline

Scale	Min.	Average	Max.
VCSS	7	14	21
CEAP	2	4	6

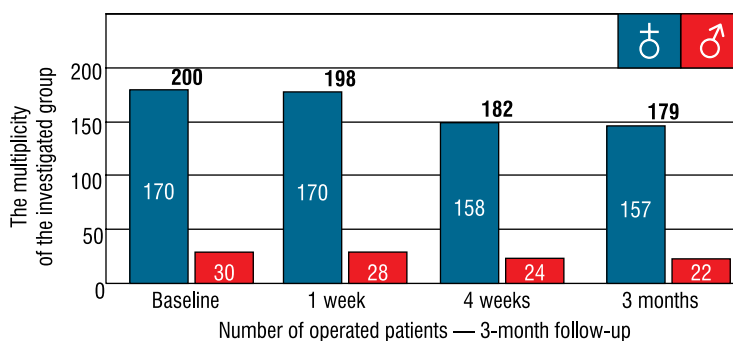


Figure 1. Numerical distribution of the patients participating in subsequent follow-up visits

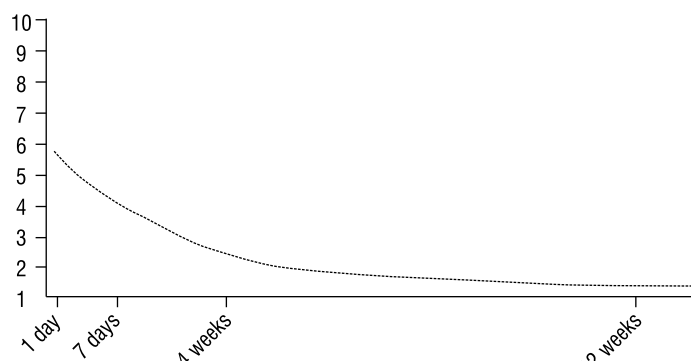


Figure 2. Graphical analysis of pain severity estimated with VAS throughout the study

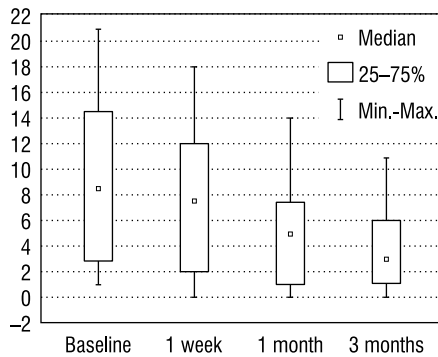


Figure 3. Evaluation of the clinical symptom severity estimated with the VCSS

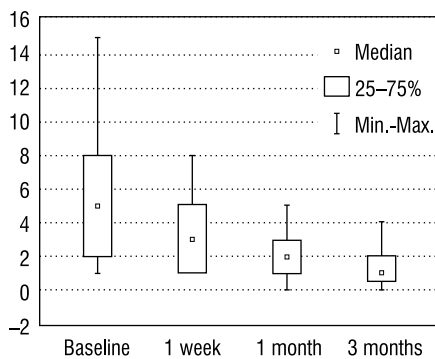


Figure 4. Evaluation of the clinical symptom severity estimated with CEAP classification

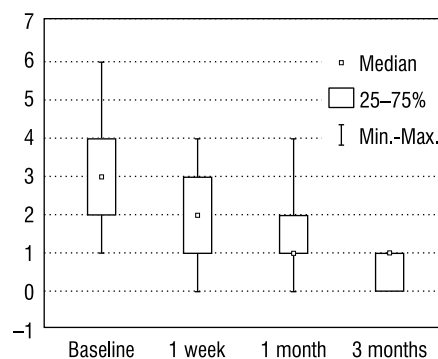


Figure 5. Estimation of pain severity with the VAS

as complete recanalization and I as partial. All cases where ablation with FlebogrifTM was not successful concerned women.

Complementary obliteration was performed in 92 patients (76 women, 16 men) during the follow-up visit 4 weeks after treatment. The volume of sclerosant foam ranged from 3 to 7 mL and the polidocanol concentration from 1–2%.

During follow-up, a young man who before the treatment presented with a low risk of thromboembolism was diagnosed with deep vein thrombosis in the operated limb. Further tests after thrombosis onset

revealed thrombophilia due to mutation of Factor V Leiden. Superficial vein thrombosis of the lower limb was diagnosed in 29 cases, and 20 patients presented hyperpigmentation after ablation. There were no complications related to the obliterating agent applied.

Discussion

Percutaneous intravascular ablation methods for insufficient superficial veins were introduced in the late 1990s and became a good, minimally invasive alternative to surgical intervention. Radiofrequency ablation (RF) presented in 1998 was the first of the aforementioned techniques to be introduced [3]. A year later, a new method based on Endovenous Laser Treatment (EVLT) was announced. At present, this method is the most commonly used in the treatment of varicose veins of the lower extremities [4]. Open versus endovascular treatment options tend to divide phlebologists into enthusiasts and skeptics, who believe that minimally invasive procedures have low effectiveness due to lack of crossotomy or ligation of the saphenofemoral junction [5]. However, this was not confirmed in long-term studies and the relapse risk in new methods was estimated to be comparable to stripping [1]. In 2008, a new method of thermal venous ablation using steam, steam vein sclerosis (SVS), was proposed. This method allows for removal of any kind of varicose veins, including their tributaries and recurrent varicose veins [6].

The most commonly observed side effects associated with thermal ablation, including pain, paresthesia, hematoma, and transient skin discoloration, occur in a relatively small percentage of patients. Other serious complications, such as injury of the deep veins, iatrogenic arteriovenous fistula, or pulmonary embolism caused by fragment of a broken laser fiber, are uncommon [7–11].

Other promising treatment options include non-thermal methods based on mechanical-chemical venous ablation (MOCA), cyanoacrylate adhesives, or microfoam obliteration. All these methods, which are free of thermal effects, cause less trauma and fewer local complications and provide a valid alternative to thermal methods. Mechanochemical ablation with the ClariVein system is the best known method, which is characterized by high effectiveness, reaching 96% in a 2-year follow-up. This is the first hybrid technique that works by mechanical irritation of the vessels with simultaneous sclerotherapy. The patient is mobilized directly after surgery and may return to normal activity the very next day. The advantage of this method is that it does not exert a thermal effect, and therefore does not require tumescent anesthesia. There is also no risk of skin burns, nerve or muscle damage, and postopera-

tive pain and the risk of thrombotic complications are significantly lower [12].

Bishawi et al. indicate that this procedure has a very high effectiveness, reaching 97% in the first 6 weeks after the procedure. Effectiveness is maintained at the level of 96% over 2 years of follow-up [13]. Elias estimated the effectiveness at 96.7% in a follow-up lasting 260 days [14]. He also did not report complications, such as skin or nerve damage. A total of 28% of patients presented with small hematomas, 17% had local skin hardening, and 18% felt discomfort for more than a week after the procedure. High effectiveness of this method over follow-up periods ranging from 6 to 24 months has been confirmed in several other studies [15–20].

Due to the relatively low number of procedures performed and a short follow-up period, this technique requires further trials. It is expected that currently ongoing comparative studies of mechanochemical ablation and thermal techniques, such as EVLT and RF will allow establishment of MOCA as a strong alternative to the current dominant intravenous methods of varicose vein treatment [21–23].

The new, alternative system of mechanochemical ablation presented in this study, Flebogrif™, is significantly simpler than ClariVein. Unlike the ClariVein system, Flebogrif™ does not require an expensive starting system; furthermore, it eliminates the risk of wedging on the venous valves at lower rotation rpm. When performing operations on a small diameter vein (< 4 mm) the risk of vessel perforation in the Flebogrif™ system appears to be minimal. The system also allows effective operation in veins with a diameter exceeding 20 mm, which is not recommended for the ClariVein system. The results of 3 months of follow-up are comparable with the results of ClariVein system application. Moreover, our results are consistent with the preliminary results of other authors using this specific technique, however based on the smaller group of patients. Ciostek et al. in their preliminary study, reported efficacy of the system reaching 94.9% after 3 months of follow-up [24].

Conclusions

The Flebogrif™ system provides high efficiency, high occlusion rate and technical success after three months of follow-up reaching 96%. The system is also characterized by good cosmetic effect and low complication rate. The procedure performed with the Flebogrif™ catheter seems to improve patient quality of life in postoperative period. A long-term follow-up is indicated for complete evaluation of the quality of the MOCA method with the Flebogrif™ catheter.

References

1. Vasić DM, Davidović LB, Maksimović ZV, Crni AR et al (2004) Primary varicose veins: frequency, clinical significance and surgical treatment. *Srp Arh Celok Lek*; 132: 398–403.
2. García-Madrid C, Pastor Manrique JO, Gómez-Blasco F, Planell ES (2012). Update on endovenous radio-frequency closure ablation of varicose veins. *Ann Vasc Surg*; 26: 281–291.
3. van Eekeren RR, Boersma D, Holewijn S et al (2014) Mechanochemical endovenous Ablation versus RADiOfrequeNcy Ablation in the treatment of primary great saphenous vein incompetence (MARADONA): study protocol for a randomized controlled trial. *Trials*; 15: 121.
4. van den Bos RR, de Maeseneer MMG (2012) Endovenous thermal ablation for varicose veins: strengths and weaknesses. *Phlebology*; 19: 163–169.
5. Göckeritz O (2012) Current standards and recent progress in minimally invasive phlebo surgery. *J Cutan Aesthet Surg*; 5: 104–114.
6. Milleret R, Huot L, Nicolini P et al (2013) Great saphenous vein ablation with steam injection: results of a multicentre study. *Eur J Vasc Endovasc Surg*; 45: 391–396.
7. Shepherd AC, Gohel MS, Lim CS et al (2010) Pain following 980-nm endovenous laser ablation and segmental radiofrequency ablation for varicose veins: a prospective observational study. *Vasc Endovascular Surg*; 44: 212–216.
8. Proebstle TM, Vago B, Alm J et al (2008) Treatment of the incompetent great saphenous vein by endovenous radiofrequency powered segmental thermal ablation: first clinical experience. *J Vasc Surg*; 47: 151–156.
9. Proebstel TM, Alm J, Göckeritz O et al (2011) Three-year European follow-up of endovenous radiofrequency-powered segmental thermal ablation of the great saphenous vein with or without treatment of calf varicosities. *J Vasc Surg*; 54: 146–152.
10. Boon R, Akkersdijk GJ, Nio D (2010) Percutaneous treatment of varicose veins with bipolar radiofrequency ablation. *Eur J Radiol*; 75: 43–47.
11. Rasmussen LH, Lawaetz M, Bjoern L, Vennits B, Blemings A, Eklof B (2011) Randomized clinical trial comparing endovenous laser ablation, radiofrequency ablation, foam sclerotherapy and surgical stripping for great saphenous varicose veins. *Br J Surg*; 98: 1079–1087.
12. van den Bos R, Arends L, Kockaert M, Neumann M, Nijsten T (2009) Endovenous therapies of lower extremity varicosities: a meta-analysis. *J Vasc Surg*; 49: 230–239.
13. Bishawi M, Bernstein R, Boter M et al (2013) Mechanochemical ablation in patients with chronic venous disease: a prospective multicenter report. *Phlebology*; 29: 397–400.
14. Elias S, Raines JK (2012) Mechanochemical tumescentless endovenous ablation: final results of the initial clinical trial. *Phlebology*; 27: 67–72.
15. Witte ME, Reijnen MM, de Vries JR, Zeebregts CJ (2015) Mechanochemical endovenous occlusion of varicose veins using the ClariVein® device. *Surg Technol Int*; 26: 219–225.
16. Lane T, Bootun R, Dharmarajah B et al (2017) A multi-centre randomised controlled trial comparing radiofrequency and mechanical occlusion chemically assisted ablation of varicose veins — final results of the Venefit versus ClariVein for varicose veins trial. *Phlebology*; 32: 89–98.

17. Tang TY (2017) ClariVein: MOCA's midterm report — still flavor of the month or a sustainable trend? *J Endovasc Ther*; 24: 156–158.
18. van Eekeren RR, Hillebrands JL, van der Sloot K et al (2014) Histological observations one year after mechanochemical endovenous ablation of the great saphenous vein. *J Endovasc Ther*; 21: 429–433.
19. Tang TY, Kam JW, Gaunt ME (2017) ClariVein® — early results from a large single-centre series of mechanochemical endovenous ablation for varicose veins. *Phlebology*; 32: 6–12.
20. Yun SV, Rashid ST, Blest NC, Spark JI (2015) Lower pain and faster treatment with mechanico-chemical endovenous ablation using ClariVein®. *Phlebology*; 30: 688–692.
21. Bootun R, Lane TR, Dharmarajah B et al (2016) Intra-procedural pain score in a randomised controlled trial comparing mechanochemical ablation to radiofrequency ablation: The Multicentre Venefit™ versus ClariVein® for varicose veins trial. *Phlebology*; 31: 61–65.
22. Boersma D, van Eekeren RR, Kelder HJ et al (2014) Mechanochemical endovenous ablation versus radiofrequency ablation in the treatment of primary small saphenous vein insufficiency (MESSI trial): study protocol for a randomized controlled trial. *Trials*; 15: 421.
23. Leung CCM, Carradice D, Wallace T, Chetter IC (2016) Endovenous laser ablation versus mechanochemical ablation with ClariVein® in the management of superficial venous insufficiency (LAMA trial): study protocol for a randomised controlled trial. *Trials*; 17: 421.
24. Ciostek P, Kowalski M, Woźniak W, Miłek T, Myrcha P, Migda B (2015) Phlebogriffe — a new device for mechanochemical ablation of incompetent saphenous veins: a pilot study. *Phlebological Review*; 23: 72–77.