

Fogarty[®] catheter dilatation of veins smaller than 2.5 mm after completion of the anastomosis during arteriovenous fistula creation

Seyhan Yilmaz¹, Behice Kaniye Yilmaz², Eray Aksoy³, Mehmet Kalender¹, Serdar Gunaydin⁴

¹Derince Training and Research Hospital, Department of Cardiovascular Surgery, Kocaeli, Turkey

²Corum Training and Research Hospital, Department of Radiology, Corum, Turkey

³American Hospital, Department of Cardiovascular Surgery, Istanbul, Turkey

⁴Ankara Numune Hospital, Department of Cardiovascular Surgery, Ankara, Turkey

Abstract

Introduction. Risk of failure after surgical creation of the AVF was linked to the diameter and flow dynamics of the vessel that is to be quantified by preoperative ultrasound mapping. We aimed to report our results using a different technique consisting of Fogarty[®] catheter dilatation of the cephalic vein after completion of the anastomosis.

Material and methods. A total of 23 patients, aged between 35 to 70 years, with a cephalic vein diameter of ≤ 2.5 mm received a dilatation technique for arteriovenous creation. Patients having reoperations, aneurysmatic or thrombosed veins and multiple risk factors were not considered eligible and access failure within 60 days was defined as early fistula failure.

Results. Mean cephalic vein diameter was 2.03 ± 0.28 mm and mean radial artery diameter was 2.33 ± 0.16 mm. At 15th day visit, 21 of 23 patients (91.3%) had patent arteriovenous fistula. Mean time of follow-up was 7.2 ± 1.67 months and was complete in 20 of 21 patients with a patent fistula. Overall patency was 18/23 (78.2%) in patients with survived AVFs.

Conclusion. Fogarty[®] catheter dilatation of the cephalic vein after completion of the anastomosis during arteriovenous fistula creation is effective and safe in patients with small calibrated veins.

Key words: arteriovenous fistula, Fogarty[®] catheter, renal failure

Acta Angiol 2015; 21, 3: 87–92

Introduction

An autologous arteriovenous fistula is the optimal vascular access allowing for repeated interventions for haemodialysis. There has been an increased trend towards the initial use of arteriovenous fistulas because other types of dialysis access, such as grafts and central venous catheters, were shown to be associated with an increased risk of failure and even mortality [1, 2]. Creation of arteriovenous fistula is undertaken well before the planned date for initiation of haemodialysis to allow

for adequate maturation of the AVFs for cannulation. Forearm vessels are widely preferred for creation of AVFs due to the relative ease of the operative technique and avoidance to harm proximal vasculature for future attempts, whereas upper arm vessels were shown to have better patency in high risk patients [3]. Long-term patency of an arteriovenous fistula is dependent on many factors including patients' health status, vessel anatomy, medications and type of anastomosis [4].

Risk of failure after surgical creation of the AVF was linked to the diameter and flow dynamics of the vessel

Address for correspondence: Seyhan Yilmaz, Derince Training and Research Hospital, Kocaeli, Turkey, tel.: +905336838186, fax: +90262317800, e-mail: drlabarna@gmail.com

that is to be quantified by preoperative ultrasound mapping [5, 6]. The recommended threshold for a successful AVF maturation is ≥ 2 mm for arterial diameter and ≥ 2.5 mm for venous diameter [7] whereas such quantification is subject to debate.

Various techniques have been described for the purpose of improving functional outcomes after AVF creation such as, new techniques for anastomosing or balloon angioplasty [8, 9]. Dilating the cephalic vein just before starting anastomosis, either using probes [10] or balloon angioplasty [11], was recently reported to be effective in terms of better maturation. We used a different technique, consisting of prophylactic dilatation of the cephalic vein after completion of the anastomosis, in an effort to ensure a more sustainable increase in vein calibration and also in order to better observe the difference in flow before and after dilating the vein.

Material and methods

The study was approved by local ethics committee. All patients were informed about the procedure. In this retrospective cohort study, the study group was made up of patients who underwent Brescia-Cimino type radio-cephalic AVF creation in the years 2013–2015. Patients were among those referred to department from the nephrology departments. Patient eligibility criterion were as follows: age < 70 years, having advanced stage chronic renal failure, being candidate for haemodialysis within the next 6 months and having radial artery ≥ 1.5 mm and cephalic vein ≤ 2.5 mm in diameter at the level of wrist. The patients who underwent multiple vascular access operation, those with aneurysmatic venous segments on the target arm and advanced heart failure were not considered eligible for the study.

Twenty-three patients were considered eligible for the study. There were 15 women and 8 men with a mean age of 51.91 ± 9.24 years (range: 35–70 years). On admission, a duplex ultrasonography was performed by a radiologist. Functional patency of the AVF was defined as having 300 ml/min flow and achieving 4 hour haemodialysis session. Access failure within 60 days was defined as early fistula failure and delayed fistula failure was defined as failure to continue to access haemodialysis two months after the haemodialysis program was started.

All patients received local anaesthesia with bupivacaine and prophylactic antibiotics were given 20 minutes before the skin incision was made. The incision was made between the cephalic vein and pulsation of the radial artery at the level of wrist. The cephalic vein was confirmed to be ≤ 2.5 mm in diameter and radial artery was confirmed to be ≥ 1.5 mm in diameter. Using silastatic loops, the vein and the artery were brought

close to each other. The vein was flushed and dilated with saline using a small calibre angiocath inserted as distal as possible without dividing the vein. All visible tributary veins were ligated. All anastomoses were created with continuous running 7.0 polypropylene in side-to-side fashion. After the anastomosis was completed, adequacy of thrill was assessed by palpation. The vessel loops were removed and the anastomosis was checked for leakage, if present, additional suturing was done. If sufficient thrill did not occur in the vein, a small calibre (2 F) Fogarty® arterial embolectomy catheter (Edwards Lifesciences, Irvine, USA) was inserted into the vein through the distal of anastomosis and advanced beyond the level of wrist. The balloon of the catheter was inflated with 0.2 ml saline about 10 cm proximal of anastomosis and kept for several seconds without withdrawing. The balloon was deflated and the catheter was withdrawn a few centimetres distally and then inflated again. This was repeated until the balloon reaches the level of anastomosis with inflation being gradually reduced. At last, the vein was dilated just at the level of anastomosis and the catheter was withdrawn. The cephalic vein was ligated distal to the anastomosis and the vein palpated to assess adequacy of thrill (Figure 1).

Statistical analysis

All statistical analyses were performed using Medcalc statistical software. Visual histograms and analytical methods (Kolmogorov-Smirnov/Shapiro-Wilk's test) were used for determination of normal distribution. Continuous variables were defined by the mean \pm standard deviations. A p value less than 0.05 was considered as statistically significant.

Results

Baseline patient characteristics are shown in Table I. Left side AVF creation was performed in 17 patients (73.9%) and right side AVF creation was performed in 6 (26.0%) patients. Non-dominant arm was used in 18 (78.2%) patients. None of the patients were receiving haemodialysis at the time of operation.

Mean cephalic vein diameter was 2.03 ± 0.28 mm (ranged from 1.50 to 2.50 mm) and mean radial artery diameter was 2.33 ± 0.16 mm.

After completion of the anastomosis, an adequate thrill was not present but there was moderate pulsatile flow in cephalic vein in 13/23 patients. A poor thrill was present in 4/23 patients. Six patients had neither thrill nor pulsatile flow in cephalic vein after completion of the anastomosis. Fogarty® catheter dilatation resulted in an adequate thrill in 20/23 patients (86.9%), whereas remaining 3 patients only had marked pulsatile flow without having an adequate thrill on cephalic vein.

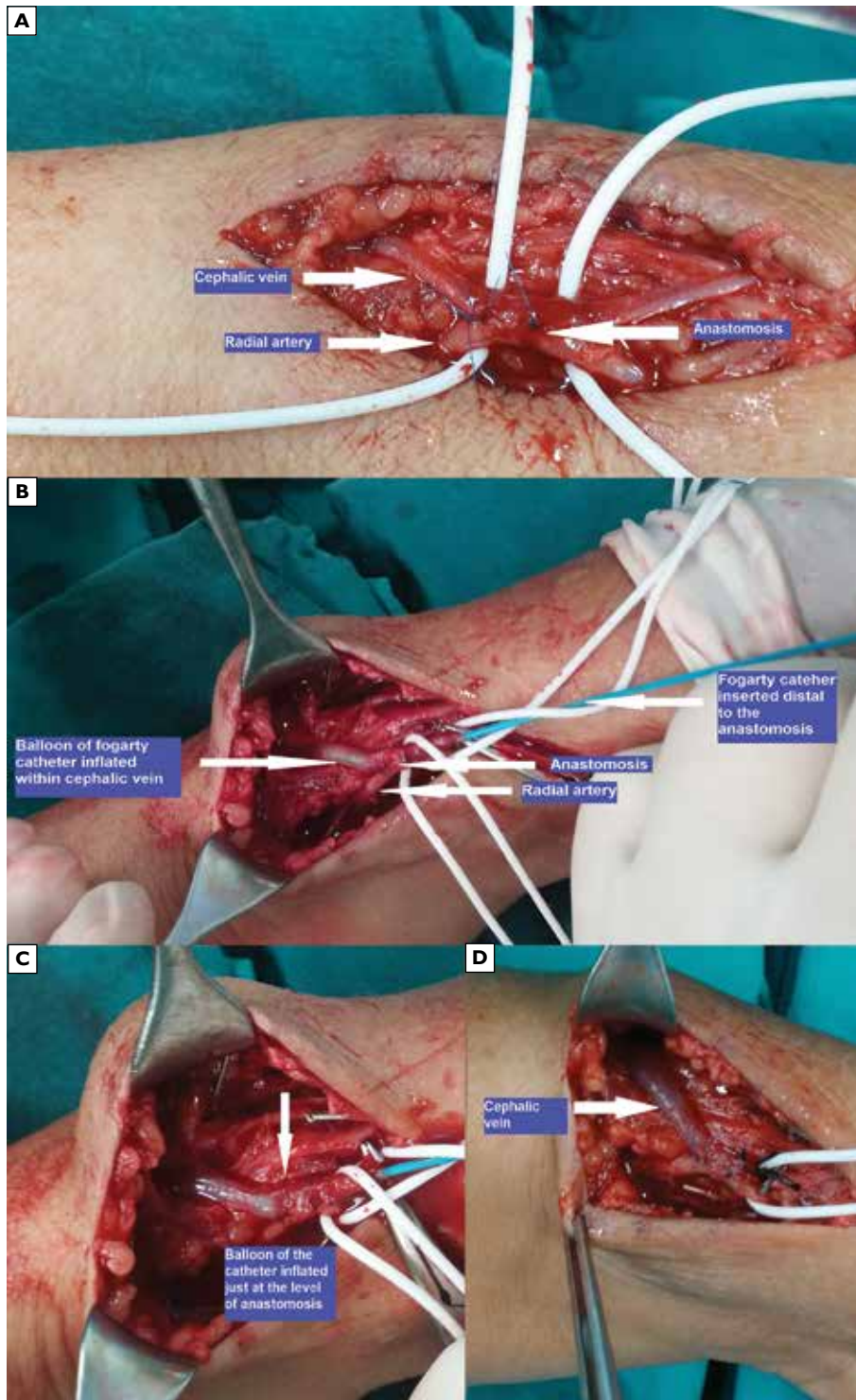


Figure 1.A. Photo taken after completion of the anastomosis; **B.** Balloon dilatation of the cephalic vein with Fogarty® arterial embolectomy catheter inserted distal to the anastomosis; **C.** Dilatation at the site of the anastomosis; **D.** Cephalic vein is seen markedly increased in diameter

Early complications were listed in Table 2. Postoperative bleeding occurred in 1 patient and this patient underwent a second revision to control bleeding. The leak was repaired without repeating the anastomosis.

Three patients with acute venous thrombus underwent revision surgery for removal of the thrombus. Opening the ligation of vein at distally to the anastomosis site, the thrombus was removed using an appropriate sized

Table 1. Baseline characteristics

Variable	N (%)	Mean \pm SD
Male/Female	8/15	
Age (years)		51.91 \pm 9.24
Diabetes	12 (52.1%)	
Hypertension	18 (78.2%)	
BMI [kg/m ²]		23.67 \pm 3.56
Tobacco use	10 (43.4%)	

Table 2. Postoperative complications

Complication	n
Bleeding	1
Haematoma	–
Thrombosis	3
Infection	–
Total	4

Fogarty® arterial embolectomy catheter. The cephalic vein was flushed with saline. Two of these patients did not benefit from thrombectomy and a brachio-cephalic AVF was created on the ipsilateral side two weeks after the operation. Thus, at 15th day visit, 21 of 23 patients (91.3%) had patent AVFs on the examination of thrill and bruits.

Mean time of follow-up was 7.2 \pm 1.67 months and was complete in 20 of 21 patients who discharged with a patent radio-cephalic AVF. In two patients AVFs failed within 60 days, duplex ultrasound revealed no thrombus formation within the cephalic vein lumen. These patients underwent a second operation for brachio-cephalic AVF creation, thus overall patency was 18/23 (78.2%). Patients with patent AVF's received their first haemodialysis at a mean time of 4.94 \pm 0.99 weeks (range 3.00 to 7.00 weeks) after the operation. None of the patients had extra complications including arm oedema, hand ischaemia, infection and venous aneurysms. None of the patients had delayed fistula failure during follow-up.

Discussion

Our study showed that balloon dilatation of the cephalic vein during radio-cephalic AVF creation allows for creation of a patent fistula without adding too much risk of complications in a selected group of patients. Using this technique, we achieved encouraging results in a small group of patients where we followed certain

criterion for eligibility. Patients with advanced age, those with a history of failed attempts for AVF creation and those having several systemic diseases were not considered suitable for the study in order to ensure the technical advantage and efficacy of the technique before extending its usage to more complicated cases. In addition, patients in this study were not of advanced age and they would likely to continue on haemodialysis in long-term. This was why we insisted on performing the procedure at the level of wrist allowing upper arm veins remain intact to be used in future interventions for access.

Flushing the vein with heparinized saline is widely used and is often done before starting the anastomosis. It allows not only testing the vein against resistance, but also distending it throughout its course in the arm [12]. Using the technique described here, we achieved relatively more controlled and more sustainable vein distension because the cephalic vein could be equally distended from its origin to the site of anastomosis. The technique provided transmitting a near-equal pressure in every few centimetres of the vein, which may not always possible with saline flushing due to tributary branches. We recommend being cautious when distending the vein over the site of anastomosis to preclude inadvertent bleeding from suture line and rupturing. Inflating the catheter's balloon slightly will be sufficient to achieve improved flow.

Mendes et al. [5] conducted a vein mapping study on 44 patients undergoing Brescia-Cimino radiocephalic AVF creation and proposed that wrist fistulas should be avoided in patients having a cephalic vein size of 2.0 mm or less. Some authors suggested that adequacy of the pre-operative radial artery diameter should be the main concern in construction of wrist AVFs [13] whereas some others claimed that venous diameter was the major predictor of fistula maturation [14].

However, it is still controversial that the diameter of the vein may be taken as the only parameter to define the threshold for creation of a successful wrist fistula. Kheda et al. suggested that arterial elasticity was more important than venous dilatation to achieve an adequate blood flow after AVF creation [15]. Also, since venous diameter is not constant but may even show daily changes [16], the elasticity and the distensibility of the vein have also been regarded as important features to define the adequacy for AVF creation [17].

The increasing knowledge of the potential complications related to central venous catheters and graft fistulas have led to the development and widespread use of endovascular therapies for saving failed fistulas [18]. Interventional radiology procedures consisting of balloon dilatation of the stenosed and thrombosed veins have increased in popularity because such methods

are appealing in avoiding the need for surgical re-interventions [19]. Although data is limited, peripheral stenting was also reported to be useful in patients with unsatisfactory outcomes after balloon angioplasty [20]. From this point of view, prophylactic dilatation of small calibre veins during the wrist AVF creation sounds plausible in an effort to give patients the best possible chance before proceeding to use upper arm veins or other alternatives.

Our study was not the first reporting intraoperative use of balloon dilatation during AVF creation. Garcia et al. [21] performed the technique in a similar manner to our, but just before starting the anastomosis. They implemented a subsequent balloon dilatation program consisting of sequential angioplasty for maturation of the veins. At 6 months follow-up, 47 of 55 patients (85.4%) achieved a working AVF at the initial site of the operation. Given that success rates we obtained was similar to reported in this study, the technique we adopted seems as effective as that they described whereas being technically less demanding.

In a more recent study, Fila et al. [10] described an alternative way for distending the veins using vessel probes again before beginning the anastomosis. The authors implemented the technique they adopted in patients having veins smaller than 2 mm in diameter. Although the technique seems affordable, this study did not report excellent outcomes in primary patency rates.

Laskowski et al. [22] reported a study with interesting results, where they performed regional nerve block to provide venous dilatation before AVF creation. In nearly one-third of patients, regional nerve block changed the decision for creating the vascular access from catheter placement towards AVF creation, based on intraoperative ultrasound imaging. This method seems promising, especially if it would be combined with the technique we described herein.

The main limitations of our study are as follows; low number of patients, lack of randomization and control group. The technique was used in a selected group of patients and this fact restrains the generalization of the results.

Conclusions

Given the potential and life-threatening complications of central venous catheters and graft fistulas, every effort should be undertaken to achieve a well-functioning AVF. In patients with end-stage renal failure, especially in those having a longer life expectancy, upper arm vessels should be preserved as much as possible for future interventions. Intraoperative dilatation of the cephalic vein after completion of the anastomosis is likely to offer a similar method with potential benefits.

Further study is warranted to establish the generalizability in different patient groups.

References

1. Ravani P, Palmer SC, Oliver MJ et al (2013) Associations between hemodialysis access type and clinical outcomes: a systematic review. *J Am Soc Nephrol*; 24: 465–473.
2. Ocak G, Rotmans JI, Vossen CY et al (2013) Type of arteriovenous vascular access and association with patency and mortality. *BMC Nephrol*; 14: 79.
3. Chiulli LC, Vasilas P, Dardik A (2011) Superior patency of upper arm arteriovenous fistulae in high risk patients. *J Surg Res*; 170: 157–164.
4. Smith GE, Gohil R, Chetter IC (2012) Factors affecting the patency of arteriovenous fistulas for dialysis access. *J Vasc Surg*; 55: 849–855.
5. Mendes RR, Farber MA, Marston WA, Dinwiddie LC, Keagy BA, Burnham SJ (2002) Prediction of wrist arteriovenous fistula maturation with preoperative vein mapping with ultrasonography. *J Vasc Surg*; 36: 460–463.
6. Saucy F, Haesler E, Haller C, Déglise S, Teta D, Corpataux JM (2010) Is intra-operative blood flow predictive for early failure of radiocephalic arteriovenous fistula? *Nephrol Dial Transplant*; 25: 862–867.
7. Tordoir J, Canaud B, Haage P et al (2007) EBPG on Vascular Access. *Nephrol Dial Transplant*; 22: 88–117.
8. Raynaud A, Novelli L, Bourquelot P, Stolba J, Beyssen B, Franco G (2009) Low-flow maturation failure of distal accesses: Treatment by angioplasty of forearm arteries. *J Vasc Surg*; 49: 995–999.
9. Bharat A, Jaenicke M, Shenoy S (2012) A novel technique of vascular anastomosis to prevent juxta-anastomotic stenosis following arteriovenous fistula creation. *J Vasc Surg*; 55: 274–280.
10. Fila B, Lovčić V, Sonicki Z, Magaš S, Sudar-Magaš Z, Malovrh M (2014) Vein diameter after intraoperative dilatation with vessel probes as a predictor of success of hemodialysis arteriovenous fistulas. *Med Sci Monit*; 20: 191–198.
11. Veroux P, Giaquinta A, Tallarita T, Sinagra N, Virgilio C, Zerbo D (2013) Primary balloon angioplasty of small (≤ 2 mm) cephalic veins improves primary patency of arteriovenous fistulae and decreases reintervention rates. *J Vasc Surg*; 57: 131–136.
12. Kumar A, Jha MS, Singla M et al (2007) Radio-median cubital/radiocephalic arteriovenous fistula at elbow to prevent vascular steal syndrome associated with brachiocephalic fistula: Review of 320 cases Indian. *J Urol*; 23: 261–264.
13. Parmar J, Aslam M, Standfield N (2007) Pre-operative radial arterial diameter predicts early failure of arteriovenous fistula (AVF) for haemodialysis. *Eur J Vasc Endovasc Surg*; 33: 113–135.
14. Lauvao LS, Ihnat DM, Goshima KR, Chavez L, Gruessner AC, Mills JL Sr (2009) Vein diameter is the major predictor of fistula maturation. *J Vasc Surg*; 49: 1499–1504.
15. Kheda MF, Brenner LE, Patel MJ, Wynn JJ, White JJ, Prisant LM (2010) Influence of arterial elasticity and vessel dilatation on arteriovenous fistula maturation: a prospective cohort study. *Nephrol Dial Transplant*; 25: 525–531.
16. Planken RN, Keuter XH, Hoeks AP, Kooman JP, van der Sande FM, Kessels AG (2006) Diameter measurements of the forearm

- cephalic vein prior to vascular access creation in end-stage renal disease patients: graduated pressure cuff versus tourniquet vessel dilatation. *Nephrol Dial Transplant*; 21: 802–806.
17. Van der Linden J, Lameris TW, van den Meiracker AH, de Smet AA, Blankestijn PJ, van den Dorpel MA (2006) Forearm venous distensibility predicts successful arteriovenous fistula. *Am J Kidney Dis*; 47: 1013–1019.
 18. Beathard GA (2009) Fistula salvage by endovascular therapy. *Adv Chronic Kidney Dis*; 16: 339–351.
 19. Turmel-Rodrigues L (2008) Dilatation is usually the best treatment for stenosis of the arteriovenous hemodialysis fistula. *Nat Clin Pract Nephrol*; 4: 116–117.
 20. Pan HB, Liang HL, Lin YH, Chung HM, Wu TH, Chen CY (2005) Metallic stent placement for treating peripheral outflow lesions in native arteriovenous fistula hemodialysis patients after insufficient balloon dilatation. *Am J Roentgenol*; 184: 403–409.
 21. De Marco Garcia LP, Davila-Santini LR, Feng Q, Calderin J, Krishnasstry KV, Panetta TF (2010) Primary balloon angioplasty plus balloon angioplasty maturation to upgrade small-caliber veins (< 3 mm) for arteriovenous fistulas. *J Vasc Surg*; 52: 139–144.
 22. Laskowski IA, Muhs B, Rockman CR et al (2007) Regional nerve block allows for optimization of planning in the creation of arteriovenous access for hemodialysis by improving superficial venous dilatation. *Ann Vasc Surg*; 21: 730–733.