

# Angioplasty of the popliteal artery using the Jaguar™ stent

Paweł Potoczny, Piotr Janik, Adam Uryniak

PAKS IX Rzeszów Centre of Vascular and Endovascular Surgery, Rzeszów, Poland

## Abstract

**Introduction.** The aim of this study was to evaluate the effectiveness of the endovascular treatment of atherosclerotic stenosis/occlusion of the popliteal artery according to TASC II recommendations using the Jaguar SM self-expanding stent depending on the modifiable and unmodifiable risk factors of repeated stenosis/occlusions.

**Material and methods.** The study included 126 men and 46 women aged 46–95 years in 2011–2015. Surgeries were performed in the scheduled and emergency mode. Angioplasty of the popliteal artery with the Jaguar stent implantation was performed in patients with severe chronic limb ischaemia and critical limb ischaemia. Post-operative popliteal artery patency was evaluated in relation to sex, obesity, diabetes, smoking tobacco, and patency of the lower extremity arteries.

**Results.** The postoperative patient follow-up was conducted for 60 months, demonstrating 67% patency after 12 months, 59% patency after 24 months, 53% patency after 36 months, 45% patency after 48 months, and 31% patency after 60 months.

**Conclusions.** The Jaguar™ stent implantation is an effective and safe method of treatment of atherosclerotic stenosis and occlusion of the popliteal artery. The occlusion was found in patients with the risk factors such as: obesity, diabetes, and tobacco smoking, limited runoff arteries in the lower leg. Stent fracture did not occur in any patient.

**Key words:** popliteal artery, balloon angioplasty, endovascular surgery, PTA, Jaguar SM self-expanding stent

Acta Angiol 2018; 24, 3: 80–85

## Introduction

The popliteal artery is one of the most movable arteries. Treatment of atherosclerotic lesions in the popliteal artery near the knee joint poses a challenge for the endovascular treatment due to the biomechanical processes taking place in this area. The morphology of the popliteal artery changes as the knee joint moves. Rotational, tensile, and compressive forces acting simultaneously on the artery and the stent have a negative effect on the results of endovascular procedures. For many years the lesions in this area have been surgical-

ly treated most frequently using the saphenous vein. Nowadays, with the development and improvement of endovascular materials, the number of minimally invasive procedures in this area has increased significantly. A normal balloon angioplasty or a mechanical atherectomy are the preferred methods of treatment in case of atherosclerotic lesions in the popliteal artery [1]. When the efficacy of these techniques is insufficient, the stent implantation is necessary [2, 3].

The first results from the implantation of steel stents to the popliteal artery were unsatisfactory (due to the inadequate physical properties of the material in trou-

**Address for correspondence:** Paweł Potoczny, PAKS IX Rzeszów Centre of Vascular and Endovascular Surgery, Rzeszów, Poland, Ks. Jałowego 10, 35–010 Rzeszów, Poland, e-mail: [pawopo@gmail.com](mailto:pawopo@gmail.com)

blesome anatomical and functional locations). Slightly better results were achieved using nitinol stents. However, there have always been concerns about potential stent breakage and subsequent restenosis.

Nowadays, stents are more often implanted after angioplasty, because there is not only an assumption, but also numerous comments and scientific publications confirming that the better production technology, efficiency, and physical structure of the new stents is applicable in these anatomic locations. This idea is supported by numerous publications [4, 5].

## Material and methods

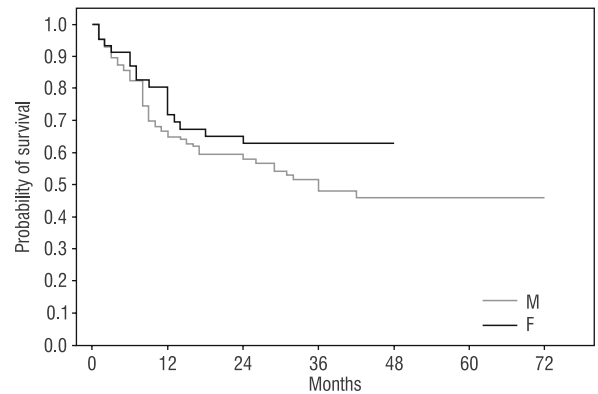
The aim of this study was to retrospectively analyse the efficacy and durability of endovascular angioplasty of stenosis and occlusions of the popliteal artery using the Jaguar stent.

The study included 126 men and 46 women, a total of 172 patients treated in 2011–2015. Surgeries were performed in the scheduled and emergency mode. The age range of these patients was between 46 and 95 years. Atherosclerosis was the causative factor in case of all the arterial lesions. Smokers accounted for 25.5% of all patients, obesity was found in 31.5%, diabetes in 24.5%, while 48% of patients were treated due to arterial hypertension, connective tissue diseases, and hyperlipidaemia. The patients qualified for the surgery included those with severe ischaemic symptoms of lower extremities (claudication distance less than 100 m), and with symptoms of critical limb ischemia (pain during rest, ulcerations, necrosis). The patients were prepared for the surgeries in a typical way. After the arteriography was performed, the balloon angioplasty was performed first. The stent was implanted in case of ineffective artery dissection, atherosclerotic plaque detachment or separation, and in case of restenosis after previous intervention. Each stent was post-dilated with a balloon. After the procedure, patients received a double antiplatelet therapy and low molecular weight heparin in a prophylactic dose. On the first post-op day they were discharged home, with further treatment and follow-up continued in outpatient basis. The effectiveness of the treatment was evaluated in 12-month, 2-year, 3-year, 4-year and 5-year follow-ups.

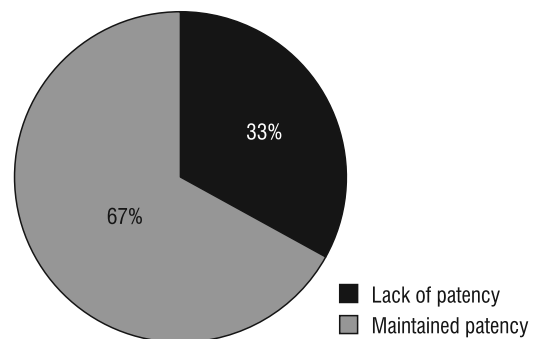
## Results

Long-term patency of the popliteal artery after the Jaguar™ stent implantation is shown on the KM curve (Fig. 1).

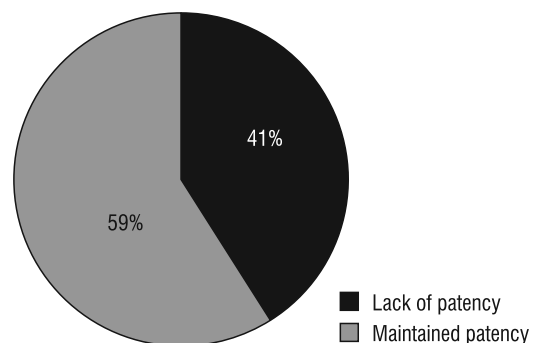
In the specific years of follow-up, it is presented as follows.



**Figure 1.** Observation of the five-year patency of the popliteal artery — a summary chart. Patience and sex



**Figure 2.** PA Patency after 12 months



**Figure 3.** PA Patency after 24 months

During 12-month follow-up, the patency of the popliteal artery was maintained in 115 patients, i.e. 67% (Fig. 2).

During the 24-month follow-up, the patency of the popliteal artery was maintained in 102 patients, i.e. 59% (Fig. 3).

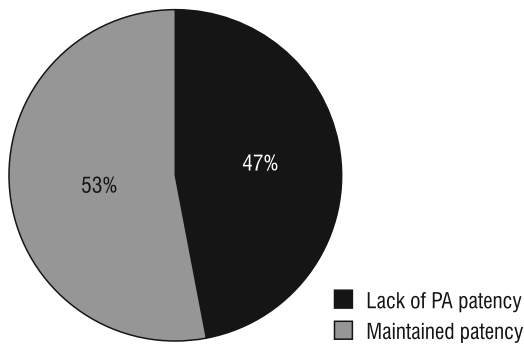


Figure 4. PA Patency after 36 months

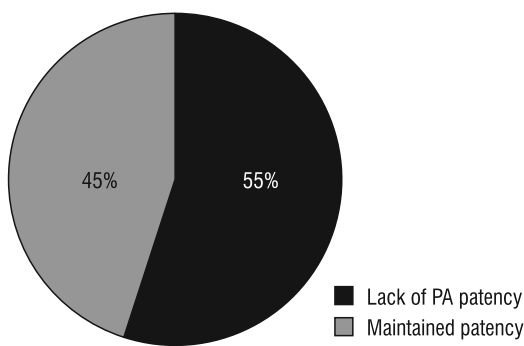


Figure 5. PA Patency after 48 months

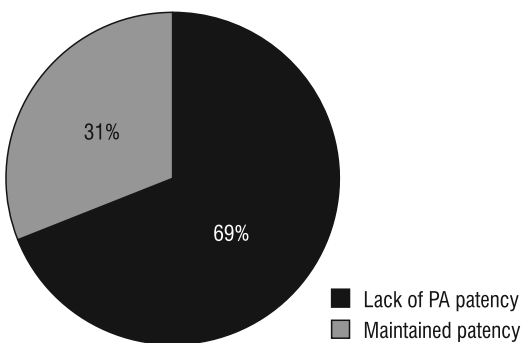


Figure 6. PA Patency after 60 months

During the 36-month follow-up, the patency of the popliteal artery was maintained in 54 patients (102 patients in 3-year follow-up), i.e. 53% (Fig. 4).

During the 48-month follow-up, the patency of the popliteal artery was maintained in 26 patients (58 patients in the 4-year follow-up), i.e. 45% (Fig. 5).

During the 60-month follow-up, the patency of the popliteal artery was maintained in 5 patients (16 patients in the 5-year follow-up), i.e. 31% (Fig. 6).

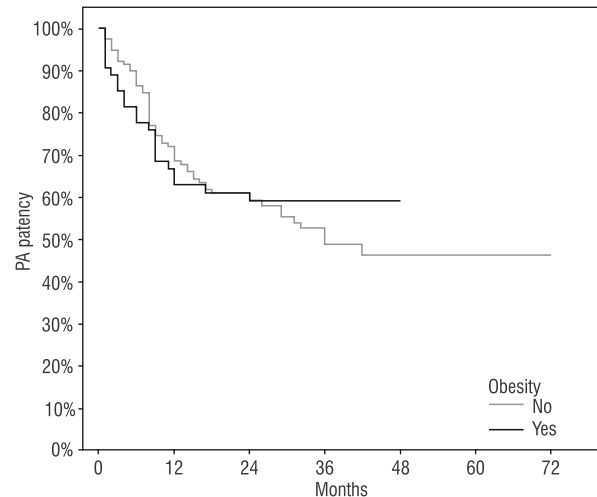


Figure 7. Patency of the popliteal artery after stent implantation and the occurrence of obesity

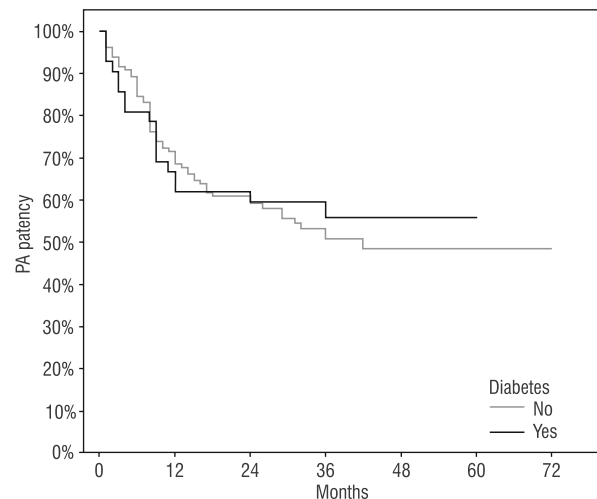


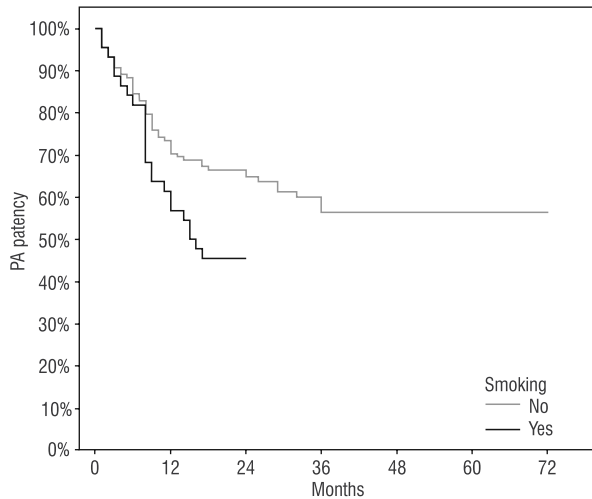
Figure 8. Patency of the popliteal artery after stent implantation and the occurrence of diabetes mellitus

Patients who experienced stent occlusion after the implantation were evaluated for the presence of all known risk factors such as obesity, diabetes, and smoking. This is shown in the KM figures (Figures 7–9).

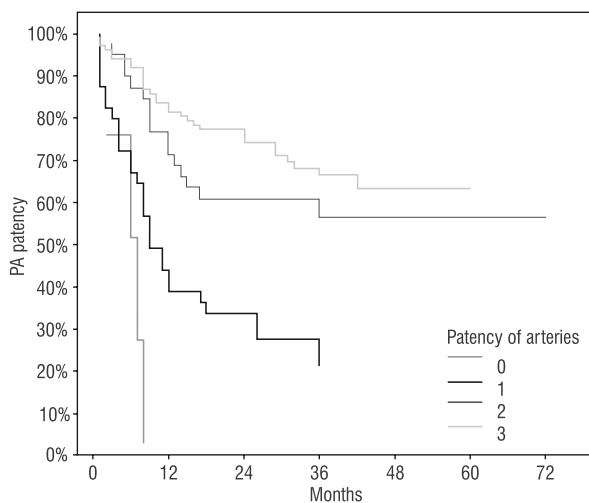
In the long-term follow-up the patency of the arteries below the knee — a condition of the so-called good runoff — is an important factor that provides good results after the stent implantation into the popliteal artery (Fig. 10).

### Discussion

The advantages of the endovascular treatment of stenosis/obstructions did not raise any doubts in the



**Figure 9.** Patency of the popliteal artery after stent implantation and smoking



**Figure 10.** Patency of the popliteal artery after the stent implantation and the amount of expensive arteries of the shin

global indications. However, is the use of the self-expandable stent in the popliteal segment the best solution? What can we say today?

Over the years, the preferred treatment method of occlusions in the femoro-popliteal segment from the adductor's canal to the anterior tibial artery origin was the femoropopliteal bypass from the patient's own vein or using a vascular prosthesis [6–8]. However, despite the effectiveness of this method, complications associated with this surgical technique occurred in patients [9].

The endovascular therapy is currently the most commonly used method of treatment in case of the peripheral artery lesions. RESILIENT2 — the first large randomized study — showed good results of

the endovascular treatment in changes in the femoral and popliteal segment. [11, 13]. Currently, there are guidelines of the European Society of Cardiology (ESC 2017, Europe)/European Society for Vascular Surgery (ESVS 2017, Europe), Chirurgia Polska (2009, Polska) confirming the effectiveness of this method in the treatment of atherosclerotic lesions in the peripheral arteries of the lower extremities [10, 11].

Atherosclerotic lesions in peripheral arteries grow for years. The nature of these lesions is usually multifocal and varied (stenoses and occlusions). Having considered the foregoing in the initial recommendations the patients with advanced lesions (TASC C and D) should be disqualified from endovascular treatment. At the moment, based on numerous scientific studies, patients with very advanced atherosclerotic lesions are suggested to be treated by means of endovascular procedure [12]. Although we achieve worse results in the long-term observations, this treatment allows healing of ischaemic ulcers and may prevent early amputation. It also does not interfere with the implementation of the femoropopliteal bypass which can be implanted below the implanted stent [14, 15].

Whether the stent implantation provides better results compared to the angioplasty without the stent implantation, it still raises a lot of controversies. Among other things, in their meta-analysis, Balk et al. did not find any significant differences in clinical results, including repeated intervention, amputation, mortality, and frequency of complications between patients undergoing balloon angioplasty (PTA) alone and stenting.

Recent studies, however, demonstrate better results and greater efficacy after the stent implantation. In a recent meta-analysis including a total of 40 randomized studies, Simpson et al. e.g. proved that the implantation of self-expanding stents significantly reduces recurrent stenoses and occlusions when compared to the angioplasty without the stent implantation.

The second stage of the study (RESILIENT2) [10] comparing the stent and balloon angioplasty implantation in the femoropopliteal segment showed greater efficacy after the stent implantation compared to the balloon angioplasty alone. 80% patency after the stent deployment and 38% patency after the angioplasty alone were achieved in the 12-month follow-up [13].

The selection of the stent depends on many factors: diameter, length, elasticity, and susceptibility to fractures. Modern Nitinol® Jaguar™ braided stent presents good biocompatibility. It is made without welding or soldering and is resistant to corrosion. This stent perfectly adapts to the curvature of the vessel and adheres to the artery wall. It is radiologically visible with all its markers, providing the ability to manipulate the stent

inside the vessel even after a partial deployment. It also has a system to prevent migration [16].

Our results with the Jaguar™ stent are comparable to the results of other authors using other nitinol stents in this area, confirming that Jaguar™ self-expanding stent meets the expectations and clinical demands associated with it [17–19].

Restenosis is one of the most important problems in the endovascular surgery. The increase in the thickness of the intima-media complex as a response to trauma, such as PTA or the stent implantation, is one of the factors leading to stenosis recurrence. Searches for new endovascular treatment equipment have led to the production of drug-eluting balloons and stents, with the aim of stopping the hypertrophy of the intima. After the assessment of several years of follow-ups, the effectiveness of this method is comparable to the traditional one [20–23].

Percutaneous atherectomy is another method of restoring the flow in the occluded segments of the popliteal artery. So far, however, atherectomy has not been widely used due to a significant percentage of restenosis [24, 25].

## Conclusions

The Jaguar stent implantation is an effective and safe method of treatment in the atherosclerotic stenosis and occlusion of the popliteal artery.

1. In the 1-year follow-up, only less than 1/3 of patients experienced an occlusion.
2. Stent fracture did not occur in any patient.
3. The number of patent below the knee arteries is an important factor in maintaining patency of the popliteal artery after the stent implantation.
4. The metabolic syndrome is an important factor causing recurring occlusion of the popliteal artery after the stent implantation.

## Conflict of interest

None.

## References:

1. Adam DJ, Bradbury AW. Dokument TASC II w leczeniu chorób tętnic obwodowych. *Eur J Vasc Endovasc Surg.* 2007 ; 33(1): 1–2.
2. Komisja ds. Zaleceń: Polskiego Towarzystwa Chirurgii Naczyniowej, Polskiego Towarzystwa Angiologicznego, Polskiego Towarzystwa Flebologicznego, Polskiego Towarzystwa Radiologicznego. Polskie zalecenia wewnątrznaczyniowego leczenia chorób tętnic obwodowych i aorty 2009. *Chirurgia Polska.* 2009; 11: 1–12.
3. Wroński J. Zabiegi wewnątrznaczyniowe w chorobach niedokrwiennych kończyn i OUN. <https://docplayer.pl/9337963-Zabiegi-wewnatrznaczyniowe-w-chorobach-niedokrwiennych-konczyn-i-oun.html>.
4. Richter GM, Roeren TH, Loelge G. Percutaneous Transluminal AnSuperior clinical results of iliac stent placement versus percutaneous transluminal angioplasty: four-years angioplasty of the subclavian arteries. *Radiology.* 1991; 18(Suppl): 161.
5. Triller J, Walpoth B, Stirnemann P, et al. A comparison study of self-expandable stents vs balloon angioplasty alone in femoropopliteal artery occlusions. *CardioVascular and Interventional Radiology.* 1992; 15(5): 306–312, doi: [10.1007/bf02733955](https://doi.org/10.1007/bf02733955).
6. Taylor LM, Edwards JM, Porter JM. Present status of reversed vein bypass grafting: five-year results of a modern series. *J Vasc Surg.* 1990; 11(2): 193–205; discussion 205, indexed in Pubmed: [2299743](https://pubmed.ncbi.nlm.nih.gov/2299743/).
7. Bergamini TM, Towne JB, Bandyk DF, et al. Experience with in situ saphenous vein bypasses during 1981 to 1989: determinant factors of long-term patency. *J Vasc Surg.* 1991; 13(1): 137–47; discussion 148, indexed in Pubmed: [1987385](https://pubmed.ncbi.nlm.nih.gov/1987385/).
8. Donaldson MC, Mannick JA, Whittemore AD. Femoral-distal bypass with in situ greater saphenous vein. Long-term results using the Mills valvulotome. *Ann Surg.* 1991; 213(5): 457–64; discussion 464, indexed in Pubmed: [2025066](https://pubmed.ncbi.nlm.nih.gov/2025066/).
9. Goshima KR, Mills JL, Hughes JD. A new look at outcomes after infrainguinal bypass surgery: traditional reporting standards systematically underestimate the expenditure of effort required to attain limb salvage. *J Vasc Surg.* 2004; 39(2): 330–335, doi: [10.1016/j.jvs.2003.10.020](https://doi.org/10.1016/j.jvs.2003.10.020), indexed in Pubmed: [14743132](https://pubmed.ncbi.nlm.nih.gov/14743132/).
10. Aboyans V, Ricco JB, Bartelink MEL, et al., 2017 ESC guidelines on the diagnosis and treatment of peripheral arterial diseases, in collaboration with the European Society for Vascular Surgery (ESVS). Endorsed by: the European Stroke Organization (ESO). The Task Force for the diagnosis and treatment of peripheral arterial diseases of the European Society of Cardiology (ESC) and of the European Society for Vascular Surgery (ESVS), ESC Scientific Document Group *European Heart Journal*, 2017; doi: [10.1093/eurheartj/ehx095](https://doi.org/10.1093/eurheartj/ehx095).
11. Polish recommendations for intravascular treatment of peripheral artery and aorta diseases — 2009. *Chirurgia Polska* 2009; 11(1): 1–12.
12. Neil N. Stent fracture in the superficial femoral and proximal popliteal arteries: literature summary and economic impacts. *Perspect Vasc Surg Endovasc Ther.* 2013; 25(1–2): 20–27, doi: [10.1177/1531003513509122](https://doi.org/10.1177/1531003513509122), indexed in Pubmed: [24225504](https://pubmed.ncbi.nlm.nih.gov/24225504/).
13. Laird JR, Katzen BT, Scheinert D, et al. RESILIENT Investigators. Nitinol stent implantation versus balloon angioplasty for lesions in the superficial femoral artery and proximal popliteal artery: twelve-month results from the RESILIENT randomized trial. *Circ Cardiovasc Interv.* 2010; 3(3): 267–276, doi: [10.1161/CIRCINTERVENTIONS.109.903468](https://doi.org/10.1161/CIRCINTERVENTIONS.109.903468), indexed in Pubmed: [20484101](https://pubmed.ncbi.nlm.nih.gov/20484101/).
14. Rabellino M, Zander T, Baldi S, et al. Clinical follow-up in endovascular treatment for TASC C-D lesions in femoro-popliteal segment. *Catheter Cardiovasc Interv.* 2009; 73(5): 701–705, doi: [10.1002/ccd.21971](https://doi.org/10.1002/ccd.21971), indexed in Pubmed: [19309709](https://pubmed.ncbi.nlm.nih.gov/19309709/).
15. Stecko W, Rogala W, Feldo M, et al. Results of endovascular treatment of iliac and femoral symptomatic lesions. Identifi-

- cation of re-intervention risk factors. *Acta Angiologica*. 2017; 23(3): 115–123, doi: [10.5603/aa.2017.0010](https://doi.org/10.5603/aa.2017.0010).
16. Brouillet J, Deloose K, Goueffic Y, et al. Primary stenting for TASC C and D femoropopliteal lesions: one-year results from a multicentric trial on 203 patients. *J Cardiovasc Surg (Torino)*. 2018; 59(3): 392–404, doi: [10.23736/S0021-9509.16.09282-X](https://doi.org/10.23736/S0021-9509.16.09282-X), indexed in Pubmed: [27272981](https://pubmed.ncbi.nlm.nih.gov/27272981/).
  17. Charakterystyka produktu. <http://balton.pl/produkty/kardiologia-i-radiologia/jaguar-stent-samorozprezalny>.
  18. Bosiers M, Deloose K, Callaert J, et al. Results of the Protégé EverFlex 200-mm-long nitinol stent (ev3) in TASC C and D femoropopliteal lesions. *J Vasc Surg*. 2011; 54(4): 1042–1050, doi: [10.1016/j.jvs.2011.03.272](https://doi.org/10.1016/j.jvs.2011.03.272), indexed in Pubmed: [21636239](https://pubmed.ncbi.nlm.nih.gov/21636239/).
  19. Kickuth R, Keo HH, Triller J, et al. Initial clinical experience with the 4-F self-expanding XPERT stent system for infrapopliteal treatment of patients with severe claudication and critical limb ischemia. *J Vasc Interv Radiol*. 2007; 18(6): 703–708, doi: [10.1016/j.jvir.2007.03.012](https://doi.org/10.1016/j.jvir.2007.03.012), indexed in Pubmed: [17538131](https://pubmed.ncbi.nlm.nih.gov/17538131/).
  20. Laird J, Jaff MR, Biamino G, et al. Cryoplasty for the treatment of femoropopliteal arterial disease: results of a prospective, multicenter registry. *J Vasc Interv Radiol*. 2005; 16(8): 1067–1073, doi: [10.1097/O1.RVI.0000167866.86201.4E](https://doi.org/10.1097/O1.RVI.0000167866.86201.4E), indexed in Pubmed: [16105918](https://pubmed.ncbi.nlm.nih.gov/16105918/).
  21. Werk M, Langner S, Reinkensmeier B, et al. Inhibition of restenosis in femoropopliteal arteries: paclitaxel-coated versus uncoated balloon: femoral paclitaxel randomized pilot trial. *Circulation*. 2008; 118(13): 1358–1365, doi: [10.1161/CIRCULATIONAHA.107.735985](https://doi.org/10.1161/CIRCULATIONAHA.107.735985), indexed in Pubmed: [18779447](https://pubmed.ncbi.nlm.nih.gov/18779447/).
  22. Tepe G, Zeller T, Albrecht T, et al. Local delivery of paclitaxel to inhibit restenosis during angioplasty of the leg. *N Engl J Med*. 2008; 358(7): 689–699, doi: [10.1056/NEJMoa0706356](https://doi.org/10.1056/NEJMoa0706356), indexed in Pubmed: [18272892](https://pubmed.ncbi.nlm.nih.gov/18272892/).
  23. Recommendation No. 8/2018 of 11th January 2018 of the president of the Agency for Health Technology Assessment and Tariff System concerning the validity of healthcare provision qualification – “Balloon Angioplasty of the Lower Limb Arteries (femoral and popliteal arteries), using drug-eluting balloon”, as a standard agreement health service in terms of hospital treatment.
  24. Gammon R. Plaque excision treatment of infrainguinal PAD. *Endovascular Today*. 2005; 4(6): 70–74.
  25. Zeller T, Krankenberg H, Reimers B, et al. Initial clinical experience with a new percutaneous peripheral atherectomy device for the treatment of femoro-popliteal stenoses. *Rofo*. 2004; 176(1): 70–75, doi: [10.1055/s-2004-814661](https://doi.org/10.1055/s-2004-814661), indexed in Pubmed: [14712409](https://pubmed.ncbi.nlm.nih.gov/14712409/).