

# His-bundle injury current and transient accelerated junctional rhythm: clinical and technical considerations

Prąd uszkodzenia pęczka Hisa i czynny rytm węzłowy  
– rozważania kliniczne i techniczne

Adam Ciesielski<sup>1</sup>, Łukasz Grydz<sup>1</sup>, Dariusz Hiczek<sup>1</sup>, Jakub Adamowicz<sup>2,3</sup>,  
Jacek Gajek<sup>2,3</sup>, Agnieszka Sławuta<sup>2</sup>, Jarosław Hiczek<sup>1</sup>

<sup>1</sup>Department of Cardiology, Multidisciplinary Public Hospital, Nowa Sol, Poland

<sup>2</sup>Department of Cardiology, Kłodzko County Hospital, Kłodzko, Poland

<sup>3</sup>Department of Clinical Nursing, Wrocław Medical University, Wrocław, Poland

## Abstract

We present a case of dual chamber cardioverter-defibrillator placement with atrial lead implanted in His-bundle area, resulting in current of injury and accelerated nodal rhythm recorded in pacing system analyzer, rarely seen in clinical practice. Such presentation resulted in excellent pacing and sensing conditions, despite primarily doubtful setting.

Key words: direct His-bundle pacing, His-bundle injury current, His-bundle injury rhythm, heart failure; atrial fibrillation

Folia Cardiologica 2018; 13, 1: 83–85

## Introduction

The active-fixation-lead placement into myocardium results in injury current observed in particular in unipolar local electrogram. This phenomenon is relatively well known as it assures excellent lead-myocardial contact and provides good long-term pacing threshold [1]. Some authors studied the morphology of the injury current in order to predict the follow-up lead performance but it was not proven to be useful [2].

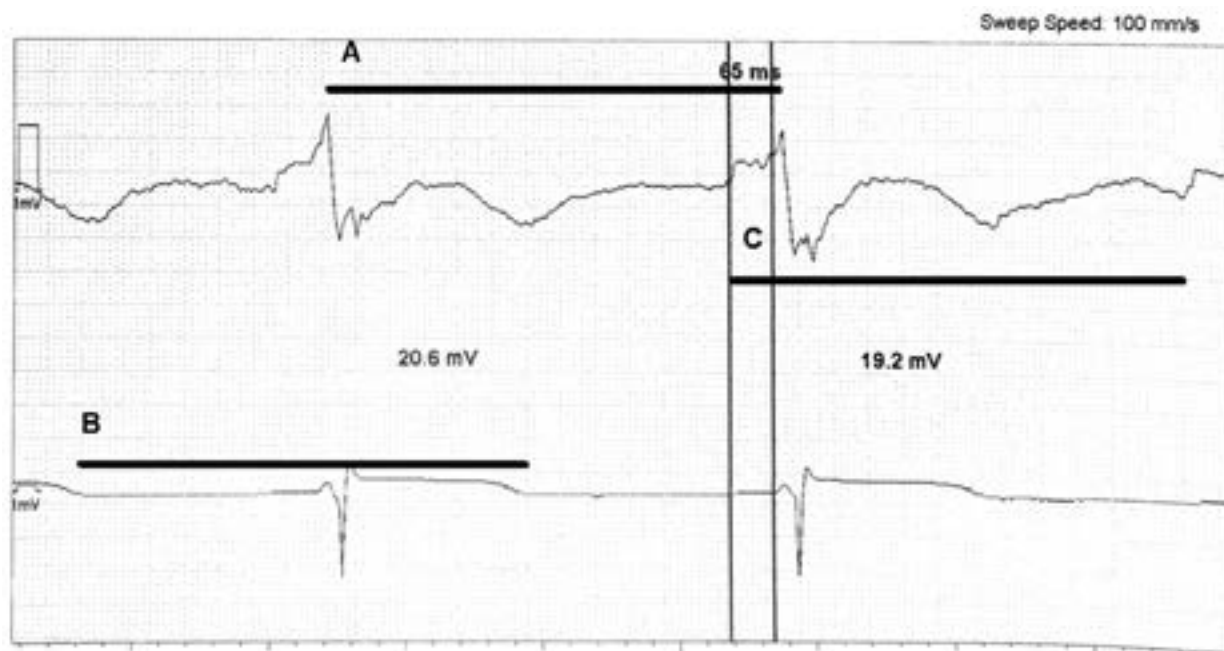
Direct His-bundle pacing gains popularity in various clinical settings. Among patients with narrow QRS complex it preserves the inter- and intraventricular electrical and mechanical synchrony. This advantage can be of particular clinical importance in patients with permanent atrial fibrillation in whom it enables the regularization of the heart rate and contributes to the reverse left ventricle remodeling [3].

In the setting of His-bundle electrode implantation the injury current points a direct hit into bundle fibers and usually indicates relatively low pacing threshold [4]. Current of injury was reported also during implantation of passive leads, which resembled local damage of myocardial cells due to direct impact and pressure, seen as ST-segment elevation. In active fixation systems, screwing in the electrode tip helix resulted in even more overt ECG changes.

## Case description

We present a case of 67-years-old male with chronic slow atrial fibrillation, non-ischemic cardiomyopathy and congestive heart failure undergoing dual chamber cardioverter-defibrillator implantation in primary prevention of sudden cardiac death. During the His-bundle electrode placement we achieved direct bundle involvement with injury current. After lead screw-in we observed the exact regularization

Address for correspondence: lek. Jakub Adamowicz, Oddział Kardiologii, Szpital ZOZ Kłodzko, ul. Szpitalna 1a, 57–300 Kłodzko, Poland, e-mail: [jakubadamow@gmail.com](mailto:jakubadamow@gmail.com)



**Figure 1.** Atrial (His-bundle) and ventricular electrograms from St. Jude Medical Pacing System Analyzer during device implantation. In the upper electrogram His-bundle signal followed by His-bundle injury current and ventricular electrogram are present. HV interval duration is 65 ms. The black segments **A**, **B**, **C** indicate the R-R, T-T and His-His intervals. Note the exactly the same duration of the **A**, **B**, **C** intervals of 650 ms indicating the His-bundle originated rhythm. Paper speed 100 mm/s

of ventricular response rate in form of junctional rhythm which seemed to have some entrance block properties. The high output bipolar pacing (6 V, 1.0 ms) could overcome the block resulting in direct, selective His-bundle pacing. The local unipolar electrogram recorded from His-bundle electrode depicting the His injury current, the rhythm and the constant time intervals of 650 ms were positioned in Figure 1.

After several minutes the elevation after His electrogram started to resolve, the pacing threshold, even if constantly high, was going to be lower (4 V, 0.8 ms) and the rhythm slowed down and finally subsided. Permanent His-bundle pacing threshold was low and stable (1.4 V, 0.5 ms).

## Discussion

Direct His-bundle pacing is a relatively new technique gaining appreciation throughout recent years. Proper lead positioning in His-bundle area requires some technical and clinical experience. As the phenomenon of the injury current was previously well-presented, local bundle injury rhythm was not described so far. And it should not be an exception as in many clinical situations the direct irritation of the excitable tissue can result in electrical response. It is also well known in particular in neurological disorders where the possibility of focal epilepsy results from the pressure of the tumor or other solid structures [5]. Another example

of influencing the cardiac viable tissue is accelerated nodal rhythm. In some procedural circumstances active rhythm precedes permanent harm to some particular elements of cardiac tissue. As an example, during radiofrequency ablation of slow pathway of atrioventricular node a rapid, active nodal rhythm often precedes impairment of compact AV node, a hub that receives stimuli from both fast and slow pathway – resulting in complete AV block [6]. Similarly the accelerated ventricular rhythm with the morphology of the native QRS complex is usually a good predictor of radiofrequency ventricular tachycardia ablation procedure success [7]. In the patient described, despite two signs (current of injury, accelerated rhythm) of damage inflicted to native conduction system, presented setting predicted precise electrode placement.

As in our case the presence of His-bundle injury rhythm resulted in temporary elevation of the pacing threshold this phenomenon is of some technical importance. The coincidence of His-bundle injury current and bundle rhythm in the presence of disturbingly high pacing threshold should not make the operator to incline towards the reposition of the already implanted lead. In fact besides the injury current it is another proof of an excellent lead position which will benefit in follow-up.

## Conflict of interest(s)

Authors declare no conflict of interest.

## Streszczenie

Zaprezentowano przypadek implantacji dwujamowego kardiowertera-defibrylatora z elektrodą przedsionkową lokowaną w okolicy pęczka Hisa, skutkującą prądem uszkodzenia i czynnym rytmem węzłowym, rzadko obserwowanym w praktyce klinicznej. Rezultatem były znakomite parametry stymulacji i czucia, mimo pierwotnie wątpliwej lokalizacji.

Słowa kluczowe: stymulacja pęczka Hisa, prąd uszkodzenia pęczka Hisa, niewydolność serca, migotanie przedsionków

Folia Cardiologica 2018; 13, 1: 83–85

## References

1. Saxonhouse SJ, Conti JB, Curtis AB. Current of injury predicts adequate active lead fixation in permanent pacemaker/defibrillation leads. *J Am Coll Cardiol.* 2005; 45(3): 412–417, doi: [10.1016/j.jacc.2004.10.045](https://doi.org/10.1016/j.jacc.2004.10.045), indexed in Pubmed: [15680721](https://pubmed.ncbi.nlm.nih.gov/15680721/).
2. Oswald H, Husemann B, Gardiwal A, et al. Morphology of current of injury does not predict long term active fixation ICD lead performance. *Indian Pacing Electrophysiol J.* 2009; 9(2): 81–90, indexed in Pubmed: [19308276](https://pubmed.ncbi.nlm.nih.gov/19308276/).
3. Sharma PS, Dandamudi G, Naperkowski A, et al. Permanent His-bundle pacing is feasible, safe, and superior to right ventricular pacing in routine clinical practice. *Heart Rhythm.* 2015; 12(2): 305–312, doi: [10.1016/j.hrthm.2014.10.021](https://doi.org/10.1016/j.hrthm.2014.10.021), indexed in Pubmed: [25446158](https://pubmed.ncbi.nlm.nih.gov/25446158/).
4. Vijayaraman P, Dandamudi G, Worsnick S, et al. Acute His-bundle injury current during permanent His-bundle pacing predicts excellent pacing outcomes. *Pacing Clin Electrophysiol.* 2015; 38(5): 540–546, doi: [10.1111/pace.12571](https://doi.org/10.1111/pace.12571), indexed in Pubmed: [25588497](https://pubmed.ncbi.nlm.nih.gov/25588497/).
5. Lo W, Marchuk DA, Ball KL, et al. Brain Vascular Malformation Consortium National Sturge-Weber Syndrome Workgroup. Updates and future horizons on the understanding, diagnosis, and treatment of Sturge-Weber syndrome brain involvement. *Dev Med Child Neurol.* 2012; 54(3): 214–223, doi: [10.1111/j.1469-8749.2011.04169.x](https://doi.org/10.1111/j.1469-8749.2011.04169.x), indexed in Pubmed: [22191476](https://pubmed.ncbi.nlm.nih.gov/22191476/).
6. Lipscomb KJ, Zaidi AM, Fitzpatrick AP, et al. Slow pathway modification for atrioventricular node re-entrant tachycardia: fast junctional tachycardia predicts adverse prognosis. *Heart.* 2001; 85(1): 44–47, indexed in Pubmed: [11119460](https://pubmed.ncbi.nlm.nih.gov/11119460/).
7. Haqqani HM, Roberts-Thomson KC. Radiofrequency catheter ablation for ventricular tachycardia. *Heart Lung Circ.* 2012; 21(6-7): 402–412, doi: [10.1016/j.hlc.2011.10.015](https://doi.org/10.1016/j.hlc.2011.10.015), indexed in Pubmed: [22237136](https://pubmed.ncbi.nlm.nih.gov/22237136/).