

Successful ablation of incessant epicardial VT guided by limited pace-mapping at open heart surgery A strategy of choice?

Skuteczna ablacja ustawicznego, nasierdziowego częstoskurczu komorowego pod kontrolą ograniczonego mappingu stymulacyjnego w czasie operacji kardiochirurgicznej. Strategia z wyboru?

Radosław Marek Kiedrowicz¹, Maciej Wielusiński¹, Jarosław Kaźmierczak¹,
Małgorzata Peregud-Pogorzelska¹, Mirosław Brykczyński²

¹Department of Cardiology, Pomeranian Medical University, Szczecin, Poland

²Cardiac Surgery Department, Pomeranian Medical University, Szczecin, Poland

Abstract

A patient presented with incessant ventricular tachycardia (VT) of suspected epicardial origin. The earliest activation of the LV apex, however with negative entrainment and pace-mapping was detected. Diagnosis of cardiac tamponade lead to the repair of the right ventricle apex laceration with an epicardial radiofrequency ablation following limited pace-mapping. Ablation lesions covering left ventricle apical segment rendered the patient VT free.

Key words: ventricular tachycardia, cardiac tamponade, epicardial ablation

Folia Cardiologica 2018; 13, 3: 270–273

Case report

A 59-year-old male with prior anterior myocardial infarction (MI), left ventricular (LV) ejection fraction of 35% and electrical storm despite the use of beta-blocker, lignocaine and amiodarone was transferred to our institution. Incessant ventricular tachycardia (VT) of 430 ms cycle length with left superior axis configuration, negative concordance pattern in the precordial leads and QRS duration of 230 ms was registered (Figure 1A). His ECG in sinus rhythm was normal (Figure 1B). The arrhythmia was occasionally terminated with pacing and cardioversion from his implantable cardioverter-defibrillator (ICD), which was immediately restarted afterwards. Although ECG suggested epicardial

VT origin, it was decided to perform an endocardial ventricular mapping before proceeding to an epicardial approach. High-density bipolar voltage map (CARTO[®]3, Biosense Webster Inc.) with a Thermocool[®]SmartTouch[™] catheter introduced into LV through a retrograde approach was acquired initially. Large low-voltage area (LVA) with electrogram amplitude < 1.5 mV limited to the inferobasal wall (29 cm²) and discrete LVA within apical segment of the inferior wall was identified (Figure 2A). An activation map acquired during VT showed the earliest activation of the LV apex, however with entrainment and pace-mapping from multiple endocardial LV sites, not consistent with clinical arrhythmia (Figure 2B). Suspecting that VT exit site could be located within the right ventricle (RV), a voltage,

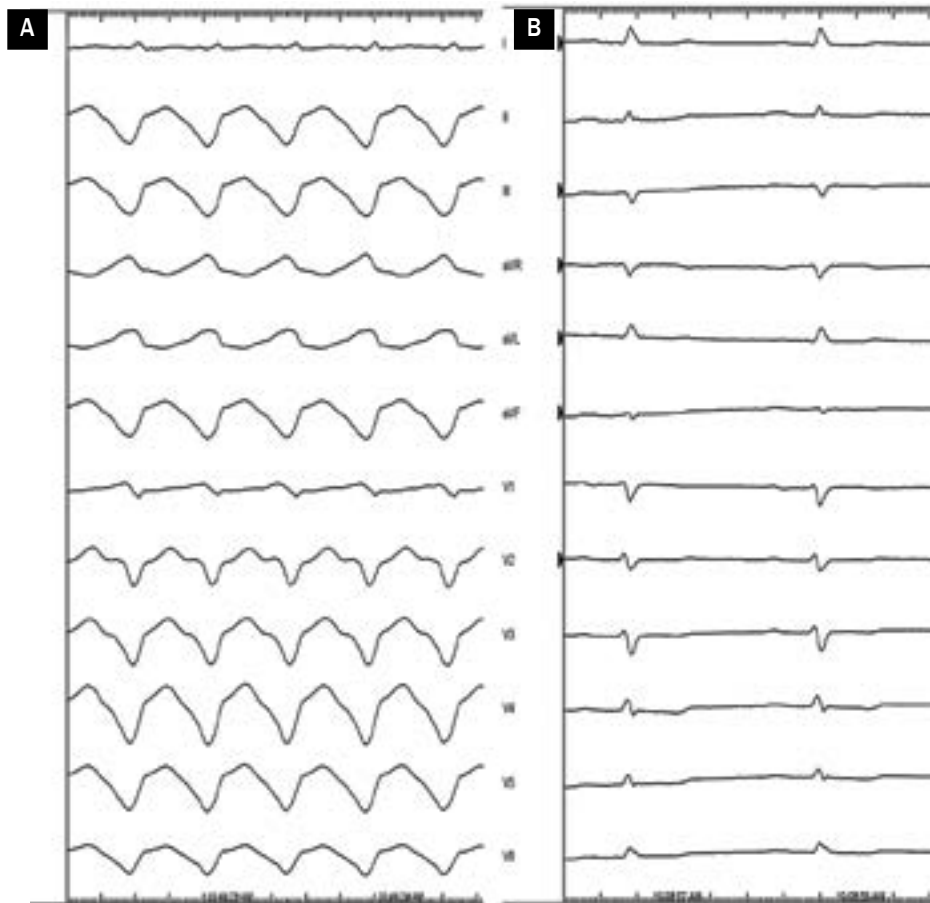


Figure 1A, B. ECG with ventricular tachycardia (VT) of 430 ms cycle length with left superior axis configuration, negative concordance pattern in the precordial leads and QRS duration of 230 ms suggesting epicardial VT origin (A) and normal ECG in sinus rhythm (B) in a patient presenting with electrical storm

activation and pace-mapping of this chamber was further performed. No LVA was identified, an activation map was inconclusive with negative entrainment and pace-mapping for clinical VT (Figure 2). The procedure was abandoned due to a diagnosis of cardiac tamponade. The perforation was clearly attributed to catheter manipulation within the RV apex. Following successful pericardiocentesis, the patient underwent urgent cardiac surgery due to continued bleeding. A repair of the RV apex laceration with sutures was performed without the need for cardiopulmonary bypass, also with a rapid improvement in haemodynamics. At this point, it was decided to perform an epicardial radiofrequency (RF) ablation with a surgical ablation pen (Cardioblade, Medtronic Inc.) following pace-mapping with a bipolar catheter of 15-mm interelectrode distance (Figure 3A), connected to an external temporary pacemaker device, limited to the QRS morphologies in the six limb leads. As the LV apical anterior wall pacing site, but not the RV apical region was concordant with VT morphology,

ablation lesions covering whole LV apical segment was performed (Figure 3B). Despite observing self-terminating VT episodes of different morphologies the following day, it was found the patient then remained free from VT up to the 12-month follow-up.

Discussion

The majority of VTs can be treated by endocardial catheter ablation exclusively [1, 2], however patients with transmural MI are at increased risk of VT recurrence if undergoing an endocardial-only procedure [3]. This is because their arrhythmogenic substrate can only be altered by epicardial ablation [2]. Intrapericardial access is usually obtained through a subxiphoidal puncture. This approach might not be possible in patients with pericardial adhesions caused by prior cardiac surgery. In such cases, a hybrid procedure involving surgical access with a subxiphoid pericardial window and a limited anterior or lateral thoracotomy

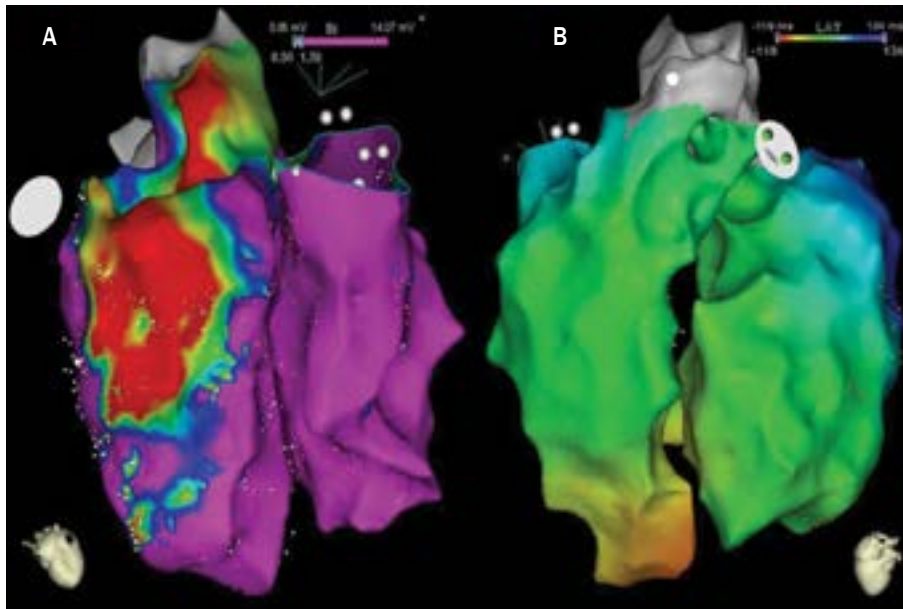


Figure 2A, B. High density bipolar voltage map (CARTO®3, Biosense Webster Inc.) of both left and right ventricle (A) showing large low voltage area < 1.5 mV (blue to red colour palette) limited to the inferobasal wall and discrete area within the apical segment of the inferior wall of the left ventricle (LV) with no low voltage areas (pink colour) within the right ventricle. An activation map (B) acquired during VT showed the earliest activation of the LV apex (reddish colour)

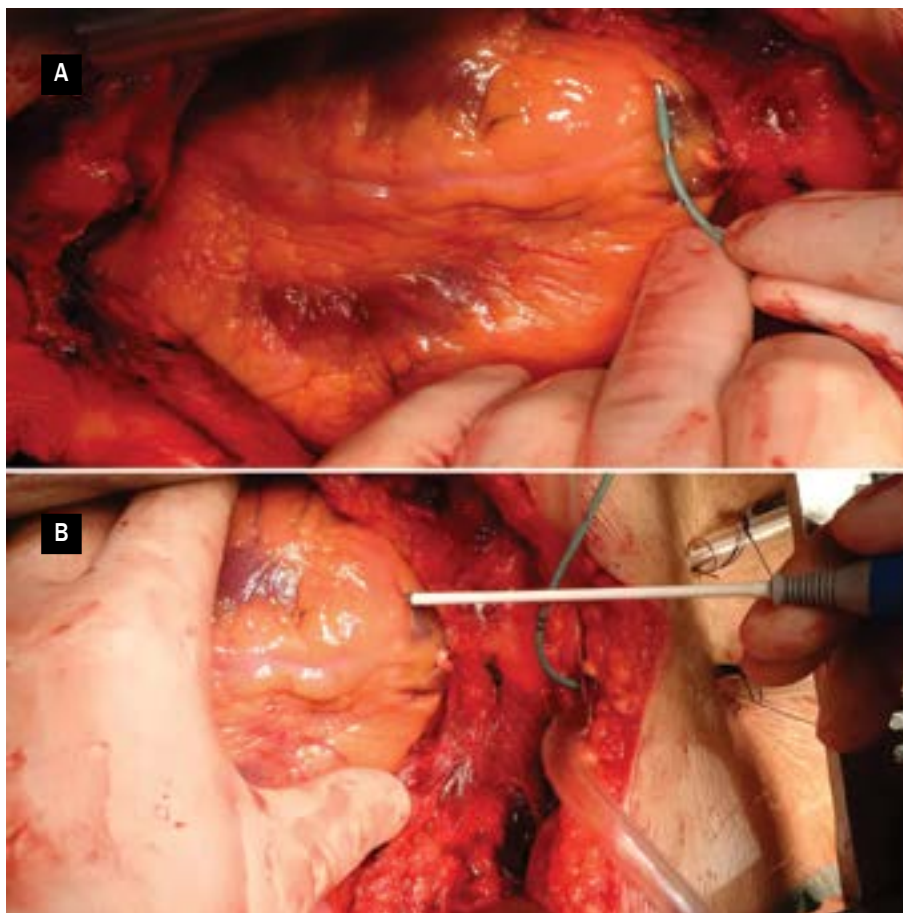


Figure 3A, B. Epicardial radiofrequency ablation of the LV apical anterior wall (B) with a surgical ablation pen (Cardioblate, Medtronic Inc.), followed by pace-mapping (A) with a bipolar catheter of 15-mm interelectrode distance connected to an external temporary pacemaker device

might be a feasible and safe method [4, 5]. There is no need to proceed to a full thoracotomy in order to obtain epicardial access, especially if the precordial leads cannot be assessed whilst applying diagnostic manoeuvres. Moreover, a catheter, but not surgical RF ablation is a golden standard for epicardial VT management. Surgical RF ablation is a more invasive procedure, with very limited data available regarding VT substrate identification and elimination. Consequently, it is not routinely performed in open heart surgery.

The case presented here shows, that an applied approach can be beneficial, however this is associated with some practical limitations and requires an alternative procedural workflow than compared to a conventional catheter based RF ablation.

Conclusion

This case report shows, that epicardial ablation following limited pace-mapping can be successfully employed at the time of cardiac surgery to prevent VT recurrence. In our opinion, this strategy should be applied in every single complicated percutaneous VT ablation case to decrease the possibility of further redo-procedures, especially, that prior chest surgery might limit epicardial access. However, it should be recognised, that surgical epicardial VT ablation in itself is not a strategy of choice for uncomplicated cases.

Conflict of interest(s)

The authors declare no conflict of interest.

Streszczenie

U chorego z ustawicznym częstoskurczem komorowym (VT) podejrzewano nasierdziowe pochodzenie zaburzeń rytmu. Stwierdzono obszar wczesnej aktywacji w okolicy koniuszka lewej komory, jednak z ujemnym rezultatem stymulacji sprzęgania (*entrainment*) i mappingu stymulacyjnego. W związku z rozpoznaniem tamponady serca naprawiono rozdarcie wierzchołka prawej komory, stosując ablację prądem o częstotliwości radiowej pod kontrolą ograniczonego mappingu stymulacyjnego. Blizny po ablacji pokrywające segment koniuszkowy LV spowodowały ustąpienie VT u chorego.

Słowa kluczowe: częstoskurcz komorowy, tamponada serca, ablacja epikardialna

Folia Cardiologica 2018; 13, 3: 270–273

References

1. Tilz RR, Lenarczyk R, Scherr D, et al. Management of ventricular tachycardia in the ablation era: results of the European Heart Rhythm Association Survey. *Europace*. 2018; 20(1): 209–213, doi: [10.1093/europace/eux332](https://doi.org/10.1093/europace/eux332), indexed in Pubmed: [29186419](https://pubmed.ncbi.nlm.nih.gov/29186419/).
2. Yamada T. Catheter ablation of epicardial ventricular tachycardia. *J Arrhythm*. 2014; 30(4): 262–271, doi: [10.1016/j.joa.2014.04.011](https://doi.org/10.1016/j.joa.2014.04.011).
3. Soto-Iglesias D, Acosta J, Penela D, et al. Image-based criteria to identify the presence of epicardial arrhythmogenic substrate in patients with transmural myocardial infarction. *Heart Rhythm*. 2018; 15(6): 814–821, doi: [10.1016/j.hrthm.2018.02.007](https://doi.org/10.1016/j.hrthm.2018.02.007), indexed in Pubmed: [29427821](https://pubmed.ncbi.nlm.nih.gov/29427821/).
4. Li A, Hayase J, Do D, et al. Hybrid surgical vs percutaneous access epicardial ventricular tachycardia ablation. *Heart Rhythm*. 2018; 15(4): 512–519, doi: [10.1016/j.hrthm.2017.11.009](https://doi.org/10.1016/j.hrthm.2017.11.009), indexed in Pubmed: [29132931](https://pubmed.ncbi.nlm.nih.gov/29132931/).
5. Michowitz Y, Mathuria N, Tung R, et al. Hybrid procedures for epicardial catheter ablation of ventricular tachycardia: value of surgical access. *Heart Rhythm*. 2010; 7(11): 1635–1643, doi: [10.1016/j.hrthm.2010.07.009](https://doi.org/10.1016/j.hrthm.2010.07.009), indexed in Pubmed: [20633702](https://pubmed.ncbi.nlm.nih.gov/20633702/).