

Cardiac magnetic resonance imaging for detect intracardiac thrombi

Badanie rezonansu magnetycznego serca
w wykrywaniu skrzeplin wewnątrzsercowych

Narumol Chaosuwannakit, Pattarapong Makarawate

Faculty of Medicine, Khon Kaen University, Khon Kaen, Thailand

Abstract

Introduction. The aim of our study was to compare the diagnostic accuracy achieved using different magnetic resonance (MR) techniques with the diagnostic accuracy achieved using transthoracic and transoesophageal echocardiography to detect intracardiac thrombi.

Materials and methods. Twenty-four patients with known or suspected intracardiac thrombi were examined using MR imaging and echocardiography. All MR examinations were performed on a 1.5-T MR scanner using dark-blood-prepared half-Fourier acquisition single-shot turbo spin-echo (HASTE) sequences, fast imaging steady-state free precession (trueFISP) cine sequences, and inversion recovery gradient-echo fast low-angle shot (inversion recovery turbo FLASH) sequences after injection of 0.2 mmol/kg of gadolinium diethylene triamine pentaacetic acid (myocardial delayed enhancement).

Results. MR imaging and echocardiography revealed 12 thrombi as following: 2 in the right atrium, 1 in the right ventricle, 3 in the left atrium, and 6 in the left ventricle. Compared with echocardiography, MR imaging revealed 3 additional thrombi in the left ventricle; these thrombi were confirmed at surgery. All 15 thrombi appeared as filling defects on early contrast-enhanced inversion recovery turbo FLASH MR images. Only 7 thrombi were detected on HASTE images, and 10 thrombi were seen on trueFISP images. Four thrombi showed enhancement 10–20 min after contrast material injection and were characterised as organised clots.

Conclusions. The contrast-enhanced inversion recovery turbo FLASH sequences (myocardial delayed enhancement) were superior to dark-blood-prepared HASTE and trueFISP cine MR images in revealing intracardiac thrombi. Compared with transthoracic echocardiography, MR imaging was more sensitive for the detection of left ventricular thrombi. The characterisation of thrombi may be used to predict the risk of embolism, which is higher for subacute clots than for organised thrombi.

Key words: cardiac MRI, cardiac thrombi

Folia Cardiologica 2018; 13, 1: 9–14

Introduction

Thrombi of the chambers of the left heart are a common source of stroke and other arterial embolic syndromes.

Thrombi of the right heart are frequently detected in patients with pulmonary embolism [1, 2]. In clinical practice, transthoracic echocardiography is the diagnostic tool of first choice in such patients. However, the inability to visualise

all the cardiac chambers and the reduced image quality in patients who are not well suited for the procedure, are major limitations of transthoracic echocardiography. Therefore, transoesophageal echocardiography has emerged as the most sensitive technique for the detection of intracardiac thrombi and is believed to be the single best test for patients with suspected intracardiac thrombi [3]. However, distinguishing normal myocardium from clots may be difficult on echocardiography, hampering the diagnosis of thin mural thrombi. In addition, because of a lack of diagnostic criteria, differentiating subacute thrombi from organised thrombi on echocardiography – a distinction that is important in predicting the risk of embolic complications – is challenging [4]. Within the last 10 years, magnetic resonance (MR) imaging has emerged as a new noninvasive cardiac imaging technique that can provide complementary information to the data obtained by echocardiography in patients with various cardiac diseases. MR imaging can be considered the first-line imaging technique in patients with congenital heart disease and in those with suspected cardiac tumours. Recently, several new cardiac MR techniques have been introduced to improve spatial and temporal resolution, robustness, and contrast properties [5, 6] of the modality. These rapid technical developments have expanded the indications for cardiac MR imaging. The aim of our study was to evaluate the diagnostic accuracy achieved with different unenhanced and contrast-enhanced MR sequences for the detection of intracardiac thrombi and to compare the results with those achieved using transthoracic and transoesophageal echocardiography.

Materials and methods

After giving informed consent, 24 consecutive patients (17 men and seven women; age range, 23–76 years; mean age \pm standard deviation [SD], 57 ± 14 years), who had been referred to the echocardiography laboratory for evaluation of known or suspected intra-cardiac thrombi were enrolled in our study, which was performed in accordance with regulations set forth by the local institutional review board. The transthoracic echocardiography was performed in all the patients, and transoesophageal echocardiography was performed in 11 of 24 patients with suspected atrial thrombi. Two-dimensional (2D) echocardiographic examinations were performed with state-of-the-art machines using standard views and techniques in accordance with the guidelines of the American Society of Echocardiography. The images were obtained with patients in the left lateral position at the end-expiration by experienced cardiologists.

A 1.5-T scanner (Siemens Medical Solutions, Erlangen, Germany) was used for all MR imaging. The MR imaging protocol included an ECG-triggered dark-blood-prepared half-Fourier acquisition single-shot turbo spin-echo

(HASTE) sequence (TR/TE, 2 heartbeats/60 msec; flip angle, 160°) covering the entire heart in the axial orientation. Thereafter, four-chamber and two-chamber views, as well as contiguous short-axis images of the entire heart were acquired with a fast imaging steady-state free precession (trueFISP) cine sequence (3 msec/1.5 msec; flip angle, 60°). Images in the oblique orientation were obtained to further investigate the suspicious areas. Immediately after the injection of 0.2 mmol/kg of gadolinium diethylene triamine pentaacetic acid (Magnevist; Schering, Berlin, Germany) (flow rate, 2 mL/sec), breath-hold ECG-triggered 2D inversion recovery turbo FLASH images (8/4; flip angle, 25°) of four- and two-chamber views of the heart were acquired. Repeated three-dimensional (3D) inversion recovery turbo FLASH sequences (4/1.4; flip angle, 10°) in the short-axis orientation were then performed. In patients with suspicious findings, additional oblique slices were obtained, using either 2D or 3D inversion recovery turbo FLASH sequence. Images were acquired both immediately after the injection of the contrast material and as long as 15 minutes after the injection (DE-CMR, delayed enhancement cardiac magnetic resonance). Whereas the 2D sequence is a single-slice technique (slice thickness, 8 mm), the 3D sequence can acquire as many as 24 slices with a slice thickness of 4 mm in one breath-hold of reasonable length, using a shorter TR, partial Fourier reconstruction (6/8), z-axis interpolation, and longer data acquisition window, with 77 k-space lines per heartbeat to improve the speed. The total imaging time required, including patient positioning, was 45–60 min. All the MR images were interpreted by an experienced radiologist who was unaware of the diagnosis and of the results of the echocardiographic examinations. The interpretations for the HASTE, trueFISP, conventional DE-CMR and DE-CMR long inversion time were performed separately.

Results

Echocardiography revealed 12 intra-cardiac thrombi. The thrombi were located in the right atrium ($n = 2$), right ventricle ($n = 1$), left atrium ($n = 3$), and left ventricle ($n = 6$). One thrombus in the appendage of the right atrium and two of the thrombi in the left atrium were visualised only on transoesophageal, not on transthoracic, echocardiography. All thrombi seen on echocardiography were detected on MR imaging. Cardiac MR imaging revealed three additional thrombi in the left ventricle not seen on transthoracic echocardiography. None of these three patients had undergone transoesophageal echocardiography. Therefore, cardiac MR imaging revealed 15 thrombi in 24 patients. In seven patients, including three with discrepant findings, the MR imaging diagnosis was confirmed at surgery. The thrombi appeared isointense or slightly hyperintense relative to the myocardium on dark-blood-prepared HASTE images. Both

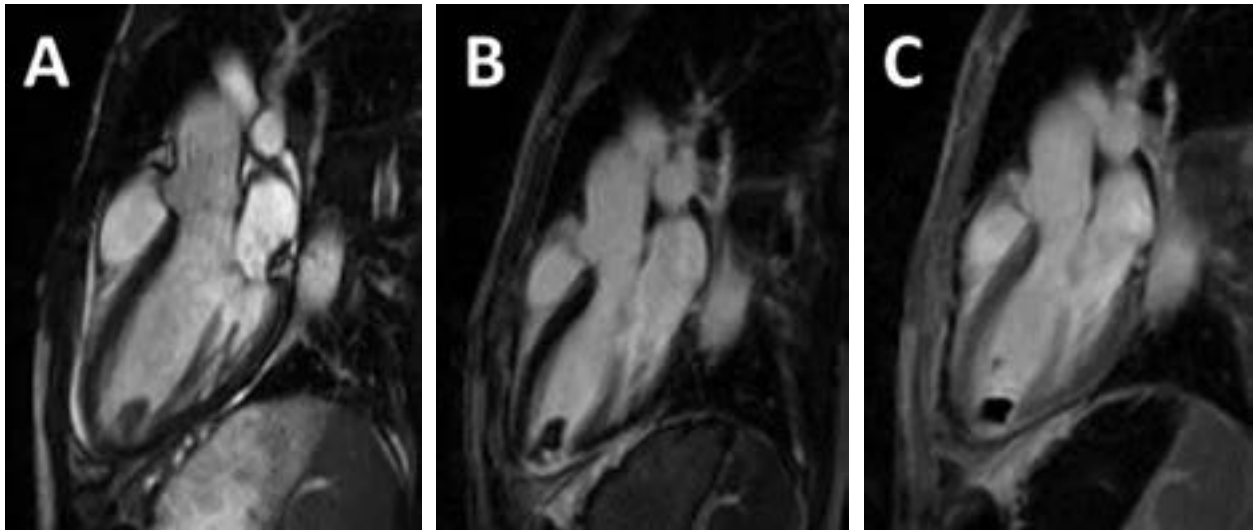


Figure 1A–C. Representative examples of LV thrombus assessment by CMR. Intracavitary thrombus within LV apex (arrow), despite negative transthoracic echocardiography. Note that thrombus appears “etched” on trueFISP SSFP (A) and standard DE-CMR (B; inversion time 250–350 msec) and homogeneously black in a long inversion time (C; inversion time = 600 msec) imaging. The patient surgical resection enabled thrombus verification based on histopathology (not shown)

of the right atrial thrombi, one of the left atrial thrombi, and four of nine left ventricular thrombi were detectable on HASTE images. The other eight thrombi were not visible on HASTE images because of poor contrast between the thrombus and the myocardium, and because of slow-flow artifacts, which hampered the establishment of the correct diagnosis, especially in patients with impaired ventricular function or left ventricular aneurysms. The thrombi showed low signal intensity on trueFISP cine images. Therefore, the differentiation of the myocardium from the thin mural thrombus was not possible on trueFISP images. Both right atrial thrombi, the only right ventricular thrombus, two left atrial thrombi, and five of nine left ventricular thrombi were detectable on trueFISP images. Delineation of thrombi was excellent on both conventional DE-CMR and long inversion time DE-CMR. All thrombi appeared as low signal-intensity filling defects in the cavity and remaining dark signal intensity on long inversion time DE-CMR (Figure 1).

Discussion

The ECG-triggered 3D inversion recovery turbo FLASH sequence provided excellent contrast and high spatial resolution after the administration of an extracellular contrast agent, making this technique the most accurate to use for the detection of intra-cardiac thrombi. The 3D sequence allows full cardiac coverage in a single breath-hold and was shown to be well suited for revealing and characterising the intra-cardiac thrombi. Among the imaging techniques routinely used to visualise the intra-cardiac thrombi, 2D transthoracic echocardiography is the modality of first

choice. The reasons include availability, high accuracy, and low cost. The technique is characterised by sensitivity and specificity values for left ventricular thrombi of approximately 90% compared with aneurysmectomy or autopsy [7]. Several studies have shown transoesophageal echocardiography to be more sensitive for the detection of atrial thrombi than transthoracic echocardiography [3, 8], particularly for the detection of thrombi in the left atrial appendage. However, transoesophageal echocardiography is semi-invasive. The sensitivity of angiocardiology for the detection of intra-cardiac thrombus is unacceptably low, and indium-111 platelet scanning is time-consuming and expensive [7]. The contrast-enhanced CT is more sensitive for ventricular and atrial thrombi than transthoracic echocardiography, but the technique has been shown to be inferior to transoesophageal echocardiography for revealing atrial thrombi [9, 10]. These imaging techniques are of limited use in distinguishing between a thrombus and a cardiac tumour or in characterising a thrombus as acute or subacute. Over the years, cardiac MR imaging with different types of sequences has emerged as a noninvasive alternative for the detection and characterisation of intra-cardiac masses [11–14]. In agreement with the earlier studies, the present study shows that the value of spin-echo and turbo spin-echo MR imaging sequences for revealing intra-cardiac masses is limited by artifacts caused by slow-flowing blood [11, 15]. Because of the high signal intensity inherent to blood, gradient-echo sequences are robust and more sensitive for the detection of intra-cardiac thrombi. The differentiation of a mural thrombus from the myocardium can be challenging, however, recently

developed trueFISP sequence used in the present study improves the contrast between the myocardium and blood [6], but thrombi are isointense relative to the myocardium, so the diagnosis of mural thrombi may be hampered. The intravenous administration of gadolinium diethylene triamine pentaacetic acid with DE-CMR sequence was shown to enhance the contrast between the myocardium and thrombi, thereby improving our ability to detect and characterise the thrombi [4, 14]. DE-CMR is a technique widely used to differentiate between infarcted and viable myocardium, based on relative differences in gadolinium-based contrast uptake and can be used to identify thrombus. Whereas gadolinium-based contrast agents demonstrate uptake within infarcted myocardium, thrombus manifests an absence of gadolinium uptake due to its avascular composition [4]. On DE-CMR, thrombus appears as a low signal intensity mass (attributable to the absence of contrast uptake) surrounded by high signal intensity (*i.e.*, contrast-enhanced) structures, such as cavity blood and/or surrounding myocardium. The absence of contrast enhancement can be used to distinguish thrombus from other masses such as neoplasm, which typically demonstrate contrast uptake due to tumour-associated vascularity. On conventional DE-CMR, which is tailored to null viable myocardium (typical inversion time 200–300 msec), thrombus appears grey or “etched,” viable myocardium black, and infarcted myocardium white. Both, viable myocardium and thrombus, can appear relatively dark and may be difficult to distinguish from one another. DE-CMR can be further tailored for thrombus assessment by prolonging the inversion time (*i.e.*, 600 msec) to selectively null avascular tissue such as thrombus. This so-called “long inversion time” approach produces an image that renders thrombus black and surrounding myocardium bright [4]. The present study suggests that the DE-CMR is optimally suited for imaging cardiac thrombi. Inversion times can be varied to improve the contrast between the thrombi and the myocardium. The signal intensity of myocardial infarctions, which are frequently associated with left ventricular thrombi, increases over time, permitting easy differentiation between the nonviable infarcted tissue and the thrombi. A recently developed ECG-triggered 3D inversion recovery turbo FLASH sequence even allows full cardiac coverage in a single breath-hold and seems ideally suited for the detection of intra-cardiac thrombi. However, the use of ECG triggering is a prerequisite for obtaining high-quality images. Although not present in our study, artifacts may occur in patients with atrial fibrillation or other arrhythmias, which are frequently associated with intra-cardiac thrombi. Intra-cardiac thrombi are associated with a variety of diseases. Functional disorders such as myocardial infarction or atrial fibrillation are a common cause of cardiac thrombi [7, 16]. The frequency of left ventricular thrombi is approximately 30% in patients with an acute or healed myocardial

infarction. Most thrombi develop within the first week after the infarction and are most often noted at the apex of the left ventricle in patients who have had an anterior myocardial infarction [7]. Deep vein thrombosis or the use of central venous catheters may lead to development of thrombi in the right heart, which should be considered pulmonary emboli in transit [1, 17–19]. Chronic anabolic steroid abuse, as well as several disorders and diseases, such as Behçet’s syndrome, coagulopathies, Löffler’s endocarditis, Churg-Strauss syndrome, or right atrial aneurysm should be considered potential causes of intracardiac thrombi [20–24]. In these rare clinical settings, the differentiation between thrombi and cardiac tumours can be challenging [21, 24], and MR imaging may provide additional information to that obtained from echocardiography. The intracardiac thrombi may cause arterial or pulmonary embolisms and should be regarded as life-threatening. It is estimated that in approximately 30% of cases of cerebral infarction, the causative thrombus originated in the heart [2, 3]. Cardiac diseases or abnormalities that may cause arterial emboli include atrial and ventricular thrombosis, cardiac tumours, thrombosis on heart valve prostheses, and endocarditis [8]. The present study indicates that contrast-enhanced MR imaging depicts intracardiac thrombi more accurately than transthoracic echocardiography does and is as sensitive as transoesophageal echocardiography. Cardiac MR imaging is the most accurate imaging modality in patients with suspected cardiac tumours. However, cardiac MR imaging cannot replace echocardiography in patients who have had a cerebral stroke, because endocarditis, thrombosis on heart valve prostheses, and other potential sources of embolism such as patent foramen ovale, valve strands, atrial septum aneurysm, and dystrophy of mitral annulus are difficult to visualise on MR imaging. In patients with a pulmonary embolism, the rare finding of right heart thrombi may be underdiagnosed. The clinical studies using echocardiography and autopsy studies suggest that these thrombi occur in 6–18% of patients with a pulmonary embolism [25–27]. Most of these patients cannot undergo MR imaging, because they present with severe dyspnea or cardiogenic shock [1, 26]. Transoesophageal echocardiography is unquestionably the imaging technique of first choice in such patients. The use of MR imaging should be restricted to clinically stable patients, who have either no symptoms or only minor ones, and in whom potential differential diagnoses, like intra-cardiac tumours and congenital structures such as Chiari’s network or persistent eustachian or thebesian valves cannot be excluded with certainty. In addition, cardiac MR imaging may be combined with pulmonary MR angiography [28] to provide a single test for the pulmonary vasculature and heart in patients with suspected pulmonary embolism. The risk of embolism depends on morphologic parameters that can easily be assessed on echocardiography and MR

imaging. The embolic risk is approximately 50% for mobile or protruding thrombi compared with an embolic risk of approximately 10% for non-mobile or flat thrombi [7]. The MR imaging can distinguish subacute clots, which do not enhance after the contrast material injection from the organised thrombi [4]. Four of the 15 thrombi in the present study showed significant enhancement and could be considered organised clots. Such characterisation provides more information than echocardiography does and may be of great clinical interest, because embolic complications are more likely to occur with subacute clots than with organised thrombi.

Conclusions

Echocardiography remains the imaging modality of choice in patients with suspected intracardiac thrombi. However, the present study shows that ECG-triggered contrast-enhanced cardiac MR imaging is emerging as an accurate noninvasive alternative technique for the detection and characterisation of intracardiac thrombi.

Conflict of interest(s)

None.

Streszczenie

Wstęp. Celem pracy było porównanie dokładności diagnostycznej różnych technik badania rezonansu magnetycznego (MRI) z dokładnością diagnostyczną echokardiografii przezklatkowej i przezprzełykowej w wykrywaniu skrzeplin wewnątrzsercowych.

Materiały i metody. Dwudziestu czterech chorych, u których potwierdzono lub podejrzewano skrzeplinę wewnątrzsercową, poddano badaniom metodami MRI i echokardiografii. Wszystkie badania MRI przeprowadzono za pomocą skanera MR 1,5 T, stosując następujące techniki: szybkie zmodyfikowane sekwencje echa spinowego, tak zwane sekwencje czarnej krwi – HASTE (*half-Fourier acquisition single-shot turbo spin-echo*); szybkie sekwencje filmowe (*cine*) trueFISP (*fast imaging steady-state free precession*) oraz sekwencje echa gradientowego typu FLAH (*fast low-angle shot*) z impulsem inwersyjnym po wstrzyknięciu 0,2 mmol/kg mc. kontrastu gadolin–kwas dietylenotriaminopentaoctowy (opóźnione wzmocnienie kontrastowe miokardium).

Wyniki. Obecność 12 skrzeplin ujawniono zarówno w badaniach MRI, jak i echokardiograficznych: 2 w prawym przedsionku, 1 w prawej komorze, 3 w lewym przedsionku i 6 w lewej komorze. W porównaniu z echokardiografią badania MRI pozwoliły uwidocznić 3 dodatkowe skrzepliny w lewej komorze. Obecność tych skrzeplin potwierdzono w trakcie zabiegu chirurgicznego. Wszystkie 15 skrzeplin było widocznych jako defekt napętniania komory na obrazach wczesnej fazy wzmocnienia kontrastowego sekwencji turbo FLASH z impulsem inwersyjnym. Na obrazach wykonanych techniką HASTE widocznych było tylko 7 skrzeplin, a na obrazach wykonanych techniką trueFISP – 10 skrzeplin. W przypadku 4 skrzeplin stwierdzono wzmocnienie kontrastowe 10–20 min po podaniu środka kontrastowego i scharakteryzowano je jako skrzepliny zorganizowane.

Wnioski. Sekwencje turbo FLASH z impulsem inwersyjnym (opóźnione wzmocnienie kontrastowe miokardium) były bardziej skuteczne w uwidocznianiu skrzeplin wewnątrzsercowych niż obrazy uzyskane techniką ciemnej krwi HASTE i sekwencje *cine* trueFISP. Badania MRI cechowały się większą czułością w wykrywaniu skrzeplin umiejscowionych w lewej komorze serca. Scharakteryzowanie cech skrzepliny może być przydatne w predykcji ryzyka zatoru, które jest wyższe w przypadku skrzeplin podostrych niż skrzeplin zorganizowanych.

Słowa kluczowe: MRI serca, skrzeplina w sercu

Folia Cardiologica 2018; 13, 1: 9–14

References

- Chartier L, Béra J, Delomez M, et al. Free-floating thrombi in the right heart: diagnosis, management, and prognostic indexes in 38 consecutive patients. *Circulation*. 1999; 99(21): 2779–2783, doi: [10.1161/01.cir.99.21.2779](https://doi.org/10.1161/01.cir.99.21.2779), indexed in Pubmed: [10351972](https://pubmed.ncbi.nlm.nih.gov/10351972/).
- Bogousslavsky J, Van Melle G, Regli F. The Lausanne Stroke Registry: analysis of 1,000 consecutive patients with first stroke. *Stroke*. 1988; 19(9): 1083–1092, doi: [10.1161/01.str.19.9.1083](https://doi.org/10.1161/01.str.19.9.1083), indexed in Pubmed: [3413804](https://pubmed.ncbi.nlm.nih.gov/3413804/).
- Daniel WG, Mügge A. Transesophageal echocardiography. *N Engl J Med*. 1995; 332(19): 1268–1279, doi: [10.1056/NEJM199505113321906](https://doi.org/10.1056/NEJM199505113321906), indexed in Pubmed: [7708072](https://pubmed.ncbi.nlm.nih.gov/7708072/).
- Shah DJ, Judd RM, Kim J. Myocardial viability. In: Edelman RR, Hesselink JR, Zlatkin M, Cruess JV. ed. *Clinical magnetic resonance imaging*, 3rd edition. Elsevier, New York 2006: 1030–1049.
- Simonetti OP, Kim RJ, Fieno DS, et al. An improved MR imaging technique for the visualization of myocardial infarction. *Radiology*.

- 2001; 218(1): 215–223, doi: [10.1148/radiology.218.1.r01ja50215](https://doi.org/10.1148/radiology.218.1.r01ja50215), indexed in Pubmed: [11152805](https://pubmed.ncbi.nlm.nih.gov/11152805/).
6. Barkhausen J, Ruehm SG, Goyen M, et al. MR evaluation of ventricular function: true fast imaging with steady-state precession versus fast low-angle shot cine MR imaging: feasibility study. *Radiology*. 2001; 219(1): 264–269, doi: [10.1148/radiology.219.1.r01ap12264](https://doi.org/10.1148/radiology.219.1.r01ap12264), indexed in Pubmed: [11274568](https://pubmed.ncbi.nlm.nih.gov/11274568/).
 7. Delewi R, Zijlstra F, Piek JJ. Left ventricular thrombus formation after acute myocardial infarction. *Heart*. 2012; 98(23): 1743–1749, doi: [10.1136/heartjnl-2012-301962](https://doi.org/10.1136/heartjnl-2012-301962), indexed in Pubmed: [23151669](https://pubmed.ncbi.nlm.nih.gov/23151669/).
 8. Palazzuoli A, Ricci D, Lenzi C, et al. Transesophageal echocardiography for identifying potential cardiac sources of embolism in patients with stroke. *Neuro Sci*. 2000; 21(4): 195–202, doi: [10.1007/s100720070076](https://doi.org/10.1007/s100720070076), indexed in Pubmed: [11214657](https://pubmed.ncbi.nlm.nih.gov/11214657/).
 9. Kitayama H, Kiuchi K, Endo T, et al. Value of cardiac ultrafast computed tomography for detecting right atrial thrombi in chronic atrial fibrillation. *Am J Cardiol*. 1997; 79(9): 1292–1295, doi: [10.1016/s0002-9149\(97\)00107-0](https://doi.org/10.1016/s0002-9149(97)00107-0), indexed in Pubmed: [9164911](https://pubmed.ncbi.nlm.nih.gov/9164911/).
 10. Barkhausen J, Hunold P, Eggebrecht H, et al. Detection and characterization of intracardiac thrombi on MR imaging. *AJR Am J Roentgenol*. 2002; 179(6): 1539–1544, doi: [10.2214/ajr.179.6.1791539](https://doi.org/10.2214/ajr.179.6.1791539), indexed in Pubmed: [12438051](https://pubmed.ncbi.nlm.nih.gov/12438051/).
 11. Jungehülsing M, Sechtem U, Theissen P, et al. Left ventricular thrombi: evaluation with spin-echo and gradient-echo MR imaging. *Radiology*. 1992; 182(1): 225–229, doi: [10.1148/radiology.182.1.1727287](https://doi.org/10.1148/radiology.182.1.1727287), indexed in Pubmed: [1727287](https://pubmed.ncbi.nlm.nih.gov/1727287/).
 12. Sparrow PJ, Kurian JB, Jones TR, et al. MR imaging of cardiac tumors. *Radiographics*. 2005; 25(5): 1255–1276, doi: [10.1148/rg.255045721](https://doi.org/10.1148/rg.255045721), indexed in Pubmed: [16160110](https://pubmed.ncbi.nlm.nih.gov/16160110/).
 13. Buckley O, Madan R, Kwong R, et al. Cardiac masses, part 1: imaging strategies and technical considerations. *AJR Am J Roentgenol*. 2011; 197(5): W837–W841, doi: [10.2214/AJR.10.7260](https://doi.org/10.2214/AJR.10.7260), indexed in Pubmed: [22021530](https://pubmed.ncbi.nlm.nih.gov/22021530/).
 14. Mousseaux E, Hernigou A, Azencot M, et al. Evaluation by electron beam computed tomography of intracardiac masses suspected by transoesophageal echocardiography. *Heart*. 1996; 76(3): 256–263, indexed in Pubmed: [8868986](https://pubmed.ncbi.nlm.nih.gov/8868986/).
 15. Raggi P, Daniels M, Shanoudy H, et al. MRI misinterpretation of spontaneous echo-contrast as a large left atrial thrombus. *Int J Card Imaging*. 1996; 12(2): 85–88, doi: [10.1007/bf01880738](https://doi.org/10.1007/bf01880738), indexed in Pubmed: [8864786](https://pubmed.ncbi.nlm.nih.gov/8864786/).
 16. Giardina EG. Atrial fibrillation and stroke: elucidating a newly discovered risk factor. *Am J Cardiol*. 1997; 80(4C): 11D–18D; discussion 35D, indexed in Pubmed: [9284039](https://pubmed.ncbi.nlm.nih.gov/9284039/).
 17. Kingdon EJ, Holt SG, Davar J, et al. Atrial thrombus and central venous dialysis catheters. *Am J Kidney Dis*. 2001; 38(3): 631–639, doi: [10.1053/ajkd.2001.26898](https://doi.org/10.1053/ajkd.2001.26898), indexed in Pubmed: [11532697](https://pubmed.ncbi.nlm.nih.gov/11532697/).
 18. Sabzi F, Nasiri B. Myxoma of the superior vena cava origin presented as a right atrial mass. *J Tehran Heart Cent*. 2013; 8(4): 202–204, indexed in Pubmed: [26005489](https://pubmed.ncbi.nlm.nih.gov/26005489/).
 19. Farfel Z, Shechter M, Vered Z, et al. Review of echocardiographically diagnosed right heart entrapment of pulmonary emboli-in-transit with emphasis on management. *Am Heart J*. 1987; 113(1): 171–178, indexed in Pubmed: [3541555](https://pubmed.ncbi.nlm.nih.gov/3541555/).
 20. Staubach P. [Large right atrial aneurysm: rare cause of recurrent pulmonary embolism]. *Z Kardiol*. 1998; 87(11): 894–899, indexed in Pubmed: [9885183](https://pubmed.ncbi.nlm.nih.gov/9885183/).
 21. Schwab J, Schwab M, Manger K, et al. [Churg-Strauss syndrome with right ventricular tumor]. *Dtsch Med Wochenschr*. 1998; 123(16): 487–492, doi: [10.1055/s-2007-1023999](https://doi.org/10.1055/s-2007-1023999), indexed in Pubmed: [9589022](https://pubmed.ncbi.nlm.nih.gov/9589022/).
 22. Mogulkoc N, Burgess MI, Bishop PW. Intracardiac thrombus in Behçet's disease: a systematic review. *Chest*. 2000; 118(2): 479–487, doi: [10.1378/chest.118.2.479](https://doi.org/10.1378/chest.118.2.479), indexed in Pubmed: [10936144](https://pubmed.ncbi.nlm.nih.gov/10936144/).
 23. McCarthy K, Tang AT, Dalrymple-Hay MJ, et al. Ventricular thrombosis and systemic embolism in bodybuilders: etiology and management. *Ann Thorac Surg*. 2000; 70(2): 658–660, doi: [10.1016/s0003-4975\(00\)01572-1](https://doi.org/10.1016/s0003-4975(00)01572-1), indexed in Pubmed: [10969698](https://pubmed.ncbi.nlm.nih.gov/10969698/).
 24. De Cock C, Lemaitre J, Deuvaert FE. Loeffler endomyocarditis: a clinical presentation as right ventricular tumor. *J Heart Valve Dis*. 1998; 7(6): 668–671, indexed in Pubmed: [9870201](https://pubmed.ncbi.nlm.nih.gov/9870201/).
 25. Schlotterbeck K, Schmid J, Bosse O, et al. [Experiences in the diagnosis and therapy of so-called thrombus in transit]. *Z Kardiol*. 1999; 88(11): 932–940, indexed in Pubmed: [10643061](https://pubmed.ncbi.nlm.nih.gov/10643061/).
 26. Casazza F, Bongarzone A, Centonze F, et al. Prevalence and prognostic significance of right-sided cardiac mobile thrombi in acute massive pulmonary embolism. *Am J Cardiol*. 1997; 79(10): 1433–1435, doi: [10.1016/s0002-9149\(97\)00162-8](https://doi.org/10.1016/s0002-9149(97)00162-8), indexed in Pubmed: [9165180](https://pubmed.ncbi.nlm.nih.gov/9165180/).
 27. Chapoutot L, Nazeyrollas P, Metz D, et al. Floating right heart thrombi and pulmonary embolism: diagnosis, outcome and therapeutic management. *Cardiology*. 1996; 87(2): 169–174, doi: [10.1159/000177081](https://doi.org/10.1159/000177081), indexed in Pubmed: [8653735](https://pubmed.ncbi.nlm.nih.gov/8653735/).
 28. Goyen M, Laub G, Ladd ME, et al. Dynamic 3D MR angiography of the pulmonary arteries in under four seconds. *J Magn Reson Imaging*. 2001; 13(3): 372–377, doi: [10.1002/jmri.1053](https://doi.org/10.1002/jmri.1053), indexed in Pubmed: [11241809](https://pubmed.ncbi.nlm.nih.gov/11241809/).