

Diuretic-induced hyperuricemia presenting as malignant gout in a 19 year-old male with moderate rheumatic mitral stenosis

Hiperurykemia wywołana stosowaniem diuretyku objawiająca się jako ostra dna moczanowa u 19-letniego chorego z umiarkowanym reumatycznym zwężeniem zastawki dwudzielnej

Santosh Kumar Sinha, Vinay Krishna, Abhishekh Aggarwal,
Kumar Himanshu, Lokendra Rekwaal

Department of Cardiology, LPS Institute of Cardiology, G.S.V.M. Medical College, Kanpur, India

Abstract

Gout, an inflammatory arthritis, is caused by an accumulation of monosodium urate crystals in the joints and soft tissues when serum uric acid concentrations rise above the physiological saturation limit (≥ 6.4 mg/dL).

Here, we report the case of a 19 year-old male who presented with gradually progressive, nontender swelling of multiple joints of the upper and lower limbs of eight months' duration. He had been receiving frusemide 40 mg, spirinolactone 50 mg, metoprolol 50 mg, and erythromycin 250 mg twice daily for the previous 12 months on account of rheumatic mitral stenosis (moderate). Though a histological diagnosis of gout is the gold standard, in our case we diagnosed frusemide-induced secondary gout with malignant course. This was based on a combination of an imaging tool (radiology showing well defined, 'punched-out' erosions with overhanging edges), and clinical presentation (soft tissue nodules, *i.e.* *tophi*, calcification of *tophi*, and asymmetric involvement). Frusemide was stopped, allopurinol and other urate lowering agent were started which led to regression of his swelling.

Key words: diuretic, monosodium urate, malignant gout, rheumatic mitral stenosis, *tophi*

Folia Cardiologica 2019; 14, 4: 401–403

A 19 year-old male presented with swelling of multiple joints of the upper and lower limbs. On detailed evaluation, he had been diagnosed one year previously with rheumatic moderate mitral stenosis. He had been receiving frusemide – 40 mg, spironolactone – 50 mg, metoprolol – 50 mg, and erythromycin – 250 mg twice daily for the past year. As he was minimally symptomatic,

he was lost to follow up. Once he noticed a swelling which was gradually progressive, and non-tender, he attended the clinic for evaluation. During this evaluation, he was diagnosed with secondary gout that was frusemide induced. The drug was stopped, and allopurinol, a urate-lowering agent, was started. On follow-up, his swelling had started regressing.

Address for correspondence: Santosh Kumar Sinha MD, FAESC, Asst. Professor, Department of Cardiology, LPS Institute of Cardiology, G.S.V.M. Medical College, G.T. Road, Kanpur, Uttar Pradesh 208002, India, fax +91 0512 255 61 99/255 65 21, e-mail: fionasan@rediffmail.com

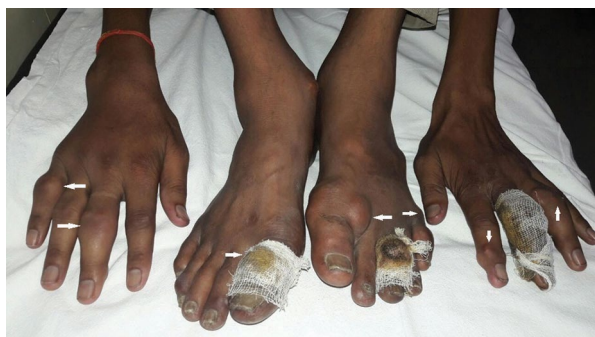

Figure 1. Photograph of both feet and hands showing joint swelling and *tophi* (white arrows)

Gout, an inflammatory arthritis, is caused by an accumulation of monosodium urate crystals (MSU) in the joints and soft tissues when serum uric acid concentrations rise above the physiological saturation limit (≥ 6.4 mg/dL) [1]. Imaging tools and clinical presentation together help in establishing the diagnosis in the absence of a histological diagnosis, and also in assessing the burden of disease.

The acute form of gout is characterised by the sudden onset of intense pain, swelling, warmth and erythema of multiple joints. The big toe is characteristically affected, however almost all joints may be affected. During an acute phase of gout, soft tissue swelling and effusions may be

seen by conventional radiography, however these findings are nonspecific.

Chronic tophaceous gout results from chronic hyperuricemia. Continued deposition of MSU crystals leads to increased frequency of acute attacks, progressive shortening of intercritical phase, and the development of *tophi* due to crystal deposition in soft tissues, bones and joints. The typical radiological findings in chronic tophaceous gout, which differentiate it from other inflammatory arthritides, include well defined, 'punched-out' erosions with overhanging edges, soft tissue nodules (*tophi*), calcification of *tophi* and asymmetric involvement [2] (Figure 1). Radiographic damage is virtually always present in patients with subcutaneous *tophi*. The erosions are typically extra-articular, but may be intra-articular or para-articular. The joint space is usually preserved until late in the disease and there is a lack of periarticular osteopenia. The site most commonly affected is the first metatarsophalangeal (MTP) joint, followed by the fifth MTP joint, mid-foot, hand, and wrist (Figures 2, 3).

The gold standard for the diagnosis of gout is the demonstration of negatively birefringent, needle-shaped MSU crystals in tissue or synovial fluid under a polarising microscope. Obtaining a histological diagnosis is not always feasible, and whilst the application of international consensus definitions may assist in the diagnosis of gout in the absence of a crystal diagnosis, at times a definitive clinical diagnosis can be difficult [3]. These radiological

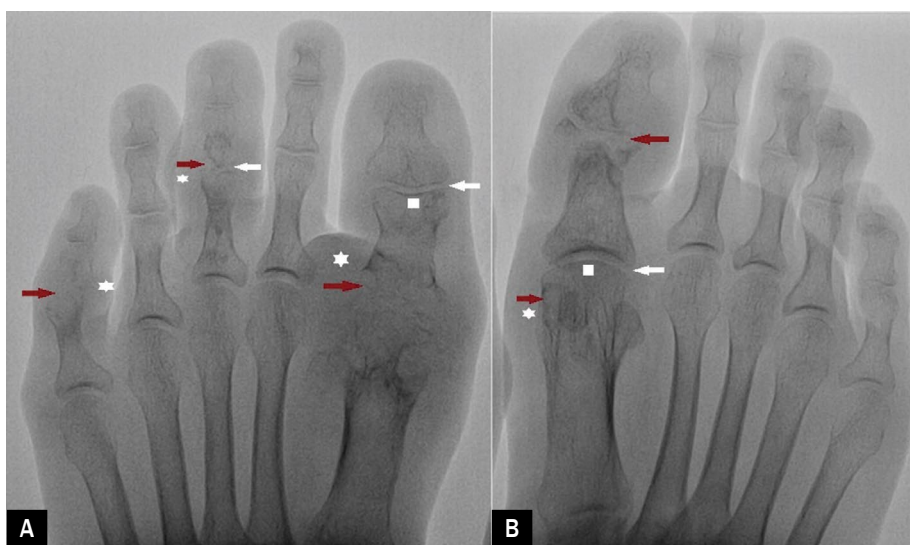


Figure 2A, B. Fluoroscope in anteroposterior (AP) view of the feet where multiple punched out juxta-articular erosions with overhanging edge (red arrow) with the relatively preserved joint space (white arrow) are visible in the first metatarsophalangeal (MTP) and interphalangeal joints. Also visible is subchondral bone density (white square) involving the 1st MTP and interphalangeal joints. Multiple soft tissue *tophi* are also visible (white asterix)

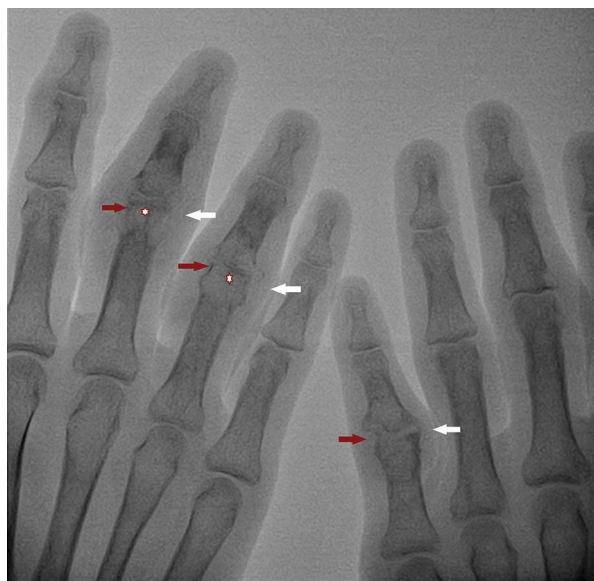


Figure 3. Fluoroscope in anteroposterior (AP) view of both hands showing subchondral deposition (white asterix), and associated erosive changes appearing as multiple punched out lesions (red arrows). Multiple soft tissue *tophi* are also visible (white arrows)

changes are fairly diagnostic, having a specificity of 93% using clinical diagnosis as the gold standard [4]. Such radiographic changes are usually delayed, but in our case they became apparent within nine months. Therefore, the lag until the development of radiographic changes limits its role in the diagnosis or monitoring of this disease [2].

The proximal tubule is the major site of urate handling; both secretion and reabsorption occur in this segment, with the net effect being reabsorption of most of the filtered urate. Hyperuricemia is a relatively common finding in patients treated with a loop or thiazide diuretic and may, over time, contribute to new-onset gouty arthritis or, more promptly, the recurrence of established gout. Loop and thiazide diuretics decrease urate excretion by increasing net urate reabsorption. Asymptomatic hyperuricemia does not require any treatment. In diuretic-induced gout where the patient is symptomatic, a urate-lowering drug such as allopurinol should be started.

Conflict(s) of interest

The authors report no conflict of interest.

Streszczenie

Zapalenie stawów w przebiegu dny moczanowej jest spowodowane akumulacją kryształów moczanu monosodowego w stawach i tkankach miękkich, gdy stężenie kwasu moczowego w surowicy wzrasta powyżej granicy nasycenia fizjologicznego ($\geq 6,4$ mg/dl).

W niniejszej pracy opisano przypadek 19-letniego mężczyzny, u którego przez ostatnie 8 miesięcy występował stopniowo postępujący, niebolesny obrzęk wielu stawów kończyn górnej i dolnej. Przez ostatni rok chory stosował furosemid w dawce 40 mg, spironolakton w dawce 50 mg, metoprolol w dawce 50 mg i erytromycynę w dawce 250 mg 2 razy/dobę w ramach leczenia reumatycznego (umiarkowanego) zwężenia zastawki dwudzielnej. Choć „złotym standardem” w diagnostyce dny jest potwierdzenie rozpoznania w badaniu histologicznym, to w przedstawionym przypadku – na podstawie połączenia danych z badań obrazowych (ostro obrysowane nadżerki z wystającymi krawędziami w badaniu radiologicznym) z obrazem klinicznym (guzki dnawe w tkankach miękkich [łac. *tophi*], zwapnienie i asymetryczne zajęcie stawów) ustalono, że furosemid wywołał wtórną dnę moczanową o złośliwym przebiegu. Po odstawieniu furosemidu i zastosowaniu allopurinolu i środka urykozurycznego obrzęki ustąpiły.

Słowa kluczowe: diuretyk, moczan monosodowy, ostra dna moczanowa, reumatyczne zwężenie zastawki dwudzielnej, guzki

Folia Cardiologica 2019; 14, 4: 401–403

References

1. Choi HK, Mount DB, Reginato AM, et al. American College of Physicians, American Physiological Society. Pathogenesis of gout. *Ann Intern Med.* 2005; 143(7): 499–516, doi: [10.7326/0003-4819-143-7-200510040-00009](https://doi.org/10.7326/0003-4819-143-7-200510040-00009), indexed in Pubmed: [16204163](https://pubmed.ncbi.nlm.nih.gov/16204163/).
2. Gentili A. The advanced imaging of gouty tophi. *Curr Rheumatol Rep.* 2006; 8(3): 231–235, indexed in Pubmed: [16901082](https://pubmed.ncbi.nlm.nih.gov/16901082/).
3. Zhang W. EULAR evidence based recommendations for gout. Part I: Diagnosis. Report of a task force of the standing committee for international clinical studies including therapeutics (ESCSIT). *Ann Rheum Dis.* 2006; 65(10): 1301–1311, doi: [10.1136/ard.2006.055251](https://doi.org/10.1136/ard.2006.055251).
4. Rettenbacher T, Ennemoser S, Weirich H, et al. Diagnostic imaging of gout: comparison of high-resolution US versus conventional X-ray. *Eur Radiol.* 2008; 18(3): 621–630, doi: [10.1007/s00330-007-0802-z](https://doi.org/10.1007/s00330-007-0802-z), indexed in Pubmed: [17994238](https://pubmed.ncbi.nlm.nih.gov/17994238/).