

# Chronic reversible post-rheumatic fever: Jaccoud's arthropathy in a 21 year-old male

Przewlekła poreumatyczna artropatia – zespół Jaccouda u 21-letniego chorego

Santosh Kumar Sinha, Dibbendhu Khanra, Lokendra Rekwai, Puneet Aggarwal,  
Nishant Kumar Abhishekh, Ramesh Thakur

Department of Cardiology, LPS Institute of Cardiology, G.S.V.M. Medical College, Kanpur, India

## Abstract

Jaccoud's arthropathy (JA) is a condition characterised clinically by 'reversible' joint deformities resulting from soft tissue abnormalities, rather than the destruction of bone joints. Although rare, it has been described in patients with chronic rheumatic heart disease. It typically involves metacarpophalangeal and metatarsophalangeal joints. JA has also been described in systemic lupus erythematosus (SLE), infections and neoplasia. Here, we report the case of a 21 year-old male who had presented with a 16-year history of polyarthralgia, deformities of the hands for the last four years, and a three-year history of exertional palpitation and dyspnoea. Physical examination revealed peripheral signs of aortic run off, with hyperdynamic left ventricle and chronic severe aortic and mitral regurgitation. On examination, gross deformities were noted in both hands in the form of ulnar deviation, swan neck, and 'z'-thumb, involving interphalangeal joints, metacarpophalangeal and first carpometacarpal joints which were partially correctable. Laboratory investigations ruled out rheumatoid arthritis, SLE, and acute rheumatic fever. Chest X-ray, electrocardiogram and two-dimensional echocardiography and Doppler study were consistent with chronic severe aortic regurgitation and severe mitral regurgitation. Radiographs of both hands showed posterior subluxation of the carpometacarpal joints, which were completely correctable. JA involving a carpometacarpal joint is exceedingly rare.

Key words: Jaccoud's arthropathy, rheumatic heart disease, metacarpophalangeal joints, carpometacarpal joints, swan neck deformity

Folia Cardiologica 2018; 13, 6: 561–564

## Introduction

Bywaters introduced Jaccoud's arthropathy (JA) into the English medical literature in 1950. It was first reported by FS Jaccoud in 1869 in a patient who had suffered several attacks of rheumatic fever (RF). It has also been described in connective tissue disorders, such as systemic lupus erythematosus (SLE), rheumatoid arthritis, Sjögren's syndrome, scleroderma, dermatomyositis, mixed conjunctive tissue disease, infections such as borreliosis, human immunodeficiency virus (HIV) infection, and in neoplasia such as angioimmunoblastic lymphadenopathy

[1]. The deformities seen in JA are secondary to soft tissue abnormalities which include laxity of ligaments and joint capsules, with distension and secondary deviation of the tendon from its axis, which can lead to muscular imbalance. As articular inflammation is mild therefore, synovitis is not a prominent feature [1].

## Case report

A 21 year-old male presented with complaints of exertional palpitation and fatigability of three years' duration. He was New York Heart Association (NYHA) functional class III and

Address for correspondence: Santosh Kumar Sinha MD, FAESC, Asst. Professor, Department of Cardiology, LPS Institute of Cardiology, G.S.V.M. Medical College, G.T. Road, Kanpur, Uttar Pradesh 208002, India, fax +91 0512 255 61 99/255 65 21, e-mail: fionasan@rediffmail.com

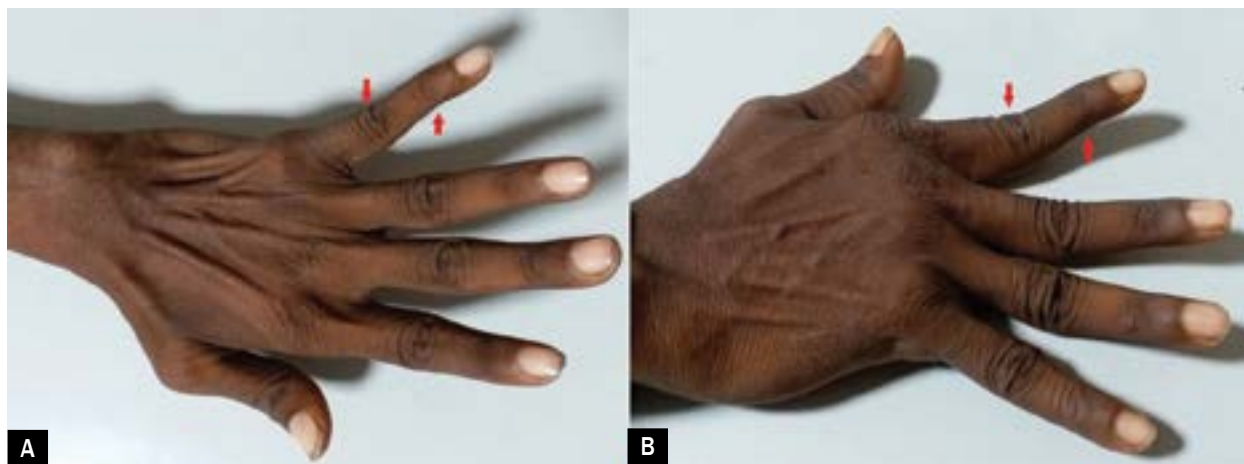


Figure 1A, B. Swan neck deformity in Jaccoud's arthropathy of both hands (red arrow)

had had deformity of both hands for four years. His parents revealed a history of fever and polyarthralgia for the past 16 years. He had started sensing palpitations when he began attending his school, and had suffered with fatigability for the past three years. Blood pressure was 110/60 and 150/50 mm Hg in upper and lower limbs respectively. Pulse rate was 68/minute, regular, high volume with bisferiens character with no radio-radial or radio-femoral delay. Jugular venous pressure was normal in height and character. The apex was situated in the 6<sup>th</sup> left intercostal space, 2 cm lateral to midclavicular line with hyperdynamic character. Systolic thrill was felt at apex. S1 was soft, S2 was wide with a variable split, and S3 was audible at apex. There was loud, long, early diastolic murmur at neoaortic area and blowing, high pitch pansystolic murmur at apex which was radiating to axilla. Electrocardiogram showed normal sinus rhythm. Chest X-ray showed cardiomegaly. Hand examination showed a reversible ulnar deviation of the fingers (Figures 1–3). Both first carpometacarpal (CMC) and metacarpophalangeal (MCP) joints were subluxed. Also noted was a swan neck deformity of the fingers of both hands (Figures 1, 2). All were nontender without any crepitus. Haemogram was normal. Erythrocyte sedimentation rate, anti-nuclear antibody, and antistreptolysin-O titre were negative. Hand radiographs typically confirmed reversible ulnar deviation caused by bilateral metacarpophalangeal subluxation without erosion, narrowing, or fusion of joint spaces (Figure 4). In addition, probable 'hook' lesions were noted on the radial aspect of the first left metacarpal head. 2D-transthoracic echocardiography with Doppler interrogation confirmed severe aortic regurgitation and mitral regurgitation; left ventricular dimensions were increased although left ventricular systolic function was normal. Because of the increased dimension with normal systolic function, he was referred for double valve repair.

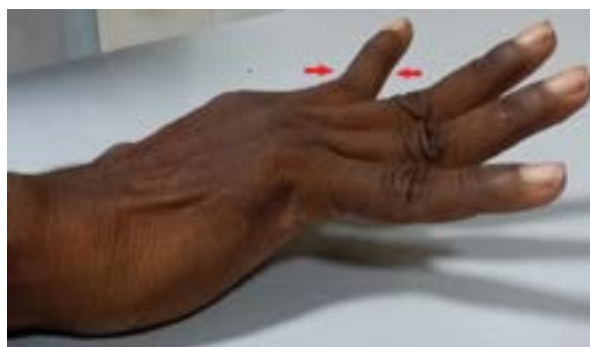
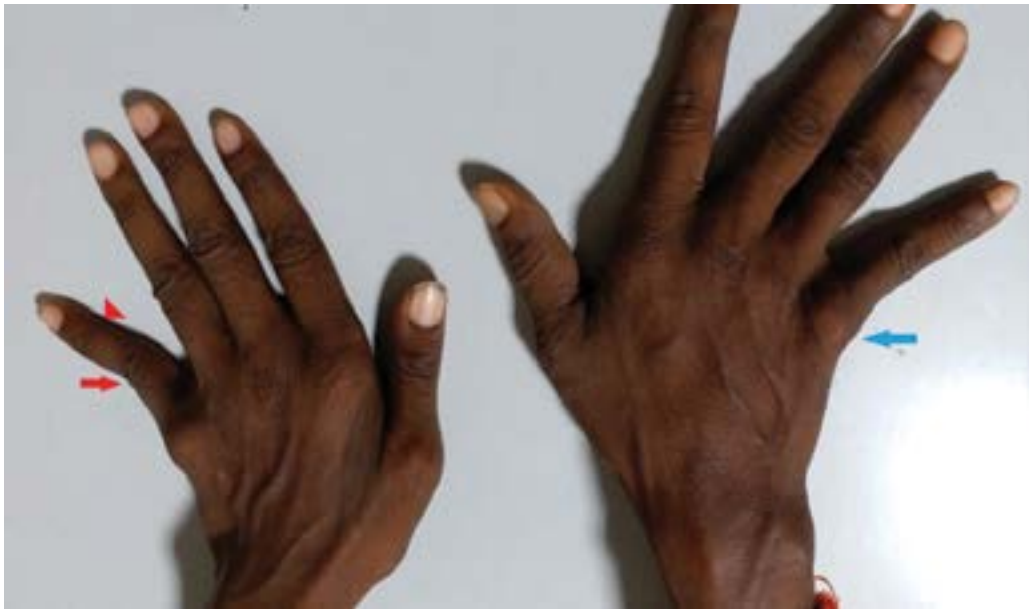
Figure 2. Swan neck deformity in Jaccoud's arthropathy of right hand in lateral view (red arrow)

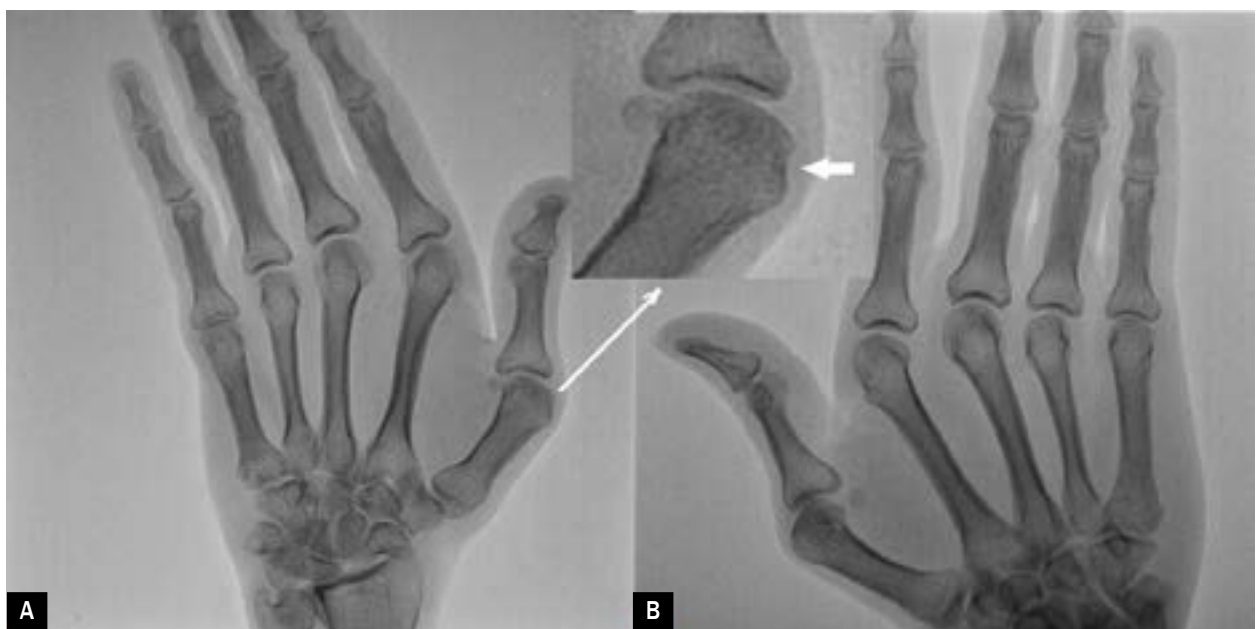## Discussion

Jaccoud's arthropathy is a deforming, 'reversible' and non-erosive condition whose prevalence is 4.2% among patients with rheumatic heart disease (RHD). It mainly affects the hands, but has also been observed in feet and shoulders [2–6]. The exact etiopathogenesis is not well known, but laxity of articular capsules and tendons are initial features when it is reversible, followed by capsular fibrosis and contractures of the joints at a late stage, by which time it may have become irreversible.

It can be symptomatic or painless and can even occur without any previous history of arthritis among patients with RHD. Although arthritis is considered to be the major diagnostic criterion for rheumatic fever, in India it can manifest with its milder form *i.e.* arthralgia, as seen in our case. The joint deformities most frequently seen in JA are ulnar deviation, swan neck, 'z'-thumb, and 'boutonniere'. These deformities vary in intensity and because it is reversible they sometimes go unnoticed. Over a long period, functional



**Figure 3.** Swan neck deformity (red arrow and arrowhead) along with 'z-deformity' (ulnar deviation – blue arrow) in Jaccoud's arthropathy of both hands



**Figure 4A, B.** Plain radiograph of both hands showing non-erosive deformities (inset view shows probable 'hook' lesion on radial aspect of first left metacarpal head – white arrow)

limitation may be noted probably secondary to local residual fibrosis leading to contractures. Therefore, at this stage, it may be misdiagnosed as rheumatoid arthritis. Clinically significant tenosynovitis has rarely been described in JA, probably because other features of the disease overshadow the symptoms related to the tendon sheaths, but in some patients crepitus can be detected. The deformities in JA are

secondary to soft tissue abnormalities which include laxity and distension of ligaments and joint capsules, which may lead to secondary deviation of the tendon from its axis, sometimes causing rupture as well. Although the presence of synovitis is well documented and may somehow contribute to the process, it is not as aggressive, and does not seem to be a main feature as it is in RA [2, 7].

Progressive fibrosis of the capsule with contractures can turn a reversible deformity into an irreversible one such as may be encountered in longstanding JA. Therefore, plain X-ray of JA reveals deformities and subluxations, without the classical erosions as seen in patients with RA, although very sensitive imaging modalities such as magnetic resonance imaging (MRI) and ultra-sound imaging may detect erosions, as reported by Ostendorf et al. [8, 9]. A classical radiographic feature of JA that is rarely described is the **hook lesion** which is observed on the palmar-radial surface of the metacarpal heads seen in plain radiograph of the

hands [10, 11]. These are the result of remodelling as an adaptive change to altered stress by the tension placed on the metacarpal head on the palmar-radial aspect [12]. Although JA has been mostly reported among patients with recurrent attacks of rheumatic fever, it can also be seen among patients with even a milder form of arthritis, or only arthralgia as in our case.

### Conflict(s) of interest

The authors declare no conflict of interest.

### Streszczenie

Artropatia (zespół) Jaccouda jest schorzeniem charakteryzującym się klinicznie „odwracalnymi” deformacjami stawów spowodowanymi zaburzeniami tkanek miękkich, a nie niszczeniem kostnych elementów stawów. Chociaż artropatia ta występuje rzadko, to opisywano przypadki JA u chorych z przewlekłą chorobą reumatyczną serca. Zazwyczaj obejmuje stawy śródrečno-paliczkowe i śródstopno-paliczkowe. Zespół ten obserwowano również w toczeniu rumieniowatym układowym (SLE), zakażeniach i chorobach nowotworowych. W niniejszej pracy przedstawiono przypadek 21-letniego chorego, u którego od 16 lat występowały bóle wielu stawów, od 4 lat – deformacje rąk i od 3 lat – wysiłkowe kołatanie serca i duszność. W badaniu przedmiotowym stwierdzono obwodowe objawy wstecznego przepływu krwi w aorcie oraz hiperdynamiczną czynność lewej komory i przewlekłą ciężką niedomykalność aortalną i mitralną. W badaniu wzrokowym wyraźnie widoczne były deformacje obu rąk w postaci odchylenia łokciowego, deformacji typu „łabędzia szyja” i kciuka w kształcie litery „z”. Na podstawie wyników badań laboratoryjnych wykluczono reumatoidalne zapalenie stawów, SLE i ostrą gorączkę reumatyczną. Wyniki badań obrazowych – badania radiologicznego (RTG) klatki piersiowej, elektrokardiografii, echokardiografii dwuwymiarowej i badania dopplerowskiego – wskazywały na przewlekłą ciężką niedomykalność aortalną i mitralną. W obrazie RTG obu rąk uwidoczniło podwichnięcia ku tyłowi w stawach nadgarstkowo-śródręcznych, które można było całkowicie skorygować. Artropatia Jaccouda obejmująca staw nadgarstkowo-śródręczny jest obserwowana wyjątkowo rzadko.

Słowa kluczowe: artropatia Jaccouda, choroba reumatyczna serca, stawy śródrečno-paliczkowe, stawy śródstopno-paliczkowe, deformacja typu „łabędzia szyja”

Folia Cardiologica 2018; 13, 6: 561–564

### References

1. Santiago MB. Jaccoud's arthropathy. *Best Pract Res Clin Rheumatol.* 2011; 25(5): 715–725, doi: [10.1016/j.berh.2011.10.018](https://doi.org/10.1016/j.berh.2011.10.018).
2. Moro C, Castro C, Lanza MG, et al. Jaccoud's arthropathy in patients with chronic rheumatic valvular heart disease. *Eur J Cardiol.* 1978; 6(6): 459–468, indexed in Pubmed: [631181](https://pubmed.ncbi.nlm.nih.gov/631181/).
3. Joseph B, Chacko V. Chronic post-rheumatic-fever arthritis (Jaccoud's arthritis) involving the feet. A case report. *J Bone Joint Surg Am.* 1984; 66(7): 1124–1125, indexed in Pubmed: [6480645](https://pubmed.ncbi.nlm.nih.gov/6480645/).
4. Mizutani W, Quismorio FP. Lupus foot: deforming arthropathy of the feet in systemic lupus erythematosus. *J Rheumatol.* 1984; 11(1): 80–82, indexed in Pubmed: [6699838](https://pubmed.ncbi.nlm.nih.gov/6699838/).
5. Arlet JB, Pouchot J. The senescent form of Jaccoud arthropathy. *J Clin Rheumatol.* 2009; 15(3): 151, doi: [10.1097/RHU.0b013e3181a023c8](https://doi.org/10.1097/RHU.0b013e3181a023c8), indexed in Pubmed: [19349798](https://pubmed.ncbi.nlm.nih.gov/19349798/).
6. Reilly PA, Evison G, McHugh NJ, et al. Arthropathy of hands and feet in systemic lupus erythematosus. *J Rheumatol.* 1990; 17(6): 777–784, indexed in Pubmed: [2388199](https://pubmed.ncbi.nlm.nih.gov/2388199/).
7. Aptekar RG, Lawless OJ, Decker JL. Deforming non-erosive arthritis of the hand in systemic lupus erythematosus. *Clin Orthop Relat Res.* 1974(100): 120–124, indexed in Pubmed: [4838392](https://pubmed.ncbi.nlm.nih.gov/4838392/).
8. Moro C, Castro C, González Lanza M, et al. [Articular sequelae of rheumatic fever (Jaccoud's arthropathy)]. *Rev Esp Cardiol.* 1978; 31(1 Pt 1): 73–78, indexed in Pubmed: [653071](https://pubmed.ncbi.nlm.nih.gov/653071/).
9. Sa RD, Galvao V, Luiz FJ, et al. D'Almeida F, Santiago M. Magnetic resonance imaging of Jaccoud's arthropathy in systemic lupus erythematosus. *Joint Bone Spine.* 2010; 77(3): 241–5.
10. Pastershank SP, Resnick D. "Hook" erosions in Jaccoud's arthropathy. *J Can Assoc Radiol.* 1980; 31(3): 174–175, indexed in Pubmed: [7419543](https://pubmed.ncbi.nlm.nih.gov/7419543/).
11. Ignaczak T, Espinoza LR, Kantor OS, et al. Jaccoud arthritis. *Arch Intern Med.* 1975; 135(4): 577–579, indexed in Pubmed: [1138673](https://pubmed.ncbi.nlm.nih.gov/1138673/).
12. Murphy WA, Staple TW. Jaccoud's arthropathy reviewed. *Am J Roentgenol Radium Ther Nucl Med.* 1973; 118(2): 300–307, indexed in Pubmed: [4712747](https://pubmed.ncbi.nlm.nih.gov/4712747/).